



Case report

Urinoma following blunt renal trauma in a patient with anomalous solitary kidney: A case report

Mitesh Karn^{a,*}, Dipendra Kandel^a, Basant Kumar Mahato^a, Sudip Thapa^b, Hari bahadur KC^b

^a School of Medicine, Gandaki Medical College Teaching Hospital and Research Center, Pokhara 33700, Nepal

^b Department of Urology, Gandaki Medical College Teaching Hospital and Research Center, Pokhara 33700, Nepal

ARTICLE INFO

Keywords:

Urinoma
Renal trauma
Trauma
Solitary kidney
Case report

ABSTRACT

Introduction and importance: Blunt traumatic injury to the genitourinary system is uncommon. Urinoma formation may occur in patients with blunt trauma after high grade renal injuries. In such cases, the presence of solitary kidney must be ruled out as it may affect treatment decisions.

Case presentation: A 21 years old male presented to our facility with complaints of abdominal pain and frank hematuria following physical assault. Physical examination revealed tenderness at the right flank. Laboratory evaluation showed a decreased hemoglobin level and urinalysis showed proteinuria and marked hematuria. Imaging findings were consistent with AAST Grade IV right renal injury affecting the renal pelvis with urinoma formation and congenital megacalyces. Incidental finding of unilateral renal agenesis on the left side was also noted. Our patient underwent Ureterscopy with double-J stenting. Subsequent ultrasonography after the procedure showed resolution of the perirenal collection.

Discussion: The presence of solitary kidney must be ruled out in cases of high grade renal trauma as operative procedures may lead to catastrophic consequences in such cases. Urinoma formation after renal trauma may occur if the renal pelvis is injured and should be managed preferably by urinary diversion in the form of ureteral stenting over other operative procedures, especially in patients with anomalous solitary kidney.

Conclusion: Presence of bilateral kidneys should be confirmed before subjecting patients with high grade renal injury to operative procedures. Early ureteric stenting appears to be an effective method of urinary diversion for management of symptomatic urinomas in patients with anomalous solitary kidney.

1. Introduction

Traumatic injuries to the genitourinary system is very uncommon, with an incidence estimated at less than 1% [1]. Of the injuries that involve genitourinary system, the kidneys are most commonly involved and blunt renal trauma is more common than its penetrating counterpart [2]. However, isolated renal injury after blunt trauma is rare. Urinoma formation after renal trauma is believed to be low (<1%) but this rate is increased after high grade renal trauma [3]. Unilateral renal agenesis may be present in patients with renal trauma and should be ruled out as it may put the patient at risk of renal insufficiency if nephrectomy is carried out in such cases.

We report a case of 21 years old male presenting to our facility after physical assault with high grade right renal injury, urinoma formation and an incidental finding of left renal agenesis. This work has been reported in line with the SCARE 2020 guidelines [4].

2. Case presentation

A 21 years old male presented to the Department of Urology at our teaching hospital with chief complaints of severe abdominal pain and bloody urine. He described the pain as a dull, constant, non-radiating, severe right flank pain which he attributed to the blows he received in that region after being involved in a brawl the previous day. He also reported observing frank hematuria later that night. Past medical and surgical history were non-revealing.

On examination, the patient had a blood pressure of 124/72 mmHg, a heart rate of 76 beats per minute, a respiratory rate of 22 and Oxygen Saturation of 94%. Abdominal examination revealed guarding and diffuse tenderness, maximum at the right flank region. Contusions and ecchymoses were absent. Initial laboratory evaluation revealed a Hemoglobin of 11.7 g/dL. Urine output was within normal limits. Urinalysis showed reddish turbid urine with proteinuria and numerous red

* Corresponding author.

E-mail address: rikkymikky@gmail.com (M. Karn).

<https://doi.org/10.1016/j.ijscr.2021.106386>

Received 10 August 2021; Received in revised form 2 September 2021; Accepted 2 September 2021

Available online 6 September 2021

2210-2612/© 2021 The Authors. Published by Elsevier Ltd on behalf of IJS Publishing Group Ltd. This is an open access article under the CC BY-NC-ND license

(<http://creativecommons.org/licenses/by-nc-nd/4.0/>).

cells. All other tests, including blood and coagulation profile, electrolytes and tests of renal function were within normal limits. Abdominal ultrasonography revealed absent left kidney, moderate right hydronephrosis, increased renal parenchymal echogenicity and perirenal fluid collection with probe tenderness in the right lumbar region. CT Urography confirmed left renal agenesis with absent left renal artery and right congenital megacalyces. Contrast extravasation was noted posteromedially, adjacent to right renal pelvis with significant urinoma formation (Figs. 1, 2 and 3). No evidence of vascular injuries were present.

Based on these findings, a diagnosis of isolated right AAST Grade IV renal injury with urinoma formation was made. The patient was then managed on an in-patient basis. Although our patient remained hemodynamically stable, he continued to experience pain and the urinary extravasation was persistent. He was subject to Ureterorenoscopy with placement of a double-J stent two days after the admission (Fig. 4). Ultrasonography two days after the procedure revealed a right-sided, partially resolved urinoma.

Our patient was discharged post-operative day 10 with resolution of his existing symptoms. He was called for a follow-up after 2 months for removal of the ureteral stent. At 1 year, he was completely well.

3. Discussion

Urinary extravasation with collecting system injury after renal trauma is classified as a grade IV injury by the American Association for the Surgery of Trauma (AAST) [5]. The accurate diagnosis of urinary extravasation requires extravasation of contrast material from the collecting system be present in CT imaging with a delayed excretory phase [6]. High grade injuries usually require some form of intervention. In the absence of hemodynamic instability, grade IV injuries are managed conservatively [7]. But sometimes, the urinary leak may lead to complications such as urinoma formation.

Urinoma is a mass formed by encapsulated extravasated urine [8]. Urinoma formation requires continued renal function, rupture of the collecting system and an element of distal obstruction [8]. The latter supports the use of ureteral stenting in the management of urinomas. The management of urinary extravasation is a very controversial topic

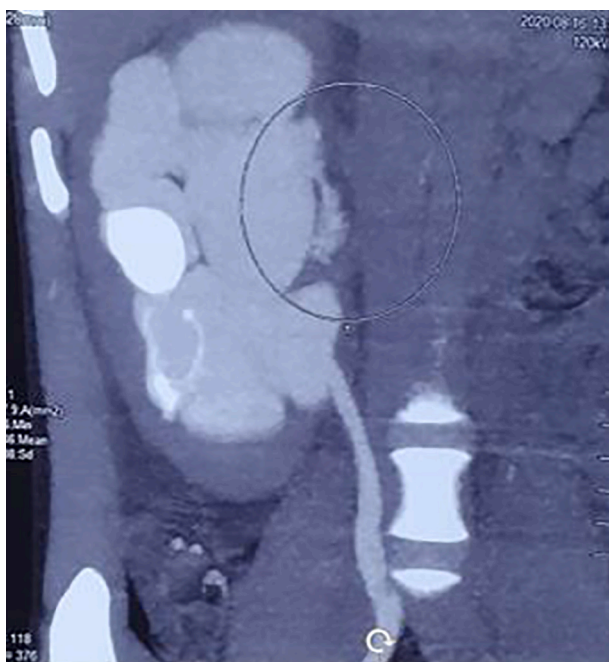


Fig. 1. Coronal CT scan during excretory phase showing rapid contrast extravasation from right kidney postero-medially, adjacent to renal pelvis.




Fig. 2. 3D Reconstruction of the Urogram confirming findings of contrast extravasation and urine leak on the right side and agenesis of kidneys on the left side.

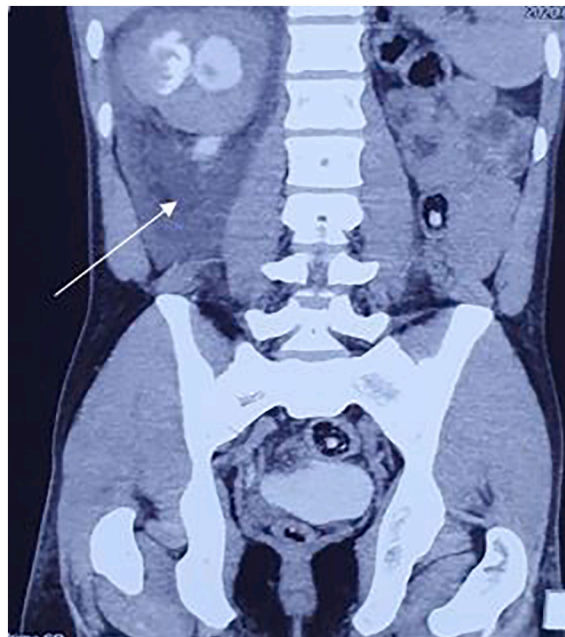

Fig. 3. Coronal CT scan showing significant urinoma formation on the right side extending inferiorly as far as the pelvic region (shown by arrow). Of note is the agenesis of kidneys on the left side.

and due to absence of specific guidelines in place, the decision to intervene is based entirely on clinician preference. Trauma surgeons usually decide to intervene by stenting early while urologists prefer a conservative approach in most cases [9]. Although most urinomas resolve spontaneously, large and medially located urinomas require some intervention to prevent complications such as page kidney, persistent hypertension, abscess formation and adhesion [10].

Unilateral renal agenesis (URA) is usually diagnosed incidentally when imaging is indicated for some other causes, such as trauma. URA has an incidence rate of about 1 in 1500 and occurs twice as more

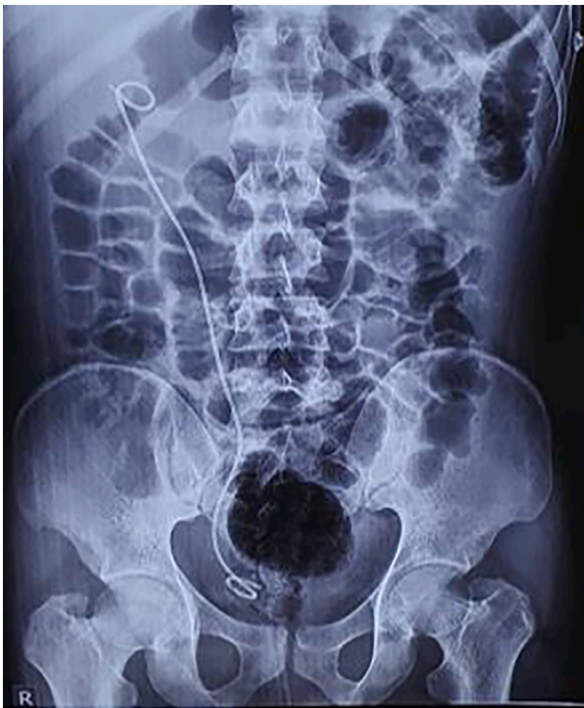

Fig. 4. AP radiograph after placement of a double-J ureteral stent.

commonly in males [11]. URA may lead to proteinuria in young patients [12]. This explains the presence of proteinuria in our case. The presence of solitary kidney is important to be considered in patients with high grade renal trauma. This is of importance as it may markedly affect the management decisions, weighing against the use of operative procedures like nephrectomy. In patients with anomalous solitary kidney with urinoma formation after renal trauma, early urinary diversion in the form of ureteral stenting may preserve renal function and prevent subsequent complications.

4. Conclusion

Though isolated traumatic injuries to genitourinary system is rare, urinary extravasation and urinoma formation after high grade renal trauma may occur. Usually, high grade renal injuries are managed by some form of intervention. It is necessary to confirm the presence of bilateral kidneys before subjecting patients with high grade renal injury to operative procedures. Early ureteric stenting appears to be an effective method of urinary diversion for management of symptomatic urinomas in patients with anomalous solitary kidney.

Funding source

This research did not receive any specific grant from funding agencies in the public, commercial, or not-for-profit sectors.

Ethical approval

No ethical approval necessary.

Consent

Written informed consent was obtained from the patient for

publication of this case report and accompanying images. A copy of the written consent is available for review by the Editor-in-Chief of this journal on request.

Guarantor

Dipendra Kandel.

Research registration

None.

Disclaimer

No patient or author details are included in the figures.

Provenance and peer review

Not commissioned, externally peer-reviewed.

CRediT authorship contribution statement

Karn M, Kandel D and KC H designed the report, reviewed the literature, edited the images and wrote the paper; Kandel D, Thapa S and Mahato B analyzed the data and revised the paper. All the authors have read and approved the final manuscript.

Declaration of competing interest

The authors report no conflicts of interest.

References

- [1] P. Paparel, A. N'Diaye, B. Laumon, J.L. Caillot, P. Perrin, A. Ruffion, The epidemiology of trauma of the genitourinary system after traffic accidents: analysis of a register of over 43 000 victims, *BJU Int.* 97 (2006) 338–341, <https://doi.org/10.1111/j.1464-410X.2006.05900.x>.
- [2] B.B. Voelzke, L. Leddy, The epidemiology of renal trauma, *Transl. Androl. Urol.* 3 (2014) 143–149, <https://doi.org/10.3978/j.issn.2223-4683.2014.04.11>.
- [3] H.S. Al-Qudah, R.A. Santucci, Complications of renal trauma, *Urol. Clin. N. Am.* 33 (2006) 41–53, <https://doi.org/10.1016/j.ucl.2005.10.005>.
- [4] for the SCARE Group, R.A. Agha, T. Franchi, C. Sohrabi, G. Mathew, The SCARE 2020 guideline: updating consensus Surgical CASE REport (SCARE) guidelines, *Int. J. Surg.* 84 (2020) 226–230, <https://doi.org/10.1016/j.ijsu.2020.10.034>.
- [5] E.E. Moore, S.R. Shackford, H.L. Pachter, J.W. McAninch, B.D. Browner, H. R. Champion, L.M. Flint, T.A. Gennarelli, M.A. Malangoni, M.L. Ramenofsky, P. G. Trafton, Organ injury scaling: spleen, liver, and kidney, *J. Trauma* 29 (1989) 1664–1666, <https://doi.org/10.1097/00005373-198912000-00013>.
- [6] B. Dane, A.B. Baxter, M.P. Bernstein, Imaging genitourinary trauma, *Radiol. Clin. N. Am.* 55 (2017) 321–335, <https://doi.org/10.1016/j.rcl.2016.10.007>.
- [7] S. Keihani, R.E. Anderson, J.M. Hotaling, J.B. Myers, Diagnosis and management of urinary extravasation after high-grade renal trauma, *Nat. Rev. Urol.* 16 (2019) 54–64, <https://doi.org/10.1038/s41585-018-0122-x>.
- [8] D. McInerney, A. Jones, J. Roylance, Urinoma, *Clin. Radiol.* 28 (1977) 345–351, [https://doi.org/10.1016/S0009-9260\(77\)80195-5](https://doi.org/10.1016/S0009-9260(77)80195-5).
- [9] S. Keihani, R.E. Anderson, M. Fiander, M.M. McFarland, G.J. Stoddard, J. M. Hotaling, J.B. Myers, Incidence of urinary extravasation and rate of ureteral stenting after high-grade renal trauma in adults: a meta-analysis, *Transl. Androl. Urol.* 7 (2018) S169, <https://doi.org/10.21037/TAU.2018.04.13>.
- [10] J.N. Reese, J.A. Fox, G.M. Cannon, M.C. Ost, Timing and predictors for urinary drainage in children with expectantly managed grade IV renal trauma, *J. Urol.* 192 (2014) 512–518, <https://doi.org/10.1016/j.juro.2014.02.039>.
- [11] L.W. Doroshov, B.S. Abeshouse, Congenital unilateral solitary kidney: report of 37 cases and a review of the literature, *Urol. Surv.* 11 (1961) 219–229. <https://pubmed.ncbi.nlm.nih.gov/13887435/>.
- [12] L.R. Argueso, M.L. Ritchey, E.T. Boyle, D.S. Milliner, E.J. Bergstralh, S.A. Kramer, Prognosis of patients with unilateral renal agenesis, *Pediatr. Nephrol.* 6 (1992) 412–416, <https://doi.org/10.1007/BF00873996>.