



Case report

Splenectomy for wandering splenomegaly in a patient with idiopathic thrombocytopenic purpura: A case report of a rare association

Ibtissem Korbi, Sophia Rabti, Mohamed Ali Chaouch^{*}, Amal Bouchrika, Khadija Zouari, Faouzi Noomene

Department of digestive surgery, Monastir University Hospital, Monastir, Tunisia



ARTICLE INFO

Keywords:

Wandering spleen
Splenectomy
Idiopathic thrombocytopenic purpura

ABSTRACT

Background: Wandering spleen (WS) is an uncommon congenital or acquired condition resulting from the absence or abnormal development of the spleen ligaments causing its outside position. WS has life-threatening complications ranging from torsion of the vascular pedicle to spleen infarction. In this paper, we report the use of open splenectomy in a female with an idiopathic thrombocytopenic purpura history with WS.

Case presentation: We report a case of a 23-year-old nulliparous female with idiopathic thrombocytopenic purpura. After complaining of chronic abdominal pain in the lower abdomen, the patient underwent an abdominal-pelvic ultrasound which showed a spleen of a pelvic seat at the size of 180 mm with homogeneous echo-structure and a free left spleen compartment. A complimentary computed tomography scan revealed ectopic splenomegaly (about 194 * 62 * 150 mm) in the pelvis with normal enhancement and no signs of infarction or torsion. A splenectomy was indicated due to the large spleen size and the patient's medical history. The post-operative course was uneventful. After the operation, an increase in the platelet count was registered, requiring aspirin administration to avoid thrombosis.

Conclusion: WS diagnosis should be considered whenever acute or chronic abdominal pain is associated with mobile abdominal or pelvic mass. Recognition of this disease is mandatory, and surgical management should not be delayed.

1. Introduction

The spleen is approximately 12 cm long and 7 cm wide intraperitoneal organ [1]. The absence or malformations of normal splenic suspensory ligaments attaching the spleen to the diaphragm, colon, and retroperitoneum is the major cause of wandering spleen (WS). In this case, the spleen, only connected to the hilum, wanders in the pelvis, causing torsion of the splenic pedicle and partial or complete spleen infarction [2]. It can be a congenital or acquired condition [3,4]. Its incidence is <0.5 %, frequently reported in females [5]. Diagnosis is often an occasional finding during radiological exams [6]. Conservative treatment may lead to high complication risks such as acute torsion, splenic gangrene, splenic abscesses, acute pancreatitis, and necrosis of the pancreatic tail [6]. Thus, surgery is the standard gold treatment [7]. To allow organ preserving surgery, early diagnosis of WS is of great significance [8]. However, in the case of association with idiopathic thrombocytopenic purpura (ITP), the preserving treatment is debatable.

In this study, we used SCARE 2020 guidelines [9] for a case report to report the use of open splenectomy in a female with an ITP history associated with WS.

2. Case report

We report a case of a 23-year-old female with a medical history of ITP. She has suffered from recurrent abdominal pain in the lower abdomen for two years. A physical examination of the abdomen revealed a visible tender pelvic mass measuring almost 150 mm. Laboratory data showed a reduced platelet count of $95 \times 10^3/\mu\text{L}$, a white blood cell count of $4.9 \times 10^3/\mu\text{L}$, and a haemoglobin level of 11.8 g/dL; other biochemical parameters were normal. Whole abdomen ultrasonography revealed a free left splenic compartment with an increased spleen (180 mm) in the left pelvic area with a homogeneous echo structure. A computed scan was performed. It showed ectopic splenomegaly measuring 190 * 65 mm of homogeneous enhancement (Fig. 1).

^{*} Corresponding author.

E-mail address: Docmedalichaouch@gmail.com (M.A. Chaouch).

<https://doi.org/10.1016/j.ijscr.2022.107719>

Received 17 May 2022; Received in revised form 27 September 2022; Accepted 27 September 2022

Available online 30 September 2022

2210-2612/© 2022 The Authors. Published by Elsevier Ltd on behalf of IJS Publishing Group Ltd. This is an open access article under the CC BY-NC-ND license (<http://creativecommons.org/licenses/by-nc-nd/4.0/>).

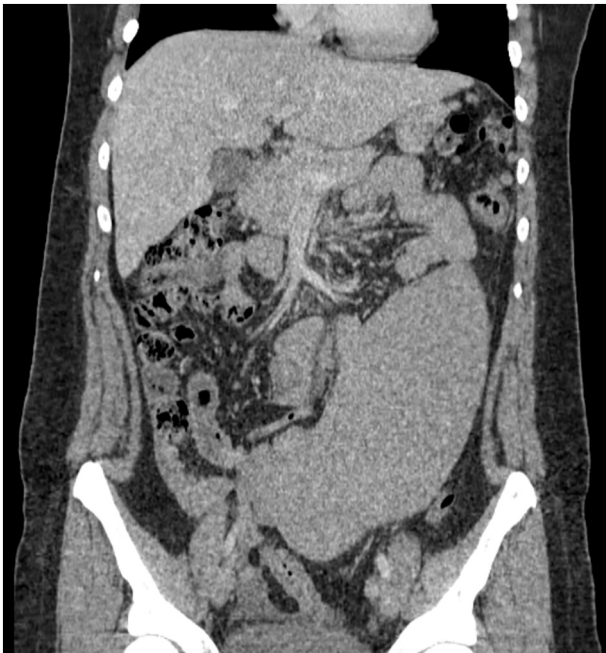

Fig. 1. CT scan showing splenomegaly with pelvic seat.

The tail of the pancreas was rotated on the right paravertebral seat with homogeneous enhancement. The splenic vessels rotated from the median seat to the right para-vertebral, and the artery was winding in a half-turn while remaining permeable. No radiological signs of torsion were found (Fig. 2). Due to the symptomatic splenomegaly, a laparotomy was performed. Steroid or any other medical treatment was not contemplated due to the WS. Examination of the abdomen cavity showed a voluminous spleen suspended only by its coiled pedicle in the pelvis with average rotation of the pancreas. However, the spleen pedicle was normal, with no sign of torsion. Other internal organs were normal. Because of the enormous splenomegaly and the patient's medical history, splenectomy was undertaken. The postoperative course was uneventful. The platelet count of $480 \times 10^3/\mu\text{L}$. The patient was discharged seven days postoperatively. The pathological examination of the spleen concluded with an enlarged normal spleen. Pneumococcal, meningococcal, and influenza vaccinations were administered during the postoperative period. However, an increase in the platelet count was registered after three months, which required aspirin administration to

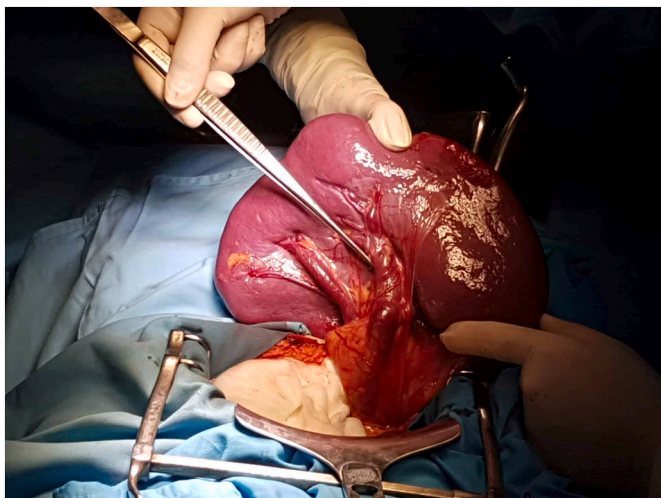


Fig. 2. CT scans showing spleen pedicle.

avoid thrombosis.

3. Discussion

This case was reported, written using SCARE guidelines [9], the use of open splenectomy in a female with an idiopathic thrombocytopenic purpura history with WS. The major lymphoid tissue is accumulated in the spleen, the organ that prenatally produces blood cells and post-natally controls them [10]. A fault explicates WS in the normal embryological development of its suspensor ligament [10]. WS is not hereditary. The absence or weakness of one or more of these suspensory ligaments may explain the congenital form of WS, which resulted from a problem in the fusion of the dorsal mesogastrium with the posterior abdominal wall during the second month of embryogenesis [10]. However, many acquired conditions may cause weakness of suspensory ligaments, such as injuries, connective tissue disease, or multiparity. Splenomegaly, which occurs in chronic myeloid leukaemia, lymphoma, malaria, and lymphosarcoma, is another acquired cause of WS [5]. This pathology may arise in people of all ages. Still, it is recurrent in 10-years old males and more frequent in female patients with a preference for multiparous women, probably due to the hormonal imbalance inducing the weakness of suspensory ligaments [4]. However, there is no evidence in the literature suggesting an association between WS and idiopathic thrombocytopenic purpura. Clinical symptoms were not specific. The patient may be asymptomatic or nauseous, vomiting, sickness, acute, intermittent, or chronic colicky abdominal pain due to torsion and detorsion of the splenic pedicle, abdominal distention, constipation, palpable, movable mass in the abdomen or pelvic [6]. Acute abdominal pain is the main sign of a complicated form of WS. It is due to splenic torsion, reported in about 0.2 to 0.3 % of patients suffering from WS, and it is more frequent in splenomegaly [2,11]. Medical history only cannot lead to the diagnosis of WS, and physical examination findings are variable depending on the location of the spleen and complications. In this case, the patient was suffering from chronic abdominal pain. Physical examination revealed a pelvic mass with a smooth surface. Being an adult female, ovarian mass was suspected; however, abdominal ultrasound showed a free left spleen compartment and a spleen of a pelvic seat. Radiological exams are the key to providing a positive diagnosis [2]. Ultrasound is the most often used [12]. It is sensibility in about 65 % of cases. It can assess the splenic vascular supply, localization, blood flow in the splenic artery and vein, and thrombi, but it still underestimates the splenic pedicle torsion [12]. A computed Tomography scan is the diagnostic modality of choice. It is diagnostic for WS in 79 % of cases by viewing the absence of the spleen in its normal position and its presence in another abdominal region, usually in the pelvis.

Moreover, a CT scan may also show the presence of ascites [13]. Spleen vascular supply may be studied by angiography, but it is invasive, more expansive, and time-consuming. Magnetic resonance imaging is another option to identify infarcts. Although using one of these radiographic investigations is enough to reveal the splenomegaly and the absence of the spleen from its normal location with high certainty, other studies have revealed that more than one imaging in >92 % of cases modality was used [8]. Yet, like in our case, the exact diagnosis was not made at the first ultrasound, and a CT was demanded. This practice is probably explained by the unwillingness of primary physicians to diagnose such a rare entity and their need to reconfirm it with different methods before surgical treatment.

Surgery is the treatment of choice. Splenopexy is the gold standard when there is no torsion, avoiding overwhelming post-splenectomy sepsis risk. It is performed when the wandering spleen is not infarcted and has no signs of hypersplenism or splenomegaly [2]. In our case, the organopexy was not contemplated due to the existence of ITP. Splenectomy remains the sole option in splenic torsion with irreversibly damaged vascular supply when the spleen is enlarged, ruptured, or with signs of hypersplenism [8]. Nowadays, laparoscopic splenectomy is the best method to treat WS, but splenomegaly may be a contraindication

for laparoscopy. European Association of Endoscopic Surgeons guidelines define “massive splenomegaly” as a spleen with a long axis > 15 cm and weight of 600 g, and “supermassive splenomegaly” along axis > 20 cm and weight of 1600 g. The European Association of Endoscopic Surgeons recommended hand-assisted laparoscopic splenectomy. While the laparoscopic approach is feasible, we have preferred to plan an open intervention. Splenectomy should be associated with prophylactic antibiotics to avoid complications [11]. Vaccination against pneumococcus, *Haemophilus influenzae*, and meningococcus should also be given.

4. Conclusion

WS can be presented with various signs and symptoms. We should be aware of this entity, especially facing recurrent abdominal symptoms. CT is the best exam for diagnosis. Timely diagnosis and interventions are crucial for spleen preservation and avoiding life-threatening complications. In addition, in case of association with ITP, the surgical procedure could be modified, and a splenectomy could be the treatment of choice than an organopexy.

Consent

Written informed consent was obtained from the patient to publish this case report and accompanying images. On request, a copy of the written consent is available for review by the Editor-in-Chief of this journal.

Funding

No funding.

Ethical approval

The study is exempt from ethic approval at our institution.

Author contribution

This list of authors contains all the surgeons that have operated on the patients in this series.

Guarantor

Mohamed Ali Chaouch.

Research registration number

Not applicable.

Declaration of competing interest

The authors declare no competing interest.

Acknowledgements

There were no acknowledgements to mention it.

Provenance and peer review

Not commissioned, externally peer-reviewed.

References

- [1] N.S. Chauhan, S. Kumar, Torsion of a wandering spleen presenting as acute abdomen, *Pol. J. Radiol.* 81 (2016) 110.
- [2] M.T. Kafadar, Y. Daduk, M. Karakoç, Acute abdomen due to torsion of the wandering spleen: a rare clinical presentation, *Ulus Travma Veacil Cerrahi Derg.* 27 (1) (2021) 154–156.
- [3] M. Aaqib, S. Omair, C. Naseer, S. Tahleel, B. Ovais, S. Faiz, et al., Wandering spleen with torsion of splenic vein and gastric varices, *J. Pediatr. Surg. Case Rep.* 65 (2021), 101756.
- [4] S.B. Abebe, Y.A. Teferi, Wandering spleen with torsion presenting as a rare case of acute abdomen, *Clin. Surg. Res. Commun.* 5 (4) (2021) 09–12.
- [5] P. Vlastarakos, A. Rouvali, M. Giourga, A. Gerebe, E. Domali, Wandering spleen: a rare case of an adnexal lesion, *Cureus* 13 (9) (2021).
- [6] D.C. Reisner, C.M. Burgan, Wandering spleen: an overview, *Curr. Probl. Diagn. Radiol.* 47 (1) (2018) 68–70.
- [7] A. Petroianu, K.R. Sabino, Wandering splenomegaly reduction after splenopexy, *Int. J. Surg. Case Rep.* 85 (2021), 106273.
- [8] M. Masroor, M.A. Sarwari, Torsion of the wandering spleen as an abdominal emergency: a case report, *BMC Surg.* 21 (1) (2021) 1–5.
- [9] R.A. Agha, T. Franchi, C. Sohrabi, G. Mathew, A. Kerwan, A. Thoma, et al., The SCARE 2020 guideline: updating consensus Surgical CAse REport (SCARE) guidelines, *Int. J. Surg.* 84 (2020) 226–230.
- [10] I. Varga, P. Galfiova, M. Adamkov, L. Danisovic, S. Polak, E. Kubikova, et al., Congenital anomalies of the spleen from an embryological point of view, *Med. Sci. Monit.* 15 (12) (2009) 269–276.
- [11] W. Sergi, S. D'Ugo, T.R.L. Marchese, S. Garritano, F. Perrone, F. Manoochehri, et al., Colonic obstruction caused by wandering spleen: case report and literature review, *Int. J. Case Rep. Images* 12 (2021), 101203Z01WS2021.
- [12] R. Lombardi, L. Menchini, T. Corneli, A. Magistrelli, A. Accinni, L. Monti, et al., Wandering spleen in children: a report of 3 cases and a brief literature review underlining the importance of diagnostic imaging, *Pediatr. Radiol.* 44 (3) (2014) 279–288.
- [13] R. Alghamdi, A. Alzahrnai, A. Alosaimi, I. Albabtain, Infarcted wandering spleen: a case report from Saudi Arabia, *J. Surg. Case Rep.* 2021 (6) (2021), rjab277.