

Received: 2017.04.28  
Accepted: 2017.05.31  
Published: 2017.08.08

ISSN 1941-5923  
© Am J Case Rep, 2017; 18: 871-877  
DOI: 10.12659/AJCR.905093

# Postoperative Biliary Leak Treated with Chemical Bile Duct Ablation Using Absolute Ethanol: A Report of Two Cases

Department of Gastrointestinal Surgery, Tenri Hospital, Tenri, Nara, Japan

Authors' Contribution:  
Study Design A  
Data Collection B  
Statistical Analysis C  
Data Interpretation D  
Manuscript Preparation E  
Literature Search F  
Funds Collection G

BDEF **Maho Sasaki**  
ACDEF **Tomohide Hori**  
ABDF **Hiroaki Furuyama**  
BF **Takafumi Machimoto**  
BF **Toshiyuki Hata**  
BF **Yoshio Kadokawa**  
BF **Tatsuo Ito**  
BF **Shigeru Kato**  
BF **Daiki Yasukawa**  
BF **Yuki Aisu**  
BF **Yusuke Kimura**  
BF **Yuichi Takamatsu**  
F **Taku Kitano**  
ADF **Tsunehiro Yoshimura**

**Corresponding Author:** Tomohide Hori, e-mail: [horitomo@tenriyorozu.jp](mailto:horitomo@tenriyorozu.jp)  
**Conflict of interest:** None declared

## Case series

**Patient:** Female, 72 • Male, 78  
**Final Diagnosis:** Postoperative biliary leakage  
**Symptoms:** Refractory and intractable symptoms  
**Medication:** —  
**Clinical Procedure:** Chemical ablation  
**Specialty:** Surgery

**Objective:** Unusual setting of medical care

**Background:** Postoperative bile duct leak following hepatobiliary and pancreatic surgery can be intractable, and the postoperative course can be prolonged. However, if the site of the leak is in the distal bile duct in the main biliary tract, the therapeutic options may be limited. Injection of absolute ethanol into the bile duct requires correct identification of the bile duct, and balloon occlusion is useful to avoid damage to the surrounding tissues, even in cases with non-communicating biliary fistula and bile leak.

**Case Report:** Two cases of non-communicating biliary fistula and bile leak are presented; one case following pancreaticoduodenectomy (Whipple's procedure), and one case following laparoscopic cholecystectomy. Both cases were successfully managed by chemical bile duct ablation with absolute ethanol. In the first case, the biliary leak occurred from a fistula of the right posterior biliary tract following pancreaticoduodenectomy. Cannulation of the leaking bile duct and balloon occlusion were achieved via a percutaneous route, and seven ablation sessions using absolute ethanol were required. In the second case, perforation of the bile duct branch draining hepatic segment V occurred following laparoscopic cholecystectomy. Cannulation of the bile duct and balloon occlusion were achieved via a transhepatic route, and seven ablation sessions using absolute ethanol were required.

**Conclusions:** Chemical ablation of the bile duct using absolute ethanol is an effective treatment for biliary leak following hepatobiliary and pancreatic surgery, even in cases with non-communicating biliary fistula. Identification of the bile duct leak is required before ethanol injection to avoid damage to the surrounding tissues.

**MeSH Keywords:** Bile • Ethanol • Postoperative Complications

**Full-text PDF:** <https://www.amjcaserep.com/abstract/index/idArt/905093>




1895



2



4



32

## Background

The postoperative biliary leak is a recognized complication of hepatobiliary and pancreatic surgery, with a reported frequency ranging from 0.5% to 15.6% [1,2–7]. Independent risk factors for postoperative biliary leak include preoperative cholangitis, complex hepatectomy, and a long operating time [6,8]. Biliary leak following hepatobiliary and pancreatic surgery may have an impact on the postoperative course and long-term patient outcome [2,9]. Postoperative biliary complications of bile duct leak, such as biliary collections or bile peritonitis, can be chronic and difficult to treat [2,9]. Therefore, invasive approaches such as radiologic intervention, endoscopic treatment, or surgical therapy are often required [3,9,10]. A definition and classification of the anatomical sites of biliary leak following hepatobiliary and pancreatic surgery have been developed to determine the optimal management [5,9].

If the leaking bile duct communicates with the main biliary tract, usually with the common bile duct (CBD), endoscopic biliary drainage can be effective [5,9]. However, if there is no fistula that communicates with the CBD, an endoscopic approach cannot be used. In such cases of ‘non-communicating’ biliary leak, bile leakage may become chronic, and therapeutic options are limited. Several treatments have been reported for chronic and complicated bile leak following hepatobiliary and pancreatic surgery, including percutaneous drainage, endoscopic drainage including endoscopic nasobiliary drainage

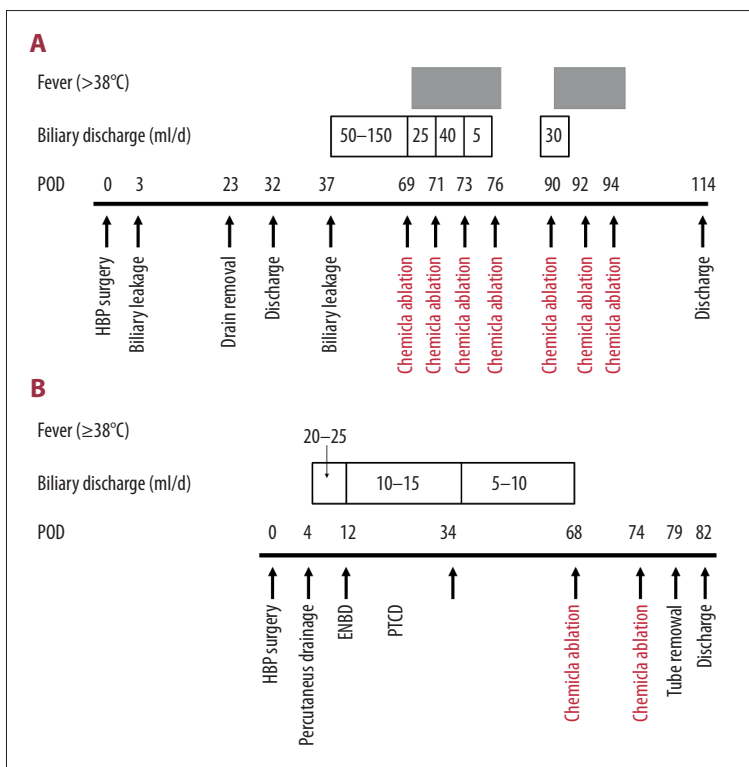
to the CBD, invasive surgery including choledochojejunostomy and liver resection, radiological intervention including portal embolization, the use of fibrin glue sealant, and chemical ablation [2,3,10–17]. However, each therapeutic option has advantages and disadvantages [2].

Although selective biliary infusion of absolute ethanol has been performed safely without serious complications in a rat experiment model [18], only a few attempts have been made to determine the clinical feasibility of selective intrahepatic chemical ablation with absolute ethanol for postoperative biliary leak in patients [2,11,15–17,19]. This case report presents two cases of bile leak following hepatobiliary and pancreatic surgery that were successfully treated by chemical ablation with absolute ethanol and discuss the key points and pitfalls of this therapeutic option.

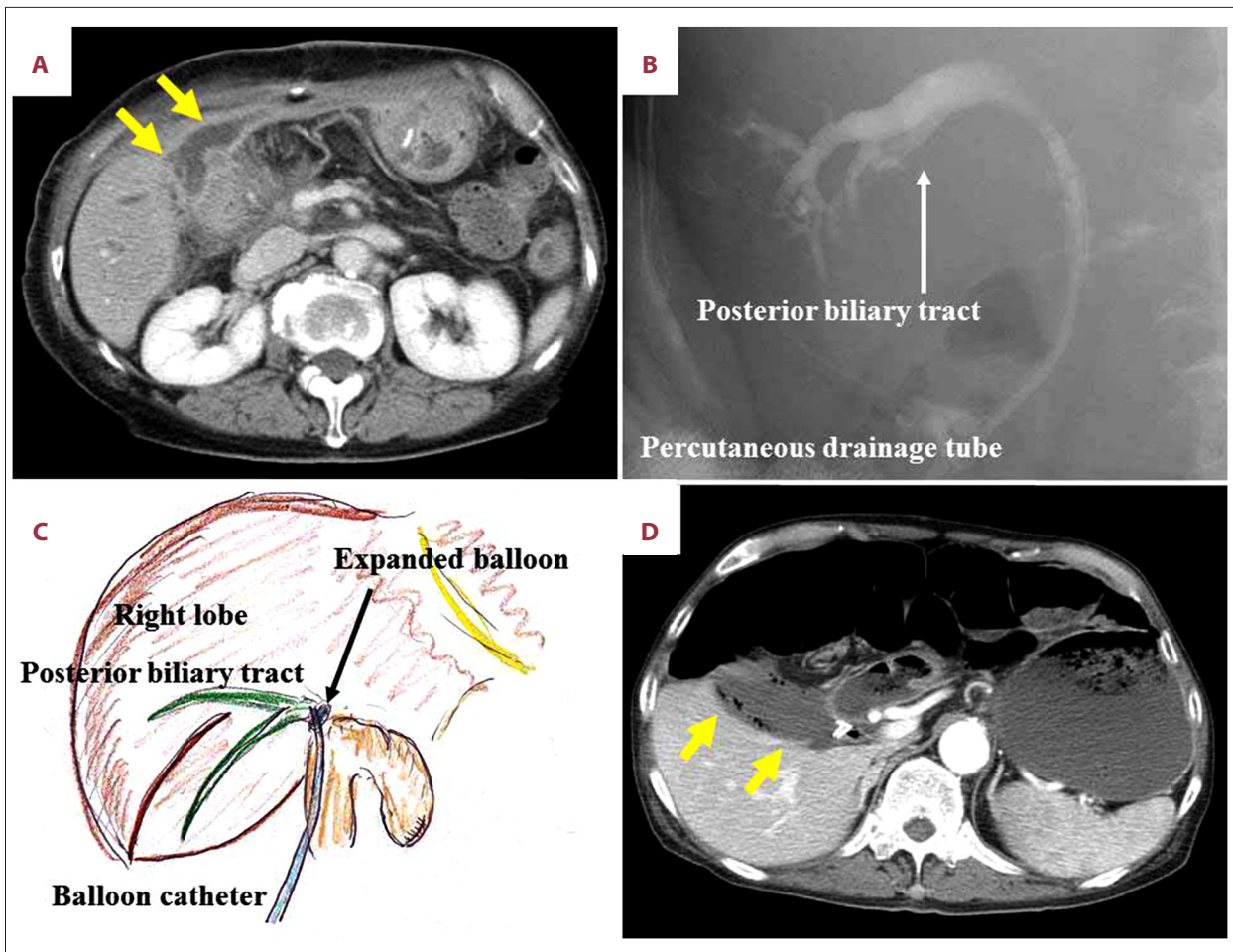
## Case Reports

### Case 1

A 72-year-old woman underwent pancreaticoduodenectomy (Whipple’s procedure) for treatment of pancreatic cancer. The intraperitoneal drain showed biliary leak on postoperative day 3, and the subsequent volume of bile decreased daily. The intraperitoneal drain was removed on postoperative day 23, and the patient was discharged from hospital on postoperative day



**Figure 1.** Clinical course and management. (A) Case 1; (B) Case 2. ENBD – endoscopic nasobiliary drainage; POD – postoperative day; PTCD – percutaneous transhepatic cholangiodrainage.



**Figure 2.** Imaging studies of the chemical ablation procedure. (A) Enhanced computed tomography (CT) showed abscess formation (yellow arrow). (B) Fistulography showed that the biliary tract of the right posterior segment had caused the biliary leak. (C) A direct approach into the right posterior branch was possible via the percutaneous route, and the isolated bile duct was chemically ablated using balloon occlusion. (D) Enhanced computed tomography revealed abscess formation (yellow arrow).

32. However, biliary leak was observed from the surgical site on postoperative day 37, and she was urgently readmitted to hospital (Figure 1A).

On re-admission, enhanced computed tomography (CT) showed abscess formation (Figure 2A). A percutaneous drain was placed into the biliary collection, and the discharge volume ranged from 50 to 150 ml/day for approximately 30 days (Figure 1A). After the discharge volume had decreased, fistulography showed that the bile leak was from the biliary tract of the right posterior segment (Figure 2B). Because the right posterior bile duct branch was joined with the common bile duct (CBD) based on the preoperative imaging, we speculated that the right posterior bile duct might have been injured during the choledochojunostomy procedure.

Direct cannulation into the right posterior biliary branch was performed via a percutaneous route, and the cannula balloon

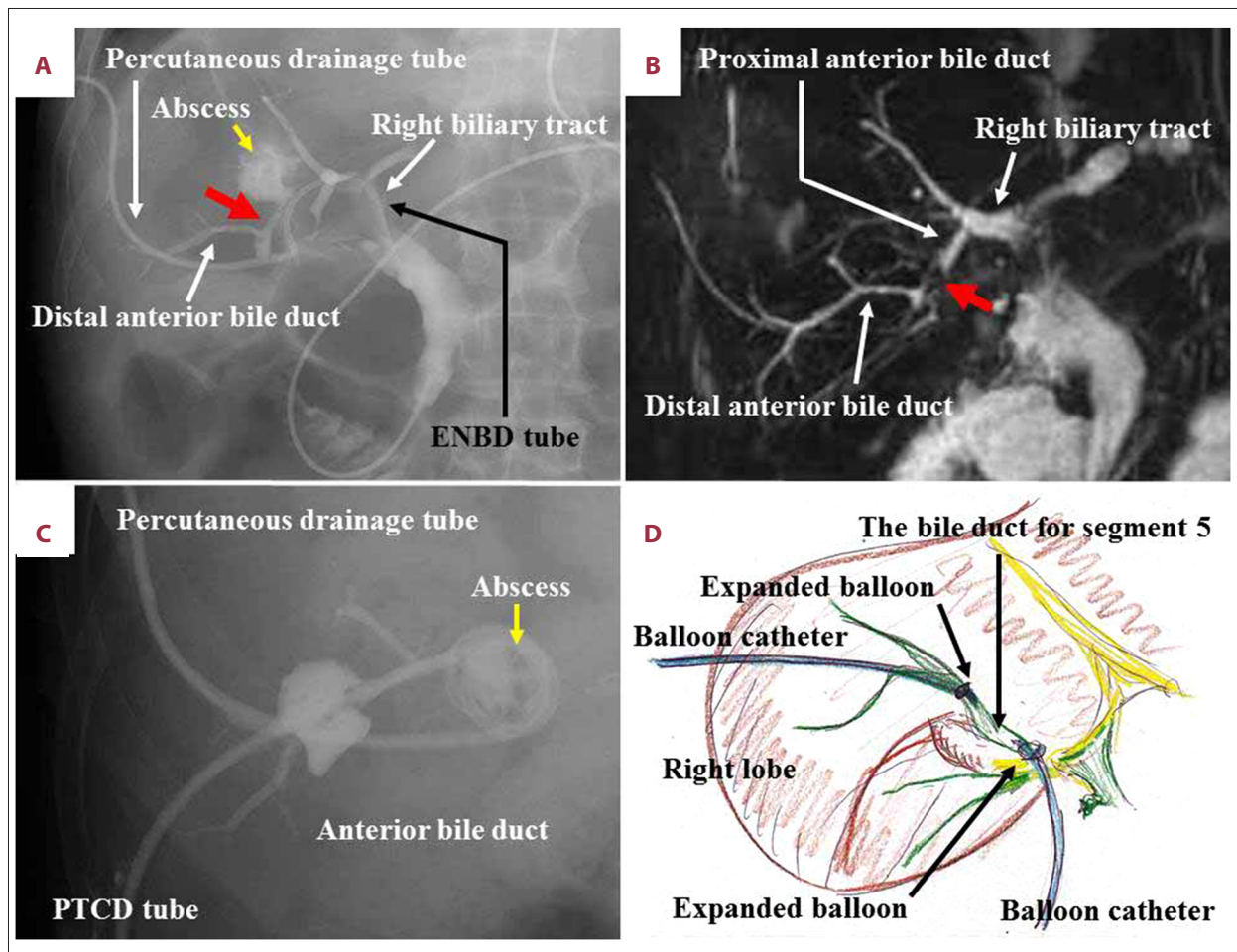
was then expanded (Figure 2C). After confirming that there was no potential damage to adjacent organs, we performed chemical ablation of the isolated bile duct with absolute ethanol. This ablation procedure was repeated, and the volume of bile leak immediately decreased. However, additional ablations with absolute ethanol were required because the bile leak returned. Although seven sessions of chemical ablation were required for a curative effect, complete healing was obtained (Figure 1A). The chemical ablation procedures are summarized in Table 1.

## Case 2

A 78-year-old man underwent laparoscopic cholecystectomy for treatment of a gallstone. Signs of postoperative inflammation until postoperative day 4, and enhanced CT imaging showed abscess formation near the liver bed (Figure 2D). Bile leak was shown by CT-guided percutaneous drainage of the

**Table 1.** Surgical procedures of chemical ablation by absolute ethanol.

Case	Session number	Injected volume (ml)	Exposure time (minute)		
Case #1	1	4	15		
	2	4	10		
	3	3	10		
	4	5	10		
	5	3	10		
	6	10	(3+5+2)	30	(10+10+10)
	7	6	(1+5)	10	
Case #2	1	2	10		
	2	3	10		



**Figure 3.** Dual drainage methods: percutaneous and endoscopic. (A) Damage to the anterior bile duct was suspected (red arrow). (B) Magnetic resonance cholangiopancreatography revealed a surgical injury of the biliary branch for segment V (red arrow). (C) A selective approach route into the responsible bile duct was acquired not via a percutaneous route, but via a transhepatic route. (D) The area was occluded, by ballooning occlusion of both percutaneous but transhepatic routes, using the “shut away” technique. ENBD – endoscopic nasobiliary drainage; PTCD – percutaneous transhepatic cholangiodrainage.

intraabdominal abscess. An endoscopic nasobiliary drainage tube was inserted for direct drainage of the CBD, and dual drainage, percutaneous and endoscopic, were completed. Damage to the anterior bile duct was suspected (Figure 3A), and magnetic resonance cholangiopancreatography showed an incisional injury of the bile duct branch draining hepatic segment V (Figure 3B).

An attempt to cannulate this bile duct branch via a percutaneous route was unsuccessful. However, a transhepatic bile duct drainage tube was successfully placed (Figure 3C). After the abscess had decreased in size and the fistula had matured, the occluded area was completed by balloon occlusion of both the percutaneous and transhepatic routes (Figure 3D). Chemical ablation was performed without exposure of adjacent organs to absolute ethanol. Two chemical ablations were performed with no associated fever or pain, and these two ablation procedures appeared to be adequate for successful treatment of the bile leak (Figure 2B). The chemical ablation procedures are summarized in Table 1.

## Discussion

Chemical ablation is a type of sclerotherapy of the biliary epithelium that includes the use of absolute ethanol. Absolute ethanol is cytotoxic to the biliary epithelium by causing membrane lysis and protein denaturation [2]. Despite the advantages of ethanol, including the fact that it is widely available, inexpensive, efficacious, and safe, only a few attempts have been made to use this agent for chemical ablation in patients with postoperative biliary leak [2,11,15–17,19]. Also, because absolute ethanol causes inflammation and fibrosis of the bile duct and also destroys the adjacent hepatic parenchyma, the production and secretion of bile are reduced [2,11,15–17,19]. As these two cases have demonstrated, if the procedure of bile duct ablation using absolute ethanol is successful, the patient should be hospitalized until complete healing is achieved.

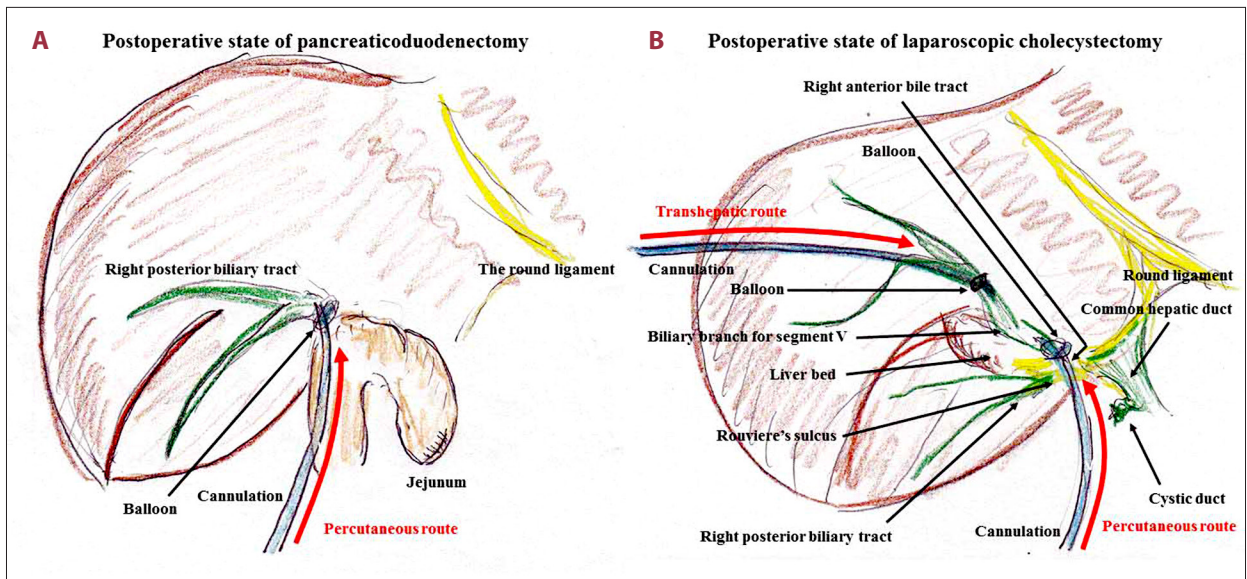
In the two cases we have presented in this report, curative treatment was completed with few complications (Figure 1). However, clinicians should be aware that patients may experience a prolonged low-grade fever or short-term pain even after successful chemical ablation [15], but these minor complications may be controlled by conventional anti-inflammatory agents. However, damage to the surrounding tissues and perilesional organs are more severe potential complications, and this is why patients should be monitored in hospital following the procedure. Hopefully, if the ethanol infusion catheter is positioned to enter directly only the responsible bile duct, these complications should be avoided [2,15,17,20]. As these two cases have shown, an effort should be made to ensure that no adjacent tissues are exposed to absolute ethanol.

The direct approach into the affected bile duct via a percutaneous route is the simplest technique, as shown in Case 1. Conversely, in Case 2, fistulography through the drainage tube and endoscopic cholangiography revealed biliary leak from the anterior biliary tract. Because this leaking bile duct did not communicate with the proximal hilar bile duct and common bile duct (CBD), two balloon catheters (Selecon MP catheter, 5.2 French; Terumo Clinical Supply Co., Ltd., Kakamigahara, Japan) were separately placed into the leaking bile ducts via percutaneous and transhepatic routes (Figure 3D). Chemical ablation was then repeated during balloon occlusion. Injection therapy with absolute ethanol can be performed safely and effectively using a balloon-occlusion catheter [2,17,20]. Hence, percutaneous sclerotherapy by ethanol injection can be useful even in cases of non-communicating biliary fistula and bile leak [2,19,20].

Chemical ablation induces atrophy of the infused hepatic segments with compensatory hypertrophy of the noninfused segments [2]. This phenomenon implies that chemical ablation with absolute ethanol, in a similar way to portal vein embolization, can act as a driving force for atrophy and hypertrophy of the liver [2]. Paradoxically, the target liver volume of chemical ablation should be within a semi-segmental area (not a segmental area) to ensure hepatic remnant viability [2,18]. The liver volumes of the responsible areas in our two cases were relatively large (Figures 2B, 3C). Therefore, repeated sessions and longer observation periods might be required [21]. A multidisciplinary approach should be considered for refractory and intractable biliary leak [21].

Cases of non-communicating biliary fistula and bile leak can be refractory and intractable to therapy, requiring various treatments and a long time for recovery [6]. A more drastic approach, of invasive surgery, may be required for intractable complications after hepatobiliary and pancreatic surgery as an option to shorten the disease duration and/or hospital stay [2,22–26]. However, minimally invasive therapy should be chosen for the management of iatrogenic complications, and surgical treatment is required only when conservative treatment or radiological management fails [23,27–29]. A diagram of the procedure in our two cases are shown in Figure 4.

The dose of absolute ethanol and frequency of ablation sessions required remain controversial [2]. The doses and the frequencies of absolute ethanol infusion are summarized in Figure 1 and Table 2. Several sessions of chemical ablation may be required to stop biliary leak [2,20], although one injection may be enough in some patients [18]. During repeated sessions, the performance of each session at an interval of several days seems to be suitable to avoid complications [2,30].



**Figure 4.** Diagram of the interventions used. (A) Case 1; (B) Case 2.

**Table 2.** Chemical ablation for biliary leak following hepatobiliary (HPB) surgery.

- Initially, drainage route(s) to the biliary collection or abscess should be made
- The abscess should be allowed to decrease in size with subsequent maturation of the fistula
- Every effort should be made to avoid exposure adjacent tissues to absolute ethanol
- A multidisciplinary approach and appropriate devices should be considered to create an occluded area
- Chemical ablation is possible even in noncommunicating cases if definitive isolation of the leaking bile duct has been assured
- The target area should be within a semi-segmental region, not a segmental region
- The injection dose and exposure time should be carefully determined
- Sessions are carefully repeated at optimal intervals until the biliary leakage stops

As these two cases have shown, following infusion of absolute ethanol, bile leak may continue at a constant daily volume, but then gradually decreases and finally stops [20]. According to previous reports of chemical ablation for postoperative biliary leak, key points for successful treatment can be summarized as follows. (i) Initially, drainage route(s) to the biliary collection/abscess should be made. (ii) The abscess should be allowed to decrease in size with subsequent maturation of the fistula. (iii) Every effort should be made to avoid the exposure of unrelated tissues to absolute ethanol. (iv) A multidisciplinary approach and appropriate devices should be considered to create an occluded area. (v) Chemical ablation is possible even in non-communicating cases if definitive isolation of the leaking bile duct has been assured. (vi) The target area should be within a semi-segmental region, not a segmental region. (vii) The injection dose and exposure time should be carefully determined. (viii) Sessions should be carefully repeated at optimal intervals until the biliary leak stops (Table 2).

Each country has health care that may be nationalized or that uses a health insurance system. The Japanese government employs a universal health insurance system. Therefore,

novel procedures in Japan are not authorized until they are included in the health insurance system listing by the governmental council [31]. At this time, chemical ablation for biliary leak is not listed in the Japanese health insurance system, although this option potentially has substantial benefits in patients with intractable biliary leakage [2,11,15–17,19]. Specific regulations and ethical policies for advanced therapeutic options for biliary leak should be established, and technological developments should be disseminated worldwide. Currently, chemical ablation has been used for other diseases, including in the large bowel [32]. The authors hope that by presenting these two cases, further clinical studies on the technique of bile duct ablation to control postoperative biliary leak using absolute ethanol will be conducted.

## Conclusions

These two cases have shown that chemical ablation of the bile duct using absolute ethanol is an effective treatment for biliary leak following hepatobiliary and pancreatic surgery, even in cases with biliary fistula that are non-communicating

with the common bile duct (CBD). Identification of the bile duct leak is required before ethanol injection, to avoid damage to the surrounding tissues, and balloon occlusion may be used. Although ablation of biliary leak using absolute ethanol is not currently supported by clinical management guidelines, future large-scale controlled studies are recommended

## References:

1. Viganò L, Ferrero A, Sgotto E et al: Bile leak after hepatectomy: Predictive factors of spontaneous healing. *Am J Surg*, 2008; 196: 195–200
2. Kyokane T, Nagino M, Sano T, Nimura Y: Ethanol ablation for segmental bile duct leakage after hepatobiliary resection. *Surgery*, 2002; 131: 111–13
3. Hai S, Tanaka H, Takemura S et al: Portal vein embolization for an intractable bile leakage after hepatectomy. *Clin J Gastroenterol*, 2012; 5: 287–91
4. Massoumi H, Kiyici N, Hertan H: Bile leak after laparoscopic cholecystectomy. *J Clin Gastroenterol*, 2007; 41: 301–5
5. Strasberg SM, Hertl M, Soper NJ: An analysis of the problem of biliary injury during laparoscopic cholecystectomy. *J Am Coll Surg*, 1995; 180: 101–25
6. Sakamoto K, Tamesa T, Yukio T et al: Risk factors and managements of bile leakage after hepatectomy. *World J Surg*, 2016; 40: 182–89
7. Kajiwara T, Midorikawa Y, Yamazaki S et al: Clinical score to predict the risk of bile leakage after liver resection. *BMC Surg*, 2016; 16: 30
8. Sano T, Shimada K, Sakamoto Y et al: One hundred two consecutive hepatobiliary resections for perihilar cholangiocarcinoma with zero mortality. *Ann Surg*, 2006; 244: 240–47
9. Koch M, Garden OJ, Padbury R et al: Bile leakage after hepatobiliary and pancreatic surgery: A definition and grading of severity by the International Study Group of Liver Surgery. *Surgery*, 2011; 149: 680–88
10. Sadakari Y, Miyoshi A, Ohtsuka T et al: Percutaneous transhepatic portal embolization for persistent bile leakage after hepatic resection: Report of a case. *Surg Today*, 2008; 38: 668–71
11. Choi KM, Jang HJ, Kwak JH et al: Management of postoperative bilomas and biliary injuries associated with laparoscopic cholecystectomy with intrabiliary ethanol ablation and micro-coil embolization. *Hepatogastroenterology*, 2014; 61: 27–30
12. Ishii T, Hatano E, Furuyama H et al: Preventive measures for postoperative bile leakage after central hepatectomy: A multicenter, prospective, observational study of 101 patients. *World J Surg*, 2016; 40: 1720–28
13. Nagino M, Kanai M, Morioka A et al: Portal and arterial embolization before extensive liver resection in patients with markedly poor functional reserve. *J Vasc Interv Radiol*, 2000; 11: 1063–68
14. Kobayashi S, Takeda Y, Nakahira S et al: Fibrin sealant with polyglycolic acid felt vs. fibrinogen-based collagen fleece at the liver cut surface for prevention of postoperative bile leakage and hemorrhage: A prospective, randomized, controlled study. *J Am Coll Surg*, 2016; 222: 59–64
15. Kataoka M, Oeda Y, Yoshioka S et al: Percutaneous transhepatic ethanol ablation for postoperative bile leakage after a hepatectomy. *Hepatogastroenterology*, 2011; 58: 988–91
16. Shimizu T, Yoshida H, Mamada Y et al: Postoperative bile leakage managed successfully by intrahepatic biliary ablation with ethanol. *World J Gastroenterol*, 2006; 12: 3450–52
17. Matsumoto T, Iwaki K, Hagino Y et al: Ethanol injection therapy of an isolated bile duct associated with a biliary-cutaneous fistula. *J Gastroenterol Hepatol*, 2002; 17: 807–10
18. Kyokane T, Nagino M, Oda K, Nimura Y: An experimental study of selective intrahepatic biliary ablation with ethanol. *J Surg Res*, 2001; 96: 188–96
19. Kusano T, Kida H, Nishiwaki Y et al: Percutaneous sclerotherapy for intractable external biliary fistula after hepatectomy. *Int Surg*, 2003; 88: 72–75
20. Sakaguchi T, Shibasaki Y, Morita Y et al: Postoperative bile leakage managed by interventional intrabiliary ethanol ablation. *Hepatogastroenterology*, 2011; 58: 157–60
21. Menclova K, Belina F, Pudil J et al: Bile leakage after liver resection: A retrospective cohort study. *Rozhl Chir*, 2015; 94: 516–21
22. Dell AJ, Krige JE, Jonas E et al: Incidence and management of postoperative bile leaks: A prospective cohort analysis of 467 liver resections. *S Afr J Surg*, 2016; 54: 18–22
23. Latteri S, Vecchio R, Angiello A: Iatrogenic biliary lesions and stenosis. *G Chir*, 1997; 18: 61–64
24. Abdel Wahab M, el-Ebiedy G, Sultan A et al: Postcholecystectomy bile duct injuries: Experience with 49 cases managed by different therapeutic modalities. *Hepatogastroenterology*, 1996; 43: 1141–47
25. Hogan AM, Hoti E, Winter DC et al: Quality of life after iatrogenic bile duct injury: A case control study. *Ann Surg*, 2009; 249: 292–95
26. Flum DR, Cheadle A, Prael C et al: Bile duct injury during cholecystectomy and survival in medicare beneficiaries. *JAMA*, 2003; 290: 2168–73
27. Saad N, Darcy M: Iatrogenic bile duct injury during laparoscopic cholecystectomy. *Tech Vasc Interv Radiol*, 2008; 11: 102–10
28. Hori T, Oike F, Furuyama H et al: Protocol for laparoscopic cholecystectomy: Is it rocket science? *World J Gastroenterol*, 2016; 22: 10287–303
29. Hoekstra LT, van Gulik TM, Gouma DJ, Busch OR: Posthepatectomy bile leakage: How to manage. *Dig Surg*, 2012; 29: 48–53
30. Shimamura T, Nakajima Y, Une Y et al: Efficacy and safety of preoperative percutaneous transhepatic portal embolization with absolute ethanol: A clinical study. *Surgery*, 1997; 121: 135–41
31. Hori T, Kaido T, Iida T et al: Comprehensive guide to laparoscope-assisted graft harvesting in live donors for living-donor liver transplantation: perspective of laparoscopic vision. *Ann Gastroenterol*, 2017; 30: 118–26
32. Isik A, Soyuturk M, Süleyman S et al: Correlation of bowel wall thickening seen using computerized tomography with colonoscopies: A preliminary study. *Surg Laparosc Endosc Percutan Tech*, 2017 [Epub ahead of print]

to determine whether this method may be of value in hepatobiliary surgery.

## Conflict of interest

None.