

Kounis syndrome associated with amoxicillin/clavulanic acid

ABSTRACT

Kounis syndrome (KS) is a life-threatening medical condition that causes severe allergic reaction and acute coronary syndrome (ACS). We describe the case of 56-year-old woman who developed ACS following an anaphylactic reaction to amoxicillin/clavulanic acid. Immediately after the administration of amoxicillin/clavulanic acid, she presented a chest pain, cutaneous allergic, hypotension, and ST depression on the electrocardiogram. After the necessary diagnostic test, the final diagnosis was variant I of KS.

Key words: Amoxicillin/clavulanic acid; anaphylactic shock; Kounis syndrome

Introduction

Kounis syndrome (KS) was first described in 1991 by Kounis and Zavras.^[1] It is characterized by the occurrence of acute coronary syndrome (ACS) and allergic reactions. KS is also known as allergic angina or allergic myocardial infarction. Several causes of KS have been reported, including drug treatment (antibiotic, analgesics), various medical conditions (angioedema, bronchial asthma); and environmental exposure (ant, bee, and wasp sting).^[1,2] The main mechanism proposed is the vasospasm of coronary arteries. Here, we report a case of 56-year-old woman who developed ACS following an anaphylactic reaction to amoxicillin/clavulanic acid.

Case Report

A 56-year-old woman, hypertensive and historical of myomectomy for symptomatic uterine fibroids. She had no personal or family history of allergy. The patient was going to be operated to tympanoplasty. In the operating room, she was

monitored by pulse oximetry, noninvasive blood pressure, and electrocardiogram (ECG). She was hemodynamically stable with a blood pressure of 150/85 mmHg.


She received 2 g amoxicillin/clavulanic acid in antibiotic prophylaxis. Directly after the administration of amoxicillin/clavulanic acid, she complained of chest discomfort, nausea, vomiting, and sweating associated to generalized erythema and urticaria rashes. Her blood pressure and heart rate of 60/23 mmHg and 133 bpm, respectively. Following administration of intravenous fluid, ephedrine boluses 9 mg, parenteral corticosteroids 120 mg of methylprednisolone, and antihistamines 50 mg of promethazine. Her blood pressure rose to 100/65 mmHg, but her chest discomfort continued. The patient's ECG showed ST depression in V4, V5, and V6 leads [Figure 1]. Intravenous 5000 IU heparin and 600 mg clopidogrel were administered in the operating room. The operation is reported, and she was transferred to the cardiology intensive care unit. One hour after, her

This is an open access article distributed under the terms of the Creative Commons Attribution-NonCommercial-ShareAlike 3.0 License, which allows others to remix, tweak, and build upon the work non-commercially, as long as the author is credited and the new creations are licensed under the identical terms.

For reprints contact: reprints@medknow.com

How to cite this article: Shimi A, Touzani S, Derkaoui A, Khatouf M. Kounis syndrome associated with amoxicillin/clavulanic acid. Saudi J Anaesth 2016;10:444-5.

Access this article online

Website: www.saudija.org	Quick Response Code
DOI: 10.4103/1658-354X.177329	

SHIMI A, TOUZANI S, DERKAOUI A, KHATOUF M

Department of Anesthesiology and Intensive Care, Intensive Care Unit A1, Hassan II University Hospital, Sidi Mohamed Ben Abdellah University, Fes, Morocco

Address for correspondence: Dr. Abdelkarim Shimi, Intensive Care Unit A1, Hassan II University Hospital, Sidi Mohamed Ben Abdellah University, Fes, Morocco. E-mail: akshimi@gmail.com

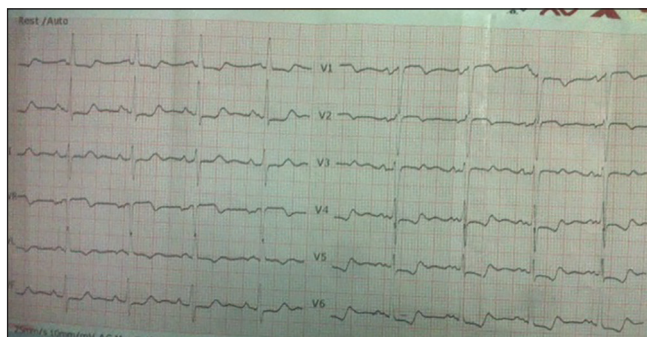


Figure 1: Electrocardiogram showed ST depression in V4, V5, and V6 leads

chest discomfort totally resolved and a check-up ECG was completely normal.

Troponin I levels were high (7.9 ng/ml) and transthoracic echocardiography showed normal left ventricular systolic functions with an ejection fraction of 60%. Coronarography was performed 24 h later, revealed normal.

Following catheterization, her medical was continued with antihistamines, 100 mg/day aspegic and 75 mg/day clopidogrel for 1 month.

Our final diagnosis was KS secondary to amoxicillin/clavulanic acid. The patient did not experience recurrent angina during hospitalization, and she was discharged on the 6th day.

Discussion

Following the first report of acute myocardial infarction during a prolonged allergic reaction to penicillin in 1950, the occurrence of allergic reaction and ACS, termed KS, has gained acceptance as a cause of coronary artery spasm.^[1,2] KS was first described in 1991. It is characterized by the simultaneous appearance of an allergic reaction and an ACS.^[2,3]

There are several causes that have been reported as capable of inducing KS.^[4] These include a number of drugs (antibiotic, analgesics, contrast media, corticosteroids, intravenous anesthetics, nonsteroidal anti-inflammatory drugs, skin disinfectants, thrombolytics, anticoagulants), various conditions (angioedema, bronchial asthma, urticaria, food allergy, exercises induced allergy, mastocytosis, serum sickness), and environmental exposures (stings of ants, bees, wasps, jellyfish, grass cutting, millet allergy, poison ivy, latex contact, shellfish eating, viper venom poisoning). The mechanism of this syndrome are characterized by coronary artery vasospasm due to the mast cell degranulation and the subsequent release of vasoactive mediators.^[3] The most important vasoactive mediators responsible for coronary

artery spasm and consequences of KS are histamine, serotonin, and leukotrienes.

Three type of KS has been described. The type I variant describes patient with normal coronary arteries without any cardiovascular risk factors;^[5] the type II variant includes patients with the preexisting atheromatous disease and type III are associated with drug-eluting stent thrombosis.^[5,6] In the present case, coronary angiography displayed normal coronary arteries with an elevated level of troponin and transient ST changes in the ECG following exposure to allergenic insult amoxicillin/clavulanic acid. Our case corresponds to the type I variant of KS.

The management of patients with KS differs from those for nonallergic common ACS.^[7] These patients need treatment with steroids, antihistamines, fluid replacement, possibly epinephrine, oxygen, and antithrombotics.

Anti-ischemic treatment including aspirin, clopidogrel, beta-blocker, nitrates, statin, as well as angiotensin-converting enzyme inhibitor were initiated.

Anaphylaxis by amoxicillin/clavulanic acid is most likely responsible for the severe ACS in the present case. We call attention to this rare entity because allergic myocardial infarction, if not recognized and management in time may cause life-threatening conditions.

Financial support and sponsorship

Nil.

Conflicts of interest

There are no conflicts of interest.

References

1. Kounis NG, Zavras GM. Histamine-induced coronary artery spasm: the concept of allergic angina. *Br J Clin Pract* 1991;45:121-8.
2. Pfister CW, Plice SG. Acute myocardial infarction during a prolonged allergic reaction to penicillin. *Am Heart J* 1950;40:945-7.
3. Kounis NG, Zavras GM. Histamine-induced coronary artery spasm: The concept of allergic angina. *Br J Clin Pract* 1991;45:121-8.
4. Gázquez V, Dalmau G, Gaig P, Gómez C, Navarro S, Mercé J. Kounis syndrome: Report of 5 cases. *J Investig Allergol Clin Immunol* 2010;20:162-5.
5. Wada T, Abe M, Yagi N, Kokubu N, Kasahara Y, Kataoka Y, *et al.* Coronary vasospasm secondary to allergic reaction following food ingestion: A case of type I variant Kounis syndrome. *Heart Vessels* 2010;25:263-6.
6. Venturini E, Magni L, Kounis NG. Drug eluting stent-induced Kounis syndrome. *Int J Cardiol* 2011;146:e16-9.
7. Akyel A, Murat SN, Cay S, Kurtul A, Ocek AH, Cankurt T. Late drug eluting stent thrombosis due to acemetacine: Type III Kounis syndrome: Kounis syndrome due to acemetacine. *Int J Cardiol* 2012;155:461-2.