

Partial resolution of chronic unilateral sinonasal obstructive disease in a cat using a temporary polyvinylchloride stent

Journal of Feline Medicine and Surgery Open Reports
1–8

© The Author(s) 2020

Article reuse guidelines:



sagepub.com/journals-permissions

DOI: 10.1177/2055116920943689

journals.sagepub.com/home/jfmsopenreports

This paper was handled and processed by the European Editorial Office (ISFM) for publication in *JFMS Open Reports*



James D Brown¹ , Dennis J Woerde¹ ,
Karon L Hoffmann^{1,2}, Wen-Meng Liu¹,
Sarah Goldsmid¹ and Narelle L Brown¹

Abstract

Case summary A 3-year-old male neutered domestic shorthair cat presented for further investigation of a swollen left eyelid and a hard, non-painful bony swelling over the left frontal sinus. Physical examination revealed no nasal discharge or airflow through the left nostril. A CT of the head revealed a left frontal sinus obstruction with expansile remodelling and osteolucency. Drainage of the frontal sinus obstruction was alleviated via placement of a temporary polyvinylchloride (PVC) stent that was left in place for 6 weeks. Purulent material removed from the frontal sinus returned a positive culture for *Pseudomonas aeruginosa* susceptible to marbofloxacin that was continued for 4 weeks, and for an additional 2 weeks after stent removal. A left-sided mucoid nasal discharge returned 3 months after removal of the stent. Repeat CT performed 20 months after surgery found the presence of a gas-filled frontal sinus and partial resolution in the amount of fluid within the mid and rostral nasal cavity. A repeat positive culture for *P. aeruginosa* was also obtained. The exact cause of the chronic unilateral sinonasal obstruction remains unclear, but an underlying chronic rhinitis with secondary obstructive frontal sinusitis or sinus mucocoele with secondary nasal extension was suspected.

Relevance and novel information Chronic rhinosinusitis in cats can be a challenging condition to treat and cure. This case illustrates the partial resolution of chronic unilateral sinonasal obstructive disease in a cat using a temporary PVC stent.

Keywords: Frontal sinus; paranasal sinus; stent; chronic rhinosinusitis; mucocoele; mucopyocoele

Accepted: 18 June 2020

Case description

A 3-year-old male neutered domestic shorthair cat presented to the referring veterinary surgery for a swelling over the left frontal bone. The cat was adopted at 5 months of age from a rescue organisation and was initially noted to have a serous left-sided nasal discharge without any concurrent sneezing, followed by a 2-year history of left-sided mucoid nasal discharge. Three months prior to presentation, the cat was seen at a primary accession veterinarian for a swollen left eyelid, chemosis and a hard, non-painful bony swelling over the left frontal bone. The cat was treated for suspected conjunctivitis with topical neomycin sulfate

and polymixin B sulfate (Amacin; Jurox) q12h and doxycycline 5mg/kg PO q24h for a period of 10 days. Routine biochemistry and haematology were performed and were within normal limits. *Cryptococcus gattii* antigen, and feline immunodeficiency virus

¹Animal Referral Hospital, Homebush, NSW, Australia

²Imaging Vets, Putney, NSW, Australia

Corresponding author:

James D Brown BSc (Hons), BVSc, MANZCVS (Surgery),
Animal Referral Hospital, 250 Parramatta Road Homebush,
Homebush West, Sydney, NSW 2140, Australia
Email: j.brown@arhvets.com



Creative Commons Non Commercial CC BY-NC: This article is distributed under the terms of the Creative Commons

Attribution-NonCommercial 4.0 License (<https://creativecommons.org/licenses/by-nc/4.0/>) which permits non-commercial use, reproduction and distribution of the work without further permission provided the original work is attributed as specified on the SAGE and Open Access pages (<https://us.sagepub.com/en-us/nam/open-access-at-sage>).

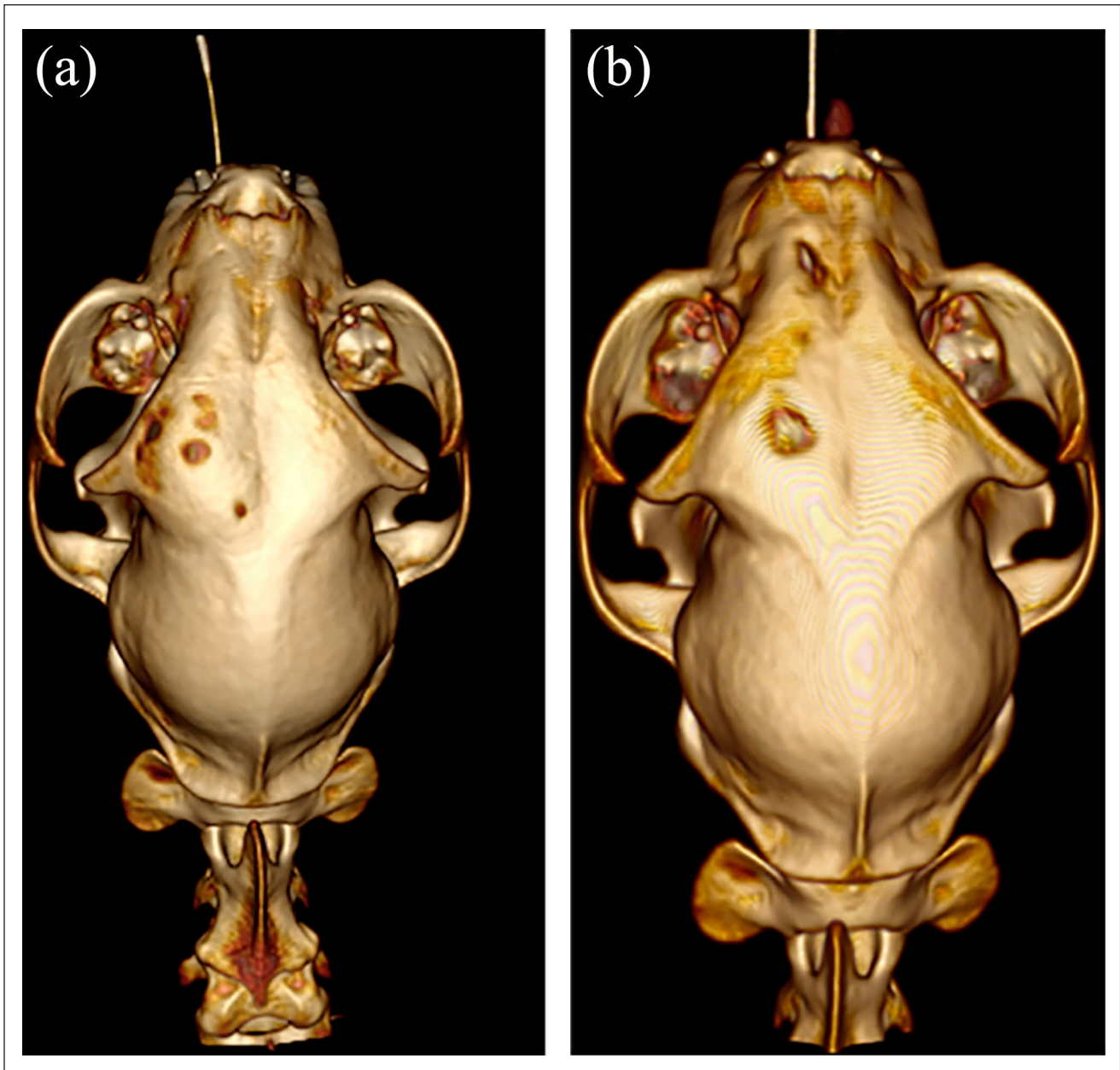


Figure 1 Three-dimensional CT reconstruction of the head. (a) Initial study showing bony expansion and focal osteolucency of the left frontal bone; and (b) 20 months post-treatment showing bony expansion and trephination burr holes

(FIV)/feline leukaemia virus (FeLV) blood antibody/antigen tests, respectively, were negative.

On referral, a firm non-painful bony swelling over the left frontal bone and oedema of the left upper eyelid that extended to the medial canthus and rostrally to the nasal bridge were found on physical examination. Epiphora of the left eye was also present. No nasal discharge or airflow were noted in the left nostril when

hair was placed in front of the nares. No other abnormalities were noted.

The cat was sedated with 0.2mg/kg butorphanol intravenously (IV) and anaesthesia induced with 1 mg/kg alfaxalone (Alfaxan; Jurox) IV. A CT of the skull was performed using a 64 slice CT (Avanto; Siemens) with bone and pre- and post-contrast soft tissue algorithm using 1 mm slices.

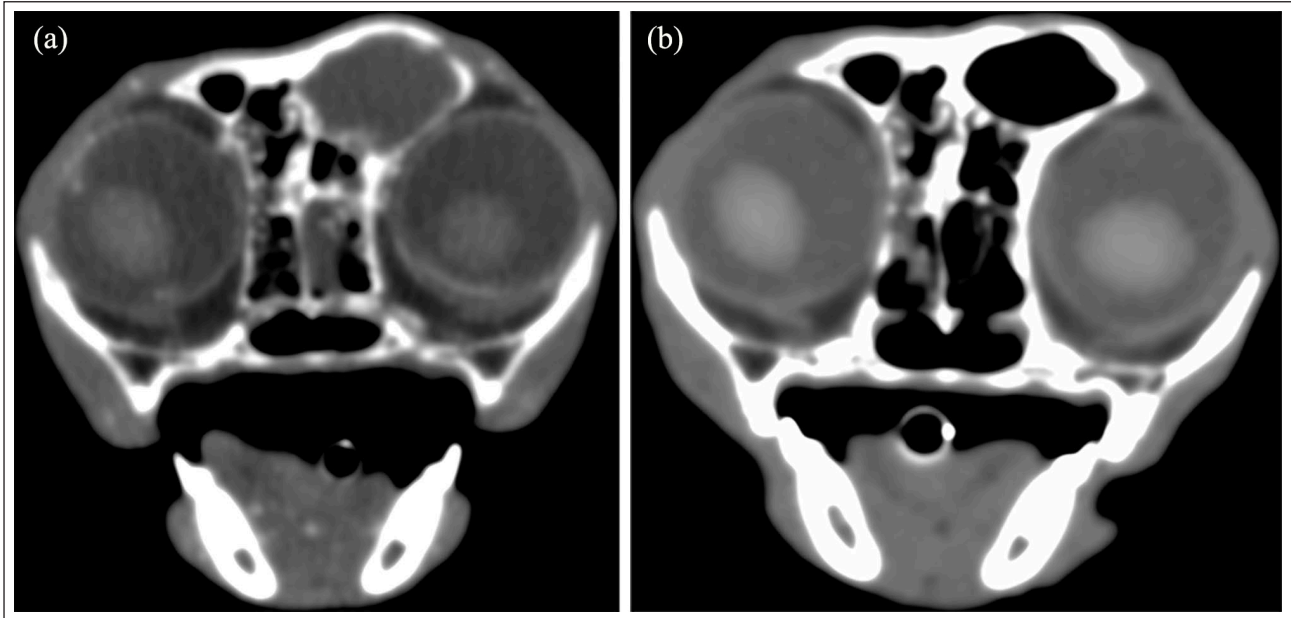


Figure 2 Axial CT with soft tissue algorithm. (a) Initial study showing non-contrast-enhancing, uniform moderately attenuating material in the left frontal sinus; and (b) 20 months post-treatment showing normal gas attenuation within the left frontal sinus

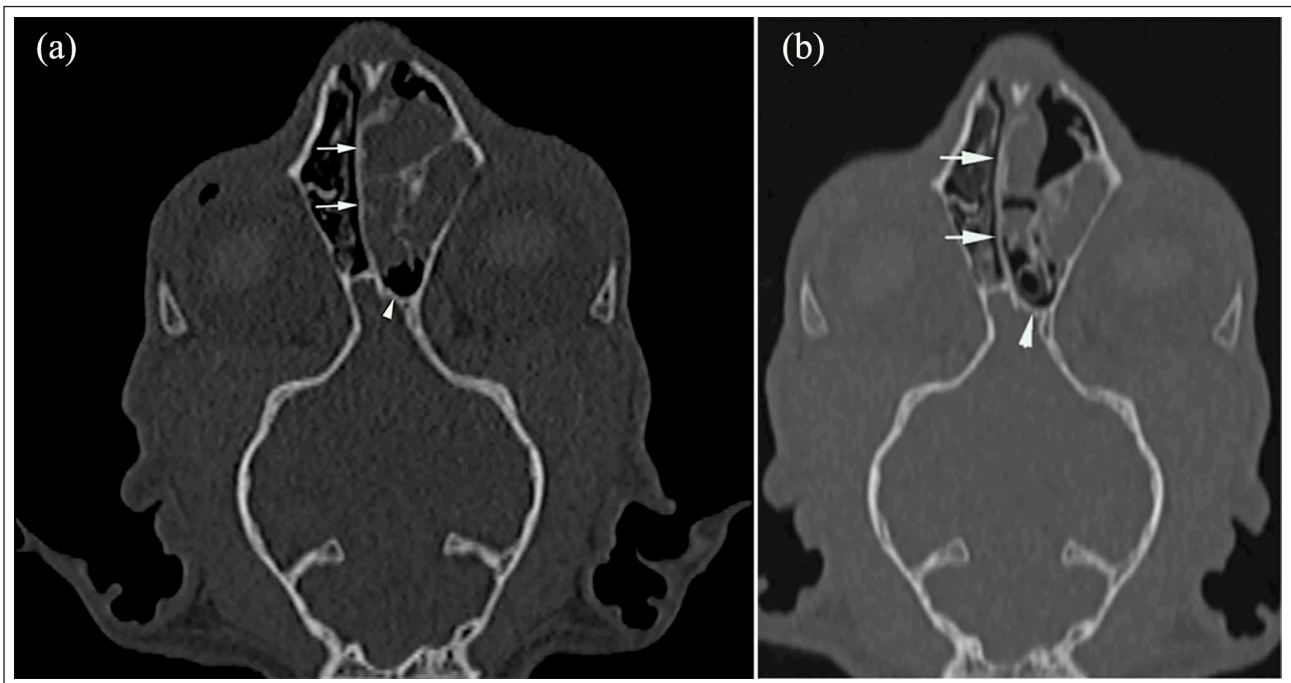


Figure 3 Dorsal CT with bone algorithm. (a) Initial study showing expansile region in the caudal nasal cavity of a uniform attenuation that is non-contrast enhancing with a reduction in the number of nasal conchae, deviation of the nasal septum to the right of midline (arrows) and remodelling of the left cribriform plate (arrowhead); and (b) 20 months post-treatment showing partial resolution of the signs within the left nasal cavity with loculated mucinous fluid present within the rostral-to-mid nasal cavity

CT images revealed hyperostosis of the caudal part of the left frontal bone with bony thinning and expansion of the left front sinus and focal region of frontal bone osteolucency (Figure 1).

The left frontal sinus was filled with uniform moderately attenuating material with density of 47–101 Hounsfield units (HU). On post-contrast administration there were no signs of contrast enhancement or rim

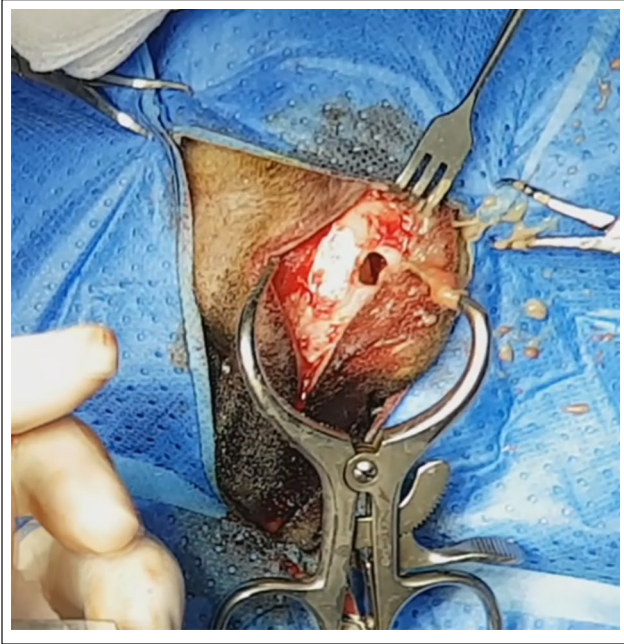


Figure 4 Trephine hole in left frontal sinus after aspiration of material

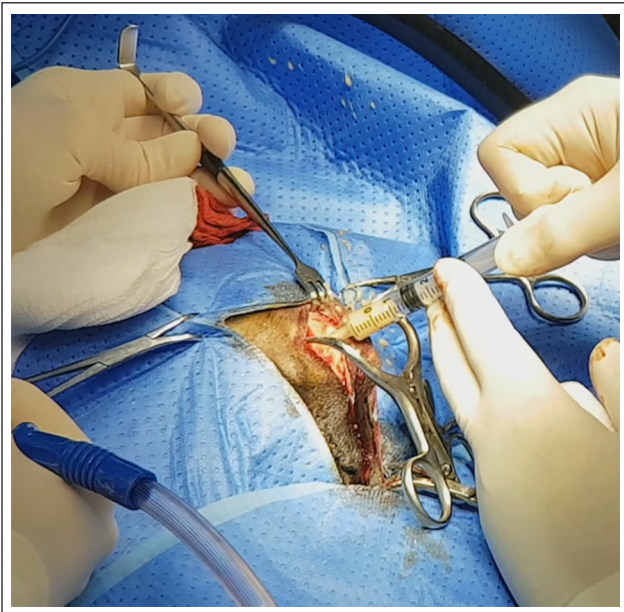


Figure 5 Aspiration of purulent-looking material from the left frontal sinus

enhancement. There was also scattered mucinous fluid within the left sphenoid sinus (Figure 2).

The left frontonasal aperture was not clearly seen and there were similar uniform and moderately attenuating regions present in the dorsal, middle and common nasal meatus with expansion of the shape of the left maxillary bone. There was deviation of the nasal septum to the right of midline, reduction in the number of nasal conchae present within the left nasal cavity relative to the

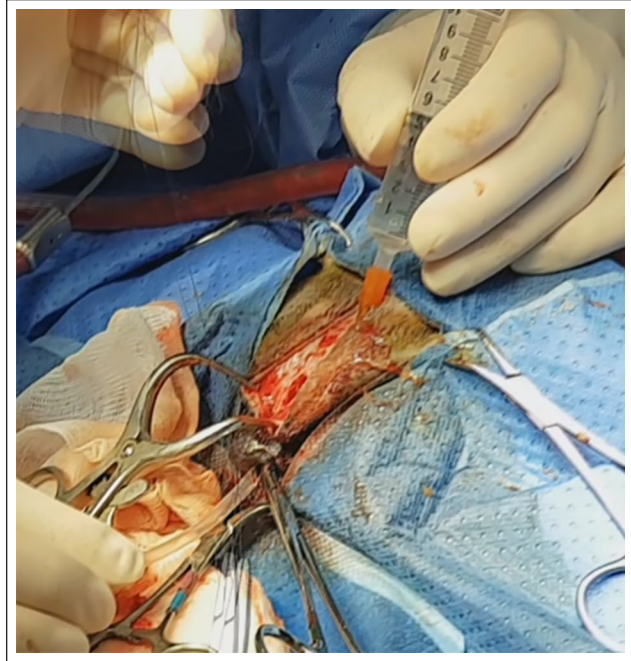


Figure 6 Placement of polyvinylchloride stent using rostrally placed 18g catheter through the nasal sinus trephine and nasal cavity. The stent was attached to the catheter and pulled caudally out through the trephine hole

right and caudal compression remodelling of the left cribriform plate (Figure 3). This was consistent with an expansile left nasal cavity disease process. The soft tissue dorsal to the left globe was thickened and moderately contrast enhanced.

It was not clear from the CT if the changes in the left frontal sinus were confluent or just adjacent to the changes in the left caudal nasal cavity. Chronic rhinitis with secondary obstructive frontal sinusitis or sinus mucocoele with possible expansion into the nasal cavity were considered as possible differential diagnoses. Fungal disease was also possible, although previous testing was negative. Neoplasia such as adenocarcinoma, squamous cell carcinoma and lymphoma was considered less likely given the lack of contrast enhancement within the sinus and nasal cavity. A congenital abnormality, nasopharyngeal polyp or previous trauma to the frontal sinus causing a narrowed sinonasal aperture was also possible but not visible on CT.

Fine-needle aspirates (FNAs) of the left upper eyelid swelling and underlying frontal sinus were obtained through the area of focal osteolucency in the frontal bone seen on CT and submitted for cytology. Fine-needles aspiration yielded purulent material that contained abundant cellular debris, increased numbers of reactive macrophages and neutrophils. No obvious microorganisms were seen. This was consistent with marked active chronic inflammation. A fluid culture was not performed at this time. A flexible 2.3mm video ureteroscope

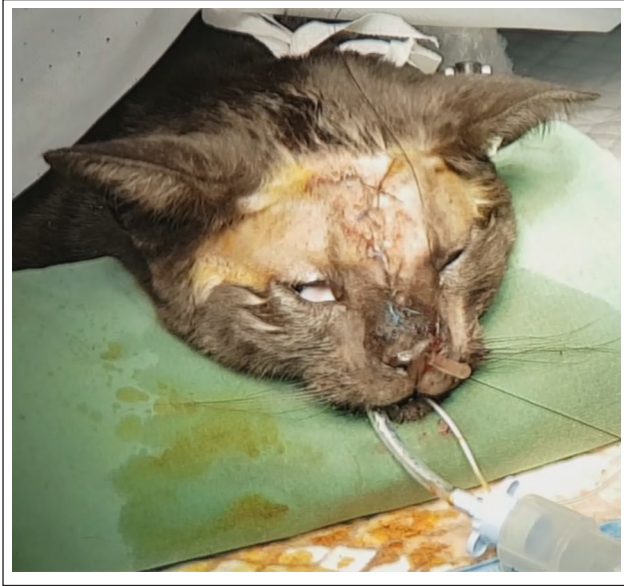

Figure 7 Secured polyvinylchloride stent at completion of surgery prior to cutting off level with nostril

(Olympus) was used to visualise the inside of the left nasal cavity to a depth of approximately 10 mm. The mucosa appeared pink and mildly oedematous with a mild-to-moderate amount of mucus present. No obvious mass lesions or fungal plaques were identified. Eight blind left-sided nasal biopsies ranging in size from $3 \times 2 \times 1$ mm to $4 \times 3 \times 2$ mm were also obtained using 2.3 mm endoscopic biopsy forceps (Ck Surgitech). During biopsy collection it was noted that the left nasal cavity felt bony and thickened. Histopathology was consistent with marked neutrophilic and lymphoplasmacytic ulcerative rhinitis. Gram and periodic acid-Schiff special stains of the biopsies failed to reveal any obvious microorganisms. Surgical curettage of the frontal sinus was recommended and the cat was sent home without antibiotics pending surgery consultation.

The owner brought the cat back for surgery 4 weeks after the CT. The cat was sedated with 0.2 mg/kg methadone IV and anaesthesia induced again with 1 mg/kg alfaxalone IV (Alfaxan; Jurox). The patient was placed in sternal recumbency. A midline skin incision was made 1.5 cm caudal to the medial canthus of the eyes and extended rostrally to 5 mm caudal to the nasal planum. The skin was retracted laterally to the left and the subcutaneous tissue elevated off the frontal bone using a periosteal elevator. A 3 mm neuro burr (Stryker) was used to make a trephine hole in the dorsal left frontal sinus (Figure 4). Thickened yellow-to-green purulent material was removed through the trephine and a sterile sample retained for fungal and bacterial culture (Figure 5). Cytology was not repeated as it had been performed 4 weeks prior. A second hole was made rostrally in the dorsal nasal cavity using the same neuro burr. The frontal sinus and nasal cavity were lavaged with sterile saline until all purulent material was removed. The lining of the frontal sinus was

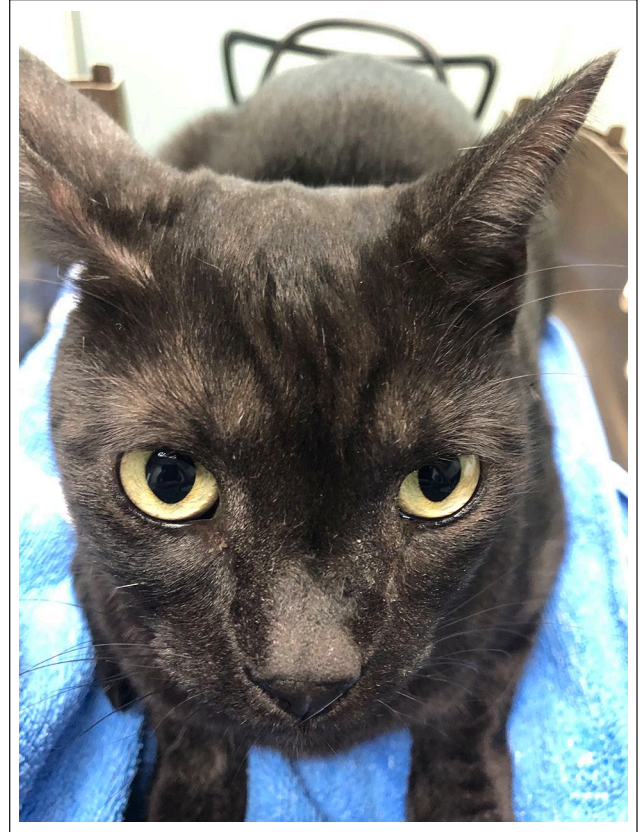

Figure 8 Cat 10 months after surgery with mild epiphora in the left eye

also removed using a 2 mm diameter Volkman curette. An 18G polyurethane catheter (Braun) was passed rostrally through the frontal sinus trephine into the nasal cavity with some resistance noted and out through the left nostril. This was then attached to a sterile piece of 2.6 mm internal diameter latex-free polyvinylchloride (PVC) giving set tubing (Interlink system; Baxter Healthcare) and pulled caudally out through the frontal sinus trephine (Figure 6). The PVC tubing was chosen for its stiffness and large internal diameter, to help reduce the likelihood of collapse and obstruction. Latex-free PVC was also chosen to help reduce mucosal irritation. The sterile tubing was anchored rostrally to the left alar fold using 3-0 Biosyn (Covidien). The caudal end was trimmed to lie flush with the opening of the frontal nasal sinus trephine before being reduced into the frontal sinus. The subcutaneous tissue was closed in two layers using a simple continuous layer of 3-0 Biosyn and the skin closed with 4-0 Daclon (SMI) cruciate sutures. The tubing was then cut to lie flush with the nostril (Figure 7).

The cat recovered uneventfully from anaesthesia. A mild amount of serosanguinous discharge was visible from the stent the day after surgery. The cat was started on meloxicam (Apex) 0.05 mg/kg PO q24h for 7 days and clindamycin (Antirobe; Zoetis) 11 mg/kg PO q12h but was switched to marbofloxacin (Zeniquin; Zoetis) 5 mg/kg PO q24h for 4 weeks when a positive culture for

Pseudomonas aeruginosa with sensitivity to marbofloxacin was obtained from the aspirated frontal sinus fluid obtained at surgery. No fungal hyphae were seen on Gram stain and fungal culture was negative.

A decision was made to leave the stent in for a minimum of 4 weeks to allow for re-epithelialisation around the stent. The left-sided epiphora had resolved when the cat was seen back for suture removal 14 days post-operatively. Minimal discharge was noted for the first 5 weeks. The cat was seen 6 weeks after surgery and 1 week after finishing the marbofloxacin as the owner reported a mucopurulent discharge and increased odour from around the left nostril. The opening of the stent was cleaned with saline and hair placed in front of the nares to assess airflow and stent patency, which was absent. The stent was subsequently removed under a short anaesthetic with methadone sedation and alfaxan induction as described previously. The cat was sent home with another 2 weeks of marbofloxacin. The cat remained free of nasal discharge for 3 months post-stent removal and the owner reported a patent left nostril with an intermittent whistling sound. After that period the left-sided mucopurulent nasal discharge returned.

A recheck 10 months after surgery found that the cat still had an intermittent mucoïd nasal discharge, which was removed every other day by the owner, using an electronic newborn nasal aspirator, and was not on any current medication. The left nostril still appeared patent when hair was placed in front of the nares. A bony crater was palpable above the left eyelid from where the nasal trephine was made and the stent attached proximally. There has been no further enlargement of the left frontal bone swelling; however, mild epiphora in the left eye was present without any chemosis (Figure 8).

A repeat CT was performed 20 months after surgery, which found the presence of a gas-filled frontal sinus and caudal nasal cavity with a visible and patent frontonasal aperture. A partial resolution in the amount of fluid was seen in the mid-to-rostral nasal cavity with persistent loculated mucinous fluid present (Figures 1b, 2b and 3b). Repeat bacterial and fungal culture of the nasal cavity through the rostral trephine hole again cultured *P aeruginosa* susceptible to marbofloxacin and the cat was started back on marbofloxacin 5 mg/kg PO q24h for 4 weeks. At the time of writing 24 months after surgery, there has been a partial resolution of clinical signs with only intermittent sneezing of mucus. The owner also reports that it is less viscous than after stent removal.

Discussion

It is theorised in this case that the cat's unilateral sinonasal obstruction and frontal bony swelling occurred secondary to chronic rhinosinusitis (CRS), a known cause in humans.¹ In this case report, the cat had a long 2-year history of left-sided nasal discharge

from a young age and previous testing for FIV/FeLV and *Cryptococcus* species was negative. Blindly obtained endoscopic nasal biopsies were also consistent with marked neutrophilic and lymphoplasmacytic ulcerative rhinitis. No history of trauma was reported. Underlying viral infection with viruses such as feline herpesvirus 1 has been theorised to contribute to underlying pathogenesis of feline CRS, which is possible in this instance given that the cat was adopted from a rescue organisation at 5 months of age.²

CT revealed expansile left sinonasal disease, which was characterised by hyperostosis of the caudal part of the left frontal bone, with bony thinning and expansion of the left frontal sinus and focal osteolucency. Uniform, non-contrast-enhancing attenuation in the frontal sinus and caudal nasal cavity was also present. These changes were most consistent with chronic rhinitis with secondary obstructive frontal sinusitis or a sinus mucocoele with possible expansion into the nasal cavity. Regardless of diagnosis, the expansile and sinonasal changes appeared most consistent with an underlying obstructive process and were the basis for surgical intervention and temporary stent placement. The negative tests for fungal disease, young age of the cat and lack of contrast enhancement also made neoplasia less likely. The partial resolution of signs within the nasal cavity and gas-filled frontal sinus 20 months after surgery without ongoing medical therapy also make fungal disease and neoplasia unlikely. The authors acknowledge that histopathology of the frontal sinus and affected nasal cavity at the time of surgery would have helped with a definitive diagnosis and possible cause for the unilateral sinonasal obstruction but, unfortunately, was not performed.

The positive culture of *P aeruginosa* from the mucopurulent-looking fluid within the frontal sinus at surgery also supports the working diagnosis of a secondary obstructive sinusitis or possible mucopyocoele formation as a result of CRS, as *P aeruginosa* is known to occur within the nasal cavity of cats.³ However, without histopathology of the frontal sinus and nasal cavity this remains speculative.

Surgery to permit drainage of sinonasal obstructions is the definitive treatment in humans, with endoscopic marsupialisation of the frontal sinus to the nasal cavity considered the treatment of choice.^{4,5} Other techniques such as external trephination or a combined external and endoscopic 'above and below' approach are also advocated by authors, but there is no clear-cut indication as to when each surgical technique should be used.⁴⁻⁸

The use of endoscopically placed stents between the frontonasal sinus and nasal cavity has also been used to treat sinus mucocoeles in humans, as well as for patients with chronic sinusitis. The temporary placement of soft silicone or latex rubber stents are preferred

to firm rubber tubes, which were found to hamper effective epithelialisation and stimulated excessive fibroplasia and granulation.⁹ Given the size of the patient, endoscopic marsupialisation was not feasible. Instead, a temporary latex-free PVC stent from a giving set was placed with the aim of achieving a similar outcome. Other stenting materials such as polyurethane and silicone could also have been considered. The PVC stent was chosen as it had a large internal diameter of 2.6 mm and was less likely to obstruct. Alternative widely available stenting options could include nasoesophageal feeding tubes. For example, to achieve a similar internal diameter a 10 F polyurethane nasoesophageal tube (Kangaroo; Cardinal Health) could have been used. Polyurethane tubes are stronger than the other two materials, which allows them to have thinner walls and a larger internal diameter. They are also softer and better tolerated in the long term than PVC, as well as being stronger.^{10,11} However, in this particular instance the owner reported that the cat tolerated the PVC stent without signs of irritation. More research into the tolerance of cats to different types of nasal stent materials is required.

In the human literature, the time frame for which a nasal stent should be left in place remains controversial, but the majority of studies give a guide of between several days and 8 weeks to allow for re-epithelialisation and remodelling of the nasal sinus.¹² An arbitrary decision of 4 weeks was decided in advance, given the possible irritation expected from the cat. However, the cat tolerated the stent for 2 weeks longer than this. Some studies show that stents can be tolerated in human patients for >6 months.¹² In this case, the stent was left in for 6 weeks and was removed once it became obstructed with mucopurulent material.

The decision to place a temporary stent was made on the assumption that the frontal sinus obstruction was causing frontal bone expansion and that fungal disease and neoplasia were less likely based on lecitin-cholesterol acyltransferase results, CT and previous nasal biopsy results. Cruder methods such as external trephination alone and opening of the nasofrontal aperture with a periosteal elevator through the nasal sinus into the nasal cavity were considered but not performed owing to the perceived risk of re-occlusion of the frontal sinus outflow tract. The lack of progression in bony expansion of the left frontal bone and gas-filled frontal sinus on CT performed 20 months postoperatively indicates that the PVC stent was successful in re-establishing a draining tract through the sinonasal aperture, and can be well tolerated in cats for a period of >4 weeks. Whether the same outcome would have been achieved with cruder methods remains unknown.

The partial resolution in the amount of fluid present within the mid and rostral nasal cavity, combined with a repeat positive culture for *P aeruginosa* with the same susceptibility suggests that there is still ongoing chronic rhinitis without frontal sinusitis, which has been reported to be notoriously difficult to resolve.¹³ However, at the time of writing, the owner was happy with the cat's breathing and general demeanour, and was tolerant of the occasional sneezing of mucoid material and weekly aspiration of nasal material.

Conclusions

To our knowledge, this is first reported use of a temporary PVC stent in a cat to relieve a unilateral frontal sinus obstruction.


Conflict of interest The authors declared no potential conflicts of interest with respect to the research, authorship, and/or publication of this article.

Funding The authors received no financial support for the research, authorship, and/or publication of this article.

Ethical approval This work involved the use of non-experimental animal(s) only (owned or unowned and data from prospective or retrospective studies), and followed established internationally recognised high standards ('best practice') of individual veterinary clinical patient care. Ethical approval from a committee was therefore not necessarily required.

Informed consent Informed consent (either verbal or written) was obtained from the owner or legal custodian of all animal(s) described in this work for the procedure(s) undertaken (either prospective or retrospective studies). For any animals or humans individually identifiable within this publication, informed consent for their use in the publication (verbal or written) was obtained from the people involved.

ORCID iD James D Brown  <https://orcid.org/0000-0002-3517-4081>

Dennis J Woerde  <https://orcid.org/0000-0003-1511-8231>

References

- 1 Lee JT, Brunworth J, Garg R, et al. **Intracranial mucocele formation in the context of longstanding chronic rhinosinusitis: a clinicopathologic series and literature review.** *Allergy Rhinol* 2013; 4: 166–175.
- 2 Michiels L, Day MJ, Snaps F, et al. **A retrospective study of non-specific rhinitis in 22 cats and the value of nasal cytology and histopathology.** *J Feline Med Surg* 2003; 5: 279–285.
- 3 Dorn ES, Tress B, Suchodolski JS, et al. **Bacterial microbiome in the nose of healthy cats and in cats with nasal disease.** *PLoS One* 2017; 12: 1–23. DOI: 10.1371/journal.pone.0180299.

- 4 Trimarchi M, Bertazzoni G and Bussi M. **Endoscopic treatment of frontal sinus mucoceles with lateral extension.** *Indian J Otolaryngol Head Neck Surg* 2013; 65: 151–156.
- 5 Bockmuhl U, Kratzsch B, Benda K, et al. **Surgery for paranasal sinus mucoceles: efficacy of endonasal microendoscopic management and long term results of 185 patients.** *Rhinology* 2006; 44: 62–67
- 6 Serrano E, Klossek JM, Percodani J, et al. **Surgical management of paranasal sinus mucoceles: a long term study of 60 cases.** *Otolaryngol Head Neck Surg* 2004; 131: 133–140.
- 7 Har-El G. **Endoscopic management of 108 sinus mucoceles.** *Laryngoscope* 2001; 111: 2131–2134.
- 8 Martel-Martin M, Gras-Cabrerizo JR, Bothe-Gonzalez C, et al. **Clinical analysis and surgical results of 58 paranasal sinus mucoceles** [article in Spanish]. *Acta Otorrinolaringol* 2015; 66: 92–97.
- 9 Neel HB III, Whitaker JH and Lake CF. **Thin rubber sheeting in frontal sinus surgery: animal and clinical studies.** *Laryngoscope* 1976; 86: 524–536.
- 10 Wallace T and Steward D. **Gastric tube use and care in the NICU.** *Newborn Infant Nurs Rev* 2014; 14: 103–108.
- 11 Sparkes A. **Feeding tubes.** In: Langley-Hobbs SJ, Demetriou J and Ladlow JF (eds). *Feline soft tissue and general surgery*. Edinburgh: Saunders/Elsevier, 2014, pp 125–131.
- 12 Malin BT and Sherris DA. **Frontal sinus stenting techniques.** *Oper Tech Otolaryngol Head Neck Surg* 2010; 21: 175–180.
- 13 Reed N. **Chronic rhinitis in the cat.** *Vet Clin Small Anim* 2014; 44: 33–50.