

# BMJ Open Quality Towards cost saving in surgery without compromising safety: stapleless laparoscopic splenectomy in a developing country – a prospective cohort study

Omar Lasheen , Mohamed Yehia, Ayman Salah, Sameh Mikhail, Ahmed Hassan

**To cite:** Lasheen O, Yehia M, Salah A, *et al.* Towards cost saving in surgery without compromising safety: stapleless laparoscopic splenectomy in a developing country—a prospective cohort study. *BMJ Open Quality* 2023;**12**:e002068. doi:10.1136/bmjog-2022-002068

OL and MY are joint first authors.

Received 26 July 2022  
Accepted 6 January 2023

## ABSTRACT

**Background** Minimally invasive surgery has been steadily growing in popularity. Control of splenic hilar vessels is the most delicate step during laparoscopic splenectomy (LS). In the earlier eras of LS, hilar vessels were controlled using clips and/or ligation. Laparoscopic staples were later introduced and have arguably led to an increase in popularity of LS. They do not abolish potential complications of splenectomy and theoretically represent an added operative cost.

In this study, we aimed to assess the safety and efficacy of stapleless LS (using knots, haemostatic devices and clips) compared with the now more conventional stapled LS.

**Methods** A pilot randomised prospective study was conducted in a university hospital between September 2018 and April 2020. It included 40 patients randomly assigned to two equal groups: (1) 20 patients: stapleless LS and (2) 20 patients: LS using laparoscopic staples. We compared operative time, intra and postoperative complications and postoperative recovery.

**Results** There was no statistically significant difference between both groups across all comparative outcomes.

**Conclusion** Both techniques are comparable in terms of safety and operative time. In terms of cost efficiency, we recommend more comprehensive analyses of hospital costs.

## INTRODUCTION

Laparoscopic splenectomy (LS) is considered the gold standard for elective spleen removal.<sup>1</sup> It has better outcomes compared with open splenectomy, with less frequent intraoperative and postoperative complications and negligible mortality.<sup>2 3</sup> However, technical difficulties may be encountered during LS due to the fragile nature of the spleen and its complex vasculature.<sup>4</sup>

Bleeding is the most frequent intraoperative complication and the most typical indication for open conversion.<sup>4</sup> It can occur due to inadequate control of the splenic vessels.<sup>5</sup> Many techniques are suggested to secure splenic hilum vessels. The use of laparoscopic staples is currently the standard technique.<sup>6</sup>

### WHAT IS ALREADY KNOWN ON THIS TOPIC

⇒ Laparoscopic splenectomy is more conventionally done using staplers.

### WHAT THIS STUDY ADDS

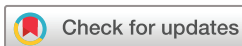⇒ We aimed to establish that the surgery can be just as efficient and safe without using staplers when compared with the more conventional stapled method.

### HOW THIS STUDY MIGHT AFFECT RESEARCH, PRACTICE OR POLICY

⇒ The use of costly disposables can be reduced, which is beneficial to healthcare institutes in both developing and developed countries.

Nevertheless, laparoscopic staples usage might be associated with complications, including pancreatic injury, splenic or portal vein thrombosis and bleeding.<sup>5 7 8</sup> The conventional approach to splenic hilum management is clip and ligation. This technique requires meticulous vessel dissection and may lead to excess bleeding.<sup>5</sup> Electrothermal bipolar vessel sealer devices or ultrasonic coagulating shears have also been used for dissection of hilar vessels as well as smaller vessels sealing.<sup>9 10</sup> Advanced bipolar devices can be safely used for hilar vessels with a diameter of up to 7 mm.<sup>11 12</sup>

This study aimed to assess the safety and efficacy of stapleless LS compared with the standard stapled LS using laparoscopic staples. Considering the added costs of using staplers and reloads, we aimed to possibly highlight the potential added benefit of reduced surgical costs by performing stapleless splenectomy should the results conclude that both techniques are at least equally safe.



© Author(s) (or their employer(s)) 2023. Re-use permitted under CC BY-NC. No commercial re-use. See rights and permissions. Published by BMJ.

General Surgery, Cairo University Kasr Alainy Faculty of Medicine, Cairo, Egypt

### Correspondence to

Dr Omar Lasheen;  
of.lasheen@gmail.com

## PATIENTS AND METHODS

This study was conducted from September 2018 till April 2020. It was initiated after approval of the ethical and research committee of the General Surgery department. It included 43 patients with various indications for splenectomy referred from the haematology department. One patient declined to participate, and two did not receive allocated intervention (converted to open before dealing with splenic hilum due to equipment failure\_ insufflator). The remaining 40 patients were randomly divided into two equal groups using sealed envelopes. Concealed allocation was accomplished using a computer-generated table of random numbers created by a medical student not involved in recruiting patients. Individual, sequentially numbered cards with the random assignment folded and placed in sealed opaque envelopes. The surgeon opened the envelope and proceeded with the technique according to the group assignment.

In the stapleless group (n=20), the splenic hilum was secured using intracorporeal knots or stainless steel clips. In the stapler group (n=20), splenic hilum was controlled using laparoscopic staples.

The main inclusion criterion was adults with normal-sized spleens or mild to moderate splenomegaly (<20 cm) evidenced by preoperative abdominal imaging. Patients with massive splenomegaly, portal hypertension or low platelet count on the day of the procedure (< 20 000/cc) were excluded.

### Patient and public involvement

There was no active patient involvement in the study design or recruitment.

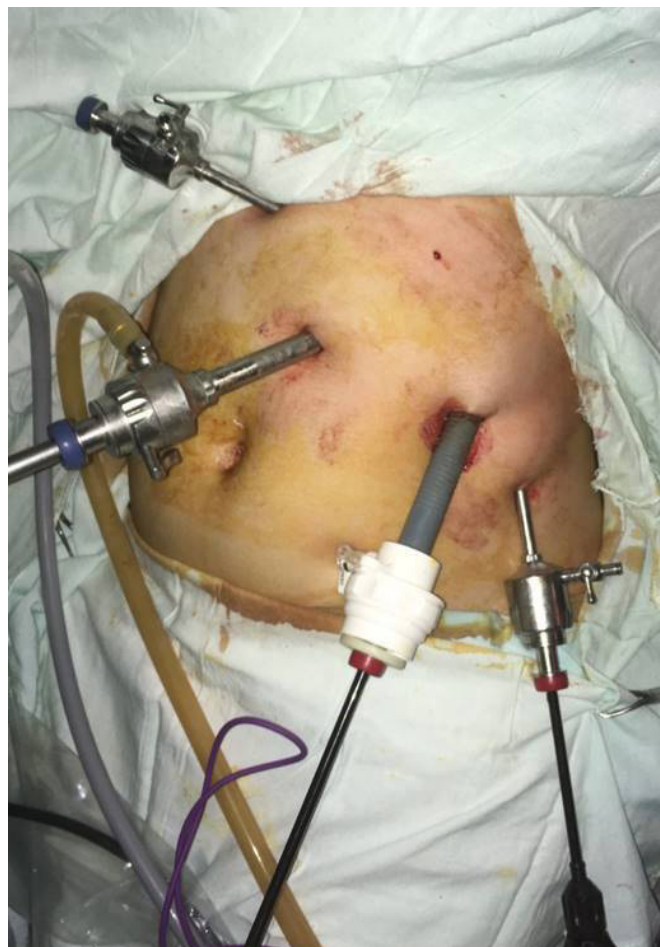### Preoperative preparation

All patients were counselled by the surgical team. The procedure, along with all possible complications, was explained. Patients received vaccination against capsulated organisms (polyvalent Pneumococcal, Meningococcal and Haemophilus Influenza) 2 to 3 weeks before surgery.

### Technique of LS

Procedures were performed by three consultants familiar with laparoscopic splenectomy.

After prophylactic antibiotics and under general anaesthesia, elastic compression stockings were placed on both legs. The patient was placed in the right lateral decubitus. The left arm was suspended from attached table support or supported across the patient's chest with a pillow. A soft roll was placed under the right axilla in a transverse direction. The lower extremities were partially flexed with a pillow between the knees. The mid-portion of the operating table was flexed, and the 'kidney rest' was elevated to maximise the distance between the left costal margin and the left iliac crest. Pneumoperitoneum was achieved by closed technique using a Veress needle, inserted at the left costal margin in the mid-clavicular line (Palmer's point). Four ports were inserted. A 10–12 mm trocar was

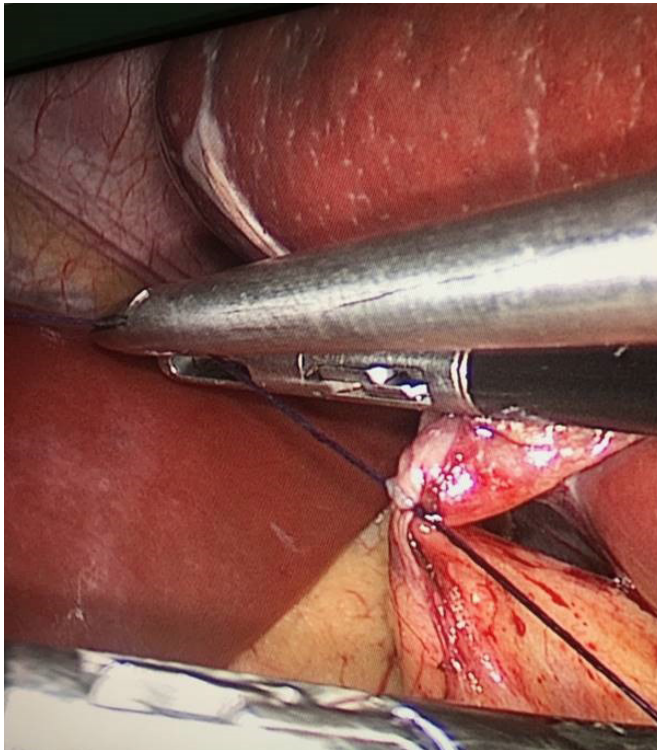


**Figure 1** Patient positioning and port placement.

placed in the left hypochondrium 2–3 cm from the costal margin and that would be the optic port for a 30° scope (figure 1). The remaining ports were placed under direct vision along the left costal margin in the epigastric subxiphoid (5 mm), mid-clavicular line (10–12 mm) and left flank at the anterior axillary line (5 mm). Dissecting instruments were used through the epigastric and the mid-clavicular port by the operating surgeon. The left flank port was used by a second assistant. Because of the gravity advantage in this position, there was no need for grasping instruments to retract or manipulate the stomach or other adjacent structures to visualise the hilum.

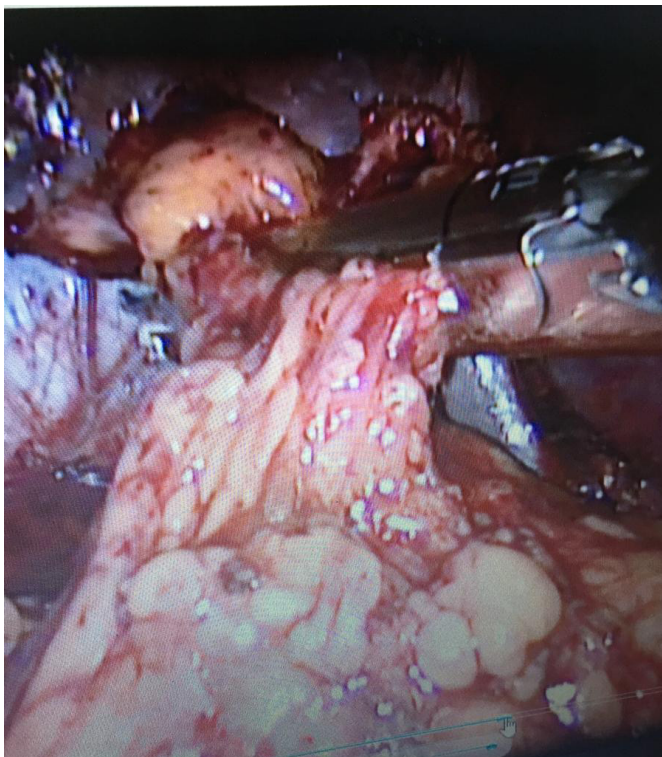
Dissection commenced inferiorly, carefully dividing any adhesions between the splenic flexure of the colon and the tail of the spleen. Further progress was cephalad with the division of the peritoneum overlying the splenic hilum anteriorly and the peritoneum of the lienorenal ligament posteriorly. Branches of the splenic vessels to the inferior pole of the spleen are encountered first and are either divided between clips or are controlled using advanced bipolar devices. The latter device was used in both groups.

Major vessels were exposed. In the stapleless group, each vessel or branch at the hilum of the spleen was dissected, then either clipped or ligated using intracorporeal Vicryl 2:0 knots. The choice was usually based

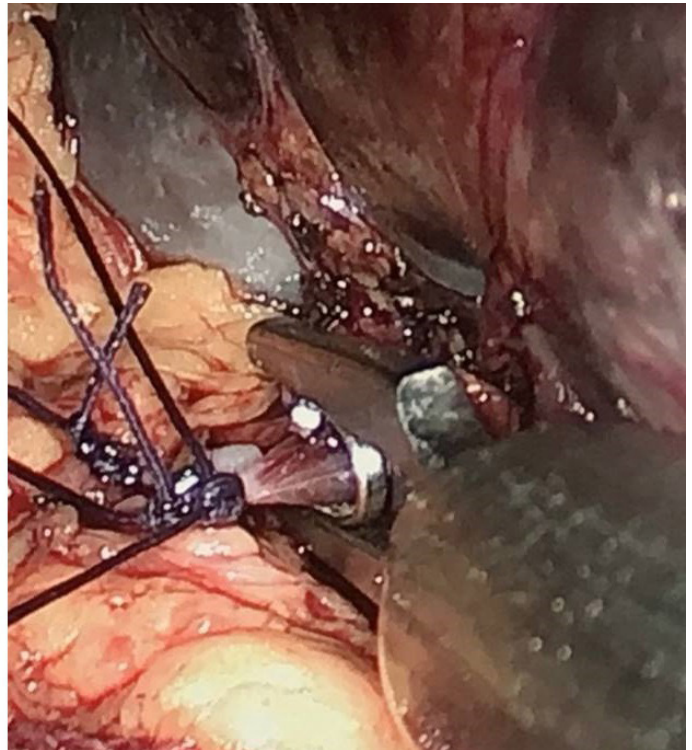


**Figure 2** Use of clips and suture ligation.

on the ease of access and the size of the vessel. In the Stapler Group, space was dissected behind the hilum to enable the passage of a 30 mm endoscopic linear cutting vascular stapler (white reload). The vessels were secured and divided by one or two applications of this device (figures 2 and 3).



**Figure 3** Use of laparoscopic staples.



Dissection progressed above the pedicle by rotating the inferior pole of the spleen towards the anterior abdominal wall to maintain slight tension on the remaining vascular attachments. The short gastric vessels were dealt with by individual ligation, clips or an advanced bipolar device. In the stapler group, further application of the 30 mm stapler was considered. As the lienorenal ligament and other attachments of the spleen were divided progressively in a cephalad direction at the same time as the vessels anteriorly, division of the last vessel completed the dissection of the spleen. The omentum was explored to exclude the presence of any splenules. None was discovered during any of the operations. A tube drain was routinely placed in the operative bed. The spleen was delivered through the abdominal wall via an 8–10 cm suprapubic transverse incision (Pfannenstiel).

### Postoperative care

Patients were sent back to the surgical wards. Regular 6–8 hourly observations were recorded. Patients were allowed to sit on a chair out of bed 2–4 hours after surgery. Mobilisation was encouraged, along with the use of a spirometer and chest physiotherapy. Nasogastric tubes (NGT) were removed at the end of the procedure. Urinary catheters were removed on day 1.

A numeric pain scale (range 1–10) was used to evaluate patients' pain. According to the WHO analgesic ladder, postoperative pain control was triaged according to the patient's requirements, using paracetamol, non-steroidal anti-inflammatory drugs and opioids if necessary. On the first postoperative day (D1), a complete blood count was performed along with drain fluid amylase. Aspirin

was given to patients whose postoperative platelet count exceeded  $10^6/\text{ul}$ . Drain was removed before discharge if drain fluid amylase was less than 600 U/L on day 1 postoperative.

Patients were discharged on the second postoperative day in the absence of any complications, if their pain was controlled and their diet established. Patients were followed up in the outpatient clinic after 2 weeks. During this visit, they were assessed clinically and their wounds were reviewed. Further follow-up with the haematology team was scheduled for some patients depending on their original condition.

### Statistical methods

Statistical analysis was done using IBM SPSS Statistics V.22 (IBM, Armonk, New York). Numerical data were expressed as mean and SD or median and range as appropriate. Qualitative data were expressed as frequency and percentage.  $\chi^2$  test (Fisher's exact test) was used to examine the relation between qualitative variables. For quantitative data, comparison between two groups was made using independent sample t test or Mann-Whitney test. A p value  $<0.05$  was considered significant.

### RESULTS

Out of the 40 patients, 37 were women while only three were men (one in the first group and two in the second group). Ages ranged from 15 and 62 years, with no significant difference between both groups. The most common indication for splenectomy was idiopathic thrombocytopenic purpura. Most patients were fit with no pre-existing medical disorders (table 1).

Table 2 shows that the two groups were comparable regarding the size of the spleen (estimated by preoperative imaging). There was no significant difference between the two groups in operating time ( $p=0.512$ ) and the total amount of blood loss during surgery ( $p=0.253$ ).

Vascular control was secured in the stapleless group with five to seven clips only in six patients (30%). In the remaining 14 patients, clips and ligatures were used to secure the hilar vessels. None of the patients in either groups developed significant intraoperative or postoperative bleeding. Out of all patients, only one from the laparoscopic staples group developed acute gastric dilatation and had an NGT reinserted. All patients had normal drain amylase. There was no significant difference in the postoperative pain scores between both groups. Duration of postoperative hospital stay was comparable in the two groups (table 3).

### DISCUSSION

Since its introduction in 1991,<sup>13</sup> LS gained popularity as a safe elective procedure. However, it is not without complications. Bleeding is the most critical intraoperative complication. A major source of bleeding is injury of the hilar vessels during dissection and ligation.<sup>2</sup> Many techniques were suggested for managing the splenic hilum

**Table 1** Baseline characteristics of the two groups

	Stapleless group (n=20)	Stapler group (n=20)	P value
Age (years)	26.4±7.4	28.4±10.3	0.698
Diagnosis			0.248
ITP	10 (50.0%)	14 (70.0%)	
Autoimmune haemolytic anaemia	9 (45.0%)	5 (25.0%)	
Lymphoma	0 (0.0%)	1 (5.0%)	
Thalassaemia major	1 (5.0%)	0 (0.0%)	
Co-morbidities			*
Type 1 diabetes mellitus	0 (0.0%)	1 (5.0%)	
Systemic lupus erythematosus	1 (5.0%)	2 (10.0%)	
PCO+habitual abortions	2 (10.0%)	1 (5.0%)	
PCO	2 (10.0%)	1 (5.0%)	
Previous abdominal surgeries			1.000
Open appendectomy	1 (5.0%)	0 (0.0%)	
Caesarean section	5 (25.0%)	6 (30.0%)	

Data are presented as mean±SD or number (%).  
\*No p-value due to the small number in all subgroups.  
ITP, idiopathic thrombocytopenic purpura; PCO, polycystic ovaries.

vessels, including clip placement,<sup>14</sup> ligation,<sup>15</sup> the use of energy devices<sup>7</sup> and stapling devices.<sup>16</sup> Clipping and ligation was the primary technique used in the early era of LS. This was substituted with surgical staplers applied for *en bloc* transection of the splenic hilum. A recent study retrospectively compared these two techniques revealing their comparable safety and feasibility.<sup>17</sup> To the best of our knowledge, our study is the first prospective study comparing the results of these two approaches. It demonstrated that clip-ligation and stapling of the splenic hilum during LS were comparable in operative duration

**Table 2** Size of spleen, operative time, intraoperative blood loss, postoperative pain score and duration of hospital stay in the two groups

	Stapleless group (n=20)	Stapler group (n=20)	P value
Spleen size (cm)	13.2±3.6	13.4±4.1	0.947
Operative time (min)	135.3±30.7	127.0±27.0	0.512
Intraoperative blood loss (mL)	141.5±44.6	131.5±58.0	0.253
Pain score on day 1	5 (4-6)	5 (4-6)	0.758
Postop stay (days)	3 (2-6)	3 (2-5)	0.529

Data are presented as mean±SD or number (%).

**Table 3** Postoperative pain score and duration of hospital stay in the two groups

	Stapler group (n=20)	Staple-less group (n=20)	P value
Pain score on day 1	5 (4-6)	5 (4-6)	0.758
Postop stay (days)	3 (2-6)	3 (2-5)	0.529

( $p=0.512$ ) and intraoperative blood loss ( $p=0.253$ ). Both techniques were safe, showing no intraoperative or postoperative complications.

LS is currently considered the standard approach for spleen removal in many institutions. This is probably encouraged by the several advantages of LS over open splenectomy, including less postoperative pain and blood loss, shorter operative time and shorter hospital stay, faster recovery and reduced complication rate.<sup>18–21</sup> However, many technical aspects are still controversial; one being splenic hilum manipulation. This step may lead to intraoperative or postoperative bleeding if not properly managed.

The conventional method of controlling the splenic hilar vessels is clipping and/or ligation. In this technique, the main trunks of the splenic artery and vein were identified at the level of the pancreatic tail. Then, the vessels were isolated, clipped or ligated, then transected. The entire hilum with branches of all vessels and perivascular fat was then dissected from the pancreatic tail. This approach is cost-effective as it does not require the relatively expensive vascular stapler.<sup>22</sup> Additionally, ligating the splenic arterial trunk results in spleen ischaemia. Consequently, the spleen shrinks and becomes tough, enlarging the operative field and enhancing the operation safety.<sup>23</sup> Risk of bleeding may be higher in clip ligation as it needs dissection of the splenic hilum. Splenic hilar dissection demands good laparoscopic experience to minimise complications. Meticulous and gentle manipulation during vascular dissection is needed to ensure safety.

With advancement in the laparoscopic field, other approaches have been accepted for transection of the splenic pedicle. Evaluation of safety and the efficacy of these techniques are debatable owing to the lack of randomised studies for comparison. The present study demonstrated similar safety and effectiveness of the conventional clipping-ligation and stapler application. A few studies are available in the literature comparing clip ligation with other modalities. A retrospective study including 60 patients compared laparoscopic staples with clip ligation. The authors found clip ligation to be associated with less intraoperative blood loss, shorter length of hospital stay and lower cost.<sup>23</sup> These results do not concur with the current study, while the more recent study by Türkoğlu *et al*<sup>17</sup> reported similar findings to the present study. A randomised prospective study compared the use of an advanced bipolar device and clip ligation during LS. Clip ligation was associated with longer operating time and more bleeding volume. However, there was no need for transfusion or surgical conversion.<sup>24</sup>

On the other hand, using stapling devices has been described by several authors. This technique has been related to postoperative complications and bleeding. In a large multicentre study, the stapling device was used in 676 LS procedures. Surgical conversion was required in 5.8% of cases because of hilar bleeding. Splenic/portal vein thrombosis occurred in 14 patients and pancreatitis in 5. No complications were recorded in 82.8% of cases.<sup>16</sup> Wang *et al*<sup>25</sup> retrospectively analysed 206 LS. Conversion because of haemorrhage was necessary in 2.4% of cases. 12.6% had complications. In another series of 300 patients, reoperation is required in only 1% of the patients due to bleeding, subphrenic abscess and intestinal ischaemia.<sup>26</sup> Stapling devices were also safe and effective in another series of 107 patients. Intraoperative and postoperative bleeding was encountered in 4.7% of cases.<sup>27</sup> Another complication of stapler use is retention of the tail of the pancreas between its jaws leading to pancreatitis or pancreatic fistula.<sup>7</sup>

Efforts are continuously made to reach the best way of controlling the splenic hilum during LS. Recently, He *et al*<sup>28</sup> introduced a method of splenic hilum manipulation through active exposure of the pancreatic tail. Sakamoto *et al* suggested another approach through mobilising the pancreatic tail first, followed by dissecting the splenic vessels at the hilum before mobilising the spleen.<sup>29</sup>

Several studies demonstrated equal costs or even reduced cost of LS compared with open splenectomy.<sup>30</sup> Having no significant difference in hospital stay, operative time and blood loss, it might be prudent to say that using less consumables, that is, staplers is probably cost-effective. There are constant pressures on healthcare services to try to reduce expenses whenever possible. This is a problem that affects any healthcare facility. In a public government funded hospital in a developing country, allocation of financial resources can be a useful strategy to face these pressures, as long as patient safety and quality of service provided is not compromised.<sup>31</sup>

Authors are aware of the limitations of this study. The small sample size making this study rather a pilot study. Splenectomy, in the patients included in this study, was usually a straightforward procedure. Therefore, care should be taken when dealing with more challenging patients. Absence of cost analysis difference between both groups is another limitation of this study.

Given the above-mentioned limitations, One should be cautious in drawing conclusions. We concluded that clipping and/or ligation of the splenic hilar vessels is a safe and effective approach to control splenic hilum during elective LS. It can be safely implemented for mild to moderately enlarged spleens. It was comparable to

staplers regarding complications and operative duration. An expected lower surgical cost is another advantage of the clip-ligation method. Being well acquainted with the anatomy of splenic blood vessels and being competent with the surgical techniques of clipping and ligation followed by transection of the pedicle during LS are essential for the safe completion of this technique. Therefore, in the presence of good surgical expertise, albeit in absence of advanced and costly equipment, the proposed stapleless approach may be an appropriate alternative in practicing LS.

**Contributors** OL (drafting of manuscript, acquisition of data)—MY (study conception and design, acquisition of data, critical revision of manuscript)—AS (critical revision of manuscript)—SM (study conception and design, acquisition of data, critical revision of manuscript)—AH (study conception and design, acquisition of data, critical revision of manuscript). OL as primary author, corresponding author and guarantor.

**Funding** The authors have not declared a specific grant for this research from any funding agency in the public, commercial or not-for-profit sectors.

**Competing interests** None declared.

**Patient and public involvement** Patients and/or the public were not involved in the design, or conduct, or reporting, or dissemination plans of this research.

**Patient consent for publication** Not applicable.

**Ethics approval** All procedures performed in studies were in accordance with the ethical standards of the institutional research committee and with the 1964 Helsinki declaration and later amendments or comparable ethical standards.

**Provenance and peer review** Not commissioned; externally peer reviewed.

**Data availability statement** All data relevant to the study are included in the article or uploaded as supplementary information.

**Open access** This is an open access article distributed in accordance with the Creative Commons Attribution Non Commercial (CC BY-NC 4.0) license, which permits others to distribute, remix, adapt, build upon this work non-commercially, and license their derivative works on different terms, provided the original work is properly cited, appropriate credit is given, any changes made indicated, and the use is non-commercial. See: <http://creativecommons.org/licenses/by-nc/4.0/>.

#### ORCID iD

Omar Lasheen <http://orcid.org/0000-0002-7918-947X>

## REFERENCES

- Somasundaram SK, Massey L, Gooch D, *et al*. Laparoscopic splenectomy is emerging “gold standard” treatment even for massive spleens. *Ann R Coll Surg Engl* 2015;97:345–8.
- Misiakos EP, Bagias G, Liakakos T, *et al*. Laparoscopic splenectomy: current concepts. *World J Gastrointest Endosc* 2017;9:428–37.
- Bai Y-N, Jiang H, Prasoon P. A meta-analysis of perioperative outcomes of laparoscopic splenectomy for hematological disorders. *World J Surg* 2012;36:2349–58.
- Bhandarkar DS, Katara AN, Mittal G, *et al*. Prevention and management of complications of laparoscopic splenectomy. *Indian J Surg* 2011;73:324–30.
- Gelmini R, Romano F, Quaranta N, *et al*. Sutureless and stapleless laparoscopic splenectomy using radiofrequency: Ligasure device. *Surg Endosc* 2006;20:991–4.
- Feldman LS. Laparoscopic splenectomy: standardized approach. *World J Surg* 2011;35:1487–95.
- Misawa T, Yoshida K, Iida T, *et al*. Minimizing intraoperative bleeding using a vessel-sealing system and splenic hilum hanging maneuver in laparoscopic splenectomy. *J Hepatobiliary Pancreat Surg* 2009;16:786–91.
- Romano F, Gelmini R, Caprotti R, *et al*. Laparoscopic splenectomy: Ligasure versus endogia: a comparative study. *J Laparoendosc Adv Surg Tech A* 2007;17:763–7.
- Yüney E, Höbek A, Keskin M, *et al*. Laparoscopic splenectomy and Ligasure. *Surg Laparosc Endosc Percutan Tech* 2005;15:212–5.
- Schaarschmidt K, Kolberg-Schwerdt A, Lempe M, *et al*. Ultrasonic shear coagulation of main hilar vessels: a 4-year experience of 23 pediatric laparoscopic splenectomies without staples. *J Pediatr Surg* 2002;37:614–6.
- Romano F, Caprotti R, Franciosi C, *et al*. Laparoscopic splenectomy using Ligasure. *Surg Endosc* 2002;16:1608–11.
- Romano F, Caprotti R, Franciosi C, *et al*. The use of Ligasure during pediatric laparoscopic splenectomy: a preliminary report. *Pediatr Surg Int* 2003;19:721–4.
- Delaitre B, Maignien B, Icard P. Laparoscopic splenectomy. *Br J Surg* 1992;79:1334.
- Rabea M, Fathi M, Al-Sayed A. Outcomes of laparoscopic splenectomy in benign hematologic and splenic diseases in children. *Egypt J Surg* 2016;35:231.
- Palanivelu C, Jani K, Malladi V, *et al*. Early ligation of the splenic artery in the leaning spleen approach to laparoscopic splenectomy. *J Laparoendosc Adv Surg Tech A* 2006;16:339–44.
- Casaccia M, Torelli P, Pasa A, *et al*. Putative predictive parameters for the outcome of laparoscopic splenectomy: a multicenter analysis performed on the Italian registry of laparoscopic surgery of the spleen. *Ann Surg* 2010;251:287–91.
- Türkoğlu A, Oğuz A, Yaman G, *et al*. Laparoscopic splenectomy: clip ligation or en-bloc stapling? *Turk J Surg* 2019;35:273–7.
- Bulus H, Mahmoud H, Altun H, *et al*. Outcomes of laparoscopic versus open splenectomy. *J Korean Surg Soc* 2013;84:38–42.
- Casaccia M, Sormani MP, Palombo D, *et al*. Laparoscopic splenectomy versus open splenectomy in massive and giant spleens: should we update the 2008 EAES guidelines? *Surg Laparosc Endosc Percutan Tech* 2019;29:178–81.
- Feng S, Qiu Y, Li X, *et al*. Laparoscopic versus open splenectomy in children: a systematic review and meta-analysis. *Pediatr Surg Int* 2016;32:253–9.
- Tada K, Ohta M, Saga K, *et al*. Long-term outcomes of laparoscopic versus open splenectomy for immune thrombocytopenia. *Surg Today* 2018;48:180–5.
- Radkowiak D, Zychowicz A, Wysocki M, *et al*. Quest for the optimal technique of laparoscopic splenectomy—vessels first or hilar transection? *Wideochir Inne Tech Maloinwazyjne* 2018;13:460–8.
- Fan Y, Liu Y-Y, Wang P, *et al*. Study on the efficacies of splenic pedicle transection by using manual manipulation and endo-GIA procedure for laparoscopic splenectomy. *Int J Clin Exp Med* 2015;8:19430–5.
- Shabahang H, Maddah G, Tavassoli A, *et al*. Laparoscopic splenectomy: Ligasure or clip ligation? *Surg Laparosc Endosc Percutan Tech* 2012;22:136–8.
- Wang Y, Zhan X, Zhu Y, *et al*. Laparoscopic splenectomy in portal hypertension: a single-surgeon 13-year experience. *Surg Endosc* 2010;24:1164–9.
- Corcione F, Pirozzi F, Aragiusto G, *et al*. Laparoscopic splenectomy: experience of a single center in a series of 300 cases. *Surg Endosc* 2012;26:2870–6.
- Vecchio R, Marchese S, Swehli E, *et al*. Splenic hilum management during laparoscopic splenectomy. *J Laparoendosc Adv Surg Tech A* 2011;21:717–20.
- He Q-J, Dai X-M, Yu C, *et al*. Laparoscopic splenectomy: a new approach. *Clinics (Sao Paulo)* 2018;73:e16–536.
- Sakamoto K, Honda G, Kurata M, *et al*. Safe approach to the splenic hilum by first mobilizing the pancreatic tail in laparoscopic splenectomy. *Asian J Endosc Surg* 2017;10:83–6.
- Park A, Targarona EM, Trias M. Laparoscopic surgery of the spleen: state of the art. *Langenbecks Arch Surg* 2001;386:230–9.
- Kaplan RS, Porter ME. How to solve the cost crisis in health care. *Harv Bus Rev* 2011;89:46–52.