



Case report

Benefit of a second opinion: From metastatic disease to resectable lung cancer with sarcoid-like reaction



Romane M. Schook^{a,*}, Lyan Koudstaal^b, Emile F. Comans^c, Pieter E. Postmus^a, Katrien Grünberg^b, Marinus A. Paul^d, Egbert F. Smit^a, Thomas G. Sutedja^a

^a Department of Pulmonary Diseases, VU University Medical Center Amsterdam, The Netherlands

^b Department of Pathology, VU University Medical Center Amsterdam, The Netherlands

^c Department of Radiology and Nuclear Medicine, VU University Medical Center Amsterdam, The Netherlands

^d Department of Cardiothoracic Surgery, VU University Medical Center Amsterdam, The Netherlands

A B S T R A C T

Keywords:

Non-small cell lung cancer
Second opinion
Mediastinal enlargement
Sarcoid-like reaction

Background: Mediastinal lymphadenopathy in combination with lung cancer is suggestive for lymph node metastases but can also have other origins.

Case report: We describe a patient diagnosed with stage IV lung cancer presenting with parenchymal lesions and enlarged mediastinal lymph nodes. A second opinion including FDG-PET scan review and a mediastinoscopy followed by surgery revealed tumor specimens originating from a single primary tumor with a sarcoid-like reaction in the mediastinal lymph nodes, changing the diagnosis from metastasized to resectable lung cancer.

Discussion: PET positive lesions are not always synonymous with metastatic disease in the presence of a malignant tumor. Conscientious review of FDG-PET scans and tissue sampling are therefore mandatory to determine definitive staging and subsequent interventions.

© 2014 The Authors. Published by Elsevier Ltd. This is an open access article under the CC BY-NC-ND license (<http://creativecommons.org/licenses/by-nc-nd/3.0/>).

Introduction

Mediastinal lymphadenopathy in combination with lung cancer is suggestive for lymph node metastases. However, lymphadenopathy may have an other cause which may result in a totally different diagnostic, therapeutic approach and prognosis.

Case report

A 75-year old male with COPD (Gold II) and a smoking history of 50 packyears underwent a CT-scan for an abdominal aortic aneurysm. Three parenchymal lesions were seen (LUL, LLL, RUL), as well as enlarged mediastinal lymph nodes. Subsequently, 18-FDG-PET images showed uptake in both lesions in the left hemi-thorax and intense multilevel bilateral mediastinal FDG uptake in lymph nodes. The 5 mm Ø lesion in the RUL showed no FDG avidity. Transthoracic needle biopsy of the Ø 3 cm lesion in the LUL revealed a squamous cell carcinoma. During the multidisciplinary discussion

at the referring hospital, it was concluded that patient most probably had stage IV lung cancer with intrapulmonary and mediastinal metastases. The patient requested a second opinion.

At our expert center, histology and imaging were reviewed. The PET uptake of the mediastinum was quite characteristic for a sarcoid-like reaction (see Fig. 1) [1,2]. Based on images of the two parenchymal lesions in the left lung, synchronous primaries were considered. Mediastinoscopy was performed to exclude metastatic disease and histology confirmed a noncaseating granulomatous inflammation of the mediastinal lymph nodes without metastases (Fig. 2). Taking the patient's limited cardiac function and pulmonary reserve capacity into account, two wedge excisions of the lesions of the left lung and lymph node dissection were performed. The two resected tumor specimens were found to be originating from a single primary tumor, based upon morphology and immunohistochemistry: a 3 cm Ø undifferentiated large cell carcinoma of the LUL (R0) and a 0.6 cm Ø undifferentiated large cell carcinoma of the LLL (R1). The final pathological staging was therefore pT4N0M0R1. The patient was followed at regular intervals. Repeated CT-scans did not show any sign of recurrence, while the enlarged lymph nodes did not change over time. Ultimately, almost 3 years after the initial second opinion the patient developed brain metastases and died.

* Corresponding author. Department of Pulmonary Diseases, VU University Medical Center, De Boelelaan 1117, 1007 MB Amsterdam, The Netherlands. Tel.: +31 20 4442193; fax: +31 20 4444328.

E-mail address: r.schook@vumc.nl (R.M. Schook).

Abbreviations

COPD	chronic obstructive pulmonary disease
CT	computed tomography
18-FDG-PET	18-fluoro-deoxyglucose positron emission tomography
LUL	left upper lobe
LLL	left lower lobe
RUL	right upper lobe.

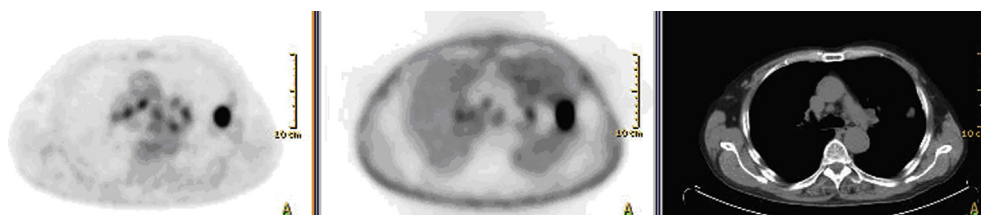


Fig. 1. PET and CT scan. PET (alternation corrected and non-alternation corrected) and low dose CT images showing a pattern of bilateral hilar and mediastinal uptake in the lymph nodes, characteristic of sarcoid-like reaction, close to a parenchymal abnormality highly suspicious for a lung cancer in the left upper lobe.

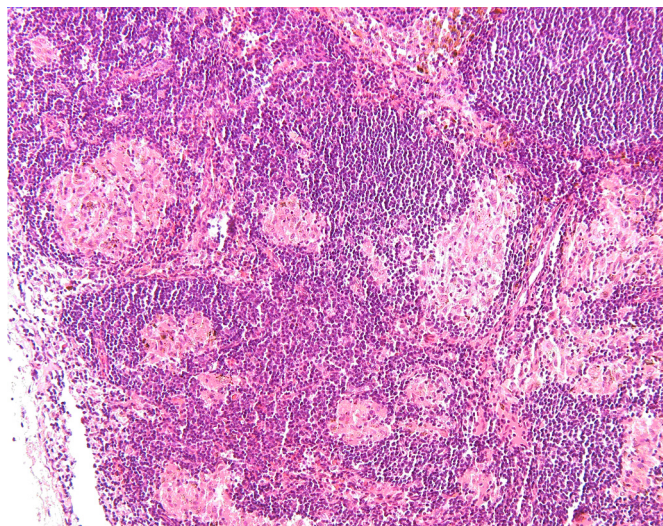


Fig. 2. Non-caseating granulomas in one of the mediastinal lymph node. The granulomas are well formed and consist primarily of epithelioid histiocytes with multinucleated giant cells. These granulomas are characteristic of sarcoidosis lymphadenopathy. The pan-cytokeratin staining was negative, excluding a sarcoid-like reaction to tumor cells (not shown).

Comment

This case illustrates the importance and need for accurate staging with the ultimate proof of histopathological findings,

despite the current developments in sensitive non-invasive imaging technologies.

In the presence of a malignant tumor e.g. lung cancer, PET positive lesions are not always synonymous with metastatic disease. Conscientious review of FDG-PET scans is therefore mandatory. Sarcoid-like reactions in mediastinal lymph nodes can be recognized, showing a typical FDG uptake pattern [1,2]. The exclusion of other diseases presenting with mediastinal lymphadenopathy e.g. infectious or idiopathic, together with histopath-

ological examination are ultimately required for an accurate diagnosis.

Granulomatous reaction is a primary reaction pattern to injury, which can also be observed along with a malignant tumor, both in adjacent tissues and regional lymph nodes as a local or more generalized immune response to cancer cells [3,4]. Another cause for a false positive PET scan, like anthracosis, was recently published [5]. Tissue sampling from both the tumor and the lymph nodes are mandatory and will determine definitive staging and subsequent interventions. To prevent clinical overstaging by underdiagnostics, extensive additional diagnostics based on histopathological findings are preferred.

References

- [1] Hunt BM, Vallieres E, Buduhan G, Aye R, Louie B. Sarcoidosis as a benign cause of lymphadenopathy in cancer patients. *Am J Surg* 2009 May;197(5): 629–32.
- [2] Chowdhury FU, Sheerin F, Bradley KM, Gleeson FV. Sarcoid-like reaction to malignancy on whole-body integrated (18)F-FDG PET/CT: prevalence and disease pattern. *Clin Radiol* 2009 Jul;64(7):675–81.
- [3] Schramel FM, van Groenigen CJ, Rasker FM, Golding RP, Meijer S, Postmus PE. Pulmonary nodules in a patient with seminoma testis. *Chest* 1996 Jan;109(1): 265–6.
- [4] Looijen R, Hoekstra HJ, Sleijfer DT, Postmus P, Oosterhuis JW, de Boer WJ, et al. Sarcoid reaction mimicking intrathoracic dissemination of testicular cancer. *Cancer* 1990 Nov 15;66(10):2221–3.
- [5] Hewitt RJ, Wtight C, Adeboyeke D, Omadel D, Berry M, Wickremasinghe M, et al. Primary nodal anthracosis identified by EBUS-TBNA as a cause of FDG PET/CT positive mediastinal lymphadenopathy. *Respir Med Case Reports* 2013;10:48–52.