

# Postoperative maxillary mucocele with orbital wall defect treated by transnasal endoscopic marsupialization with a penrose drain insertion

## A case report

Tae Hoon Kim, MD<sup>a</sup>, Jung Soo Kim, MD, PhD<sup>a</sup>, Sung Jae Heo, MD<sup>b,\*</sup>

### Abstract

**Rationale:** A postoperative maxillary mucocele (POMM) is a delayed complication of maxillary sinus surgery. Although transoral enucleation is a conventional approach for its treatment, the intraoperative risk of injury to the inferior rectus muscle increases when there is an orbital floor defect. The transnasal endoscopic marsupialization has also been used widely for treatment. However, it has a potential risk of postoperative stenosis of the meatal antrostomy site, especially when the medial wall of the maxillary sinus is thick.

**Patient concerns:** A 60-year-old man who underwent a right Caldwell–Luc operation about 30 years ago came to the emergency room with pain and swelling in the right periorbital region.

**Diagnosis:** He was diagnosed with a POMM accompanied by an orbital floor defect and a thick medial wall of the maxillary sinus.

**Interventions:** Transnasal endoscopic marsupialization was performed, and a cylindrical penrose drain was placed at the antrostomy site for one month.

**Outcomes:** The patient's periorbital pain disappeared after surgery. After 3 months, the postoperative computed tomography scan showed good opening at the meatal antrostomy site.

**Lessons:** In a patient with POMM with an orbital floor defect and a thick medial wall of the maxillary sinus, transnasal endoscopic marsupialization with penrose drain insertion could prevent both injury of the inferior rectus muscle and postoperative stenosis.

**Abbreviations:** CT = computed tomography, POMM = postoperative maxillary mucocele.

**Keywords:** orbital floor defect, penrose drain, postoperative maxillary mucocele

## 1. Introduction

Postoperative maxillary mucocele (POMM) is a late complication of radical maxillary sinus surgery, mainly the Caldwell–Luc operation.<sup>[1,2]</sup> It develops from the residual sinus mucosa about 10 to 30 years after the sinus surgery.<sup>[2]</sup> Transoral enucleation

with a sublabial antrostomy or transnasal endoscopic marsupialization is recommended as treatment.<sup>[1]</sup> If the POMM is accompanied by an orbital floor defect, the risk of injury to the inferior rectus muscle increases with transoral enucleation. On the contrary, when the medial wall of the maxillary sinus is thick, the risk of postoperative stenosis of the meatal antrostomy site and the difficulty of the operation greatly increase with transnasal endoscopic marsupialization.<sup>[2,3]</sup>

We report a case of a patient with a POMM with an ipsilateral orbital floor defect and thickening of the medial wall of the maxillary sinus. We performed transnasal endoscopic marsupialization and succeeded in preventing postoperative stenosis by placing a penrose drain at the antrostomy site for 1 month. To our knowledge, this is the first case where the penrose drain was used to prevent stenosis after endoscopic marsupialization of the POMM in the presence of an orbital floor defect and a thick medial wall of the maxillary sinus.

## 2. Case report

A 60-year-old man who had undergone a right Caldwell–Luc operation about 30 years ago presented with right periorbital pain for 4 months. He had been treated with a maxillary sinus puncture and antibiotics at another hospital for 2 months before visiting our emergency room with persistence of symptoms. At the time of admission, his right cheek was red and swollen. He did not have visual symptoms such as decreased vision, diplopia, or limitation of eye movement (Figs. 1–3).

Editor: N/A.

Informed written consent was obtained from the patient for publication of this case report and accompanying images.

The authors have no conflicts of interest to disclose.

<sup>a</sup>Department of Otorhinolaryngology - Head and Neck Surgery, School of Medicine, Kyungpook National University, Kyungpook National University Hospital, <sup>b</sup>Department of Otorhinolaryngology - Head and Neck Surgery, School of Medicine, Kyungpook National University, Kyungpook National University Chilgok Hospital, Daegu, South Korea.

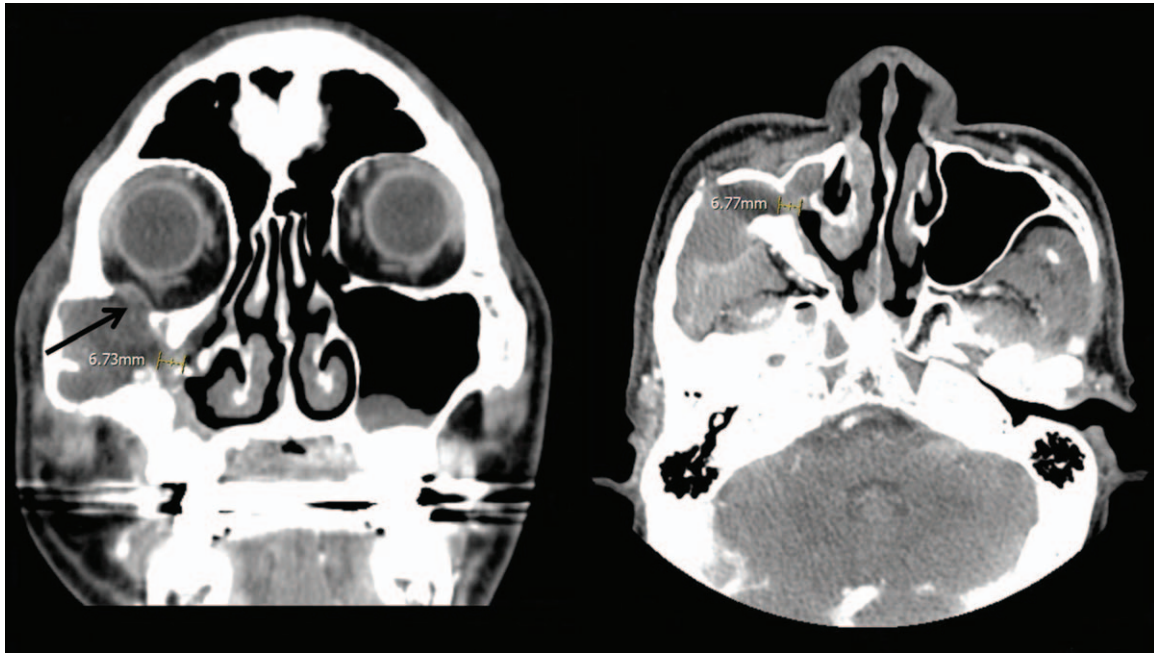
\*Correspondence: Sung Jae Heo, Department of Otorhinolaryngology - Head and Neck Surgery, Kyungpook National University Chilgok Hospital, 807, Hoguk-ro, Buk-gu, Daegu 41404, Korea (e-mail: blueskyhsj@hanmail.net).

Copyright © 2019 the Author(s). Published by Wolters Kluwer Health, Inc. This is an open access article distributed under the terms of the Creative Commons Attribution-Non Commercial-No Derivatives License 4.0 (CCBY-NC-ND), where it is permissible to download and share the work provided it is properly cited. The work cannot be changed in any way or used commercially without permission from the journal.

Medicine (2019) 98:21(e15674)

Received: 21 December 2018 / Received in final form: 5 April 2019 / Accepted: 23 April 2019

<http://dx.doi.org/10.1097/MD.00000000000015674>



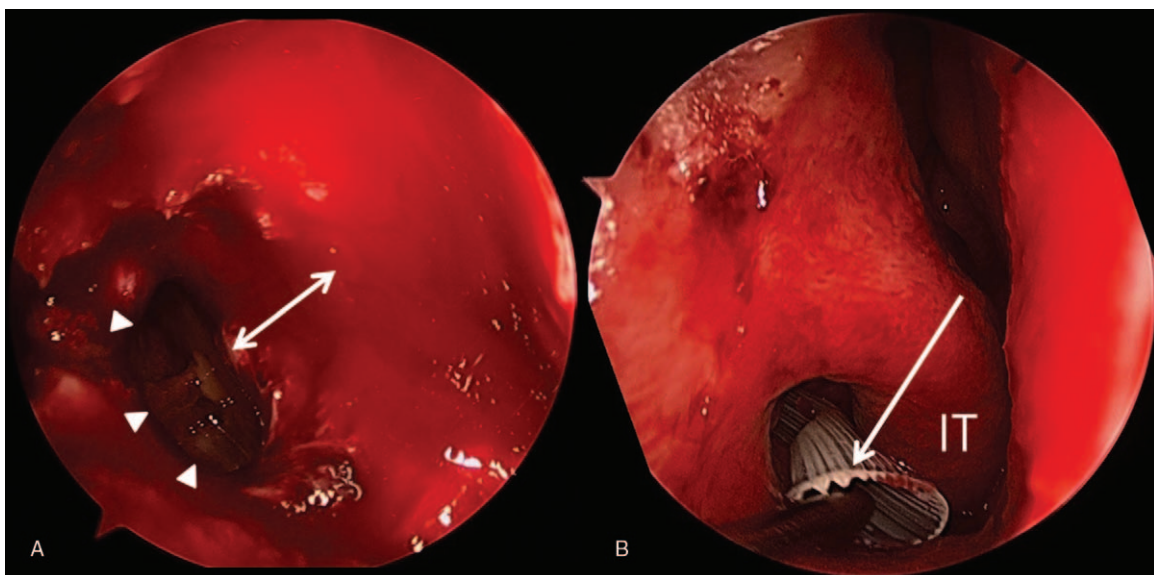
**Figure 1.** Computed tomography shows a cyst with a thick medial wall of the right maxillary sinus (6.73mm) and a defect in the right orbital floor (black arrow).

Contrast-enhanced facial computed tomography (CT) showed a cyst in the right maxillary sinus and a defect in the right orbital floor. The thickness of the medial wall of the right maxillary sinus was approximately 6.7 mm. The diagnosis of POMM was made based on his past history, symptoms, and CT findings.

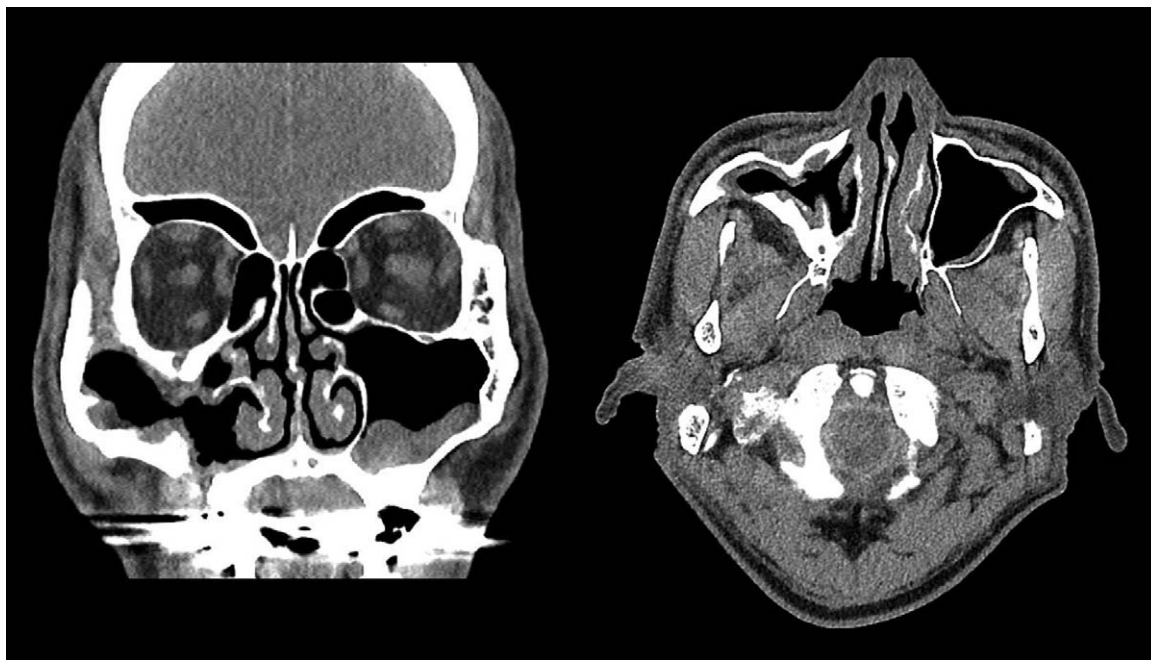Transoral enucleation was deferred, as the risk of injury to the inferior rectus muscle was considered to be very high due to the defect in the orbital floor. Hence, transnasal endoscopic marsupialization was performed under 30° endoscopy using a curved drill. A large quantity of mucopurulent discharge was drained. We then attempted to enlarge the meatal antrostomy site

as wide as possible to reduce the risk of postoperative stenosis. However, in the vicinity of the mucocele, the movement of the drill was limited, and the opening could not be made wide. The size of the meatus at the antrostomy site that could be achieved was approximately  $0.9 \times 0.4$  cm. Hence, we placed a cylindrical penrose drain at the antrostomy site to reduce the risk of postoperative stenosis, and the tip of the drain was fixed with 4-0 nylon to the inferior turbinate. After surgery, the patient's right periorbital pain disappeared.

The patient was discharged without any complications one day after the operation. One month later, the penrose drain was



**Figure 2.** (A) The antrostomy opening (white arrowheads) could not be made wide enough due to the thick medial wall of the maxillary sinus (white double-headed arrow). (B) A penrose drain (black arrow) was placed at the antrostomy site. IT = inferior turbinate.



**Figure 3.** Postoperative computed tomography 3 months after surgery shows the patent opening of antrostomy site.

removed during outpatient treatment. The CT performed 3 months postoperatively showed that the right maxillary sinus was filled with air and the opening of the meatal antrostomy site was good.

### 3. Discussion

POMM is a kind of mucocele that occurs 10 to 30 years after radical maxillary sinus surgery. It originates from the residual mucosa in the maxillary sinus after surgery. It was first described by Kubo in 1927 and is reported to be more common in Japan than in the US or Europe.<sup>[2,4]</sup> Symptoms of the disease vary and progress slowly. The initial symptoms are usually pain and swelling. As the disease progresses, symptoms of orbital involvement such as decreased visual acuity, epiphora, and exophthalmos can also appear.<sup>[4]</sup>

Transoral enucleation with a sublabbial antrostomy has conventionally been used for the treatment of POMM.<sup>[4,5]</sup> As POMM arises from the residual mucosa of the maxillary sinus, thorough removal of the mucocele lining is necessary to prevent the recurrence of POMM after the enucleation.<sup>[2,5]</sup> If an orbital floor defect is present, as in our case, the risk of injury to the inferior rectus muscle during the enucleation is greatly increased.

Transnasal endoscopic marsupialization has also been used for the treatment of POMM after the development of sinus endoscopy and has been proven to be safe and efficacious in several papers.<sup>[2,5]</sup> However, it is associated with a risk of stenosis of the meatal antrostomy site after surgery, especially when the antrostomy site is narrow. Lund<sup>[6,7]</sup> reported that postoperatively, the antrostomy site closed completely in all cases with a meatal antrostomy size of  $0.5 \times 0.5$  cm and suggested that the ideal size of the antrostomy site should be larger than  $1.5 \times 1$  cm. Moreover, when the medial wall of the maxillary sinus is thick, the difficulty of access significantly increases.<sup>[3,4]</sup>

Various methods have been suggested to reduce the risk of stenosis after transnasal endoscopic marsupialization such as using an inferiorly-based mucosal flap, application of mitomycin-C, and using a T-shaped ventilation stent.<sup>[2,3,8]</sup> Among them, the use of the T-shaped ventilation stent, which is placed at the meatal antrostomy site, is most similar to the method used in the present case. However, it has been reported that in this method, an additional sublabbial antrostomy had to be simultaneously performed in half of the patients.<sup>[2]</sup> Moreover, the appropriate T-shaped ventilation stent is available in fewer hospitals than the penrose drain. In addition, if the T-shaped ventilation stent is inserted through the sublabbial incision site, its removal during postoperative outpatient care is difficult.

The penrose drain is inexpensive and widely available. It is also easily removable during outpatient care after surgery. In addition, as in this case, it is possible to insert the penrose drain without performing an additional sublabbial antrostomy.

In this case, the meatal antrostomy site could not be made wide enough during transnasal endoscopic marsupialization. As an alternative method to prevent stenosis, a penrose drain was inserted, maintained for a month, and then removed, which maintained the openness of the antrostomy site. We suggest that the penrose drain insertion be considered as a method of reducing the risk of stenosis of the antrostomy site after transnasal endoscopic marsupialization of POMM.

### Author contributions

**Conceptualization:** Sung Jae Heo.

**Data curation:** Taehoon Kim, Jung Soo Kim.

**Formal analysis:** Taehoon Kim, Jung Soo Kim, Sung Jae Heo.

**Methodology:** Jung Soo Kim, Sung Jae Heo.

**Writing – original draft:** Taehoon Kim, Jung Soo Kim.

**Writing – review & editing:** Sung Jae Heo.

## References

- [1] Shakib K, McCarthy E, Walker DM, et al. Postoperative maxillary cyst: report of an unusual presentation. *Br J Oral Maxillofac Surg* 2009;47:419–21.
- [2] Sawatsubashi M, Murakami D, Oda M, et al. Transnasal endoscopic surgery of post-operative maxillary cysts. *J Laryngol Otol* 2015;129:S46–51.
- [3] Durr ML, Goldberg AN. Endoscopic partial medial maxillectomy with mucosal flap for maxillary sinus mucocoeles. *Am J Otolaryngol* 2014;35:115–9.
- [4] Huang CC, Chen CW, Lee TJ, et al. Transnasal endoscopic marsupialization of postoperative maxillary mucocoeles: middle meatal antrostomy versus inferior meatal antrostomy. *Eur Arch Otorhinolaryngol* 2011;268:1583–7.
- [5] Lee JY, Baek BJ, Byun JY, et al. Long-term efficacy of inferior meatal antrostomy for treatment of postoperative maxillary mucocoeles. *Am J Otolaryngol* 2014;35:727–30.
- [6] Lund VJ. The design and function of intranasal antrostomies. *J Laryngol Otol* 1986;100:35–9.
- [7] Lund VJ. Fundamental considerations of the design and function of intranasal antrostomies. *J R Soc Med* 1986;79:646–9.
- [8] Chung JH, Cosenza MJ, Rahbar R, et al. Mitomycin C for the prevention of adhesion formation after endoscopic sinus surgery: a randomized, controlled study. *Otolaryngol Head Neck Surg* 2002;126:468–74.