

Bilateral Transcervical Femur Neck Fracture in a Case of Pseudohypoparathyroidism: A Rare Case Report and Review of Literature

Shaligram Purohit¹, Nandan Marathe¹, Ankit Amin¹, Abhinav Jogani¹, Ashraf Shaikh¹

Learning Point of the Article:

Multidisciplinary team approach with the involvement of pediatrician, endocrinologist, and orthopedic surgeon and devising a plan after thorough workup keeping in mind the infrequent presentations of hypoparathyroidism and adequate pre-operative optimization helps provide appropriate management of this rare presentation.

Abstract

Introduction: Pseudohypoparathyroidism (PHP) is an uncommon metabolic bone disorder characterized by biochemical hypocalcemia, hyperphosphatemia and raised parathyroid hormone (PTH), and target tissue unresponsiveness to the biological actions of PTH. In addition, many patients with PHP exhibit a distinctive constellation of developmental and skeletal defects.

Case Report: An 11-year-old girl was brought to emergency pediatric department for the assessment of fever with generalized tonic-clonic seizure (GTCS) with inability to walk. She had hypocalcemia and hyperphosphatemia. The diagnosis of PHP was made and was started on Vitamin D3 and oral calcium. Physical examination revealed no dysmorphic features. Biochemical investigations revealed normal complete blood count, liver and renal functions, and arterial blood gas. However, serum PTH was high with slightly decreased Vitamin D3.

Conclusion: As per our knowledge, this is the first reported case in literature of bilateral pathological transcervical neck femur fracture in a case of PHP following episode of GTCS. Multidisciplinary team approach with the involvement of pediatrician, endocrinologist, and orthopedic surgeon and devising a plan after thorough workup keeping in mind the infrequent presentations of hypoparathyroidism and adequate pre-operative optimization helps provide appropriate management of this rare presentation. This case report was prepared following the CARE guidelines.

Keywords: Bilateral transcervical fracture, pathological fractures, pseudohypoparathyroidism.

Introduction

The term pseudohypoparathyroidism (PHP) was first defined by Fuller Albright in a disorder that presented with hypocalcemia and hyperphosphatemia due to parathyroid hormone (PTH) resistance (not deficiency) [1]. Affected individuals show partial/complete resistance to biologically active, exogenous PTH (known as PHP type I). Further, subclassification into Ia and Ib is based on the presence or absence of Albright's hereditary osteodystrophy (AHO) which includes association with other endocrinal disorders such as hypothyroidism and characteristic physical features. PHP type Ia shows AHO, whereas PHP type Ib affected individuals show PTH-resistant hypocalcemia and hyperphosphatemia and lack AHO [2, 3].

Herein, we present an unreported case of PHP who presented with bilateral femoral neck fracture following episode of generalized tonic-clonic seizure (GTCS) and highlights its multidisciplinary management. This case report has been written as per the CARE guidelines [4].

Case Report

Introduction and patient information: An 11-year-old girl was brought to pediatric emergency for the assessment of fever with generalized tonic-clonic seizures and inability to walk. Her serological evaluation revealed hypocalcemia and hyperphosphatemia (Table 1). Workup for fever was normal which subsided on antipyretics.

Access this article online

Website:
www.jocr.co.in

DOI:
10.13107/jocr.2020.v10.i07.1930

Author's Photo Gallery



Dr. Shaligram Purohit



Dr. Nandan Marathe



Dr. Ankit Amin



Dr. Abhinav Jogani



Dr. Ashraf Shaikh

¹Department of Orthopedics, Seth Gordhandas Sunderdas Medical College and King Edward Memorial Hospital, Mumbai, Maharashtra, India.

Address of Correspondence:

Dr. Nandan Marathe,
Saraswati Prasad, Gaul Wada, Vasai (w), Pin: 401201
E-mail: nandanmarathe88@gmail.com

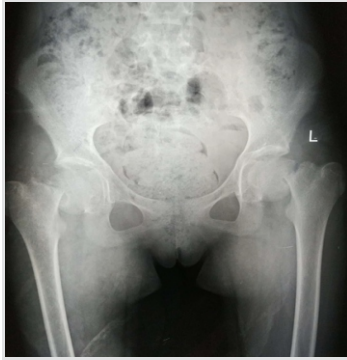

Figure 1: Plain X-ray of the pelvis with both hips: Bilateral displaced femur neck fracture.

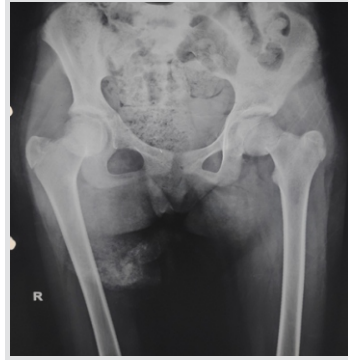

Figure 2: Plain X-ray of the pelvis with both hips traction view.

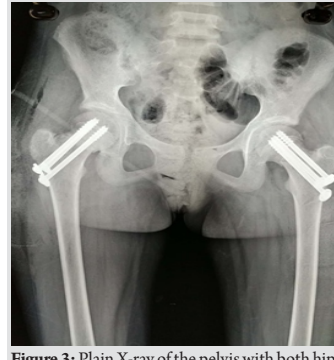

Figure 3: Plain X-ray of the pelvis with both hips (anteroposterior view) showing fracture fixation with three partially threaded cancellous screws.

Radiological examination of hip showed bilateral displaced femur neck fracture (Fig. 1, 2).

Clinical findings, timeline, and diagnostic assessment: The diagnosis of pseudohyperparathyroidism was made and the patient started on oral calcitriol 0.25 mcg daily along with oral calcium. She was born of non-consanguineous marriage full-term normal pregnancy with no immediate neonatal problems. She had received adequate sun exposure with appropriate development (weight and height for age was within normal percentile range) and no signs of liver/renal disease with no dysmorphic features.

Biochemical investigations revealed normal complete blood count, Sr. Vitamin D3 levels, Sr. TSH, free thyroxine (Ft4), urinary calcium/creatinine ratio, liver and renal functions, and arterial blood gas. However, serum calcium was low, while phosphorus, alkaline phosphatase, and PTH levels were elevated, (Table 1).

She was started on oral calcitriol 0.75 µg thrice daily and oral calcium, and after 3 weeks of therapy, her serum calcium levels had risen to 9.2 mg/dl, and serum phosphorus and alkaline phosphatase levels had fallen to 6.2 mg/dl and 238 IU/L, respectively. The level of PTH remained grossly elevated (240 ng/L).

Therapeutic interventions: The patient was managed with bilateral skin traction till normalization of biochemical profile. After correction of biochemical profile, fracture was managed with closed reduction and fixation with three partially threaded cancellous (PTCC) screws about 3 weeks after trauma [5] (Fig. 3, 4)

On traction table under spinal and epidural anesthesia, both the fractures were reduced by closed reduction under fluoroscopic guidance and 3 mm × 6.5 mm partially threaded cannulated cancellous screws were inserted in inverted triangle fashion. Reduction was reconfirmed under C-arm.

Follow-up and outcomes: Postoperatively, hips were kept in abducted position with abduction bar. She was kept nil weight-bearing for 3 months. At latest 1-year follow-up, she was able to sit cross-legged and squat [Fig. 5, 6].

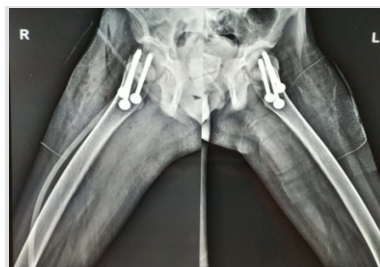

Figure 4: Plain X-ray of the pelvis with both hips (lateral view) showing fracture fixation with three partially threaded cancellous screws.

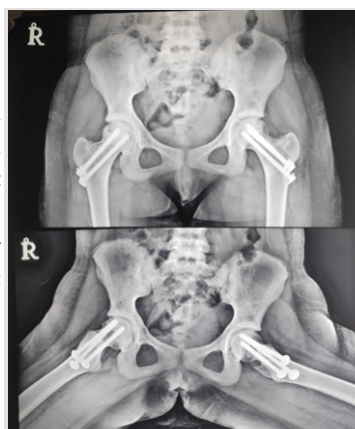


Figure 5: X-ray at 1-year follow-up showing union and remodeling.

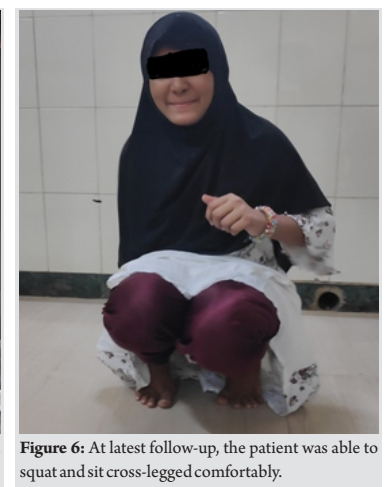

Figure 6: At latest follow-up, the patient was able to squat and sit cross-legged comfortably.

Discussion

Femoral neck fractures in

children are uncommon, accounting for <1% of all fractures in pediatric patients and most orthopedic surgeons have the opportunity to treat such fractures very few times during their career [6]. Bilateral neck femur fracture following GTCS is extremely rare. The treatment of choice is emergency closed or open reduction and internal fixation.

Inadvertent delay in fixation is not uncommon in developing countries due to a variety of reasons [6]. These fractures are known to be associated with multiple complications including osteonecrosis of the femoral neck (which happens to be the most common and disabling complication), non-union, chondrolysis, coxa vara, limb length discrepancies, and premature physeal closure. Primarily, complications have been linked to age of patient, deferred treatment, fracture type, inadequate reduction, and fixation failure [6, 7]. The quest for better outcomes demands thorough enquiry into the etiology.

The differential diagnosis is worked on through a combination of serological tests. The possibility of hypoparathyroidism should be suspected on encountering the twin findings of biochemical hypocalcemia and hyperphosphatemia. A normal thyroid profile without Albright’s specific dysmorphic features or mental retardation then warrants investigation to rule out PHP. Various subtypes of PHP appear to be related to diverse pathophysiologic mechanisms [2, 8]. In PHP type I, PTH is unable to elicit cyclic AMP (cAMP) production in target cells and administration of exogenous PTH does not increase urinary cAMP production. PHP type II is the least common and typically sporadic form devoid of AHO features. Renal resistance to PTH in PHP type 2 is manifested by a reduced phosphaturic response to administration of PTH, despite a normal increase in urinary cAMP excretion [9].

Some patients with PHP type Ia are affected by other endocrinopathies (apparently a result of end-organ resistance) such as hypothyroidism, hypogonadism, and decreased glucagon response. In the PHP type IB patients, the N protein contents of cells are normal



Table 1: Serological parameters

Parameter	Value	Normal
Sr. calcium (mg/dl)	4.2	9.5–10.5
Sr. phosphate (mg/dl)	8.9	2.5–5
Sr. Alkaline phosphatase (IU/L)	193	Up to 117
Sr. PTH (pg/ml)	211	10–65

PTH: Parathyroid hormone

and have no dysmorphic features [4, 10]. In these patients, the exact molecular basis for PTH resistance is unknown. End-organ resistance is mainly encountered in the kidney while the bone remains normally responsive. These patients, classified as PHP type I with osteitis fibrosa [11] or pseudohypo-hyperparathyroidism, have a combination of hypocalcemia and hyperphosphatemia with skeletal signs of hyperparathyroidism. The patient suffering from pseudopseudohyperparathyroidism elicit skeletal resistance but no renal resistance and present with the constitutional features of PHP devoid of hypocalcemia or hyperphosphatemia. In patients with PHP type II, cyclic AMP creation in urine is usually provoked by PTH, but

phosphaturic response is intensely reduced. Malfunctioning tubular response to cyclic AMP leads to end-organ resistance. Interestingly, in these patients, restoration of normocalcemia by treatment with Vitamin D and calcium also restores the phosphaturia response to PTH [3, 9]. Hence, we were able to work up our patient and appropriately manage them with the help from pediatricians and endocrinologists.

Conclusion

As per our knowledge, this is the first reported case in literature of bilateral pathological transcervical neck femur fracture in a case of PHP following episode of GTCS.

Clinical Message

Multidisciplinary team approach with the involvement of pediatrician, endocrinologist, and orthopedic surgeon and devising a plan after thorough workup keeping in mind the infrequent presentations of hypoparathyroidism and adequate pre-operative optimization helps provide appropriate management of this rare presentation.

References

1. Lowe C, Ellinger A, Wright W, Stauffer H. Pseudohypoparathyroidism; the seabright bantam syndrome. *J Pediatr* 1950;36:1-10.
2. Maimin DG, Meneses-Turino L. Seizures causing simultaneous bilateral neck of femur fractures. *Case Rep Orthop* 2019;2019:1-3.
3. Linglart A, Bastepe M, Jüppner H. Similar clinical and laboratory findings in patients with symptomatic autosomal dominant and sporadic pseudohypoparathyroidism Type Ib despite different epigenetic changes at the GNAS locus. *Clin Endocrinol (Oxf)* 2007;67:822-31.
4. Riley DS, Barber MS, Kienle GS, Aronson JK, Von Schoen-Angerer T, Tugwell P, et al. CARE guidelines for case reports: Explanation and elaboration document. *J Clin Epidemiol* 2017;89:218-35.
5. Germain-Lee EL. Management of pseudohypoparathyroidism. *Curr Opin Pediatr* 2019;31:537-49.
6. Varshney MK, Kumar A, Khan SA, Rastogi S. Functional and radiological outcome after delayed fixation of femoral neck fractures in pediatric patients. *J Orthop Traumatol* 2009;10:211-6.
7. Moon ES, Mehlman CT. Risk factors for avascular necrosis after femoral neck fractures in children: 25 Cincinnati cases and meta-analysis of 360 cases. *J Orthop Trauma* 2006;20:323-9.
8. Kidd GS, Schaaf M, Adler RA. Skeletal responsiveness in pseudohypoparathyroidism: A spectrum of clinical disease. *Am J Med* 1980;68:772-81.
9. De Beur SM, Levine MA. Pseudohypoparathyroidism: Clinical, biochemical and molecular features. In: Bilezikian JP, Marcus R, Levine MA, editors. *The Parathyroids: Basic and Clinical Concept*. New York: Academic Press; 2001. p. 807-25.
10. Al-Jurayyan N, Mohamed S, Saad Uddin M, Al-Jurayyan A. Pseudohypoparathyroidism Type 1b; a rare cause of femoral neck fracture. *J Taibah Univ Med Sci* 2011;6:42-6.
11. Murray TM, Rao LG, Wong MM, Waddell JP, McBroom R, Tam C, et al. Pseudohypoparathyroidism with osteitis fibrosa cystica: Direct demonstration of skeletal responsiveness to parathyroid hormone in cells cultured from bone. *J Bone Miner Res* 1993;8:83-91.

Conflict of Interest: Nil
Source of Support: Nil

Consent: The authors confirm that Informed consent of the patient is taken for publication of this case report

How to Cite this Article

Purohit S, Marathe NA, Amin A, Jogani A, Shaikh A. Bilateral transcervical femur neck fracture in a case of pseudohypoparathyroidism: A rare case report and review of literature. *Journal of Orthopaedic Case Reports* 2020 October;10(7):85-87.