

Effects of low-level laser therapy following surgical extraction of the lower third molar with objective measurement of swelling using a three-dimensional system

MAHMUT KOPARAL¹, AYSE OZCAN KUCUK², HILAL ALAN², FATIHA ASUTAY³ and MEHMET AVCI⁴

¹Department of Oral and Maxillofacial Surgery, Faculty of Dentistry, Adiyaman University, Adiyaman 02200;

²Department of Oral and Maxillofacial Surgery, Faculty of Dentistry, Inonu University, Malatya 44280;

³Department of Oral and Maxillofacial Surgery, Faculty of Dentistry, Afyon Kocatepe University, Afyon 03030;

⁴Department of Orthodontics, Faculty of Dentistry, Inonu University, Malatya 44280, Turkey

Received December 12, 2016; Accepted July 11, 2017

DOI: 10.3892/etm.2018.5921

Abstract. The aim of the present study was to evaluate and compare the effects of single- and two-dose low-level laser therapy (LLLT) on the postoperative swelling, trismus and pain of patients undergoing extraction of impacted mandibular third molars. In addition, edema was volumetrically measured with a 3dMD face system. A total of 45 patients were randomly divided into three treatment groups (15 patients in each group) as follows: Group 1, receiving routine management with ice application and serving as the control group; Group 2, receiving a single dose of LLLT immediately following surgery; and Group 3, receiving two doses of LLLT, immediately following surgery and on day 2 after surgery. In the present study, a gallium-aluminum-arsenide (0.3 W, 40 sec, 4 J/cm²) diode laser device was applied extraorally at the insertion point of the masseter muscle. The trismus, pain level and facial swelling of the patients were evaluated. The visual analog scale (VAS) was used to examine the pain degree, while a 3dMD face photogrammetric system was used to evaluate the volumetric alterations of the swelling. The results indicated no statistically significant differences in the mean swelling or trismus among the three groups. The mean VAS measurements did not differ significantly among the groups at postoperative day 2; however, significantly reduced VAS values were observed in Group 2 compared with Group 1 at postoperative day 7 ($P < 0.05$). The present study demonstrated that, although single-dose or two-dose LLLT had beneficial effects on the swelling, trismus and pain level, a significant reduction was only observed in the pain level at postoperative day 7.

Introduction

Surgical extraction of an impacted third molar, typically performed by oral and maxillofacial surgeons, frequently causes postoperative limitation of jaw function and swelling. The surgical trauma-initiated inflammatory process promotes these conditions (1). Numerous approaches have been used to suppress postoperative inflammation, including the use of nonsteroidal anti-inflammatory drugs, corticosteroids, drains, different types of incisions and low-level laser therapy (LLLT) (2,3).

Since the development of laser therapy in 1971, LLLT has been used for the management of various diseases, such as osteoarthritis, carpal tunnel syndrome, tendinopathy, rheumatoid arthritis, lumbago, non-healing ulcers and epicondylitis (1,4,5). The application of LLLT in dentistry also began in the 1970s (6). Laser therapy has been used to prevent or reduce trismus and swelling following the extraction of impacted third molars, and for the treatment of chronic sinusitis, herpes simplex, chronic facial pain, gingivitis, sensory anomalies in the inferior alveolar nerve, dentinal hypersensitivity and pain following periodontal surgery (6). However, while LLLT has been previously used to prevent postoperative trismus and swelling following removal of the third molar, the outcomes are unclear. This may be due to variations in the study plans, differences in the determination of variables associated with postoperative swelling, the use of diverse types of lasers and hand-pieces, and differences in the treatment parameters in previous studies (1).

The objective assessment of postoperative swelling subsequent to the extraction of impacted mandibular third molars is difficult, and evaluation of the results mainly depends on the subjective opinion of the physician. However, facial imaging systems are rapidly improving with the advent of three-dimensional (3D) devices. With these systems, soft tissues of the face can be assessed objectively in a noninvasive manner, as compared with the conventional two-dimensional (2D) imaging technology (7-9). Imaging methods such as traditional 2D cephalometry have disadvantages such as exposing the patient to radiation (10). The 3dMD system provides high

Correspondence to: Dr Hilal Alan, Department of Oral and Maxillofacial Surgery, Faculty of Dentistry, Inonu University, Central Campus, Elazığ Road, Malatya 44280, Turkey
E-mail: hilalturker@hotmail.com

Key words: low-level laser therapy, mandibular third molar surgery, pain, swelling, trismus

precision 3D surface imaging and has several advantages over the traditional 2D imaging systems, including ease of use, rapid image acquisition and being a noninvasive technique. It has been previously reported that 3D imaging affects the diagnosis, preoperative planning and postoperative evaluation (8,11). However, there are few studies in the literature that have evaluated 3D imaging techniques in the assessment of postoperative swelling following the extraction of impacted mandibular third molars (10,12).

It is hypothesized that the postoperative swelling of patients receiving two-dose LLLT following the removal of impacted third molars may be reduced as compared with that occurring after single-dose LLLT. The present study investigated this hypothesis using a 3dMD system to objectively evaluate whether the use of LLLT decreased the postoperative swelling following the removal of impacted third molars. In addition, the current study aimed to evaluate and compare the effects of single- and two-dose LLLT on the maximum mouth opening (indicator of trismus) and the pain level following the molar extraction.

Materials and methods

Patients. A total of 45 patients with an age of ≥ 16 years were enrolled into the present study. The study was approved by the Human Ethics Committee of Inonu University (Malatya, Turkey). All subjects were informed of the risks of oral surgery and experimental treatment, and informed written consent was obtained from all patients.

The inclusion criteria were as follows: Female or male gender, age of >16 years, absence of systemic illness, presence of impacted mandibular third molar(s), and surgical difficulty grade of III B according to the scales of Pell and Gregory (13). Exclusion criteria included: Local infection, contraindications to laser therapy, tobacco use, systemic illness, pregnancy, oral contraceptive use and breastfeeding. All subjects were operated by the same surgeon using similar surgical procedures. The duration of the surgical procedure was noted in each case. LLLT was performed by a different operator on all patients of each group, and measurements were performed by another operator blinded to the patient groups.

Treatment groups. Patients were randomized into three treatment groups (n=15 in each), as follow is: Group 1, which received only routine management with ice application and served as the control group; Group 2, which received single-dose LLLT immediately following surgery; and Group 3, which received two-dose LLLT, immediately following surgery and on postoperative day 2. Ice therapy was given for 24 h after surgery. The laser was applied extraorally at the insertion point of the masseter muscle.

Surgical procedure and treatment. Surgery was performed under local anesthesia with 2 ml of 4% articaine with 1:100,000 epinephrine (Ultracain® D-S Forte; Sanofi Aventis, Topkapı, Istanbul, Turkey). A single surgeon performed all the surgical procedures in order to avoid variations due to the different surgeon skills, which may influence the results. Following surgery, all patients received 500 mg paracetamol (Parol; Atabay Pharmaceuticals and Fine Chemicals, Inc., Istanbul,

Turkey) and benzydamine hydrochloride + chlorhexidine gluconate gargle antiseptic solution (Farhex; Santa Farma, Istanbul, Turkey) two times per day for 7 days.

In the present experimental study, LLLT was performed using a gallium-aluminum-arsenide (GaAlAs) diode laser device (Cheese Dental Laser System; Wuhan Gigaa Optronics Technology Co., Ltd., Wuhan, China) was used. Parameters of the LLLT are given in Table I.

Assessment of trismus and pain. Trismus was assessed at postoperative days 2 and 7 by determining the maximal opening between the right upper and right lower central incisors with a compass and comparing with that prior to surgery as described previously (14). The pain degree was assessed using a visual analog scale (VAS) of 10 points. The scores extended between 0 (no pain) and 10 (the greatest pain). Subsequent to surgery, the patients were directed to mark the intensity level of pain during the postoperative period.

Imaging. The 3dMD face system (3dMD Inc., Atlanta, Georgia, USA) was used to obtain a preoperative image and postoperative images on the days 2 and 7 in all patients included in the present study (Fig. 1). The 3dMD Vultus software was used to analyze the images. Preoperative and postoperative 3D stereophotogrammetric images were imported into the 3dMD Vultus software. Using this program, two different images can be aligned on the selected surfaces, and linear and volumetric measurements can be performed between the aligned images. The analysis began by transferring the images of the patients obtained prior to the surgical procedure, and on postoperative days 2 and 7 as tsb file format into the 3dMD Vultus software. Two images were aligned on the forehead and nasofrontal area for examination subsequent to adjustment. A quadrilateral area with the subnasale, tragion, gonion and menton points as the corners was selected after the images were aligned (Fig. 2), and the volumetric difference between the two surfaces was calculated (Fig. 1). Furthermore, a color histogram was prepared showing the relative volume change between the preoperative and postoperative image (Fig. 3).

Statistical analysis. The IBM SPSS version 22.0 statistics program (IBM Corp., Armonk, NY, USA) was used for statistical analyses. The data are summarized as the mean \pm standard deviation. Normal distribution was assessed using the one-way analysis of variance test. For non-normally distributed data, the Mann-Whitney U test with Bonferroni correction was used to compare between two groups. $P < 0.05$ was considered to indicate a statistically significant difference.

Results

Patient demographics. A total of 45 patients (18 males and 27 females) who had asymptomatic impacted mandibular third molars extracted were included in the study. The patients in Group 1 were 17 to 27 years old (mean, 22.4 years); the patients in Group 2 were 16 to 21 years old (mean, 18.4 years) and the patients in Group 3 were 17 to 27 years old (mean, 21.7 years). Mean duration of surgery was 15.3 min in Group 1, 14.9 min in Group 2 and 12.5 min in Group 3. Regarding the age of

Table I. Parameters of the low-level laser therapy performed in the present study.

Parameter	Value
Wavelength	810 nm
Beam area	3 cm ²
Output power	0.3 Watts
Irradiation time	40 sec
Energy density	4 J/cm ²
Energy delivered	12 J
Pulse rate	Continuous
Application	Non-contact




Figure 1. (A) Preoperative 3dMD image and (B) postoperative 3dMD image on day 2 after surgery. (C) 3dMD image obtained by superimposing two photographs.

patients included in the study, the mean age of Group 2 patients was significantly lower compared with that in Groups 1 and 3

($P<0.001$; Table II). By contrast, there were no statistically significant differences in the sex ratios and duration of surgery among the three groups ($P=0.757$ and $P=0.119$, respectively; Table II).

Swelling, pain level and trismus. The swelling and pain level (according to the VAS values) were significantly reduced between days 2 and 7 in all groups (Table III). However, no statistically significant difference was observed in the mean swelling among the different groups on postoperative day 2 or on day 7 ($P=0.140$ and $P=0.643$, respectively). In addition, there was no significant difference in the mean VAS scores among the three treatment groups on postoperative day 2 ($P=0.233$). By contrast, on day 7 following surgery, there was a statistically significant difference in VAS values among the groups ($P=0.008$). The mean VAS score of Group 1 was significantly higher compared with that of Group 2 ($P=0.005$), although no significant difference was detected between Group 3 and Groups 1 and 2 ($P=0.178$ and $P=0.021$, respectively; Table III).

For the determination of alterations in trismus, the interincisal mouth opening of patients was examined. The results detected no statistically significant difference in the trismus occurring subsequent to surgery in Groups 1, 2 or 3 when compared with the interincisal opening prior to surgery ($P=0.730$, $P=0.441$ and $P=0.918$; Table III).

Discussion

The removal of impacted mandibular third molar teeth is one of the most common procedures in oral surgery (15). The surgical extraction of an impacted third molar tooth results in postoperative morbidity, which may be divided into immediate postoperative tissue reactions and complications (16). Pain, swelling and limited mouth opening due to muscle spasm (also known as trismus) are the most common complications that cause significant postoperative discomfort (17), and adversely affect the quality of life of patients (18). Therefore, clinicians have highlighted the necessity for better management of these complications in patients who undergo third molar surgery (19).

These complications can be reduced by administration of nonsteroidal anti-inflammatory drugs (NSAIDs), local or systemic corticosteroids, or the combination of corticosteroids and NSAIDs (20-23). However, these drugs may be unsafe in certain patients and may cause various side effects, such as gastrointestinal irritation, systemic bleeding or allergic reactions (22). Thus, there is growing interest in establishing alternative methods without side effects. In this regard, the use of LLLT offers promising application possibilities (1).

LLLT was first used in the fields of dentistry and oral surgery in the early 1970s, and has since expanded to different medical specialties (1). Due to variations in application, the efficacy of LLLT for the prevention of pain, postoperative swelling and trismus subsequent to third molar surgery remains controversial. This variation may be due to differences in study design or methods, difficulties in the measurement of variables associated with postoperative sequelae, differences in the type of lasers and hand-pieces used, and differences in irradiation parameters (1,24,25).




Figure 2. 3dMD image demonstrating the selection of the swelling region (blue) on day 2 after surgery.

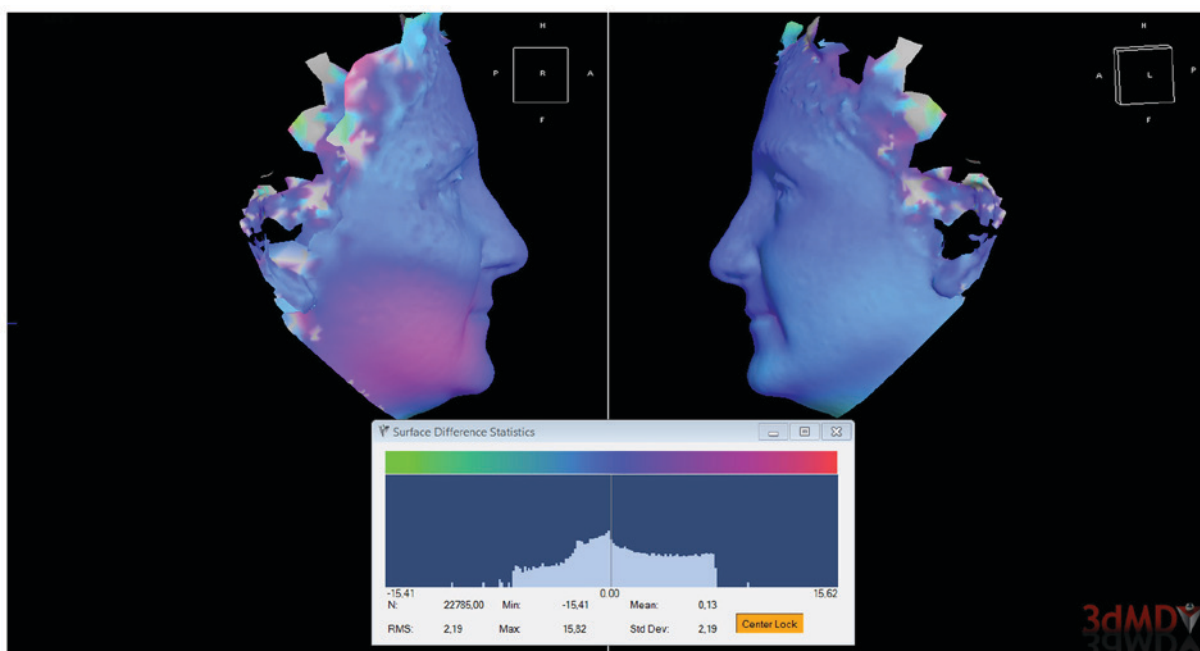


Figure 3. Pink-shaded regions in the three-dimensional histograms define the regions of volume increase, while blue-shaded regions in the histograms define the areas of volume decrease (postoperative day 2).

Numerous studies have used LLLT in dentoalveolar surgery in order to reduce facial swelling, pain and trismus (1,6,21,24,26). However, there is not sufficient evidence to support that the use of LLLT is more effective when compared with no active treatment (placebo or no treatment) to minimize pain, swelling and trismus following impacted mandibular third molar surgical removal (27). Studies with positive, as well as negative results have been reported. For instance, Carrillo *et al* (26) reported no significant differences in the levels of pain and swelling between the laser-treated and the placebo groups. However, in the same study, LLLT (He-Ne; 633 nm; energy density of 10 J/cm²) provided a significant reduction in trismus in the laser-treated group after 7 days. In addition, Aras and Güngörmüş (6) observed that LLLT (GaAlAs; 808 nm; energy density of 4 J/cm²) significantly decreased trismus, although there were no significant differences in the levels of swelling between the intraoral-LLLT and the placebo groups. By contrast, López-Ramírez *et al* (14) reported that LLLT (GaAlAs; 810 nm; energy density of 5 J/cm²) had no beneficial effects in reducing pain, swelling and trismus following removal

of impacted third molars. Røyneisdal *et al* (28) reported that LLLT (830 nm; 40 mW; 6 J) had similar results to those observed by the López-Ramírez *et al* (14) study. Furthermore, Ferrante *et al* (1) demonstrated that LLLT (980 nm; 300 mW; 180 sec) was useful for the reduction of postoperative trismus and swelling subsequent to third molar surgery. According to the results of the present study, significantly reduced pain and swelling was observed between days 2 and 7 after surgery in all three groups. However, LLLT treatment had no significant effect on the swelling and trismus among the three groups at either postoperative time point. In addition, while no statistically significant differences were observed in the levels of pain at 2 days after surgery, there was a statistically significant difference in pain levels among the groups at 7 days after surgery.

Amarillas-Escobar *et al* (29) performed a similar study to the current study, although in order to evaluate the cumulative effect of the therapeutic laser, LLLT (Nd-YAG; 810 nm; 4 J/cm²) was applied as multiple daily intraoral doses immediately after surgery and postoperatively at 24, 48 and 72 h. The results of their study demonstrated no significant differences

Table II. Patient demographics and surgery duration.

Parameter	Group 1	Group 2	Group 3	P-value
Gender, n (%)				0.757
Female	9 (60)	8 (53.3)	10 (66.7)	
Male	6 (40)	7 (46.7)	5 (33.3)	
Age, years	22.4±5.4 ^a	18.4±1.4	21.7±3.2 ^a	0.002
Duration of surgery, min	15.3±5.8	14.9±3.8	12.5±3.2	0.119

Data are presented as the number of patients (%) or as the mean ± standard deviation. ^aP<0.01 vs. Group 2 (Bonferroni correction).

Table III. Swelling, trismus (according to the interincisal opening alteration) and VAS of patients.

Parameter	Group 1	Group 2	Group 3	P-value
Swelling (ml)				
Day 2	20.3±11.8	15.5±5.4	22.8±13.4	0.140
Day 7	6.6±8.2	2.3±1.8	3.8±3.6	0.643
P-value	0.001	0.001	0.001	
VAS score				
Day 2	4.1±2.0	3.4±1.9	4.7±2.4	0.233
Day 7	2.1±1.4	0.6±1.2 ^a	1.5±1.1	0.008
P-value	0.007	0.001	0.002	
Interincisal opening (mm)				
Day 0	44.1±6.0	43.3±6.9	45.0±4.1	0.730
Day 2	26.8±4.6	31.1±10.7	28.1±7.5	0.441
Day 7	37.2±6.9	37.1±9.7	38.1±6.1	0.918
P-value	<0.001	<0.001	<0.001	

Data are presented as the mean ± standard deviation. ^aP<0.05 vs. Group 1 (Bonferroni correction). VAS, visual analog scale.

in the reduction of pain, swelling or trismus between the laser-treated and control groups. In the present study, patients in Group 3 received two doses of LLLT, immediately following surgery and postoperatively at 48 h, and no statistically significant differences were observed in the swelling and trismus between groups. However, a statistically significant difference was identified in the mean VAS levels between the groups at postoperative day 7 (P=0.008), and the mean VAS score was significantly higher in Group 1 compared with that in Group 2.

In the current study, the laser was used extraorally since a previous study by Aras and Güngörmüş (6) demonstrated that extraoral LLLT was more effective in comparison with intraoral LLLT for the reduction of postoperative trismus and swelling following extraction of the lower third molar.

A number of different techniques have been previously used to measure postoperative swelling, including verbal response scales, mechanical methods (cephalostats, calipers, and registration of reference points or landmarks), ultrasound, photographic techniques, computed tomography and magnetic resonance imaging (28,30-32). Advances in 3D imaging techniques have made it possible to capture and superimpose facial images and measure alterations in soft tissue position in three dimensions (33). Soft tissue images obtained with the 3dMD system provide photorealistic views and capture the texture

of the skin with better accuracy and reproducibility (34). Therefore, the present study used the 3dMD face imaging system to measure the postoperative swelling following mandibular third molar surgery. The 3D facial images were obtained immediately prior to the surgical procedure, as well as on days 2 and 7 following the surgical procedure.

Clinically, 3dMD system can be used to objectively measure volume changes in the craniomaxillofacial region and to evaluate the effects of clinical interventions (35). Asutay *et al* (9) evaluated the effects of platelet rich fibrin on swelling with the 3dMD imaging system, which was used for the first time in lower third molar surgery. Furthermore, in our earlier study (12), we evaluated the effect of LLLT (two doses) on the pain, mouth opening and swelling of patients whose bilateral impacted third molar teeth were extracted in addition to measurement volumetrically to the edema with 3dMD face system. A random side impacted tooth of the patients was extracted at the first appointment, and an extraoral laser was applied on the area of masseter muscle immediately after surgery and at postoperative day 2. At the follow-up appointment 1 month later, the other side impacted 3rd molar tooth was then extracted and ice was applied for the first 48 h. In this earlier study, although the results show that the proposed method reduces pain, swelling, and trismus,

significant differences in pain level were observed only at day 7 compared with the control group (12). The current study aimed to examine the effect of two different LLLT protocols (single dose and two doses) on postoperative pain, facial swelling and trismus of patients whose unilateral impacted third molar tooth was extracted. The results of the present study have shown that LLLT was effective in reducing pain level only at postoperative day 7.

In conclusion, the present study evaluated the effect of two different LLLT protocols on postoperative pain, facial swelling and trismus subsequent to mandibular third molar surgery. Furthermore, a 3D method was used to objectively evaluate volume changes in swelling. Intergroup analysis revealed no significant differences between the groups regarding swelling and trismus on postoperative days 2 or 7. However, single-dose LLLT resulted in a significant reduction in pain on day 7. These data suggested that the use of single-dose LLLT was more effective compared with routine management for the reduction of pain following third molar surgery. However, the application of two-dose LLLT did not increase the beneficial effects on reducing pain, swelling and trismus following the surgery.

Acknowledgements

This study was presented as a poster presentation at the 21st Congress of the Balkan Stomatological Society, May 2016, Banja Luka, Bosnia and Herzegovina.

References

- Ferrante M, Petrini M, Trentini P, Perfetti G and Spoto G: Effect of low-level laser therapy after extraction of impacted lower third molars. *Lasers Med Sci* 28: 845-849, 2013.
- Mehrabi M, Allen JM and Roser SM: Therapeutic agents in perioperative third molar surgical procedures. *Oral Maxillofac Surg Clin North Am* 19: 69-84, vi, 2007.
- Carrillo JS, Calatayud J, Manso FJ, Barberia E, Martinez JM and Donado M: A randomized double-blind clinical trial on the effectiveness of helium-neon laser in the prevention of pain, swelling and trismus after removal of impacted third molars. *Int Dent J* 40: 31-36, 1990.
- Mester E, Spiry T, Szende B and Tota JG: Effect of laser rays on wound healing. *Am J Surg* 122: 532-535, 1971.
- Silveira PC, Silva LA, Freitas TP, Latini A and Pinho RA: Effects of low-power laser irradiation (LPLI) at different wavelengths and doses on oxidative stress and fibrogenesis parameters in an animal model of wound healing. *Lasers Med Sci* 26: 125-131, 2011.
- Aras MH and Güngörmüş M: Placebo-controlled randomized clinical trial of the effect two different low-level laser therapies (LLLT)-intraoral and extraoral-on trismus and facial swelling following surgical extraction of the lower third molar. *Lasers Med Sci* 25: 641-645, 2010.
- Kau CH, Cronin AJ and Richmond S: A three-dimensional evaluation of postoperative swelling following orthognathic surgery at 6 months. *Plast Reconstr Surg* 119: 2192-2199, 2007.
- Simanca E, Morris D, Zhao L, Reisberg D and Viana G: Measuring progressive soft tissue change with nasoalveolar molding using a three-dimensional system. *J Craniofac Surg* 22: 1622-1625, 2011.
- Asutay F, Yolcu Ü, Geçör O, Acar AH, Öztürk SA and Malkoç S: An evaluation of effects of platelet-rich-fibrin on postoperative morbidities after lower third molar surgery. *Niger J Clin Pract* 20: 1531-1536, 2017.
- Nord F, Ferjencik R, Seifert B, Lanzer M, Gander T, Matthews F, Rucker M and Lübbers HT: The 3dMD photogrammetric photo system in cranio-maxillofacial surgery: Validation of interexaminer variations and perceptions. *J Craniofac Surg* 43: 1798-1803, 2015.
- Bared A, Rashaan A, Caughlin BP and Toriumi DM: Lower lateral cartilage repositioning: Objective analysis using 3-dimensional imaging. *JAMA Facial Plast Surg* 16: 261-267, 2014.
- Alan H, Yolcu U, Koparal M, Özgür C, Öztürk SA and Malkoç S: Evaluation of the effects of the low-level laser therapy on swelling, pain, and trismus after removal of impacted lower third molar. *Head Face Med* 12: 25, 2016.
- Pell GJ and Gregory GT: Report on a ten-year study of a tooth division technique for the removal of impacted teeth. *Am J Orthod Oral Surg* 28: B660-B666, 1942.
- López-Ramírez M, Vélchez-Pérez MA, Gargallo-Albiol J, Arnabat-Domínguez J and Gay-Escoda C: Efficacy of low-level laser therapy in the management of pain, facial swelling, and postoperative trismus after third molar extraction. A preliminary study. *Lasers Med Sci* 27: 559-566, 2012.
- Sigron GR, Pourmand PP, Mache B, Stadlinger B and Locher MC: The most common complications after wisdom-tooth removal: Part 1: A retrospective study of 1,199 cases in the mandible. *Swiss Dent J* 124: 1042-1046, 1052-1056, 2014.
- Bello SA, Adeyemo WL, Bamgbose BO, Obi EV and Adeyinka AA: Effect of age, impaction types and operative time on inflammatory tissue reactions following lower third molar surgery. *Head Face Med* 7: 8, 2011.
- Barone A, Marconcini S, Giacomelli L, Rispoli L, Calvo JL and Covani U: A randomized clinical evaluation of ultrasound bone surgery versus traditional rotary instruments in lower third molar extraction. *J Oral Maxillofac Surg* 68: 330-336, 2010.
- Colorado-Bonnin M, Valmaseda-Castellón E, Berini-Aytés L and Gay-Escoda C: Quality of life following lower third molar removal. *Int J Oral Maxillofac Surg* 35: 343-347, 2006.
- Kazancıoğlu HO, Ezirganlı S and Demirtas N: Comparison of the influence of ozone and laser therapies on pain, swelling, and trismus following impacted third-molar surgery. *Lasers Med Sci* 29: 1313-1319, 2014.
- Vegas-Bustamante E, Micó-Llorens J, Gargallo-Albiol J, Satorres-Nieto M, Berini-Aytés L and Gay-Escoda C: Efficacy of methylprednisolone injected into the masseter muscle following the surgical extraction of impacted lower third molars. *Int J Oral Maxillofac Surg* 37: 260-263, 2008.
- Marković AB and Todorović L: Postoperative analgesia after lower third molar surgery: Contribution of the use of long-acting local anesthetics, low-power laser, and diclofenac. *Oral Surg Oral Med Oral Pathol Oral Radiol Endod* 102: e4-e8, 2006.
- Merry AF, Gibbs RD, Edwards J, Ting GS, Frampton C, Davies E and Anderson BJ: Combined acetaminophen and ibuprofen for pain relief after oral surgery in adults: A randomized controlled trial. *Br J Anaesth* 104: 80-88, 2010.
- Kim K, Brar P, Jakubowski J, Kaltman S and Lopez E: The use of corticosteroids and nonsteroidal antiinflammatory medication for the management of pain and inflammation after third molar surgery: A review of the literature. *Oral Surg Oral Med Oral Pathol Oral Radiol Endod* 107: 630-640, 2009.
- Markovic A and Todorovic L: Effectiveness of dexamethasone and low-power laser in minimizing oedema after third molar surgery: A clinical trial. *Int J Oral Maxillofac Surg* 36: 226-229, 2007.
- Miloro M and Repasky M: Low-level laser effect on neurosensory recovery after sagittal ramus osteotomy. *Oral Surg Oral Med Oral Pathol Oral Radiol Endod* 89: 12-18, 2000.
- Carrillo JS, Calatayud J, Manso FJ, Barberia E, Martinez JM and Donado M: A randomized double-blind clinical trial on the effectiveness of helium-neon laser in the prevention of pain, swelling and trismus after removal of impacted third molars. *Int Dent J* 40: 31-36, 1990.
- Brignardello-Petersen R, Carrasco-Labra A, Araya I, Yanine N, Beyene J and Shah PS: Is adjuvant laser therapy effective for preventing pain, swelling, and trismus after surgical removal of impacted mandibular third molars? A systematic review and meta-analysis. *J Oral Maxillofac Surg* 70: 1789-1801, 2012.
- Røynesdal AK, Björnland T, Barkvoll P and Haanaes HR: The effect of soft-laser application on postoperative pain and swelling. A double-blind, crossover study. *Int J Oral Maxillofac Surg* 22: 242-245, 1993.
- Amarillas-Escobar ED, Toranzo-Fernández JM, Martinez-Rider R, Noyola-Frías MA, Hidalgo-Hurtado JA, Serna VM, Gordillo-Moscote A and Pozos-Guillén AJ: Use of therapeutic laser after surgical removal of impacted lower third molars. *J Oral Maxillofac Surg* 68: 319-324, 2010.
- Erdogan O, Tatlı U, Ustün Y and Damlar I: Influence of two different flap designs on the sequelae of mandibular third molar surgery. *Oral Maxillofac Surg* 15: 147-152, 2011.

31. Al-Khateeb TH and Nusair Y: Effect of the proteolytic enzyme serrapeptase on swelling, pain and trismus after surgical extraction of mandibular third molars. *Int J Oral Maxillofac Surg* 37: 264-268, 2008.
32. Meisami T, Musa M, Keller MA, Cooper R, Clokie CM and Sándor GK: Magnetic resonance imaging assessment of airway status after orthognathic surgery. *Oral Surg Oral Med Oral Pathol Oral Radiol Endod* 103: 458-463, 2007.
33. Cevidanes LH, Oliveira AE, Grauer D, Styner M and Proffit WR: Clinical application of 3D imaging for assessment of treatment outcomes. *Semin Orthod* 17: 72-80, 2011.
34. Lane C and Harrell W Jr: Completing the 3-dimensional picture. *Am J Orthod Dentofacial Orthop* 133: 612-620, 2008.
35. van der Meer WJ, Dijkstra PU, Visser A, Vissink A and Ren Y: Reliability and validity of measurements of facial swelling with a stereophotogrammetry optical three-dimensional scanner. *Br J Oral Maxillofac Surg* 52: 922-927, 2014.



This work is licensed under a Creative Commons Attribution-NonCommercial-NoDerivatives 4.0 International (CC BY-NC-ND 4.0) License.