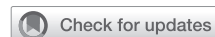

Case report: Using the so-called “sutureless-technique” for the treatment of a giant right atrium myocardial lipoma



Spiros Lukas Marinos, MD, Rodrigo Sandoval Boburg, MD, Migdat Mustafi, MD, and Christian Schlensak, MD, PhD, Tübingen, Germany

From the Department of Thoracic and Cardiovascular Surgery, Tübingen University Hospital, Tübingen, Germany.

Disclosures: The authors reported no conflicts of interest.

The *Journal* policy requires editors and reviewers to disclose conflicts of interest and to decline handling or reviewing manuscripts for which they may have a conflict of interest. The editors and reviewers of this article have no conflicts of interest.

Received for publication July 2, 2022; revisions received Sept 15, 2022; accepted for publication Sept 16, 2022; available ahead of print Oct 4, 2022.

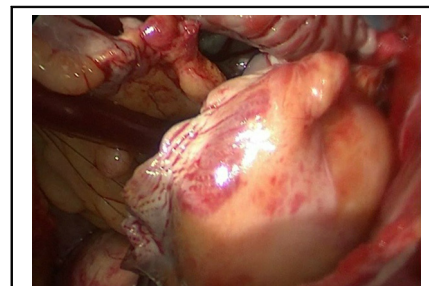
Address for reprints: Spiros Lukas Marinos, MD, Department of Thoracic and Cardiovascular Surgery, Tübingen University Hospital, Hoppe-Seyler-Straße 3, 72076 Tübingen, Germany (E-mail: Spiros.marinos@med.uni-tuebingen.de).

JTCVS Techniques 2022;16:120-2

2666-2507

Copyright © 2022 The Author(s). Published by Elsevier Inc. on behalf of The American Association for Thoracic Surgery. This is an open access article under the CC BY-NC-ND license (<http://creativecommons.org/licenses/by-nc-nd/4.0/>).

<https://doi.org/10.1016/j.jtc.2022.09.018>



Interatrial lipoma before excision using the sutureless technique.

CENTRAL MESSAGE

The sutureless technique is a useful and safe technique to provide atrial reconstruction of the right heart in complex cardiac tumors.

Video clip is available online.

A 65-year-old woman with progressive dyspnea underwent a diagnostic computed tomography scan, from which a right atrial mass measuring 4 × 5 cm was diagnosed. A preoperative axial computed tomography scan is shown in [Video 1](#). The structure had a broad base at the right atrial septum ([Figure 1](#)). After the diagnosis, the patient was referred to our center for urgent operative treatment.

Findings of the physical examination of the cardiopulmonary system were normal. Secondary diagnoses included hypothyroidism, depression, nicotine abuse, and a history of left-side breast carcinoma. Intraoperative echocardiography showed a normal ventricular function, no significant valvopathies, and a right atrial mass infiltrating the atrial septum ([Figure 1](#)).

Access to the heart was performed through a right anterolateral thoracotomy in the fifth intercostal space with cannulation of the femoral vessels. The access of this minimally invasive procedure was performed for reduced sternal damage associated with reduced postoperative complications such as decreased bleeding and pain and improved access to the right and left atrium without luxation of the heart. In addition, we used femoral and jugular venous drainage to avoid a limitation of both cannulas in the operative situs. After start of cardiopulmonary bypass, the pericardium was incised 2 cm above the right phrenic nerve and extended to

the superior vena cava. A solid structure was palpable at the level of the right pulmonary veins. After clamping of the ascending aorta, cardioplegia (modified Buckberg solution) was administered via the coronary sinus.

The tumor was broad based, infiltrating almost the complete atrial septum. The tumor was removed in toto with a safe margins, removing the atrial septum and amputating the superior and inferior venae cavae, as well as the right pulmonary veins ([Figure 2](#)). For reconstruction of the left atrium, autologous pericardium was used. Then, the right phrenic nerve was carefully removed (neurolysis) from the pericardium. We created a new left atrium by anastomosing the left atrium wall to the posterior pericardium.

Then, the pericardium was turned over the right merging pulmonary veins and anastomosed with the remaining atrial septum so called “sutureless-technique.”¹⁻⁵ The remaining pericardium was then anastomosed to the left atrial wall. For reconstruction of the right atrium, a bovine pericardial patch was anastomosed with the superior vena cava via a continuous polypropylene suture. The remaining right atrium was then reconstructed with the remaining patch, following the insertion of the inferior vena cava in the patch-reconstruction.

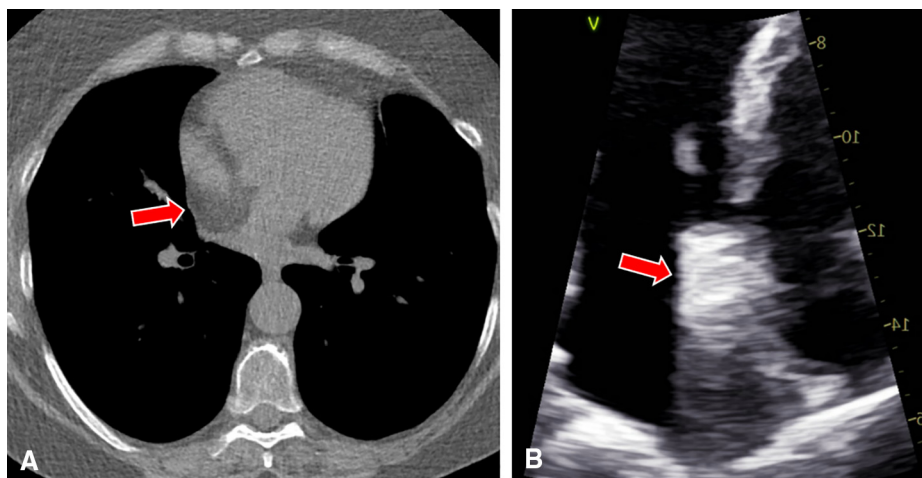


FIGURE 1. A, Preoperative computed tomography scan. *Red arrow* is indicating a mass in the atrial septum. B, Intraoperative transesophageal echocardiography scan. *Red arrow* is indicating a mass in the atrial septum.

After we completed the reconstruction of the right and left atrium, deairing of the left heart was performed via the ascending aorta. After we successfully weaned the patient from cardiopulmonary bypass, echocardiography showed an unobstructed inflow of the right pulmonary veins as well as both venae cavae. After an uncomplicated postoperative course, she was discharged home 7 days after the operation on a single-aspirin regimen. Histologic evaluation of the intraoperative specimen revealed a myocardial lipoma. We performed an echocardiographic follow-up 3 months after the operation. Left ventricular function was preserved, and there was no pericardial effusion or atrial septal defect detected.

No specific personal data were used in this manuscript; therefore, informed consent was not necessary.

DISCUSSION

Solid masses of the right atrium are rarely found incidentally by using routine echocardiography at an early stage before causing clinical symptoms. Diagnostic investigations are usually limited to imaging studies; therefore, a precise primary diagnosis is difficult to make. The alternative

presence of a right atrial mass is highly suspicious of a myxoma, a thrombus, or an endocardial fibroelastoma.

The macroscopic differentiation criteria, however, are unreliable, and a final diagnosis of the type and dignity of the tumor can only be made by means of histologic evaluation. A specific characteristic of myocardial lipomas is the absence of the absorption of contrast medium on magnetic resonance imaging examination.

In consideration of a differential diagnosis, the atrial myxoma is the most likely of a variety of cardiac tumors. Although typically located in the left atrium, myxomas have also been found in the right atrium in a substantial number of patients.² Myocardial lipomas are described as extremely rare in the literature. In comparison with other benign tumors of the heart, the myocardial lipoma has no preferred localization.⁶

One of the advantages of using the sutureless technique for treating a solid interatrial tumor is the improved freedom of pulmonary vein stenosis after reconstructing the left atrium. The sutureless repair shows a lower risk of reoperation and death in children with postrepair stenosis and

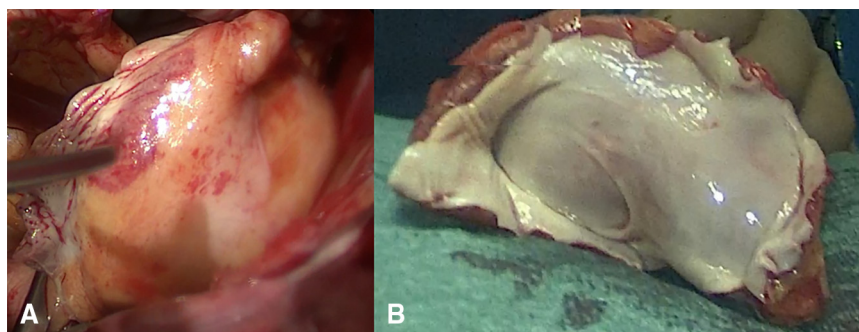
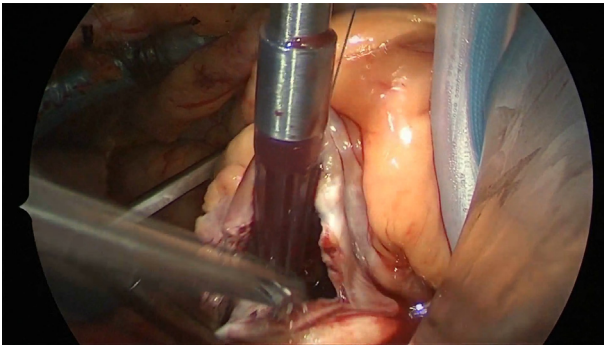


FIGURE 2. A, Right atrial lipoma in situ. B, Right atrial lipoma after excision as seen from the right atrium.



VIDEO 1. This video shows the access to the operative situs. It also shows the technique to excise the tumor of the atrium. It also includes total overview of the tumor. Video available at: [https://www.jtcvs.org/article/S2666-2507\(22\)00520-X/fulltext](https://www.jtcvs.org/article/S2666-2507(22)00520-X/fulltext).

therefore seems to be safe in adult patients with need of intratrial reconstruction. One of the disadvantages is the nearby located phrenic nerve, which needs to be carefully freed in order to avoid an injury.

CONCLUSIONS

Myocardial lipomas of the right atrium are extremely rare; the sutureless technique, described formerly in pediatric cardiac surgery, is a useful and safe technique to provide atrial reconstruction of the right heart in complex cardiac tumors.

References

1. Hickey EJ, Caldarone CA. Surgical management of post-repair pulmonary vein stenosis. *Semin Thorac Cardiovasc Surg Pediatr Card Surg Annu.* 2011;14:101-8.
2. Reynen K. Cardiac myxomas. *N Engl J Med.* 1995;333:1610-7.
3. Lacour-Gayet F, Rey C, Planché C. Pulmonary vein stenosis. Description of a sutureless surgical procedure using the pericardium in situ. *Arch Mal Coeur Vaiss.* 1996;89:633-6.
4. Lacour-Gayet F, Zoghbi J, Serraf AE, Belli E, Piot D, Rey C, et al. Surgical management of progressive pulmonary venous obstruction after repair of total anomalous pulmonary venous connection. *J Thorac Cardiovasc Surg.* 1999;117:679-87.
5. Xia J, Ma K, Ge H, Hu X, Du J, Wu G, et al. Outcomes of surgical repair of total anomalous pulmonary venous drainage: role of primary sutureless technique. *Pediatr Cardiol.* 2021;42:1316-23.
6. Thelen M, Raimund E, Kreitner K-F, Barkhausen J. *Bildgebende Kardiagnostik.* Georg Thieme Verlag; 2007.