


## Case Report

# Intraoperative complications of vertebral body stenting system

Ryo Kanematsu<sup>1</sup>, Junya Hanakita, Toshiyuki Takahashi, Manabu Minami, Sho Nakamura, Shinya Tokunaga, Izumi Suda  
Spinal Disorders Center, Fujieda Heisei Memorial Hospital, Fujieda, Japan.

E-mail: \*Ryo Kanematsu - ryo.knmt@gmail.com; Junya Hanakita - heisei.spine-jh@ny.tokai.or.jp; Toshiyuki Takahashi - heisei.t-taka@ny.tokai.or.jp; Manabu Minami - minami@mac.com; Sho Nakamura - nsho.1018@gmail.com; Shinya Tokunaga - stokunaga129@kuhp.kyoto-u.ac.jp; Izumi Suda - izumis306@gmail.com



### \*Corresponding author:

Ryo Kanematsu,  
Spinal Disorders Center,  
Fujieda Heisei Memorial  
Hospital, Fujieda, Japan.

ryo.knmt@gmail.com

Received : 05 April 2023

Accepted : 13 April 2023

Published : 28 April 2023

### DOI

10.25259/SNI\_299\_2023

### Quick Response Code:



## ABSTRACT

**Background:** Vertebral body stenting systems (VBSs) are superior to balloon kyphoplasty for performing vertebral augmentation and height restoration. However, VBS may likely result in more material-related complications that have been under-reported. Here, an 84-year-old female's vertebral stents "toppled over" before the filling cement was fully applied, thus necessitating an additional posterior fusion.

**Case Description:** An 84-year-old female presented with low back pain after a fall. Dynamic standing and decubitus X-rays revealed a vertebral compression fracture at T12 resulting in an intravertebral vacuum cleft (i.e., the lowermost level of diffuse idiopathic skeletal hyperostosis). When the VBS was performed, the stents "toppled over" just after removing the balloon catheters; we successfully restored with the cement volume in one stent but not the other, thus warranting an additional posterior fusion to maintain stability.

**Conclusion:** The proper injection of cement into a VBS requires dual correct stent positioning, and careful control of requisite stent expansion. In an 84-year-old female with a T12 vertebral body fracture and a remarkable vacuum cleft, the VBS procedure resulted in an inadvertent injection into one stent thus warranting a secondary posterior fusion.

**Keywords:** Material failures, Stent tumbling motion, Stent-related complication, Vertebral body stenting system (VBS)

## INTRODUCTION

Vertebral body stenting systems (VBSs) are superior to percutaneous vertebroplasty and balloon kyphoplasty (BKP) for augmenting and restoring vertebral body height following vertebral compression fractures.<sup>[2,4]</sup> One clinical randomized trial, however, documented that VBS results in more material-related, and procedural complications versus BKP.<sup>[5]</sup> Here, we evaluated an 84-year-old female's VBS stents that "toppled over" before filling completely with cement thus requiring an additional posterior fusion for stabilization.

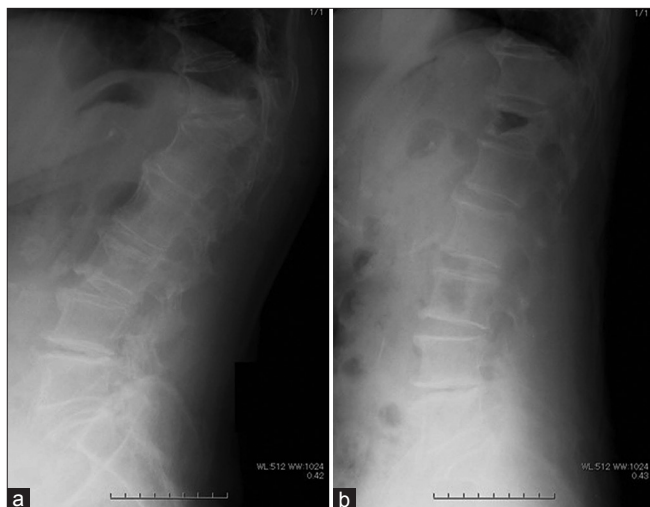## CASE DESCRIPTION

### Clinical presentation

An 84-year-old female presented with low back pain. Standing/decubitus dynamic X-rays revealed a vertebral compression fracture at T12 level accompanied by an intravertebral vacuum cleft (i.e., the lower-most level of diffuse idiopathic skeletal hyperostosis [DISH]) [Figure 1].

This is an open-access article distributed under the terms of the Creative Commons Attribution-Non Commercial-Share Alike 4.0 License, which allows others to remix, transform, and build upon the work non-commercially, as long as the author is credited and the new creations are licensed under the identical terms.

©2023 Published by Scientific Scholar on behalf of Surgical Neurology International



**Figure 1:** X-ray on standing (a) and decubitus position (b) revealed compression fracture at Th 12 with remarkable intravertebral vacuum cleft, which was the lowermost part of diffuse idiopathic skeletal hyperostosis.

A VBS was planned to treat the T12 vertebral compression fracture.

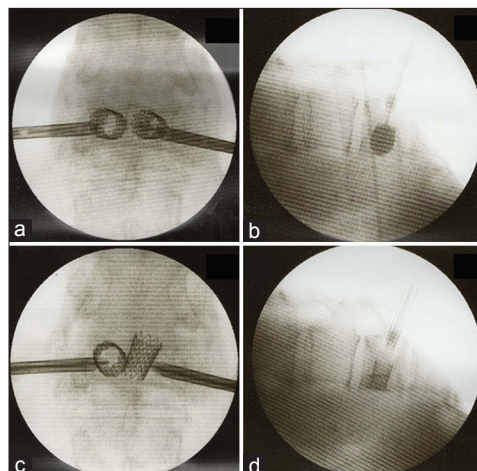
### Surgery

Under fluoroscopic-guidance, the drill and blunt plungers from a vertebral body stent access kit were inserted transpedicularly through working sleeves to create working “channels” for the stents. Inflation catheters were inserted and balloons were expanded until appropriate reduction and/or complete balloon expansion had occurred within the T12 vertebral (i.e., inflation of balloons inside the vertebral body) [Figures 2a and b]. However, the right-sided stent “toppled over” just after removing the balloon catheter, making it impossible to inject an adequate volume (i.e., and to retain) an adequate volume of cement [Figures 2c and d]. The left-sided stent received the requisite cement volume. Therefore, an additional posterior fixation procedure from Th10 to L1 was warranted (i.e., bony fusion to Th11 covered the beaked stent) [Figures 3a and b]. Pedicle screws were removed 1 year postoperatively [Figures 3c and d].

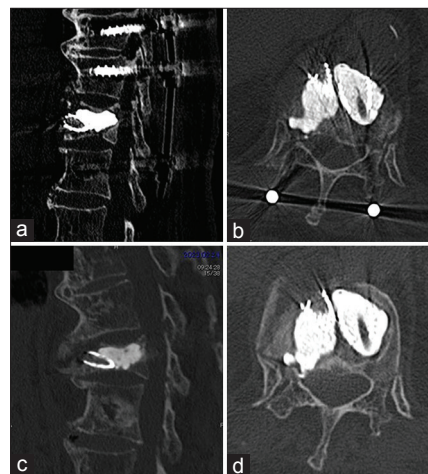
## DISCUSSION

### Stent-related complications

VBS is less able to tolerate errors is versus BKP, especially in the presence of an immobile fracture, and/or a sclerotic zone that may contribute to incomplete stent expansion.<sup>[1]</sup> Furthermore, if two stents interfere with each other, they are not able to “expand sufficiently.”<sup>[3]</sup> Here, an unilateral “tumbling stent,” attributed to insufficient stent expansion occurred, resulted in insufficient filling of the right-sided stent. The left-sided stent was sufficiently filled, but the construct required a secondary posterior instrumented fusion.



**Figure 2:** Balloon was expanded until either appropriate reduction or complete balloon expansion within the vertebral body. The stents were deployed through inflation of the balloon inside the vertebral body, confirming the stability between the endplate and stent (a and b). However, the right side stent toppled over just after removing balloon catheter and it was difficult to inject the cement into the toppled stent (c and d).



**Figure 3:** Vertebral body stenting system and additional posterior fixation was performed at the three levels spanning from Th10 to L1 because the pedicles above Th11 and below L2 were too narrow to insert screws. The stent edge directed toward ventral side (a and b). Bony fusion to Th11 covering beaked stent was achieved and pedicle screws were removed 1 year after operation (c and d).

## CONCLUSION

For VBS, it is not only critical that stent positioning be correct, but that the stent can tolerate expansion following the injection of cement. In this 84-year-old female with a T12

vertebral body fracture and DISH, the inadvertent “tumbling motion” and failure to fill the right-sided stent (i.e., only adequately filled left stent) required a secondary posterior fusion.

#### Declaration of patient consent

The authors certify that they have obtained all appropriate patient consent.

#### Financial support and sponsorship

Nil.

#### Conflicts of interest

There are no conflicts of interest.

#### REFERENCES

1. Diel P, Röder C, Perler G, Vordemvenne T, Scholz M, Kandziora F, *et al.* Radiographic and safety details of vertebral

- body stenting: Results from a multicenter chart review. *BMC Musculoskelet Disord* 2013;14:233.
2. Disch AC, Schmoelz W. Cement augmentation in a thoracolumbar fracture model: Reduction and stability after balloon kyphoplasty versus vertebral body stenting. *Spine (Phila Pa 1976)* 2014;39:E1147-53.
3. Oswald KA, Kälin J, Tinner C, Deml MC, Bigdon SF, Hoppe S, *et al.* Anterior thoracolumbar column reconstruction with the vertebral body stent-safety and efficacy. *Eur Spine J* 2023;32:934-49.
4. Rotter R, Martin H, Fuerderer S, Gabl M, Roeder C, Heini P, *et al.* Vertebral body stenting: A new method for vertebral augmentation versus kyphoplasty. *Eur Spine J* 2010;19:916-23.
5. Werner CM, Osterhoff G, Schlickeiser J, Jenni R, Wanner GA, Ossendorf C, *et al.* Vertebral body stenting versus kyphoplasty for the treatment of osteoporotic vertebral compression fractures: A randomized trial. *J Bone Joint Surg Am* 2013;95:577-84.

**How to cite this article:** Kanematsu R, Hanakita J, Takahashi T, Minami M, Nakamura S, Tokunaga S, *et al.* Intraoperative complications of vertebral body stenting system. *Surg Neurol Int* 2023;14:156.

#### Disclaimer

The views and opinions expressed in this article are those of the authors and do not necessarily reflect the official policy or position of the Journal or its management. The information contained in this article should not be considered to be medical advice; patients should consult their own physicians for advice as to their specific medical needs.