




Since January 2020 Elsevier has created a COVID-19 resource centre with free information in English and Mandarin on the novel coronavirus COVID-19. The COVID-19 resource centre is hosted on Elsevier Connect, the company's public news and information website.

Elsevier hereby grants permission to make all its COVID-19-related research that is available on the COVID-19 resource centre - including this research content - immediately available in PubMed Central and other publicly funded repositories, such as the WHO COVID database with rights for unrestricted research re-use and analyses in any form or by any means with acknowledgement of the original source. These permissions are granted for free by Elsevier for as long as the COVID-19 resource centre remains active.



## Shoulder injury related to vaccine administration (SIRVA) after COVID-19 vaccination

Jessica R. Bass<sup>a</sup>, Gregory A. Poland<sup>b,\*</sup>

<sup>a</sup>NCH Healthcare System, Naples, FL, United States

<sup>b</sup>Mayo Clinic Vaccine Research Group, Mayo Clinic, Rochester, MN, United States



### ARTICLE INFO

#### Article history:

Received 9 February 2022  
Received in revised form 13 May 2022  
Accepted 2 June 2022  
Available online 8 June 2022

#### Keywords:

SARS-CoV-2  
COVID-19  
Vaccine  
Shoulder injury  
SIRVA  
Bursitis  
Tendinopathy

### ABSTRACT

**Objective:** The global fight against COVID-19 has required mass vaccination clinics as well as mass recruitment of personnel, including many who may not regularly administer intramuscular deltoid immunizations, potentially increasing the incidence of improper intramuscular injection. Shoulder injury related to vaccine administration (SIRVA) is a well-described, preventable injury resulting from improper injection into anatomic structures adjacent to the deltoid muscle leading to mechanical and chemical trauma augmented by an inflammatory immune response to the vaccine and/or adjuvants. SIRVA is best described in the setting of influenza vaccination, and little is known about it as it pertains to COVID-19 vaccination. This study aims to describe SIRVA in the current pandemic, increase clinician awareness, and offer considerations for prevention.

**Methods:** To identify clinical characteristics of patients with post-COVID-19-vaccination shoulder injuries, we performed a systematic review of the cases of vaccination-related shoulder injuries reported in the literature and conducted a review of the public Vaccine Adverse Event Reporting System (VAERS). **Results:** We identified 305 cases of SIRVA in the VAERS database and 28 cases of SIRVA in the setting of COVID-19 vaccination from the literature (n = 333). Patients had a mean age of 51.8 years and a median of 51.5 (range: 19–90) years. Of these, 76.3% were female and 23.7% male. Most patients sought medical evaluation with 54 of the 305 VAERS cases reporting utilizing emergency services. Of patients with imaging-confirmed SIRVA (n = 95), the most common diagnoses were adhesive capsulitis and bursitis, and the most common symptoms were pain (97.7%) and limited range of motion (68.1%). Most patients reported requiring treatment with the majority receiving physical therapy (56.3%), followed by cortisone injection (34.4%). Other modalities used were non-steroidal anti-inflammatory drugs, oral steroids, and surgery. Only 5 patients from this group reported recovery while 60 stated they had not yet recovered. Of those, 23.3% reported disability.

**Conclusion:** SIRVA should be regarded as an under-reported, significant cause of post-vaccination morbidity. In the setting of COVID-19 mass vaccination, clinicians must be aware of signs and symptoms of SIRVA as well as appropriate diagnostic modalities and treatment options. Additionally, standardization and proper education regarding injection technique and appropriate needle length is imperative to reducing harm.

© 2022 Elsevier Ltd. All rights reserved.

### 1. Introduction

In the current SARS-CoV-2 era, there has been a race to rollout COVID-19 vaccinations and boosters across the globe at a speed and scale which has never been seen before. This herculean effort to immunize virtually every human on the planet has resulted in pop-up vaccination clinics as well as mass recruitment of person-

nel, including many who may not regularly administer intramuscular (IM) deltoid immunizations. Such mass immunization clinic protocols give little guidance as to injection technique. For example, the BNT162b2 (Pfizer) protocol only states “the vaccine should be administered into the deltoid muscle preferable to the non-dominant arm by an appropriately qualified Good Clinical Practice (GCP)-trained, and vaccine experienced member (e.g., physicians, nurses, physician, assistant, nurse practitioner, pharmacist, or medical assistant)” [1]. Similarly, the m-RNA-1273 SARS-CoV-2 vaccine (Moderna) protocol solely mentions that both doses should not be injected into the same arm, and the Ad26.CO2V.S (Janssen)

\* Corresponding author.

E-mail address: [Poland.gregory@mayo.edu](mailto:Poland.gregory@mayo.edu) (G.A. Poland).

vaccine protocol only states that the vaccine should be given intramuscularly [2,3]. One of the authors (GAP) was immunized by a technician who reported that her only training was watching a 20-minute video. The lack of explicit instructions combined with insufficient training and the exponential increase in inexperienced personnel administering the vaccine has the potential to drastically increase the risk of improper IM injection.

Proper IM injection technique is critical for proper delivery of the vaccine into the well-vascularized muscle as opposed to the less-vascularized subcutaneous tissue or adjacent bursae, tendons, and nerves. The problem is two-fold in that deposition of the vaccine in an under-vascularized area can result in decreased immunogenicity and therefore reduced effectiveness of the vaccine and can lead to pain and complications such as shoulder injury related to vaccine administration (SIRVA) [4].

SIRVA is a broad term encompassing atypical shoulder pain and dysfunction following deltoid IM injection. It is a well-described preventable injury resulting from improper injection technique into anatomic structures adjacent to the deltoid muscle resulting in chemical and/or mechanical trauma which may be augmented by an inflammatory immune response to the vaccine and/or adjuvants. The most commonly reported cause of SIRVA is injection into the bursa which can lead to both subacromial and subdeltoid bursitis as well as adhesive capsulitis. However, rotator cuff tears, chondral injury, septic arthritis, and nerve injuries have all been reported and are included under a diagnosis of SIRVA [5]. In comparison to injection-site tenderness post-vaccination, pain secondary to SIRVA usually begins within 48 h of vaccination and is poorly or unresponsive to over-the-counter medications. A Centers for Disease Control and Prevention report demonstrated that of 859 patients with SIRVA, 65% had pain lasting longer than 1 month, and 25% had pain for >3 months [6]. A systematic review similarly found that 22% of SIRVA patients ultimately required surgery. Limited treatment options are available, though data suggest that early detection and physician-directed treatment limit symptom length, and that there may be a role for early corticosteroid injection [5,7].

While SIRVA is gaining recognition, it is best described in the setting of influenza vaccination. To date, little is known about SIRVA as it pertains to COVID-19 vaccination [6,8]. This study aimed to describe the demographics of patients with SIRVA secondary to COVID-19 vaccination and to assess for commonalities with prior SIRVA data with the ultimate goal of increasing clinician awareness and recognition of the signs and symptoms of SIRVA after COVID-19 vaccination and to offer considerations for prevention.

## 2. Methods

A search was conducted in the publicly available Vaccine Adverse Event Reporting System (VAERS). A query was instigated of the 2021 database current through 9/10/2021 at the time of collection. Vaccination type was matched to symptoms using the VAERS ID. Only COVID-19 vaccinations were included. Simultaneously administered vaccines were excluded. For the purposes of this study, SIRVA was defined as a diagnosis of bursitis, adhesive capsulitis, tendinopathy, or persistent, unilateral shoulder pain, loss of range of motion, stiffness of the joint, atypical sensory changes, or weakness on the side of injection that first occurred within 2 weeks of ipsilateral deltoid IM COVID-19 vaccination and that did not resolve within 48 h. Due to the large increase in knowledge about SIRVA during the COVID-19 pandemic and exponentially higher numbers of self-entered cases on the VAERS database compared with previous years, only cases which had been evaluated by a physician in an attempt to limit diagnostic error. Data were narrowed by symptom search for the terms “bursa,”

“bursitis,” “adhesive capsulitis,” “shoulder injury,” and “SIRVA.” Cases were manually reviewed and excluded if the symptoms resolved within 2 days, or if the injury or dysfunction was systemic or in a joint other than the shoulder or if there was bilateral shoulder involvement, or if there was a history of trauma or dysfunction prior to vaccination. Cases with too few details to come to any diagnostic conclusion were also removed. A subset of data with confirmed testing with a diagnostic modality was then separately analyzed. In an attempt to capture data regarding nerve injuries related to SIRVA, the terms “nerve,” “neuritis,” and “weakness” were initially included but later excluded as these search terms yielded thousands of reports irrelevant to this study and which were unable to be verified by either a physician, testing, or imaging.

Additionally, a search of PubMed, OvidSP MEDLINE, Web of Science, Google Scholar, and the World Health Organization Global Research on Coronavirus Disease (COVID-19) database for articles published in the literature involving COVID-19 vaccine-associated shoulder injury was conducted on April 20, 2022 using the following search strategy (COVID-19 OR SARS-CoV-2) AND (immunization OR vaccine) AND (“shoulder injury” OR bursitis OR “adhesive capsulitis” OR SIRVA) published in English between 2020 and 2022. Only case reports and case series were included. The same exclusion criteria listed above was applied. Case reports were cross-referenced with the VAERS database and duplicates were excluded.

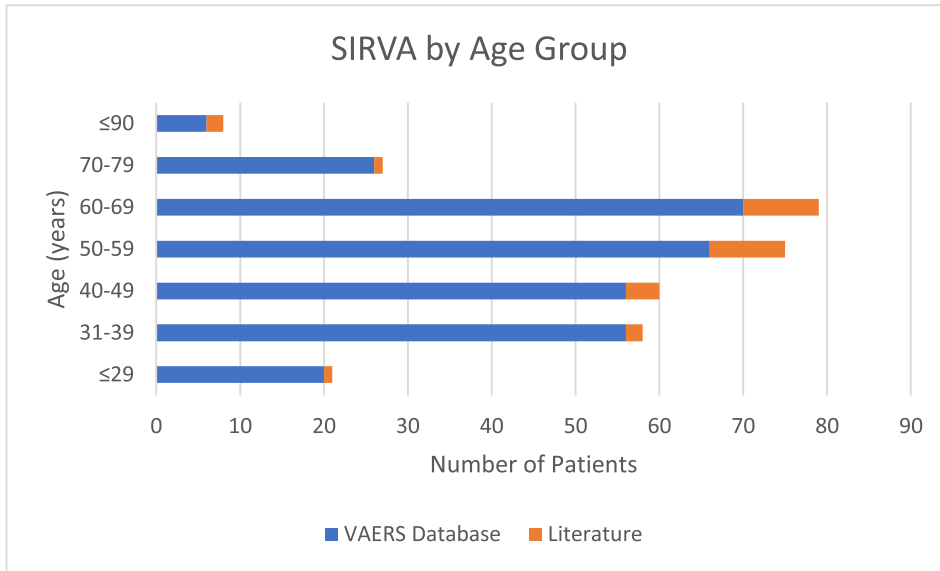
## 3. Results

Between 1/1/2021 and 9/10/2021, 545,110 adverse events related to COVID-19 vaccination were reported in VAERS. A search of the above terms resulted in 621 entries, of which 476 met our study definition of SIRVA. Of these, 306 had a confirmed diagnosis of SIRVA after evaluation by a physician with 281 individuals having seen a physician in the office, 54 in the ER, with 29 being seen in both settings.

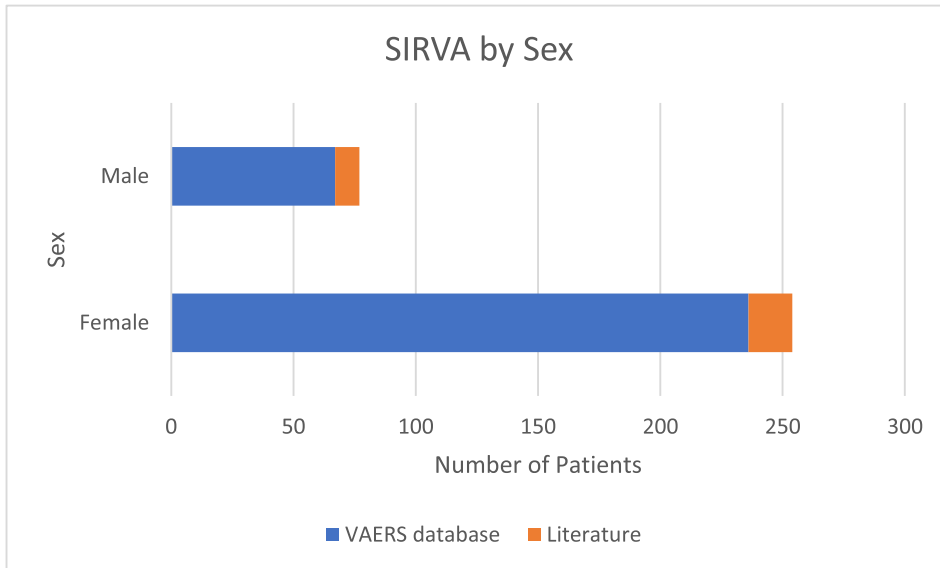
Based on the systematic literature review, 18 case reports and series published in the medical literature were found, of which 3 were excluded. One was excluded as it related to COVID-19 disease rather than vaccination, and 2 were excluded as they pertained to systemic illness post-vaccination. Twelve individual case reports and 3 case series, totaling 32 clinical vignettes, were deemed to meet the study criteria and were selected for complete reading. Of these, two were duplicate patients included both as part of a series and as an individual case report [13,16,22]. One patient in a series was excluded as they had only subcutaneous reactions which is out of the scope of this paper. Two case reports appear to regard the same patient [9,18]. One patient from the literature was also found in the VAERS database. For subgroup purposes, that patient is counted in the cases from the literature [9]. In total, 28 patients were included from literature [9–23].

The results from the VAERS data in addition to the 28 cases noted above resulted in a case series (n = 333) of SIRVA related to COVID-19 vaccination. All the patients were adults with a mean age of 51.8 years and a median of 51.5 with a range of 19–90 years. Of these, 76.3% were female and 23.7% male [Fig. 1]. The mean and median for the VAERS data were 51.5 and 51 respectively (range: 19–90 years) with 74.3% female and 25.7% male. For the cases found by systematic review, the mean and median were 55.8 and 55 respectively (age range: 26–84 years) with 64.2% female and 35.7% male (Fig. 1a-b).

All the patients included in these reports received a vaccine for COVID-19 with 123 subjects (40.3%) from the VAERS data reporting receiving Pfizer vaccine, 152 (49.8%) reporting receipt of Moderna vaccine, and 30 (9.9%) the Janssen vaccine. Of the systematic



a



b

**Fig. 1.** a: Age distribution of patients with SIRVA from both the VAERS database and literature review. b: Sex distribution of patients with SIRVA from both the VAERS database and literature review.

review cases, 82% of which occurred outside of the United States, 19 patients received the Oxford-AstraZeneca vaccine, 1 received the Sinovac vaccine, and 1 received the Bharat Biotech vaccine. Seven patients received mRNA vaccines with 3 receiving Pfizer, 3 receiving Moderna, and 1 not specifying further. Of the 282 patients who received an mRNA COVID-19, 62 commented on whether SIRVA occurred after their first or second dose. Thirty-one individuals (50%) received a diagnosis of SIRVA after their first dose while 31 (50%) reported SIRVA after their second dose. Of those who developed SIRVA after their first dose, 13 reported completing the series with none of them reporting further complications after their second dose.

In the VAERS group, 67 subjects explicitly stated that they felt their vaccine was administered too high, as did 6 subjects from the literature review. Geographic site of vaccination was reported by 87% of cases and was highly varied, with 25.5% selecting that

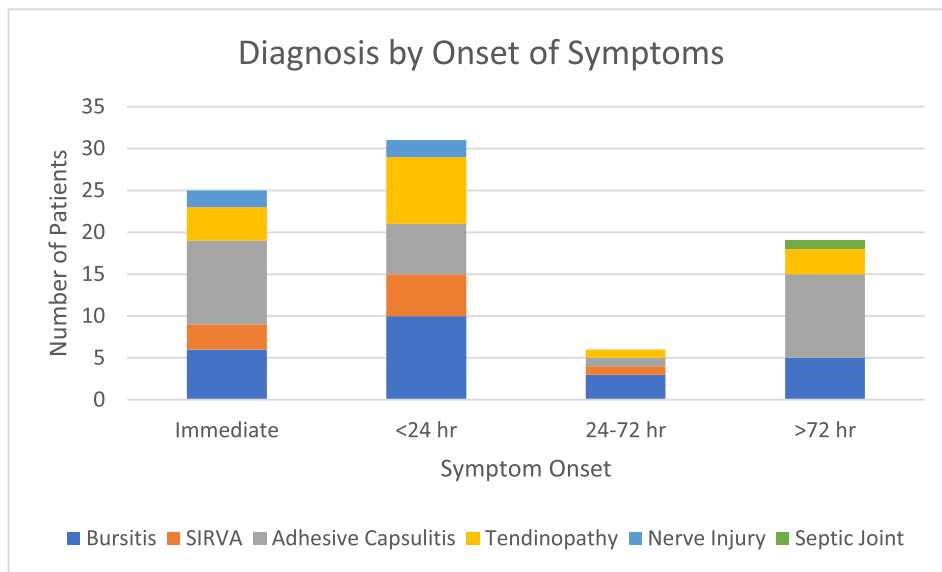
they received their vaccination in a private setting, 22.9% in a pharmacy, 13.1% in a public setting, 4.6% at work, 2.9% in a military location, 1.3% at a school, 0.7% at a senior center, and 16.0% only reporting “other” without further delineation. Of the 305 VAERS reports, 22 subjects had recovered at the time of reporting (7.2%) with 234 subjects reporting that they had not yet recovered (76.5%). Of those who had not recovered, 37 subjects (15.8%) reported being disabled as a result of their injuries. The status of an additional 49 patients was not reported. At the time of reporting, 7.5% of patients underwent invasive treatment with 23 receiving corticosteroid injection while 1 underwent surgical debridement secondary to septic arthritis.

For the sake of diagnostic accuracy, cases without diagnostic confirmation of SIRVA via either shoulder ultrasound (US) or MRI completed at the time of reporting were excluded for this subgroup analysis. In total, 68 patients from VAERS data and 27 cases from

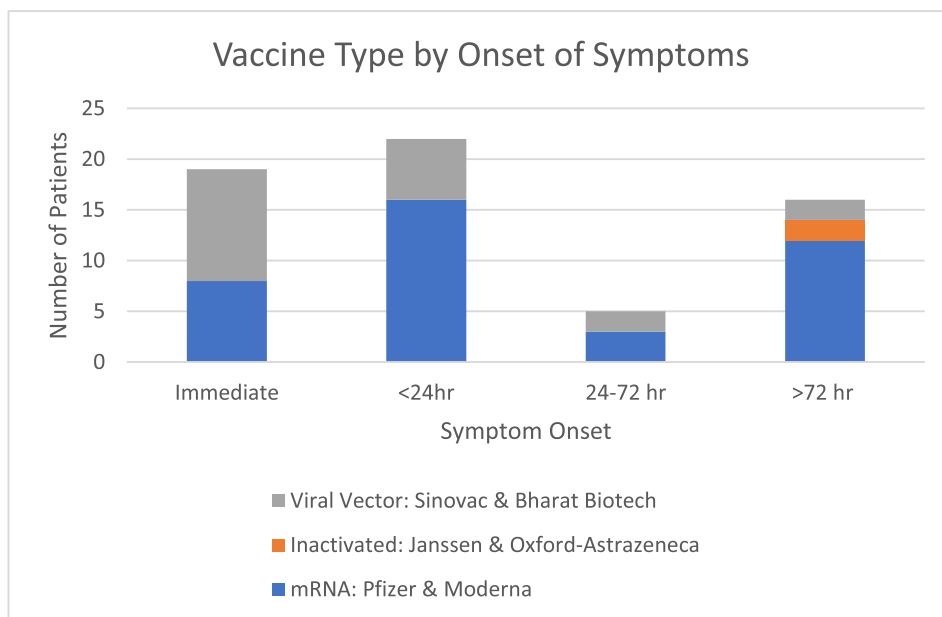
the literature were included (n = 95). Females comprised 73.6% of the group and males 26.3%. The age range was 23–86 years and the mean was 53.5 years with a median of 52.5. Imaging revealed the following: bursitis (n = 33), adhesive capsulitis (n = 36), tendinopathy (n = 19), SIRVA otherwise unspecified (n = 24), nerve injury (n = 4), septic arthritis (n = 1). Of these, 18 subjects had multiple pathologies diagnosed including bursitis and adhesive capsulitis (n = 2), bursitis and tendinopathy (n = 10), adhesive capsulitis and tendinopathy (n = 2), adhesive capsulitis and nerve injury (n = 1), bursitis, adhesive capsulitis, and tendinopathy (n = 1), bursitis and nerve injury (n = 1), and a combination of bursitis, tendinopathy, and septic arthritis (n = 1) (Fig. 2).

Sixty-two patients commented on the onset of their symptoms in relation to vaccine administration, with 19 patients reporting

immediate onset, 22 patients reporting onset within 24 h, 5 patients reporting onset between 24 and 72 h, and 16 patients reporting onset over days to weeks (Fig. 2a,b). Eighty-eight reports commented on symptoms. Shoulder pain (n = 86) and limited range of motion (ROM) (n = 60) were the most common symptoms reported, followed by stiffness (n = 18), altered sensation (n = 7), and weakness (n = 4). Sixty-nine patients had multiple symptoms. The most common diagnostic modality was X-ray (n = 49), followed by MRI (n = 47), US (n = 19), and CT (n = 3) with 29 individuals reporting multiple studies. Treatment was reported by 64 patients with 44 patients receiving more than one modality of treatment. Physical therapy was the most common (n = 36), followed by cortisone injection (n = 22), non-steroidal anti-inflammatory drugs (NSAIDs) (n = 19), oral steroids (n = 13), and



a



b

Fig. 2. a: Diagnosis by Onset of Symptoms b: Vaccine type by onset of symptoms.

surgery (n = 2) (Table 1). Only 5 patients in this group reported recovery while 60 patients reported that they had not yet recovered. Of those who reported not yet recovering, 14 patients (23.3%) reported disability.

**4. Discussion**

To our knowledge, this is the first large-scale review of reports of SIRVA after COVID-19 vaccination. Compared with previous systematic reviews of SIRVA, SIRVA in the setting of COVID-19 vaccination was similarly female predominant with approximately 76% of cases being female and 24% male with a median age of 51.5 compared to 73% female, 24% male with a median age of 51 [8]. Symptoms were also consistent with prior studies with pain and limited range of motion being the most common. Prior studies of other vaccinations suggest onset is typically within the first 48 h [5,6,8,24]. In our study, >65% of patients had symptom onset within the first 24 h. However, there were a significantly larger group of patients that had insidious onset of shoulder pain between 72 h and 2 weeks in comparison. Previous studies have suggested rotator cuff tendinopathy and bursa injury as the most common manifestations of SIRVA. However, adhesive capsulitis was the most common finding in our study, followed by bursitis, tendinopathy, nerve injury, and infection [6,8]. The comparative delay in symptom onset and increase in adhesive capsulitis is better visualized in Fig. 2, which shows that the majority of cases in the > 72-hour timeframe were cases of adhesive capsulitis. While this could be incidental, Fig. 2b suggests a similar bimodal distribution within the mRNA vaccine group. This could suggest an immune-mediated phenomenon specific to COVID-19 vaccination, however further research is needed before any such statement can be made with statistical significance. There was also significant healthcare utilization among those with signs and symptoms of SIRVA. Most sought medical evaluation with 54 of the 333 VAERS cases reporting utilizing emergency services. Though many diagnoses were made based on history and clinical exam, 95 underwent diagnostic imaging. X-Ray was the most-utilized modality, followed by MRI. X-ray appeared to be of limited diagnostic benefit

in this patient group as has been similarly noted in prior studies [8].

Invasive testing and treatments such as cortisone injection and surgery were not uncommon. Previous literature has shown that up to 22% of cases ultimately require surgery [5]. At the time of reporting, only 2 patients in the subgroup analysis had undergone surgery, one for septic arthritis and the other for hemorrhagic bursitis [9,14]. No VAERS cases had undergone surgery at the time of reporting. However, this number is likely largely underrepresented due to the limitations of VAERS as it provides only a single snapshot in time.

In this data set, only one person commented on their COVID-19 status, stating that they contracted COVID-19. The patient was a 52-year-old female who received the Moderna vaccine and who had a diagnosis of shoulder bursitis as a result of intra-bursal injection. A second person who had the same issue of intra-bursal injection also asks the question of whether they need a 3rd booster. While scattered narratives are far from scientific, this highlights an important gap in our scientific knowledge as little is known about the immunogenicity of mRNA vaccines in the setting of inadequate IM penetration. Proper IM vaccine administration ensures adequate exposure of vaccine antigen to a blood-rich area while simultaneously avoiding harm. Overpenetration has been implicated as the largest contributing factor to development of SIRVA, though correct technique also plays an important role [5].

The subdeltoid bursa is located between 0.8 cm and 1.6 cm below the skin surface, a distance easily penetrable by the standard 1-inch (25 mm) needle [25]. It is well-documented in the literature that a one-size-fits-all approach should not be uniformly applied to all adult deltoid IM vaccinations [26–28]. Important characteristics to consider when selecting needle length are sex, age, and weight as females are known to have smaller muscle mass and increased delta fat pad thickness when compared with men, increasing the risk for injury [26]. This is likely why women consistently experience SIRVA more often than men. Therefore, guidelines for proper needle length selection are based on sex and weight (Table 2) [26,29].

In this data set, only one case from VAERS reported needle length and weight of the patient (a 1-inch (25 mm) needle in a

**Table 1**  
Clinical characteristics of patients with imaging-confirmed SIRVA (n = 95).

<b>Demographics:</b>			
<b>Gender:</b>	Female (n = 69) 73.6%	Male (n = 26) 26.3%	Total (n = 95)
<b>Age (years):</b>	Mean: 53.5	Median: 52.5	Range: 23–86
<b>Vaccination Data:</b>			
<b>Vaccine (n = 95):</b>	Moderna: (n = 38) 40.0% Sinovac: (n = 1) 1.1% mRNA unspecified: (n = 1) 1.1%	Pfizer: (n = 29) 30.5% Oxford-astrazeneca: (n = 18) 18.9%	Janssen: (n = 7) 7.4% Bharat Biotech: (n = 1) 1.1%
<b>Site (n = 62):</b>	Private: (n = 20) 32.3% School: (n = 2) 3.2% Military: (n = 4) 6.5%	Public: (n = 6) 9.7% Work: (n = 5) 8.1%	Other: (n = 14) 22.6% Pharmacy: (n = 10) 16.1%
<b>Objective Data:</b>			
<b>Diagnosis:</b>	Bursitis: 34.7% Nerve injury: 4.2%	Adhesive Capsulitis: 37.9% Septic joint: 1.1%	Tendinopathy: 20% SIRVA otherwise unspecified: 25.3%
<b>Clinical Data:</b>			
<b>Symptom Onset: (n = 62)</b>	Immediate: 30.6% >72 h to 2 weeks: 25.8%	<24 h: 35.5%	24–72 h: 8.1%
<b>Signs and Symptoms: (n = 88)</b>	Pain: 97.7% Stiffness: 20.5%	Limited ROM: 68.1% Weakness: 4.5%	Altered sensation: 8.0% Multiple: 78.4%
<b>Diagnostic Tests: (n = 95)</b>	X-Ray: 51.5% US 20.0%	MRI: 49.5%	CT: 3.2% Multiple: 30.5%
<b>Treatments: (n = 64)</b>	Physical Therapy: 56.3% Oral Steroids: 20.3%	Cortisone Injection: 34.4% Surgery 3.1%	NSAIDs: 29.7% Multiple: 45.3%

**Table 2**  
Guidelines for needle-length selection based on sex and weight [11,12].

Needle Length	Male	Female
16-mm (5/8-inch)	<60 kg	<60 kg
25-mm (1-inch)	60–70 kg	60–70 kg
25-mm or 38-mm (1 or 1.5-inch) *	70–118 kg	70–90 kg
38 mm (1.5-inch)	>118 kg	>90 kg

\*Best judgement should be used depending on patient's anatomy.

Note: Adapted from "Shoulder Injury Related to Vaccine Administration and Other Injection Site Events," by A. Bancsi, S. Houle, and K. Grindrod, 2019, *Canadian family physician Medecin de famille canadien*, 65(1), 40–42. Copyright by the College of Family Physicians of Canada.

59 kg female patient). Similarly, a case in the literature describes a 1-inch needle in a 58 kg female patient [20]. Assuming proper injection technique was otherwise used, a 16 mm needle should have been selected in each of these cases, based on guidelines [26,29–31]. An additional VAERS case did not explicitly state needle length but did comment that the patient was a female weighing 108 lb (49.1 kg) and that the needle was too long. A report from the literature reported only needle length, stating that a 1.5-inch (38 mm) needle was used in a non-obese female, though weight was not reported [25]. Based on the images given, a more appropriate choice would likely have been the 25-mm needle.

Proper technique is likewise an important factor in the avoidance of SIRVA. An injection that is too high risks injecting the subacromial bursa, injections placed too low can reach the radial nerve, and too laterally risks injury to the axillary nerve [29]. In this data set, 73 patients in total explicitly stated that they felt their injection was "too high [25,26]." This suggests that understanding and using proper landmarking continues to play a significant role in the development of SIRVA in the setting of COVID-19 vaccination. The safest anatomical site for deltoid intramuscular injection in adults is midway between the acromion and deltoid tuberosity [32]. However, as the deltoid tuberosity is not a readily palpable landmark, proper landmarking can be obtained by having the patient's arm hang relaxed at their side, marking the central point between 3 fingerbreadths below the acromion process (2 if large fingers) and above the anterior axillary line with your index finger and thumb, and holding the needle at a 90-degree angle and administering the vaccine without "bunching" the skin. [29]. An additional safety measure to decrease the exposure of the subacromial bursa can be achieved by abducting the shoulder to 60 degrees by having the patient place their hand on their hip [32]. Of the 28 case reports from the literature, 2 had pictures of the patient receiving their vaccination. Neither case used the shoulder abduction technique and one demonstrated inappropriate angling of the needle [12]. Skin bunching is another technique frequently used in an attempt to reduce overpenetration. However, this is not recommended as it has been shown that this technique can result in under-penetration of the deltoid muscle, particularly in patients with a BMI > 30, and result in a non-IM injection [33].

While VAERS has gained attention and awareness since the onset of the pandemic, it remains likely that large numbers of cases are likely unreported. For example, one of the authors (GAP) is personally aware of multiple cases that had been reported to VAERS, and which included 2 likely nerve injuries (by history). In addition to the known errors with passive safety reporting systems, the reporting format of VAERS makes it difficult to analyze large volumes of data without a large burden of manual review as many of the data fields allow for free-text data entry and others are open to interpretation such as the geographical vaccination site. For example, while the options of "pharmacy," "military," and "school" are fairly clear-cut, the terms "public," "private," "work," and "other" lack formal definition and specificity. For example, one patient explicitly stated that they received their vaccine at a drive-thru clinic, but on the loca-

tion, they marked "private," whereas others may feel that is better categorized as "public" or "other." This made it impossible to determine whether patients were at an increased risk of developing SIRVA after vaccination at a pop-up vaccination site in comparison to a site where vaccines are typically given. An additional issue encountered was that, in many cases, discrete data such as patient age, sex, and physician visits were erroneously entered into the free-text "symptoms" box including patient age, sex, symptoms, physician visits, and tests performed, rendering these cases incomplete and therefore excluded when data analysis was performed. Cases with signs and symptoms consistent with SIRVA but without physician evaluation and confirmation at the time of reporting were also excluded. Our study also likely underestimates the numbers of neurologic injuries sustained secondary to SIRVA as the search terms were designed for injuries which can be objectively measured in an attempt to decrease the bias from self-reporting. The intention of this study is to describe SIRVA in the setting of COVID-19 vaccination, increase clinician awareness, and offer techniques for prevention. Due to the aforementioned limitations, it is not designed to report the incidence of SIRVA in the setting of COVID-19 vaccination.

## 5. Conclusion

As mass-scale vaccination continues, especially as additional booster doses are approved, cases of SIRVA should not be ignored as it can result in significant morbidity as reported by the number of patients reporting disability, increased healthcare utilization and costs in an already strained system and deter people from receiving necessary vaccinations while also potentially decreasing effectiveness of the vaccine. A standardized procedure, training, and direct observation by qualified instructors for all vaccination centers is crucial. All vaccination centers should ensure that they have adequate supplies of 16-mm, 25-mm, and 38-mm needles appropriate for deltoid IM injection. Scales should be available for determining weight and needle length with charts readily available to guide personnel. Additionally, all personnel should be utilizing appropriate injection technique such as abducting the shoulder to 60 degrees, using their thumb and forefinger to identify the muscle, avoiding skin-bunching techniques, and injecting at 90 degrees. Furthermore, clinicians should be aware of the signs and symptoms of SIRVA and utilize appropriate imaging modalities such as US and MRI when necessary. Early treatment with NSAIDs, PT, and consideration of glucocorticoid injection is warranted and has been shown to improve recovery [5,7].

## Disclosures

Dr. Poland is the chair of a Safety Evaluation Committee for novel investigational vaccine trials being conducted by Merck Research Laboratories. Dr. Poland provides consultative advice on vaccine development to Merck & Co., Medicago, GlaxoSmithKline, Valneva, Johnson & Johnson/Janssen Global Services LLC, Emergent Biosolutions, Dynavax, Genentech, Eli Lilly and Company, Kentucky Bioscience, Bavarian Nordic, AstraZeneca, Exelixis, Regeneron, Vyriad, Moderna, Novavax, Medicago, Affinivax, Parexel, and Genvant Sciences, Inc. Dr. Poland holds patents related to vaccinia, influenza, and measles peptide vaccines. Dr. Poland has received grant funding from ICW Ventures for preclinical studies on a peptide-based COVID-19 vaccine. This research has been reviewed by the Mayo Clinic Conflict of Interest Review Board and was conducted in compliance with Mayo Clinic Conflict of Interest policies.

These activities have been reviewed by the Mayo Clinic Conflict of Interest Review Board and are conducted in compliance with Mayo Clinic Conflict of Interest policies.

© 2022 Mayo Foundation for Medical Education and Research.

**Declaration of Competing Interest**

The authors declare that they have no known competing financial interests or personal relationships that could have appeared to influence the work reported in this paper.

**Appendix 1. VAERS IDs utilized in this study**

919310	1052636	1171079	1296348	1400424	1513194
919440	1053573	1171925	1300368	1400428	1516357
922206	1053984	1172687	1304101	1400428	1521978
926909	1059945	1173388	1304406	1405831	1523395
928425	1062643	1173687	1307201	1406275	1523475
928580	1073894	1181610	1310531	1409508	1526753
932189	1073956	1184604	1311468	1410718	1526758
933101	1076806	1184976	1313662	1414064	1534731
933625	1078990	1186326	1314900	1419017	1536360
935571	1089156	1190398	1320656	1420393	1536360
938301	1091401	1195556	1320925	1423696	1551408
944050	1091755	1197098	1320940	1423767	1558204
945132	1093589	1197108	1322910	1423863	1558303
947248	1093752	1204374	1323449	1429458	1561659
947705	1099333	1204400	1324765	1429773	1570504
948245	1101746	1206140	1327286	1430438	1573908
956312	1103050	1207801	1328230	1431086	1579756
958094	1104136	1208387	1333294	1432362	1582461
961383	1109662	1210563	1333847	1433627	1583039
964609	1109957	1212792	1336546	1433812	1587398
966895	1110496	1213463	1336713	1440643	1594331
967159	1117527	1216069	1341100	1443148	1603569
968794	1118654	1216391	1342990	1446455	1604495
974297	1119140	1216391	1343096	1450596	1607210
984959	1119821	1216758	1346404	1450596	1617473
987541	1119821	1218907	1346959	1457424	1617703
988194	1120110	1219552	1352129	1459700	1627302
990908	1120592	1228796	1355111	1460037	1628347
995561	1120853	1230857	1355382	1461734	1628722
996269	1122236	1232534	1355594	1466912	1628858
998941	1123866	1232562	1357994	1467018	1633766
1006372	1124324	1233185	1358283	1467738	1634198
1008015	1124668	1243041	1361624	1469948	1637401
1018521	1125926	1243090	1364484	1471071	1641161
1019651	1129956	1247499	1364579	1474445	1649125
1020946	1129956	1248295	1367903	1474515	1650952
1021047	1131497	1251344	1368214	1474610	1653897
1022941	1134604	1258862	1374336	1474999	1655736
1024471	1136498	1259557	1375096	1481646	1660120
1025373	1141348	1259571	1382573	1481672	1660126
1028011	1141903	1261718	1385979	1482039	1662826
1028370	1143964	1267291	1386080	1484567	1665990
1029426	1144303	1271583	1386148	1484762	1670750
1031532	1144736	1271963	1386184	1484771	1673041
1036059	1151511	1274952	1388330	1485204	1673190
1036189	1155612	1285534	1390329	1495707	1674752
1038851	1156143	1289646	1394386	1498133	1678546
1040711	1159914	1289815	1394823	1500872	1682031
1042332	1160519	1289994	1399243	1501216	1682620
1042415	1168064	1292710	1399507	1501334	1684348

**References**

- [1] Polack FP, T. S. (2020). Protocol. Retrieved from safety and efficacy of the BNT162b2 mRNA Covid-19 vaccine N Engl J Med: [https://www.nejm.org/doi/suppl/10.1056/NEJMoa2034577/suppl\\_file/nejmoa2034577\\_protocol.pdf](https://www.nejm.org/doi/suppl/10.1056/NEJMoa2034577/suppl_file/nejmoa2034577_protocol.pdf)
- [2] Baden LR, E. S. (2021). Protocol. Retrieved from efficacy and safety of the mRNA-1273 SARS-CoV-2 vaccine N Engl J Med: [https://www.nejm.org/doi/suppl/10.1056/NEJMoa2035389/suppl\\_file/nejmoa2035389\\_protocol.pdf](https://www.nejm.org/doi/suppl/10.1056/NEJMoa2035389/suppl_file/nejmoa2035389_protocol.pdf)
- [3] Sadoff J, Gray G, Et Al. Safety and Efficacy of Single-Dose Ad26.COV2.S Vaccine and Caovid-19.
- [4] Edelman R, Deming ME, Toapanta FR, Heuser MD, Chrisley L, Barnes RS, et al. The SENIEUR protocol and the efficacy of hepatitis B vaccination in healthy elderly persons by age, gender, and vaccine route. *Immunity and Ageing*. 2020;17(1).
- [5] Cagle Jr PJ. Shoulder Injury after Vaccination: a Systematic Review. *Rev Bras Ortop* (Sao Paulo). 2021;56(3):299–306. <https://doi.org/10.1055/s-0040-1719086>.
- [6] Hibbs BF, Ng CS, Museru O, Moro PL, Marquez P, Woo EJ, et al. Reports of atypical shoulder pain and dysfunction following inactivated influenza vaccine, Vaccine Adverse Event Reporting System (VAERS), 2010–2017. *Vaccine*. 2020;38(5):1137–43.
- [7] Macomb CV, Evans MO, Dockstader JE, Montgomery JR, Beakes DE. Treating SIRVA Early With Corticosteroid Injections: A Case Series [published correction appears in *Mil Med*. 2020 Feb 12;185(1–2):e325. Dockstader, Jo E [corrected to Dockstader, Jo E]]. *Mil Med*. 2020;185(1–2):e298–e300. doi:10.1093/milmed/usz269
- [8] Martín Arias LH, Sanz Fadrique R, Sáinz Gil M, Salgueiro-Vazquez ME. Risk of bursitis and other injuries and dysfunctions of the shoulder following vaccinations. *Vaccine*. 2017;35(37):4870–6. <https://doi.org/10.1016/j.vaccine.2017.07.055>.
- [9] Flowers RC, Rivera Rodriguez B, Corbitt K. *Streptococcus gordonii* septic arthritis of the glenohumeral joint following deltoid intramuscular vaccination. *BMJ Case Rep*. 2021;14(5):e243066. Published 2021 May 25. doi:10.1136/bcr-2021-243066
- [10] Boonsri P, Chuaychoosakoon C. Combined subacromial-subdeltoid bursitis and supraspinatus tear following a COVID-19 vaccination: a case report. *Annals of Medicine and Surgery* 2021;69:102819.
- [11] Cantarelli Rodrigues T, Hidalgo PF, Skaf AY, Serfaty A. Subacromial-subdeltoid bursitis following COVID-19 vaccination: a case of shoulder injury related to vaccine administration (SIRVA). *Skeletal Radiol* 2021;50(11):2293–7.
- [12] Chuaychoosakoon C, Parinyakump W, Tanutit P, Maliwankul K, Klabklay P. Shoulder injury related to Sinovac COVID-19 vaccine: a case report. *Annals of Medicine and Surgery* 2021;68:102622.
- [13] Massel DH, Haziza S, Rivera S, Mohile N, Subhawong TK, Hernandez VH. Septic Arthritis of the Shoulder After SARS-CoV-2 Pfizer Vaccination. *JBJS Case Connector* 2021;11(3). <https://doi.org/10.2106/JBJS.CC.21.00090>.
- [14] Mayer EN, Gajewski CR, Bernthal NM, et al. Arthroscopic debridement for acute hemorrhagic subacromial bursitis following COVID-19 vaccine administration: a case report. *Shoulder & Elbow* 2022;1–7.
- [15] Klabklay P, Boonsri P, Kanyakool P, Chuaychoosakoon C. A COVID-19 vaccination precipitating symptomatic calcific tendinitis: a case report. *Ann Med Surg* (Lond). 2022;74:. <https://doi.org/10.1016/j.amsu.2022.103347>103347.
- [16] Nakajima K, Miyata A, Kato S, et al. Calcific Tendinitis of the Shoulder Induced by mRNA Vaccine for COVID-19. A Case Report. *Modern Rheumatology Case Reports* 2022;rxac006. <https://doi.org/10.1093/mrcr/rxac006>.
- [17] Maliwankul K, Boonsri P, Klabklay P, Chuaychoosakoon C. Shoulder Injury Related to COVID-19 Vaccine Administration: a Case Series. *Vaccines*. 2022;10(4):588. <https://doi.org/10.3390/vaccines10040588>.
- [18] Yuen WLP, Loh SYJ, Wang DB. SIRVA (Shoulder Injury Related to Vaccine Administration) following mRNA COVID-19 Vaccination: case discussion and literature review. *Vaccine*. 2022;40(18):2546–50. <https://doi.org/10.1016/j.vaccine.2022.03.037>.
- [19] Chow JCK, Koles SL, Bois AJ. Shoulder injury related to SARS-CoV-2 vaccine administration. *CMAJ* 2022;194(2):E46–9. <https://doi.org/10.1503/cmaj.211162>.
- [20] Aldosary AH. Prolonged shoulder dysfunction after coronavirus disease vaccination: A case of shoulder injury related to vaccine administration. *SAGE Open Medical Case Reports*. January 2022. doi:10.1177/2050313X221089494
- [21] Sahu D, Shetty G. Frozen shoulder after COVID-19 vaccination [published online ahead of print, 2022 Mar 18]. *JSES Int*. 2022. <https://doi.org/10.1016/j.jseint.2022.02.013>.
- [22] Wharton BR, Doan KC, Wolcott ML. Shoulder injury related to COVID-19 vaccine administration: a case report. *JSES Reviews, Reports, and Techniques* 2022;2(2):178–81.
- [23] Honarmand AR, Mackey J, Hayeri R. Shoulder injury related to vaccine administration (SIRVA) following mRNA COVID-19 vaccination: report of 2 cases of subacromial-subdeltoid bursitis. *Radiol Case Rep*. 2021 Dec;16(12):3631–4. <https://doi.org/10.1016/j.radcr.2021.08.019>.



- [24] Atanasoff S, Ryan T, Lightfoot R, Johann-Liang R. Shoulder injury related to vaccine administration (SIRVA). *Vaccine*. 2010;28(51):8049–52. <https://doi.org/10.1016/j.vaccine.2010.10.005>.
- [25] Bodor M, Montalvo E. Vaccination-related shoulder dysfunction. *Vaccine*. 2007;25(4):585–7. <https://doi.org/10.1016/j.vaccine.2006.08.034>.
- [26] Poland GA, Borrud A, Jacobson RM, et al. Determination of deltoid fat pad thickness. implications for needle length in adult immunization. *JAMA* 1997;277(21):1709–11.
- [27] Cook IF, Williamson M, Pond D. Definition of needle length required for intramuscular deltoid injection in elderly adults: an ultrasonographic study. *Vaccine*. 2006;24(7):937–40. <https://doi.org/10.1016/j.vaccine.2005.08.098>.
- [28] Shankar N, Saxena D, Lokkur PP, Kumar NM, William NC, Vijaykumar N. Influence of skin-to-muscle and muscle-to-bone thickness on depth of needle penetration in adults at the deltoid intramuscular injection site. *Med J Armed Forces India*. 2014;70(4):338–43. <https://doi.org/10.1016/j.mjafi.2014.08.005>.
- [29] Bancsi A, Houle S, Grindrod KA. Shoulder injury related to vaccine administration and other injection site events. *Can Fam Physician/MeDecin de famille canadien* 2019;65(1):40–2.
- [30] Public Health Agency of Canada. Canadian immunization guide. Vaccine administration practices. Table 3: needle selection guidelines. Ottawa, ON: Government of Canada; 2017. Available from: <https://www.canada.ca/en/public-health/services/publications/healthy-living/canadian-immunization-guide-part-1-key-immunization-information/page-8-vaccine-administration-practices.html#t3>. Accessed April 20, 2022.
- [31] ACIP Vaccine Administration Guidelines for Immunization. Centers for Disease Control and Prevention. <https://www.cdc.gov/vaccines/hcp/acip-recs/general-recs/administration.html#ref17>. Published April 14, 2022. Accessed April 20, 2022.
- [32] Behrens RH, Patel V. Avoiding shoulder injury from intramuscular vaccines. *Lancet (London, England)* 2021;397(10273):471. [https://doi.org/10.1016/S0140-6736\(21\)00192-6](https://doi.org/10.1016/S0140-6736(21)00192-6).
- [33] Rahamimov N, Baturov V, Shani A, Ben Zoor I, Fischer D, Chernihovsky A. Inadequate deltoid muscle penetration and concerns of improper COVID mRNA vaccine administration can be avoided by injection technique modification. *Vaccine* 2021;39(37):5326–30. <https://doi.org/10.1016/j.vaccine.2021.06.081>.