

Inflammation and infection

Emphysematous pyelonephritis with successful renal preservation using open drainage surgery: A case report

Taiki Hayashi*, Hitoshi Yanaihara, Hirofumi Kaguyama, Fuminari Hanashima, Hirofumi Sakamoto, Yoko Nakahira, Hirotaka Asakura

Saitama Medical University Hospital, Saitama, Japan



ARTICLE INFO

Article history:

Received 9 October 2017

Accepted 21 November 2017

Available online 28 January 2018

Introduction

Emphysematous pyelonephritis (EPN) is a rare urinary tract infection that is observed the production of gas inside and outside the kidney.

Although there has been the development of antibiotics, there are some cases of EPN that have become serious. Therefore, this disease requires accurate and prompt treatment.

Currently, the initial treatment for EPN consists of combination therapy with antibiotics along with percutaneous drainage (PCD). When PCD offers poor infection control, nephrectomy may be necessary. However, if the patient's general health condition is poor, or if renal dysfunction is observed, nephrectomy may not be considered.

Here we report on case of EPN which could be preserved renal, by open drainage surgery.

Case report

A 60-year-old Japanese female presented to another hospital with a 3-day history of high fever and disturbance of consciousness. She was diagnosed with left EPN and underwent percutaneous nephrostomy. She was started on antibiotics. Subsequently, she was referred to our institution because of poor infection control. Her medical history revealed poorly controlled diabetes mellitus and untreated breast cancer. On presentation, her vital signs were as follows: body temperature, 37.7 °C; heart rate, 101 beats/min; and

blood pressure, 128/90 mmHg.

Relevant laboratory parameters were as follows; creatinine level, 2.24mg/dl; white blood cell count, 10,890 cells/ μ L with 86.5% segmented neutrophils; haemoglobin level, 7.6 mg/dl; haematocrit, 22.5%; platelet count, 25,000/ μ L; sodium level, 140 mEq/L; chloride level, 102 mEq/L; potassium level, 4.1 mEq/L; uric acid level, 10.6 mg/dl; albumin level, 1.7 g/dl; lactate dehydrogenase level, 305 U/L and haemoglobin A1c level, 9.3%.

Abdominal computed tomography (CT) revealed abscess formation accompanied by gas accumulation in the renal parenchyma. We also noted extensive destruction of the left kidney parenchyma (Fig. 1A–B).

Because of her poor response to PCD, we initially considered performing a left nephrectomy. However, on addition to her generally poor health condition, she developed disseminated intravascular coagulation, and her platelet count was remarkably low (25000/ μ L). We determined nephrectomy to be a high-risk procedure and consequently, performed open drainage surgery.

First, we made an incision in the left flank to reach the retro-peritoneal cavity. We confirmed the presence of gas inside the kidney parenchyma using ultrasonography; then, we incised the renal parenchyma to release the gas. We washed the wound and placed a drain into the cavity and left the wound and renal parenchyma open.

After open drainage surgery, her clinical condition gradually improved, and her wound site closed naturally. The patient's renal parenchyma extensively destroyed before surgery, gradually improved after the operation (Fig. 2A–C).

The patient's infection was controlled without performing nephrectomy, and she was discharged from the hospital on day 43.

Discussion

EPN is a rare urinary tract infection, first reported by Kelly and Maccallum¹ in 1984 and named by Schultz and Klorfein². Diabetes mellitus is observed in 80%–96% of patients, and hydronephrosis associated with urinary tract obstruction, is observed in 22%–66% of the patient with EPN.

EPN features pyelonephritis-like symptoms such as fever and flank pain. When severe, EPN can elicit shock and is associated with

* Corresponding author.

E-mail address: taiki.h6072@gmail.com (T. Hayashi).

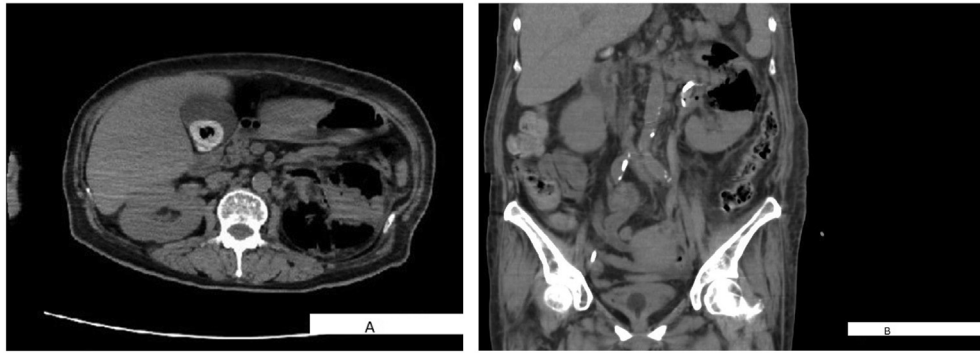


Fig. 1. A. computed tomography image taken at presentation. B. computed tomography image taken at presentation.

a high mortality rate.

Until the 1980's EPN treatment typically consisted of antibiotics and surgical treatment such as nephrectomy and open drainage surgery. However, the mortality rate associated with these approaches was as high as 40%–50%.

EPN mortality rate improved from 12% to 20% since 1990's with the introduction of broad-spectrum antibiotics. At this point, PCD became a treatment option for EPN^{3–4}.

In 2000, Huang and Tseng⁴ sub-divided EPN into four classes according to gas localization on CT images, creating an EPN treatment algorithm that remained widely used.

Today, first-line treatment for EPN typically consist of combination therapy with antibiotics and PCD. Nephrectomy is performed in cases with poor infection controlled by PCD.

Somani et al.⁵ reports that PCD combination therapy is associated with lower mortality than conservative therapy alone or

emergent nephrectomy. Consequently, PCD remained the primary treatment for EPN. However, there is poor consensus as to the preferred treatments for patients with poor infection control by PCD.

Our patient could not control her infection with PCD. But we could control infection by performing open drainage surgery. Additionally, her renal parenchyma, which had been extensively destroyed, improved after open drainage surgery.

It seemed possible that if sufficient drainage was achieved, kidney function may improve, even in cases where renal function was abolished, and nephrectomy was rendered unavoidable.

EPN can become severe. When PCD fails, and the general health condition of the patient is already poor, emergent nephrectomy is often contraindicated. EPN often complicates cases with diabetes mellitus, and there is a risk of future renal dysfunction due to diabetic nephropathy. Therefore, it is necessary to preserve the

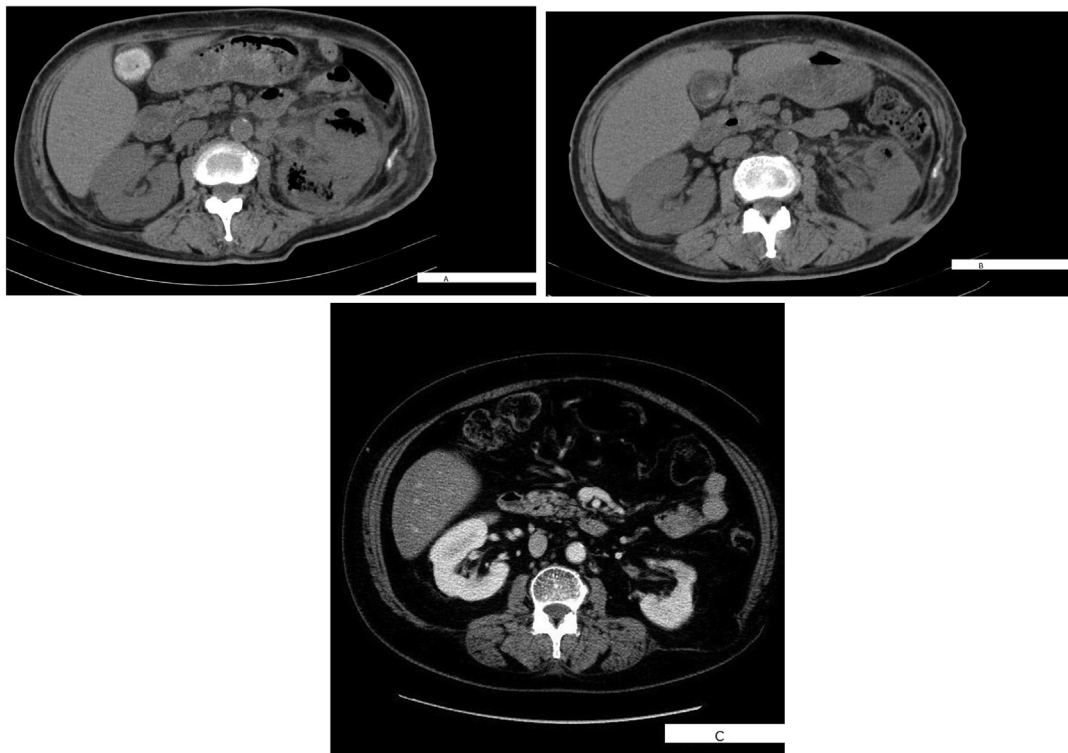


Fig. 2. A. computed tomography image taken 7 days after performing open drainage surgery. B. computed tomography image taken 30 days after performing open drainage surgery. C. computed tomography image taken 2 years after performing open drainage surgery.

kidneys to the extent possible. In our experience, when PCD failed, open drainage surgery may be an alternative method to emergent nephrectomy for patient with EPN with very poor general health condition.

References

1. Kelly HA, MacCallum WG. pneumaturia. *J Am Med Assoc.* 1898;31:375–381.
2. Schultz Jr EH, Klorfein EH. Emphysematous acute pyelonephritis. *J Urol.* 1962;87: 765–766.
3. Chen MT, Huang CN, Chou YH, et al. Percutaneous drainage in the treatment of emphysematous pyelonephritis: 10 -year experience. *J Urol.* 1997;157: 1569–1573.
4. Huang JJ, Tseng CG. Emphysematous Pyelonephritis: clinical radiological classification, management, prognosis and pathogenesis. *Arch Intern Med.* 2000;160: 797–805.
5. Somani BK, Nabi G, Thorpe P, et al. Is percutaneous drainage the new gold standard in the management of emphysematous pyelonephritis ? : evidence from a systematic review. *J Urol.* 2008;179:1844–1849.