

Single-Incision Laparoscopic Ventral Hernia Repair with Suprapubic Incision

Hanh Tran, FRACS, Isidro Turingan, RN, Mai Tran

ABSTRACT

Introduction: Although natural orifice transluminal endoscopic surgery promises truly scarless surgery, this has not progressed beyond the experimental setting and a few clinical cases in the field of ventral hernia repair. This is mainly because of the problem of sterilizing natural orifices, which prevents the use of any prosthetic material because of unacceptable risks of infection. Single-incision laparoscopic ventral hernia repair has gained more widespread acceptance by specialized hernia centers. Even so, there is a special subset of patients who are young and/or scar conscious and find any visible scar unacceptable. This study illustrates an innovative way of performing single-incision laparoscopic ventral hernia repair by a transverse suprapubic incision below the pubic hair/bikini line in 2 young male patients who had both umbilical and epigastric hernias as well as attenuated linea alba in the upper abdomen.

Case Description: Both patients underwent successful laparoscopic repair, and both were highly satisfied with the procedure, which produced no visible scars on their abdomen.

Discussion: Willingness to adopt new innovative procedures, such as single-incision laparoscopic surgery, has allowed modification of the incision site to produce invisible scars and hence become highly attractive to the young and scar-phobic segment of the population.

Key Words: NOTES, SILS, Ventral hernia, Suprapubic incision.

INTRODUCTION

Although natural orifice transluminal endoscopic surgery (NOTES) promises the possibility of truly scarless surgery, its applications and acceptance have been exceedingly low.¹⁻³ In contrast, its offshoot, single-incision laparoscopic surgery (SILS), has gained widespread acceptance in many surgical disciplines.⁴⁻⁸ Indeed, many minimally invasive surgical centers have adopted single-port laparoscopic ventral hernia repair (LVHR) as their preferred procedure.⁹⁻¹¹ The main disadvantage of single-port, compared to multiport, surgery is the relative loss of triangulation, but this can be overcome with increased experience, modification of dissection techniques, smaller/longer laparoscopes, and angulated/roticulated instruments.^{4,10}

Although the benefits of single-port over conventional multiport surgery await results of prospective, randomized, control studies, single-port surgery is advantageous for certain hernia types or patients with certain demographics. For instance, patients who have upper abdominal hernias are also prone to develop inguinal hernias. If these patients have their ventral hernia repaired laparoscopically, the mesh usually extends well below the umbilicus, making it impossible to perform conventional multiport laparoscopic hernia repair. The ability to use a single port, below the previous intraperitoneal mesh, enables the laparoscopic repair to be performed. In this study, we explored the surgical treatment of a subset of young patients who have multiple midline hernias with concomitant weakened linea alba, predisposing them to further hernias and for whom visible scars, from conventional open or laparoscopic multiport or single-port surgery, are not acceptable. We aimed to identify the challenges associated with SILS LVHR by a suprapubic incision below the pubic hair/bikini line.

CASE REPORT

This study was approved by the institutional review board of Holroyd Private Hospital (Sydney, NSW, Australia) for the purpose of patient data collection and reviews. The patients were 21- and 30-y-old males; both were construction workers. Both patients enjoyed regular vigorous gym

Discipline of Surgery, Sydney Medical School, University of Sydney, Westmead Hospital, Westmead NSW (Dr. H. Tran)

The Sydney Hernia Specialists Clinic, Sydney, NSW (Mr Turingan)

Charles Sturt University, Leeds Parade, Orange NSW Australia (Ms M. Tran)

Address correspondence to: Dr Hanh Tran FRACS, Level 2, 195 Macquarie Street, Sydney NSW 2000 Australia. Tel: +61 2 9221 1043 Fax: +61 2 8076 3229, E-mail: info@sydneyherniaspecialists.com.au

DOI: 10.4293/108680813X13654754534431

© 2013 by JSLS, *Journal of the Society of Laparoendoscopic Surgeons*. Published by the Society of Laparoendoscopic Surgeons, Inc.

workouts, including weight lifting, to maintain their 6 packs. Both patients presented with small umbilical and epigastric hernias, which were 4cm apart. However, both had significant widening of the linea alba, resulting from their well-built recti. In addition, the 21-y-old patient worked part-time as a topless waiter/dancer. He had seen 2 other surgeons; one suggested separate incisions to repair the hernias anteriorly, whereas the other suggested conventional multiport laparoscopic repair. This would have ended his career as a topless dancer, and he was prepared to put up with the hernias until such time that he finished with this career path, unless he could be offered scarless surgery. He provided the inspiration for this study. A search of MEDLINE, PubMed, and GoogleScholar in November 2011 did not reveal any publications on the use of single-incision LVHR with a suprapubic incision.

Preoperatively, patients were asked to wear their normal briefs or swim wear and the upper limit of these were marked with the aim to create a transverse suprapubic incision at least 1cm below this line. The patients were brought to the operating room, sequential compression devices were applied, 1g of cefazolin was given, and general anesthesia was induced without complication. The patients were catheterized and nasogastric suction was applied. The patients were placed in the lithotomy position with the legs in stirrups, prepped, and draped in standard sterile fashion. The skin was protected with iodine impregnated ioband.

A 2-cm transverse suprapubic incision was made, and the subcutaneous tissue was dissected down to the linea alba. This was incised longitudinally retracting the rectus muscle bellies until the peritoneum was entered under direct vision. At this time, the patient was placed head down at 15 degrees, and a SILS port was then deployed. Then, three 5-mm ports were introduced, with the upper port being used for insertion of a 5.5-mm/52-cm/30-degree-angle laparoscope. The surgeon and assistant stood between the legs, with the assistant standing behind and to the right side of the surgeon (**Figure 1**). In both cases, a small umbilical hernia measuring 1.5cm was identified, and the herniated fat content was reduced (**Figure 2**). The ligamentum teres was taken down superiorly to the level of the xiphoid cartilage. The herniated falciform ligament, through a 1.5-cm defect, was reduced. The relative loss of triangulation associated with SILS was overcome by the use of a smaller, longer laparoscope and by modifying the dissection techniques, namely, inline and vertical dissection, to minimize clashing with

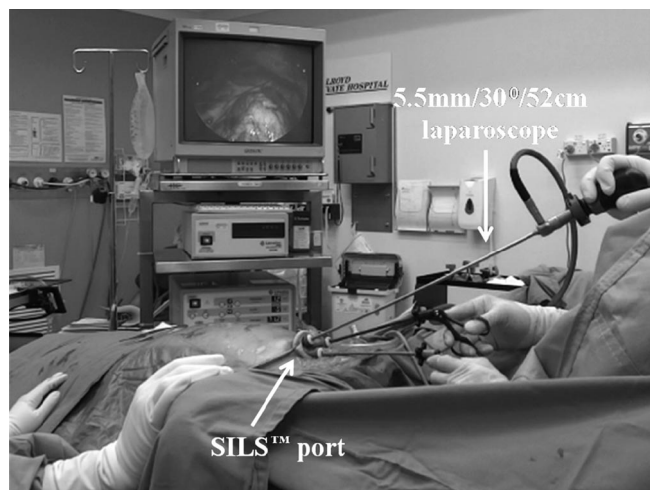

Figure 1. Patient in Trendelenburg position with suprapubic SILS™ port.

the laparoscope from within and without.⁴ Although standard straight dissecting instruments were used as the dissection progressed superiorly, longer instruments were used to complete the dissection of the ligamentum teres. The latter exposed the stretched linea alba fibers posteriorly with some potential sites for further herniation (**Figure 3**).

Mesh Measurement, Placement, and Fixation

Insufflation pressure was reduced from 12 mm Hg to 4 mm Hg for the purpose of measuring mesh size with the aim to use one that had a 5-cm clearance of hernia defects. In both cases, the transverse mesh diameter was 12cm, whereas the longitudinal diameter was 22cm, which extended inferiorly 5cm below the umbilicus and superiorly to just below the xiphoid cartilage. A C-QUR mesh (Atrium Medical Corporation, Hudson, NH) was used, and this was rolled up along the long axis from both edges inward with the coated surface inside to protect the antiadhesive coating from being damaged during insertion. For insertion of the mesh, a 12-mm port was introduced. However, because the skin/fascial defect was only 2cm, this necessitated partially pulling one posterior 5-mm port out of the skin level while still within the SILS port to maintain the air seal. The laparoscope was placed in the remaining posterior port for direct visualization as the 12-mm port was inserted anterior to it under direct vision. The rolled-up mesh was then inserted through this port before this was replaced by a 5-mm port for the continuation of the procedure. For ease of stapling, the mesh was transfixed with transfascial 0 PDS sutures superiorly and

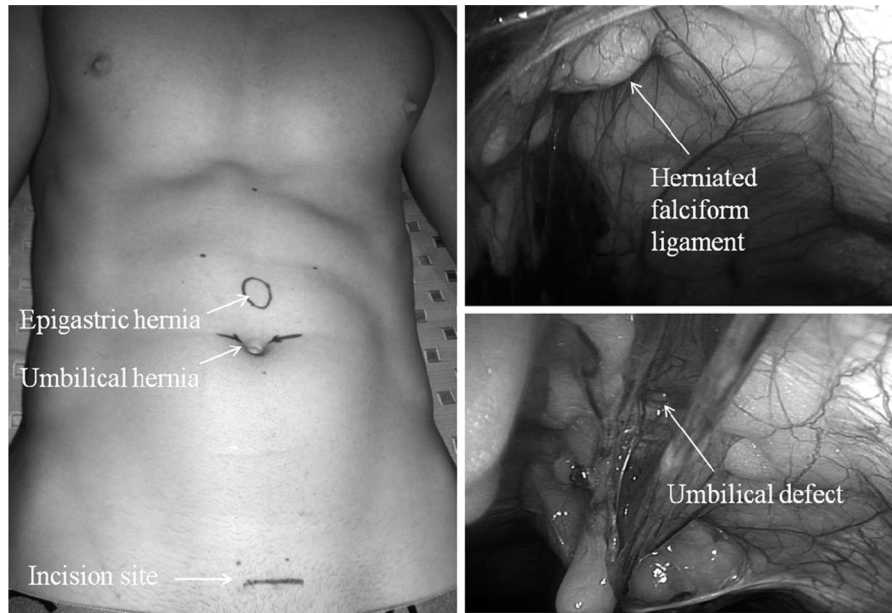


Figure 2. Epigastric and umbilical hernias with divarication of the recti in a well-built young man; the incision site being marked to be at least 1 cm below the top of the usual underwear.

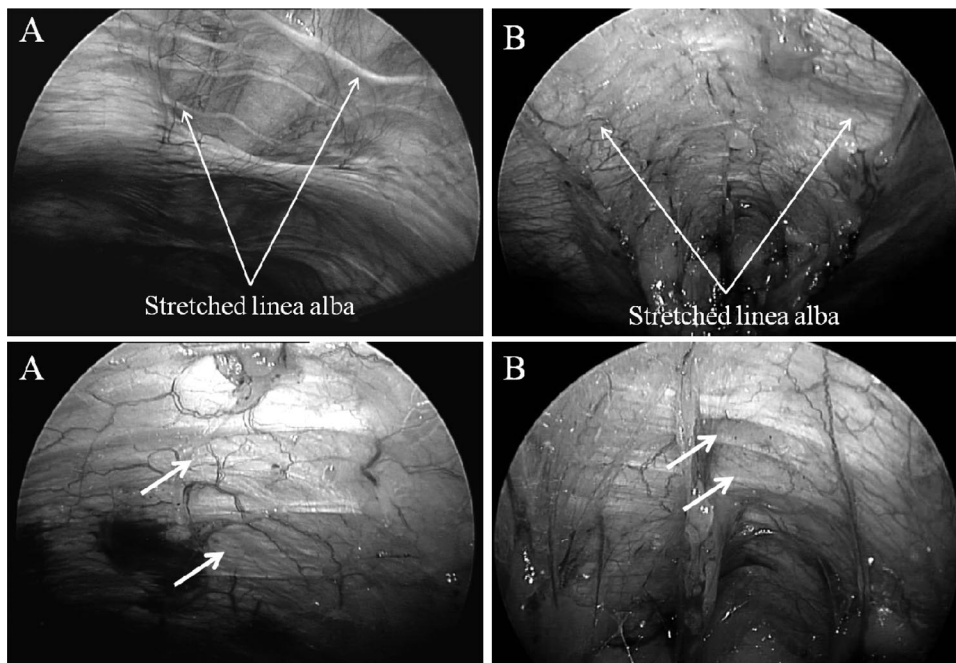


Figure 3. Intraoperative pictures of the stretched linea alba with potential sites (unmarked arrows) for further herniation: Patients A and B.

inferiorly, by stab incisions, using a suture passer (WL Gore & Associates, Flagstaff, AZ). The mesh was then fixed with spiral staples (Protacks, Covidien, Norwalk, CT) in a double-crown technique as per our usual practice (**Figure 4**).

The fascial defect was then closed with 1 PDS continuous and interrupted, 2.0 Vicryl subcutaneously, and 4.0 Monocryl subcuticularly. The patients were followed up at 1 wk as well as 1 and 3 mo after surgery. Time to return to work and satisfaction scores (1=dis-

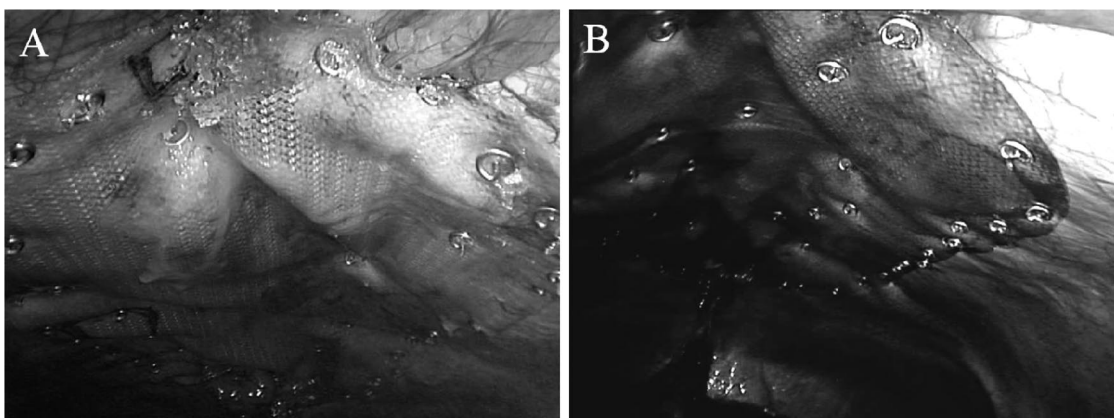


Figure 4. Placement of 12–21 cm C-Qur mesh with a “double crown” layer of spiral staples in patients A and B.

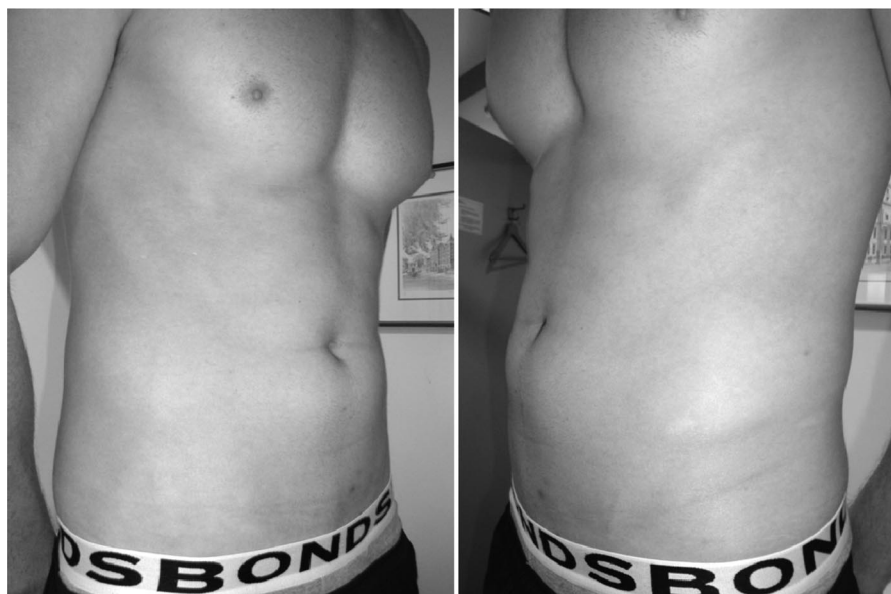


Figure 5. Suprapubic SILS LVHR resulting in “scarless” incision - (Patient A) 6 wk postop.

satisfied; 2=satisfied; and 3=highly satisfied) were obtained.

Both patients recovered uneventfully from the general anesthetic and were discharged home within 24 h. Both patients went back to work 3 wk after surgery, being highly satisfied with the procedure. No evidence of recurrence was observed after 3 mo, and with the patients wearing their usual underwear/swimmers, no visible abdominal scars could be seen (**Figure 5**).

DISCUSSION

The concept of NOTES has been present for some 10 y, yet its applications in surgery have been limited.¹ In the

field of ventral hernia repair, only a handful of cases have been performed worldwide, and universally for very small hernias.^{3,12} Even then, these were predominantly hybrid NOTES, where, for safety reasons, an abdominal 5-mm port was introduced first to allow safe entry of the port through the natural orifice into the peritoneal cavity.³ The main reason why NOTES has such severe limitations in hernia surgery is because the route of delivery, either vaginal or gastric, cannot be sterilized, thereby necessitating the use of biological meshes.^{13–15} Currently, the use of biological mesh is not recommended for routine ventral hernia repair, unless one is operating in the infected or contaminated fields.¹⁶ Further, biological meshes are vastly more expensive than prosthetic meshes. In contrast,

single-incision laparoscopic hernia repair has become more widely adopted for a wide range of ventral, incisional, and even parastomal hernias.⁹ The delivery of mesh through a sterile single-port, in common with conventional multiport laparoscopic hernia repair, assures similar sterility.

One of the important spin-offs of NOTES has been SILS, which is becoming widely practiced in some specialized minimally invasive centers, whether it is for urological, gynecological, or general surgical procedures. Successful adoption of SILS has resulted in the innovative way of hiding the single incision below the pubic hair/bikini line.

The main benefit of single-port versus multiport surgery is the use of blunt trocars, as well as inline insertion of instruments, which should reduce the risks of visceral and vascular injuries. As for whether reduced ports surgery improves cosmesis, causes less postoperative pain, and reduced port-site hernia formation, this awaits results of prospective, randomized, control studies. As a result of the relatively higher incidence of inguinal, compared to ventral, hernias, the repair of the former with single-port surgery has become the standard of care in some hernia centers.⁴ Experience gained with single-port inguinal hernia repair has been successfully applied to all types of ventral hernias, including, arguably, the most difficult of hernias, namely, parastomal hernias.⁹ Although the primary aim of hernia surgery is the successful repair of the hernia with minimal complications, for a small segment of the population, particularly the young and image-conscious patients, cosmesis becomes equally, if not more, important than success. This was exemplified by our 21-year-old male dancer who initially refused to have conventional open or laparoscopic repair unless he could be assured of a scarless incision. This was successfully achieved in both of our patients. Further, the laparoscopic repair achieved the reinforcement of the linea alba in the upper abdomen, which would result in greatly reduced risks of further midline hernia formation.

*Jacobsen et al.*³ reported the first case of hybrid NOTES recurrent umbilical hernia repair. In this report, the patient had a 2-cm × 2-cm defect and the repair was performed with a 7-cm × 7-cm biological mesh. The use of the latter is based on experimental evidence showing virtually 100% abscess formation and/or positive mesh cultures when prosthetic mesh was used. Although the short-term result was excellent, it would be interesting to have long-term follow-up, because the mesh size alone would not be considered ideal by most laparoscopic hernia surgeons, who would insist on a 5-cm overlap around the hernia

defect, even with defect closure.^{17–19} Further, the biological mesh is known to be absorbed within months, and this would result in the repair not being reinforced in the medium and long term. Again, this goes against current surgical practice of tension-free permanent prosthetic mesh coverage of the defects.

Bower and Love demonstrated the safety and efficacy of SILS LVHR in a series of 16 highly selected patients with relatively small ventral/incisional hernias. Tran went one step further and routinely repaired all ventral/incisional/parastomal hernias with SILS without conversion to open or multiport surgery and with complete success. Although these series are small, given the relatively low incidence of ventral, compared to inguinal, hernias, they provide the foundation for multicenter prospective, randomized, control studies in dedicated hernia centers.

Finally, multiple studies²⁰ have shown placement of transfascial sutures, in addition to stapling of the mesh, to be important in reducing the incidence of mesh dislocation and hence recurrence. Most of these used ePTFE mesh, with a single layer of staples, which is known to induce only very superficial collagen infiltration. This means that the permanent staples are important for the continuation of mesh stability. Other studies, however, have shown stapling of the mesh in a double-crown layer to be sufficient.^{21–23} Furthermore, some experimental studies²⁰ have shown polypropylene-based mesh induced significant collagen deposition between the mesh fibers without any significant shrinkage. Therefore, placement of transfascial sutures may not be important for mesh stability. In this study, we elected not to place transfascial sutures through the rectus muscles, because this could potentially cause significant postoperative pain, especially when these patients are likely to continue with their vigorous physical activities. Indeed, both of our patients resumed normal physical activities 3 wk after surgery without any discomfort.

CONCLUSION

Successful adoption of SILS for the repair of ventral hernias has resulted in innovative ways to tailor hernia repair for individual patients and, in this study, for the young and scar-phobic patients. The single suprapubic incision used for SILS LVHR produced a virtually invisible scar below the pubic hair/bikini line while providing reinforcement of the weakened linea alba in this particular patient demographic. This approach should encourage such patients to seek hernia repair earlier, which should improve

success rates while reducing complications associated with late repairs.

References:

1. Moreira-Pinto J, Lima L, Carreira-Pinto J, Rolanda C. Natural orifice transluminal endoscopy surgery: a review. *World J Gastroenterol.* 2011;17:3795–3801.
2. Zorrón R, Maggioni LC, Pombo L, Oliveira AL, Carvalho GL, Filgueiras M. NOTES transvaginal cholecystectomy: preliminary clinical application. *Surg Endosc.* 2008;22:542–547.
3. Jacobsen GR, Thompson K, Spivack A, et al. Initial experience with transvaginal incisional hernia repair. *Hernia.* 2010;14:89–91.
4. Tran H. Demonstrated safety and efficacy of single incision laparoscopic total extraperitoneal inguinal hernia repair. *JLS.* 2011;15:47–52.
5. Joseph S, Moore BT, Sorensen GB, et al. Single-incision laparoscopic cholecystectomy: a comparison with the gold standard. *Surg Endosc.* 2011;25:3008–3015.
6. Geisler D, Garrett T. Single incision laparoscopic colorectal surgery: a single surgeon experience of 102 consecutive cases. *Tech Coloproctol.* 2011;15:397–401.
7. Fanfani F, Rossitto C, Gagliardi ML, et al. Total laparoendoscopic single-site surgery (LESS) hysterectomy in low-risk early endometrial cancer: a pilot study. *Surg Endosc.* 2012;26:41–46.
8. Kaouk JH, Autorino R, Kim FJ, et al. Laparoendoscopic single-site surgery in urology: worldwide multi-institutional analysis of 1076 cases. *Eur Urol.* 2011;60:998–1005.
9. Tran HM. Laparoendoscopic single site ventral hernia repair: demonstrated safety and efficacy. *JLS.* 2012;16(2):242–9.
10. Bower CE, Love KM. Single incision laparoscopic ventral hernia repair. *JLS.* 2011;15:165–168.
11. Bucher P, Pugin F, Morel P. Single-port access prosthetic repair for primary and incisional ventral hernia: toward less parietal trauma. *Surg Endosc.* 2011;25:1921–1925.
12. Candage R, Jones K, Luchette FA, Sinacore JM, Vandevender D, Reed RL 2nd. Use of human acellular dermal matrix for hernia repair: friend or foe? *Surgery.* 2008;144:703–709; discussion, 709–711.
13. Buck L, Michalek J, Sickle K, Schwesinger W, Bingener J. Can gastric irrigation prevent infection during NOTES mesh placement? *J Gastrointest Surg.* 2008;12:2010–2014.
14. Miedema BW, Bachman SL, Sporn E, Astudillo JA, Thaler K. Transgastric placement of biologic mesh to the anterior abdominal wall. *Hernia.* 2009;13:415–419.
15. Powell B, Whang SH, Bachman SL, et al. Transvaginal repair of a large chronic porcine ventral hernia with synthetic mesh using NOTES. *JLS.* 2010;14:234–239.
16. Kim H, Bruen K, Vargo D. Acellular dermal matrix in the management of high-risk abdominal wall defects. *Am J Surg.* 2006;192:705–709.
17. Heniford BT, Park A, Ramshaw BJ, Voeller G. Laparoscopic repair of ventral hernias: nine years' experience with 850 consecutive hernias. *Ann Surg.* 2003;238:391–400.
18. Franklin ME Jr, Gonzalez JJ Jr, Glass JL, Manjarrez A. Laparoscopic ventral and incisional hernia repair: an 11-year experience. *Hernia.* 2004;8:23–27.
19. Sharma A, Mehrotra M, Khullar R, Soni V, Baijal M, Chowbey PK. Laparoscopic ventral/incisional hernia repair: a single centre experience of 1,242 patients over a period of 13 years. *Hernia.* 2011;15:131–139.
20. Tran HM, Saliba L, Chandraratnam E, Turingan I, Hawthorne W. Strategies to minimize adhesions to intraperitoneally placed mesh in laparoscopic ventral hernia repair. *JLS.* 2012;16:89–94.
21. Baccari P, Nifosi J, Ghirardelli L, Staudacher C. Laparoscopic incisional and ventral hernia repair without sutures: a single-center experience with 200 cases. *J Laparoendosc Adv Surg Tech A.* 2009;19:175–179.
22. Wassenaar E, Schoenmaeckers E, Raymakers J, van der Palen J, Rakic S. Mesh-fixation method and pain and quality of life after laparoscopic ventral or incisional hernia repair: a randomized trial of three fixation techniques. *Surg Endosc.* 2010;24:1296–1302.
23. Brill JB, Turner PL. Long-term outcomes with transfascial sutures versus tacks in laparoscopic ventral hernia repair: a review. *Am Surg.* 2011;77:458–465.