

Pulmonary thrombosis in 2019-nCoV pneumonia?

Last February, the *Journal of Thrombosis and Haemostasis* published a retrospective study of 138 patients admitted to Tongji Hospital in Wuhan, China, for novel coronavirus (2019-nCoV) pneumonia.¹

The purpose of this study was to describe the characteristics of coagulative tests in these patients. At admission, the deceased patients showed higher levels of D-dimer and fibrin degradation products other than significantly prolonged prothrombin time (PT) than survivors. International Society on Thrombosis and Haemostasis (ISTH) criteria for disseminated intravascular coagulation (DIC) were present in 71.4% of non-survivors and in 0.6% of survivors. The total mortality rate was 11.5%.

The authors suggested an activation of blood coagulation with secondary fibrinolysis. However, they reported only laboratory findings of DIC but no bleeding was mentioned, indicating that there was not an overt DIC.

Our hypothesis is that the abnormal laboratory findings could be an expression of a local DIC, ie, a pulmonary vascular thrombosis with subsequent activation of fibrinolysis. The concept of pulmonary thrombosis has been recently proposed for conditions such as pneumonia, asthma, and chronic obstructive pulmonary disease.² It is known that viral diseases such as those from EBOLA and cytomegaloviruses can induce DIC.^{3,4} Therefore, it is not surprising that 2019-nCoV could be capable of doing the same.

The development of DIC is due to the activation of cytokine-producing monocytes, such as interleukin 6 and tumor necrosis factor, which in turn induce activation of the endothelial cells and tissue factor that triggers the blood coagulation cascade.⁵ The activation of blood coagulation is essential in counteracting viral infections along with the immune system trapping viruses by forming a fibrin network, thus limiting their dissemination.⁶ However, a massive inflammatory and coagulative response is dangerous because it can lead to a local thrombosis in the lungs.⁷

Acute respiratory distress syndrome (ARDS) has been described in approximately 40% of 201 patients with 2019-nCoV pneumonia⁸ and it was crucial in increasing the risk of death. ARDS may be associated with pulmonary vascular microthrombosis.⁹

Thus, a different interpretation of the results obtained by Tang et al¹ may be advanced.

It could be possible that pulmonary thrombosis may further complicate the course of 2019-nCoV pneumonia. It could induce a

prothrombotic endothelial dysfunction, which may cause a severe acute inflammation via complement and cytokine release and a blood coagulation activation with vascular microthrombosis that induces a local consumption coagulopathy, ie a DIC, resulting in ARDS (Figure 1).

What may this suggest? It could be useful to combine drugs to reduce the inflammatory cytokine potential with anticoagulant treatment. Low molecular weight heparin or fondaparinux may be helpful by limiting the vicious circle of inflammation-blood coagulation activation-inflammation, thus improving the severely impaired gas exchange in these patients. In particular, fondaparinux was effective in reducing sepsis derived coagulopathy in an animal model¹⁰ further affirming the concept that coagulation and inflammation are closely linked.

AUTHOR CONTRIBUTIONS




All the authors contributed to write the draft of the manuscript.

KEYWORDS

2019 nCoV, ARDS, DIC, heparin, pulmonary thrombosis

CONFLICT OF INTEREST

The authors have no conflict of interest to declare.

Francesco Marongiu¹ 
Elvira Grandone^{2,3} 
Doris Barcellona¹ 

¹Department of Medical Science and Public Health, University of Cagliari, Cagliari, Italy

²Atherosclerosis and Thrombosis Unit, IRCCS Ospedale Casa Sollievo della Sofferenza, Foggia, Italy

³Department of Obstetrics and Gynecology, First Moscow State Medical University, Moscow, Russia

ORCID

Francesco Marongiu  <https://orcid.org/0000-0001-7277-2868>

Elvira Grandone  <https://orcid.org/0000-0002-8980-9783>

Doris Barcellona  <https://orcid.org/0000-0002-0823-3357>

REFERENCES

1. Tang N, Li D, Wang X, Sun Z. Abnormal coagulation parameters are associated with poor prognosis in patients with novel coronavirus pneumonia. *J Thromb Haemost.* 2020;18(4): 844-847

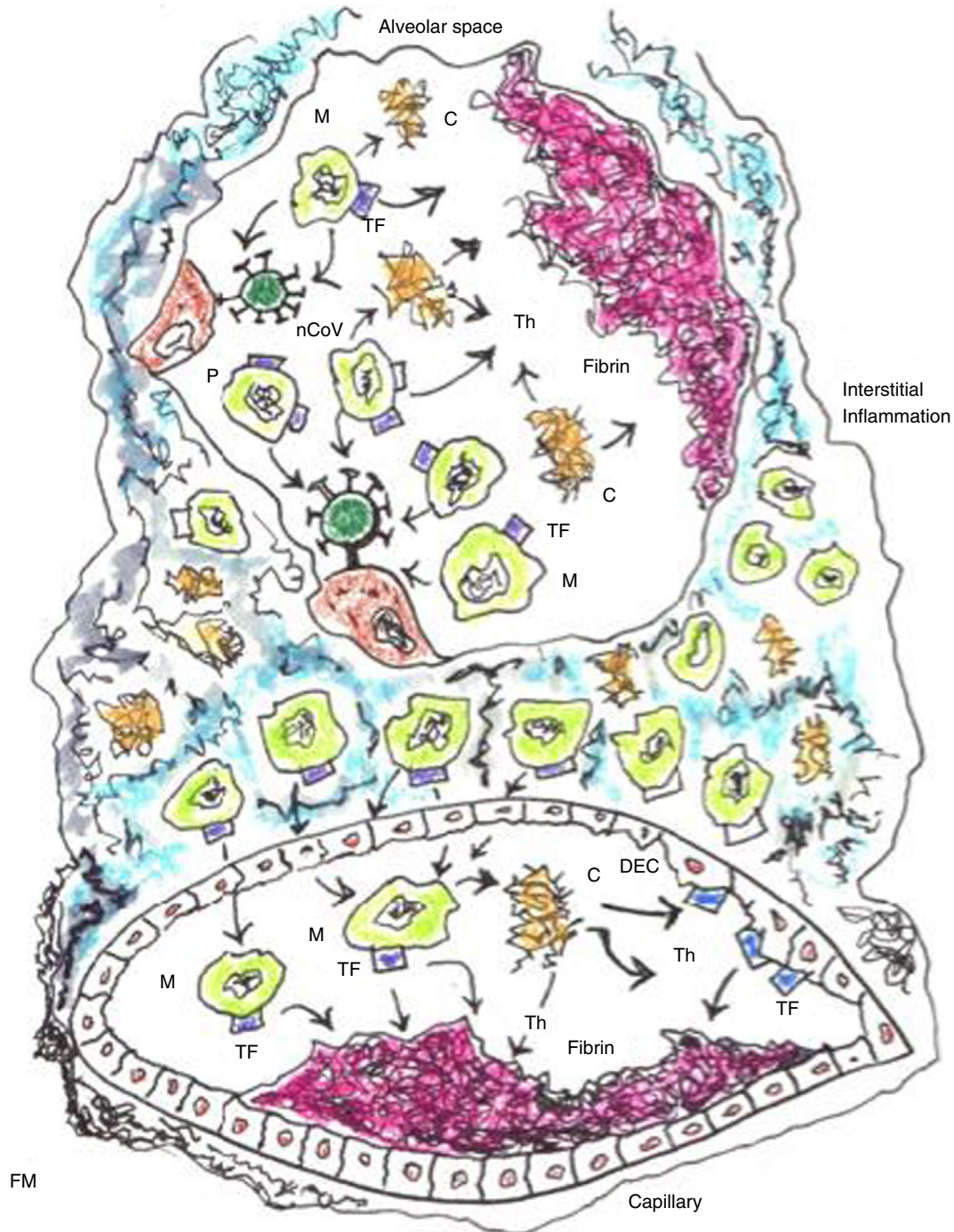


FIGURE 1 A drawing to illustrate a possible mechanism inducing pulmonary thrombosis. After nCoV infection monocytes and released cytokines can provoke interstitial inflammation, endothelial damage, and blood coagulation activation. Tissue factor is crucial in that it can be either exposed by monocytes, damaged endothelial cells or activated by the cytokines' burden. The final result may be thrombin production and consequent alveolar and capillary thrombosis. C, cytokines; DEC, damaged endothelial cells; M, monocyte; nCoV, novel coronavirus; P, pneumocyte; TF, tissue factor; Th, thrombin

- Marongiu F, Mameli A, Grandone E, Barcellona D. Pulmonary thrombosis: a clinical pathological entity distinct from pulmonary embolism? *Semin Thromb Hemost.* 2019;45:778-783.
- Rogers KJ, Maury W. The role of mononuclear phagocytes in Ebola virus infection. *J Leukoc Biol.* 2018;104:717-727.
- Müller NF, Schampera M, Jahn G, Malek NP, Berg CP, Hamprecht K. Case report: severe cytomegalovirus primary infection in an immunocompetent adult with disseminated intravascular coagulation treated with valganciclovir. *BMC Infect Dis.* 2016;16:19.
- Levi M. Pathogenesis and diagnosis of disseminated intravascular coagulation. *Int J Lab Hematol.* 2018;40(Suppl 1):15-20.
- Antoniak S. The coagulation system in host defense. *Res Pract Thromb Haemost.* 2018;2:549-557.

7. Stroo I, Ding C, Novak A, et al. Inhibition of the extrinsic or intrinsic coagulation pathway during pneumonia-derived sepsis. *Am J Physiol Lung Cell Mol Physiol.* 2018;315:L799-L809.
8. Wu C, Chen X, Cai Y. Risk factors associated with acute respiratory distress syndrome and death in patients with coronavirus disease 2019 pneumonia in Wuhan, China. *JAMA Intern Med.* 2020; e200994.
9. Jae C, Chang JC. Acute respiratory distress syndrome as an organ phenotype of vascular microthrombotic disease: based on hemostatic theory and endothelial molecular pathogenesis. *Clin Applied Thromb Hemost.* 2019;25:1-20.
10. Keshari RS, Silasi R, Popescu NI. Fondaparinux pentasaccharide reduces sepsis coagulopathy and promotes survival in the baboon model of *Escherichia coli* sepsis. *J Thromb Haemost.* 2020;18:180-190.

Received: 17 March 2020 | Accepted: 19 March 2020

DOI: 10.1111/jth.14843

Response to 'Pulmonary thrombosis in 2019-nCoV pneumonia?'

1 | REPLY TO THE COMMENT

We appreciate the opportunity to respond to the comments by Dr. Marongiu et al. They presented only laboratory findings of disseminated intravascular coagulation (DIC), but no bleeding was mentioned, indicating that there was not overt DIC in our patients; instead, the abnormal laboratory findings could be an expression of local DIC (ie, a pulmonary vascular thrombosis). Thus, they suggested anticoagulant treatment in patients with coronavirus disease 2019 (COVID-19).

First, bleeding is less common than thrombosis and presents late in DIC induced by infection, and the site of bleeding is sometimes hard to find (eg, brain, intra-abdominal).¹ We suggest the International Society of Thrombosis and Haemostasis diagnostic criteria² rather than just relying on clinical manifestation for DIC diagnosis. In fact, because of neglect or lack of available coagulation tests, the diagnosis of DIC is often delayed until bleeding from multiple sites occurs.³

We agree with Dr. Marongiu et al that pulmonary vascular thrombosis may exist in some severe COVID-19 cases, the pulmonary inflammatory reaction and hypoxemia resulting from SARS-CoV-2 infection can lead to hypercoagulability.⁴ However, because DIC is an acquired syndrome characterized by systemic intravascular activation of coagulation, leading to deposition of fibrin in the circulation,⁵ we disagree with the contradictory concept of "local DIC." Once patients meet the diagnostic criteria of DIC, multiple organ dysfunction resulting from microthrombus should be considered, not only in the lung, although it may be the most affected organ.

Finally, anticoagulant treatment is a reasonable choice for preventing DIC and venous thromboembolism in COVID-19. However, the activation of blood coagulation is essential in counteracting virus infections⁶; on the other hand, patients meeting the diagnostic criteria of overt DIC may have illness progression that no longer

benefits from anticoagulant treat.⁷ Hence, it is important to identify patients who can benefit from anticoagulants using the criteria of sepsis-induced coagulopathy suggested by International Society of Thrombosis and Haemostasis,⁸ markedly elevated D-dimer on admission and so on can also be considered. We are retrospectively analyzing the association of anticoagulant treatment with outcome in severe COVID-19 patients of our hospital, and hope the results will contribute to the management of COVID-19 in the future.

CONFLICT OF INTEREST

None declared.

Ning Tang

Tongji Hospital, Tongji Medical College, Huazhong University of Science and Technology, Wuhan, China

Correspondence

Ning Tang, Tongji Hospital, Tongji Medical College, Huazhong University of Science and Technology, Wuhan, Hubei, China.

Email: tonyjesus@126.com

REFERENCES

1. Bernard GR, Margolis BD, Shanies HM, et al. Extended evaluation of recombinant human activated protein C United States Trial (ENHANCE US): a single-arm, phase 3B, multicenter study of drotrecogin alfa (activated) in severe sepsis. *Chest.* 2004;125(6):2206-2216.
2. Taylor FB, Toh CH, Hoots WK, et al. Towards definition, clinical and laboratory criteria, and a scoring system for disseminated intravascular coagulation. *Thromb Haemost.* 2001;86:1327-1330.
3. Thachil J. Platelets and infections in the resource-limited countries with a focus on malaria and viral haemorrhagic fevers. *Br J Haematol.* 2017;177(6):960-970.
4. Gupta N, Zhao YY, Evans CE. The stimulation of thrombosis by hypoxia. *Thromb Res.* 2019;181:77-83.