



Received: 2015.01.22
Accepted: 2015.02.28
Published: 2015.05.22

Authors' Contribution:

- A** Study Design
- B** Data Collection
- C** Statistical Analysis
- D** Data Interpretation
- E** Manuscript Preparation
- F** Literature Search
- G** Funds Collection

Endovascular Removal of the Viatorr Stent-Grafts. Report of Two Cases

Wojciech Cwikiel^{ABDEF}, Magnus Bergenfeldt^{ACDE}, Inger Keussen^{ABDE}

Department of Radiology, University of Lund Hospital, Lund-S, Sweden

Author's address: Wojciech Cwikiel, Department of Radiology, University of Lund Hospital, Lund-S, Sweden,
e-mail: wojciech.cwikiel@med.lu.se

Background:	The dysfunction of misplaced or dislodged endovascular endoprostheses, may be a serious complication, and endovascular removal may be attempted in some cases.
Case Report:	A Viatorr [®] stent-graft (Gore, Flagstaff, AR, USA) is an endoprosthesis designed and commonly used for creation of a transjugular intrahepatic portosystemic shunt (TIPS). Two Viatorrs were accidentally dislodged during TIPS procedure. In another patient, the Viatorr was malpositioned, with its distal end being placed in the bile duct. All endoprostheses were successfully removed without serious complications.
Conclusions:	Removal of a misplaced or dislodged Viatorr endoprosthesis is possible using interventional methods.
MeSH Keywords:	Device Removal • Endovascular Procedures • Hypertension, Portal • Portosystemic Shunt, Transjugular Intrahepatic • Stents
PDF file:	http://www.polradiol.com/abstract/index/idArt/893642

Background

TIPS is currently one of the generally accepted treatment methods for patients with symptomatic portal hypertension (PH). The procedure may be challenging, requires appropriate skills of the performing physician. A rate of up to 20% of procedure-related complications has been reported [1]. An inadequate placement of endoprostheses used for TIPS creation requires additional interventions. In case of migration of the endoprosthesis, need of advanced surgical procedures has been reported [2–4]. We reported successful retrieval of two dislodged Viatorrs in one patient and one misplaced endoprosthesis in another patient, with the use of endovascular methods.

Case Reports

Case one

A 55-year-old male with liver cirrhosis was admitted due to bleeding from gastric varices. Ascites and chronic occlusion of the portal vein (PV) were diagnosed on CT of the abdomen and the patient was referred for TIPS combined with PV recanalization.

Following informed consent and initiation of general anesthesia, a 4 F Cobra catheter (Cordis, Johnson&Johnson, Miami Lake, FL, USA) was placed through the left transjugular access and wedged with a tip in the branch of the right hepatic vein. CO2 injection showed partly patent but very small intrahepatic PV branches and occlusion of the main PV to the confluence of the superior mesenteric vein and the splenic vein. Following replacement of the catheter with a 10-F introducer sheath, several unsuccessful attempts of transjugular transhepatic puncture of the intrahepatic PV branches were carried out using a Rösch-Uchida transjugular liver access set (Cook Inc., Bloomington, IN, USA).

In order to facilitate transjugular, transhepatic access to PV, a trans-splenic puncture of the splenic vein branch was performed using a 22-G needle, and a 5-F introducer sheath was placed. Subsequently, a 4-F Cobra catheter jointly with a 0.035-inch guidewire (Terumo, Tokyo, Japan) was manipulated through the splenic vein and into the occluded part of PV in the liver. That catheter was exchanged over the wire for a 6×20-mm dilation balloon (Powerflex Pro, Cordis), and then via the transjugular access, a transhepatic puncture towards the balloon was performed from the right hepatic

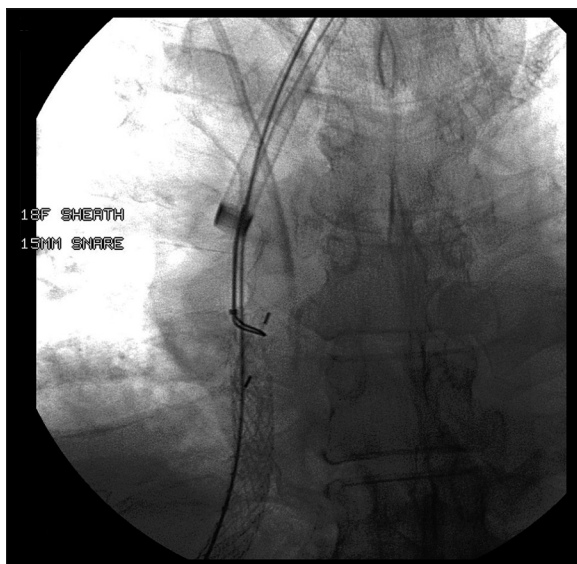


Figure 1. Snare placed over the cranial edge of the Viatorr dislodged to the right atrium.

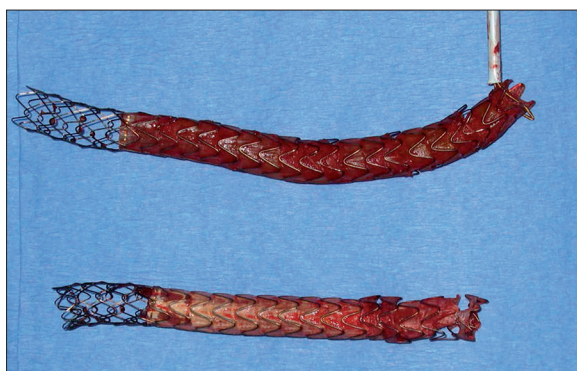


Figure 2. Removed Viatorrs.

vein using the transjugular access set. With the use of that access, the tip of the guidewire was advanced into the balloon, and then by pulling back the balloon, the guidewire was advanced to the splenic vein. Following dilation of the tract with a 4×40-mm balloon (Powerflex Pro), a 10-F transjugular sheath was advanced through the transhepatic tract and the recanalized segment of PV. Two Viatorrs (8×80+20 mm and 8×60+20 mm) were deployed coaxially, connecting the SMV/splenic vein confluence with the right hepatic vein. Contrast-enhanced examination showed a short stenosis at the cranial end of the created shunt and repeated balloon dilation was attempted. The 8 x40-mm balloon (Powerflex Pro) inflated partly into the Viatorr was accidentally moved in the cranial direction, causing dislodgement of the cranial part of the endoprosthesis to the right atrium.

After replacing the previous sheath with an 18-F sheath (Cook Inc.), a GooseNeck Snare (EV3, Plymouth, MN, USA) with a 15-mm loop was introduced over the guide wire. The loop of the snare was placed over the cranial edge of the Viatorr (Figure 1). The Viatorr was squeezed and the sheath was advanced over the endoprosthesis. The Viatorr was withdrawn into the sheath and was removed together with the sheath. However, during that withdrawal, the second (coaxially placed in the first one) Viatorr followed into

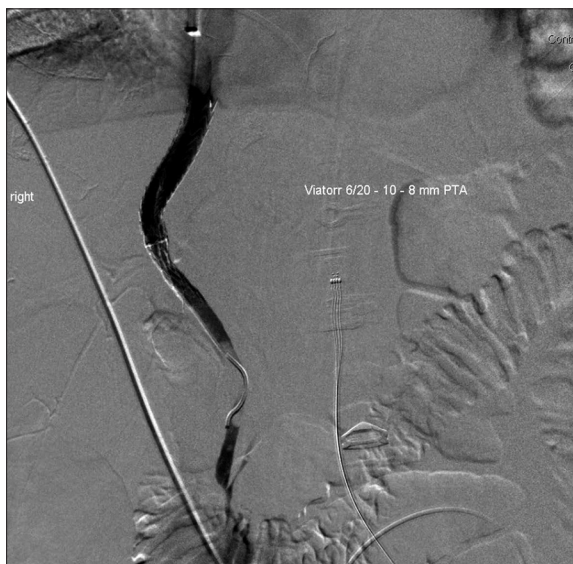

Figure 3. Viatorr connecting the bile duct with IVC.

IVC and the removal procedure was repeated as described above (Figure 2). Thereafter, two new Viatorr endoprostheses (8×80+20 mm) were placed in an adequate position, with subsequent good function of the TIPS. The transsplenic tract was embolized with två 3×10-mm coils (Cook Inc) and gelfoam pledgets.

Case two

A 43-year-old male with alcohol-related cirrhosis, ascites and bleeding from the varices was referred for TIPS to the Department of Endovascular Surgery of a nearby hospital. CO₂ portography was performed in there through a balloon catheter placed in the branch of the middle hepatic vein, showing patent PV.

During transjugular, transhepatic attempt to puncture PV, a bile duct was accidentally entered (Figure 3). That was misinterpreted by the physician performing the procedure, who placed a Viatorr connecting the bile duct to the right hepatic vein. The physician reported later that "the flow from the SMV was good, the gradient was=0 mmHg, and the TIPS was created successfully".

On the following three days the patient's condition deteriorated and on the fourth day he showed signs of general sepsis and abdominal distension requiring urgent ICU care. The inflammatory parameters were high and the laboratory tests were critically elevated (P-bilirubin=466 μmol/L; CRP=43mg/L; P-creatinine=435 μmol/L). At that time the error was identified and a percutaneous biliary drainage catheter was placed percutaneously through the right liver lobe bile ducts to the duodenum.

Afterwards, the patient was transferred to the Department of Hepatic Surgery at our hospital, for urgent treatment. Following an interdisciplinary decision and discussion with the patient and his family, it was undertaken to attempt removal of the Viatorr. With the patient under general anesthesia, a paraumbilical vein was punctured using ultrasonographic guidance, and a 4-F Cobra catheter was advanced to

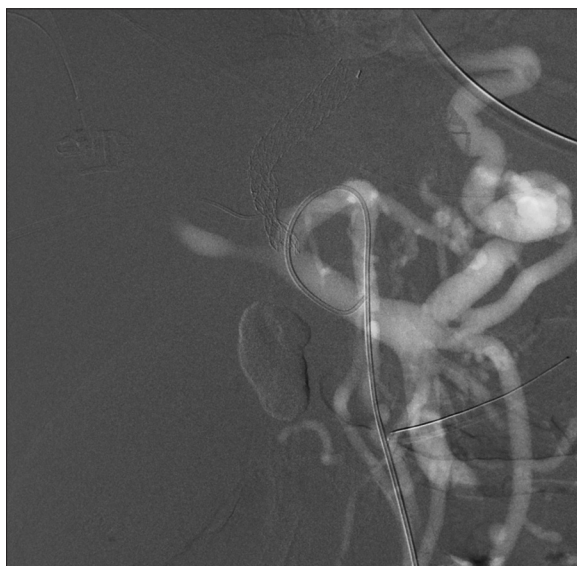

Figure 4. CO2 portography through the catheter placed through a paraumbilical vein.

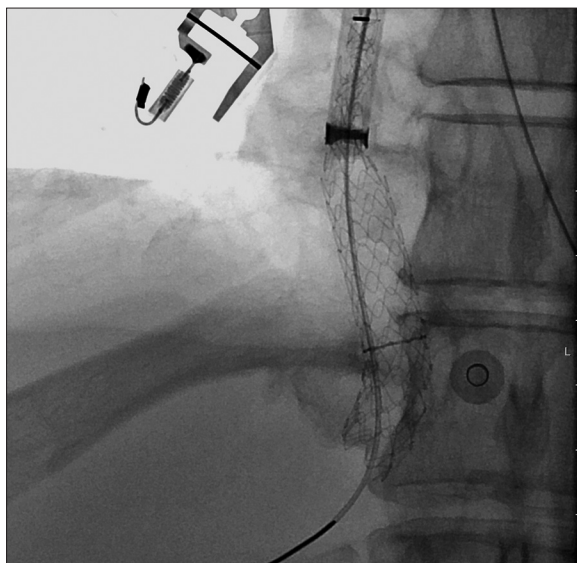


Figure 5. Viatorr pulled back to the right atrium, partly in the sheath.

the right portal vein branch. CO2 portography through that catheter showed a hepatofugal flow in the portal vein but no connection with the bile duct (Figure 4). The percutaneous biliary drainage catheter was removed over the guide-wire and replaced with a 8-F sheath. Through the left jugular vein, a 4-F Cobra catheter was introduced jointly with a 0.035-inch glide-wire through the Viatorr to the common bile duct. After confirmation of their position, the sheath was exchanged over the 0.035-inch Amplatz wire for a 45-cm-long 16-F sheath. The loop of the 15-mm GooseNeck Snare was placed over the wire. Subsequently, a 10×40-mm dilation balloon was advanced into the Viatorr in order to facilitate placement of the snare over the cranial edge of the Viatorr. However, only a part of the cranial portion of the Viatorr could be grasped with the snare.

The balloon was deflated and attempt to withdraw the Viatorr into the sheath was performed. About 50% of the

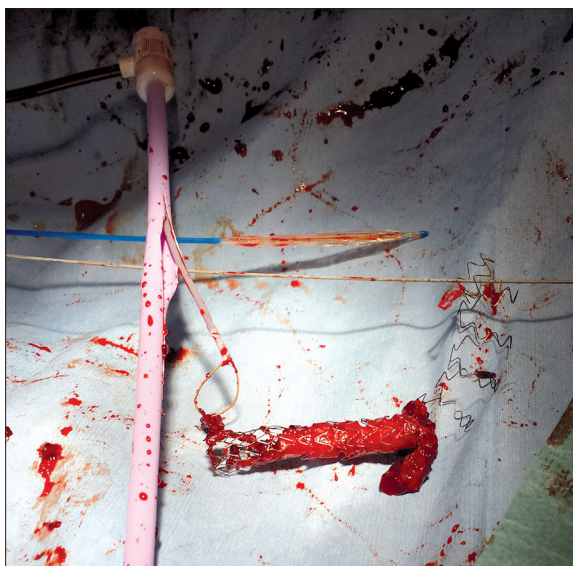


Figure 6. Removed Viatorr.

Viatorr could be retrieved into the sheath, but then the Viatorr became partly disintegrated and could not be further retracted in the sheath. However, the entire Viatorr could be pulled back from the transhepatic tract to the right atrium (Figure 5).

The Amplatz wire tip was withdrawn from the bile duct and advanced to the inferior caval vein (IVC). The right common femoral vein was accessed and another 45-cm-long 16-F sheath was placed with the tip in the IVC. The Amplatz wire was grasped with a 15-mm snare and withdrawn through that sheath. The snare was then advanced over the caudal edge of the Viatorr, which was squeezed and the entire endoprosthesis was pulled back into the sheath in the IVC.

The sheath with the endoprosthesis was removed (Figure 6) and hemostasis was obtained with manual compression. A puncture of the portal vein was performed from the transjugular approach towards the tip of the catheter inserted through the paraumbilical vein (PV). The 10×2+8-mm Viatorr was placed in the tract and dilated with a 10×40-mm balloon. CO2 portography confirmed good flow through the TIPS channel and no flow to the bile duct.

The sheath in the right lobe bile duct was replaced with an 8-F biliary drainage catheter. Following percutaneous puncture, a left liver lobe internal-external biliary drainage catheter was placed to optimize bile outflow. There were no immediate complications.

In the following three weeks, the patient recovered substantially and his laboratory test results normalized. The follow-up evaluation at six weeks showed normal bile ducts and biliary catheters were removed.

Discussion

The first successful TIPS supported with stents in patients was reported on in 1990 [5]. In the following years TIPS procedure became more common and was

mainly performed by experienced interventional radiologists. Shunt dysfunction requiring invasive revision was commonly caused by ingrowth of the hyperplastic tissue through the stent mesh or stenoses at the edge of the stents.

The Viatorr® endoprosthesis developed specifically for TIPS was introduced in 2001 [6].

Dysfunction of that endoprosthesis was also reported on. However, long-term results on TIPS with Viatorr are better than for shunts created with bare stents [7,8].

Before TIPS, assessment of the venous liver circulation is mandatory, in addition to the routine clinical evaluation of the patient. Occlusion of the main portal vein is a relative contraindication for TIPS but the procedure may be done using a modified technique [9].

During TIPS, blood flow in the portal vein should be evaluated and pressure before and after shunt placement should be measured. Once placed in the transhepatic tract, the Viatorr is stable, due to relatively strong, self-expanding radial forces of the nitinol skeleton, which support a graft material. Coaxial placement of more than one endoprosthesis may be required e.g. in cases where the occluded segment of the portal vein must be covered as well.

Complications during TIPS procedure include inadvertent puncture of the bile duct, hepatic artery, transhepatic puncture of the peritoneal cavity, bleeding etc. [1]. Most of these complications can be corrected immediately without serious consequences for the patient.

Displacement of the Viatorr from the TIPS channel to facilitate liver transplant was reported on [10]. Endovascular removal or repositioning of misplaced/dislodged stents/stent grafts was described [10,11], but to our knowledge, no attempt to remove misplaced or dislodged Viatorr endoprostheses was reported on.

In the first of our patients, coaxial placement of two Viatorrs was necessary and the inserted endoprostheses were balloon-dilated. This first dilation reduced the stability of the Viatorrs in the transhepatic channel. Due to an

unsatisfactory position of the edge of the cranial Viatorr, a second balloon dilation was attempted, resulting in inadvertent dislodgement of endoprostheses in the cranial direction. Due to a possibility of arrhythmia caused by the cranial edge of Viatorr and suspicion of further migration, a decision was made to remove and replace the endoprosthesis. Due to its migration, the second Viatorr was also removed, which was conducted without complications.

In the second patient, the Viatorr was placed in the bile duct, obviously due to misinterpretation of the anatomy. That caused serious deterioration of the patient's condition, which could have had fatal consequences. Treatment options such as embolization or surgical removal of the misplaced Viatorr were discussed. However, surgical repair, which would require partial hepatectomy, was considered unsafe in the patient with liver cirrhosis, portal hypertension, and ongoing infection. Embolization of the misplaced Viatorr was able to close communication between bile ducts and the hepatic vein. However, a foreign body would keep up the infection and the caudal part of the Viatorr would further damage the bile ducts. The removal procedure was more complicated than in the first patient. However, it could be completed, TIPS was created and bile ducts were decompressed. Fortunately that patient recovered by the time of this report, but it is uncertain whether the damage to the bile ducts will have future consequences or not.

Conclusions

We concluded that the creation of TIPS may be a complicated procedure; it requires careful pre-procedural preparation. TIPS should be performed by a properly trained interventional radiologist only, to avoid serious complications, as those described in our second patient. Removal of a Viatorr, if required, is technically possible with endovascular approach.

Statement

All procedures were in accordance with the ethical standards of the institutional and/or national research committee and with the 1964 Helsinki declaration and its later amendments or comparable ethical standards.

References:

- Gaba RC, Khiatani Vishal L et al: Comprehensive review of TIPS technical complications and how to avoid them. *Am J Roentgenol*, 2011; 196: 675-85
- Darcy M: Evaluation and management of transjugular intrahepatic portosystemic shunts. *Am J Roentgenol*, 2012; 199: 730-36
- Te HS, Jeevanandam V, Millis JM et al: Open cardiotomy for removal of migrating transjugular intrahepatic portosystemic shunt stent combined with liver transplantation. *Transplantation*, 2001; 71: 1000-3
- Salvalaggio PR, Koffron AJ, Fryer JP, Abecassis MM: Liver transplantation with simultaneous removal of an intracardiac transjugular intrahepatic portosystemic shunt and a vena cava filter without the utilization of cardiopulmonary bypass. *Liver Transpl*, 2005; 11: 229-32
- Richter GM, Noeldge G, Palmaz JC et al: Transjugular intrahepatic portacaval stent shunt: preliminary clinical results. *Radiology*, 1990; 174: 1027-305
- Cejna M, Peck-Radosavljevic M, Thurnher SA et al: Creation of transjugular intrahepatic portosystemic shunts with stent-grafts: initial experiences with a polytetrafluoroethylene-covered nitinol endoprosthesis. *Radiology*, 2001; 221: 437-46
- Vignali C, Bargellini I, Grosso M et al: TIPS with expanded polytetrafluoroethylene-covered stent: results of an Italian multicenter study. *Am J Roentgenol*, 2005; 185: 472-80
- Fidelman N, Kwan SW, LaBerge JM et al: The transjugular intrahepatic portosystemic shunt: an update. *Am J Roentgenol*, 2012; 199: 746-55
- Semiz-Oysu A, Keussen I, Cwikiel W: Interventional radiological management of prehepatic obstruction of [corrected] the splanchnic venous system. *Cardiovasc Intervent Radiol*, 2007; 30: 688-95
- Ray MJ, Savage C, Klintmalm GB, Rees CR: Endovascular caudal retraction of the cranial end of a misplaced Viatorr TIPS prior to liver transplantation. *Proc (Bayl Univ Med Cent)*, 2012; 25: 341-43
- Cohen GS, Ball DS: Delayed Wallstent migration after a transjugular intrahepatic portosystemic shunt procedure: relocation with a loop snare. *J Vasc Interv Radiol*, 1993; 4: 561-63