

[Imaging]

Lisfranc Injury in a West Point Cadet

Angela R. Diebal, PT, DSc, OCS, SCS, ATC,*† Richard B. Westrick, PT, DSc, OCS, SCS,†‡
Curtis Alitz, MD,§ and J. Parry Gerber, PT, PhD, SCS, ATC†

Background: Lisfranc joint injuries are fairly uncommon; however, few injuries hold such an elevated potential for devastating chronic secondary pain and disability. It is imperative when evaluating an injury to the ankle or foot to have a high clinical index of suspicion for Lisfranc injury, as physical examination findings are often subtle.

Case Description: An 18-year-old military cadet reported to a direct-access sports physical therapy clinic with foot pain. Despite negative radiographic findings, there was a high suspicion for Lisfranc injury based on the injury mechanism and physical examination. A computed tomography scan demonstrated an oblique fracture through the base of the third metatarsal, a small marginal fracture at the plantar base of the second metatarsal, and a subtle diastasis. Two days following his injury, he underwent an open reduction and internal fixation, completed subsequent rehabilitation, and returned to full activity approximately 1 year following injury.

Conclusion: Early diagnosis of Lisfranc injuries is imperative for proper management and prevention of a poor functional outcome. If a strong clinical suspicion exists, negative radiographic findings are insufficient to rule out a Lisfranc injury, and therefore, advanced imaging is required.

Keywords: Lisfranc; foot sprain; tarsometatarsal joint injury

Tarsometatarsal (TMT) joint injuries, also referred to as Lisfranc joint injuries, are fairly uncommon, occurring in only 1 of 55,000 individuals annually in the United States; however, few injuries hold such an elevated potential for devastating chronic secondary pain and disability.^{16,20,23,28} Approximately 20% of Lisfranc injuries are misdiagnosed or overlooked on initial examination, leading to improper initial management and an eventual poor functional outcome.^{9,28}

The TMT joint complex comprises the 3 cuneiforms, the cuboid, and the articulations with the 5 metatarsal bases. The Lisfranc joint consists of several dorsal, interosseous, and plantar ligaments. The interosseous ligaments are the strongest of the Lisfranc complex and join the second-through-fifth metatarsals. The Lisfranc ligament is the strongest and largest interosseous attachment connecting the first cuneiform and second metatarsal base.³ The intrinsic stability of the TMT joint is primarily based on the stable bony and capsuloligamentous relationships around the second metatarsal base, which resembles a Roman arch.^{1,22,28} The proximal end of the second metatarsal is securely recessed between the first and third cuneiforms, while the second cuneiform and second metatarsal articulation form the keystone of the arch, which prevents medial and lateral translation

(Figures 1-3). Because of this inherent structural stability, the precise anatomic restoration of the joint and its maintenance should be the primary management goals for those unfortunate enough to sustain injury to the TMT joint.^{1,2,10,14,25} The following case outlines the injury mechanism, presentation, and treatment of a patient who sustained a Lisfranc joint injury.

CASE REPORT

An 18-year-old military cadet presented to physical therapy with acute foot pain 1 day after being tackled during a full-contact football game. The injury mechanism was described as a direct vertical force onto the calcaneus of a planted and plantarflexed foot (Figure 4). He walked into the physical therapy clinic without an assistive device but with a significant limp. He was unable to bear full weight through the foot without significant pain. Physical examination revealed midfoot edema and tenderness to palpation at the dorsal midfoot, with exquisite focal tenderness present at the base of the first, second, and third metatarsals and the first and second cuneiforms. The patient had increased pain in the TMT area with passive pronation and abduction stress to the forefoot.

From the †US Army–Baylor University Post Professional Sports Medicine–Physical Therapy Doctoral Residency, West Point, New York, ‡Regis University Orthopedic Manual Physical Therapy Fellowship, Denver, Colorado, and §Keller Army Community Hospital, West Point, New York

*Address correspondence to Angela R. Diebal, PT, DSc, OCS, SCS, ATC, Resident, US Army–Baylor University Post Professional Sports Medicine–Physical Therapy Doctoral Residency, 900 Washington Road, West Point, NY 10996 (e-mail: angie.diebal@us.army.mil).

The views expressed in this article are those of the authors and do not reflect the official policy or position of the US Government.

The authors report no potential conflicts of interest in the development and publication of this manuscript.

DOI: 10.1177/1941738113477991

© 2013 The Author(s)

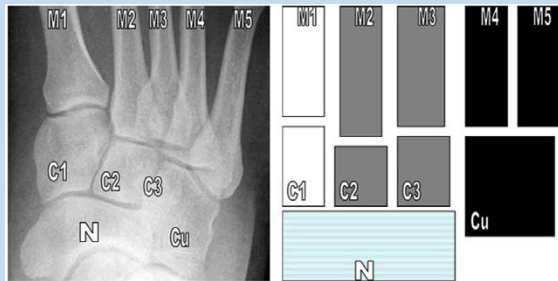


Figure 1. Normal anteroposterior radiograph and schematic of the osseous relationships of the Lisfranc joint. Note how M2 is recessed in a mortise formed by C1 and C3. White shading indicates the medial column; gray, the middle column; and black, the lateral column. C1, first (medial) cuneiform; C2, second (middle) cuneiform; C3, third (lateral) cuneiform; Cu, cuboid; M1, first metatarsal; M2, second metatarsal; M3, third metatarsal; M4, fourth metatarsal; M5, fifth metatarsal; N, navicular. Reprinted from Hatem¹¹ with permission.

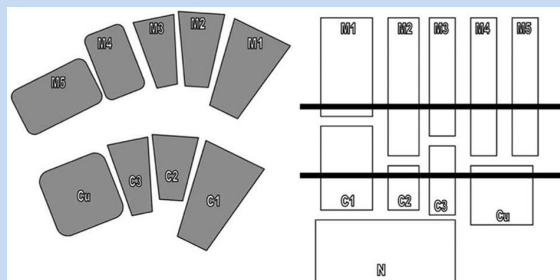


Figure 2. Asymmetric Roman arch of the tarsometatarsal region in the short axis. Note the keystone position of the second metatarsal (M2) and cuneiform (C2). Also note how an image slice between these variably includes both cuneiforms and metatarsal bases. On cross-sectional imaging, cross-referencing using a longitudinal plane allows confident localization. Reprinted from Hatem¹¹ with permission.

Standard radiographs and weightbearing images demonstrated normal results; a computed tomography (CT) scan or magnetic resonance imaging (MRI) was indicated on the basis of continued clinical suspicion of Lisfranc injury (Figures 5 and 6).^{4,24} CT is more useful for preoperative planning and for detecting small bony avulsions, while MRI is useful in assessing the Lisfranc ligament.^{3,4,11} This patient's CT scan showed an oblique fracture through the base of the third

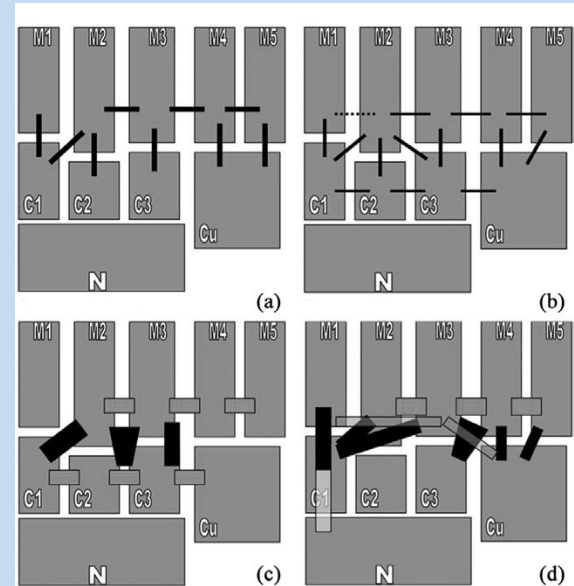


Figure 3. Ligamentous constraints. (a) Simplified approach to the Lisfranc ligamentous constraints emphasizes absence of M1-M2 intermetatarsal ligament and presence of C1-M2 Lisfranc ligament. (b) Dorsal ligaments are thinner and weaker than the interosseous and plantar ligaments. Insignificant M1-M2 ligaments are occasionally identified (dashed line). (c) Interosseous ligaments, including the C1-M2 Lisfranc ligament, are substantial on gross inspection and mechanical evaluation. (d) Plantar ligaments are also substantial. The plantar C1-M2M3 ligament is an important contributor to Lisfranc stability. Refer to the text for a detailed description. Solid lines in figures b through d indicate tarsometatarsal ligaments, the grid indicates intermetatarsal ligaments, stripes indicate intertarsal ligaments, and dashes indicate an inconstant relationship. Reprinted from Hatem¹¹ with permission.

metatarsal, a small marginal fracture at the plantar base of the second metatarsal, and a subtle diastasis (Figure 7).¹⁵ To restore and maintain structural integrity of the TMT joint, a TMT open reduction internal fixation was performed 2 days later (Figure 8).

His postoperative management consisted of strict immobilization (cast) and crutch ambulation (nonweightbearing) for 6 weeks, followed by immobilization in a protective boot and crutch ambulation (progressive weightbearing) for 4 weeks. The patient then transitioned to full weightbearing using carbon fiber footplate inserts for 2 weeks. Twelve weeks following stabilization, the surgical hardware was removed. The patient then performed ankle/




Figure 4. The injury mechanism: direct vertical force onto the calcaneus of a planted and plantarflexed foot.

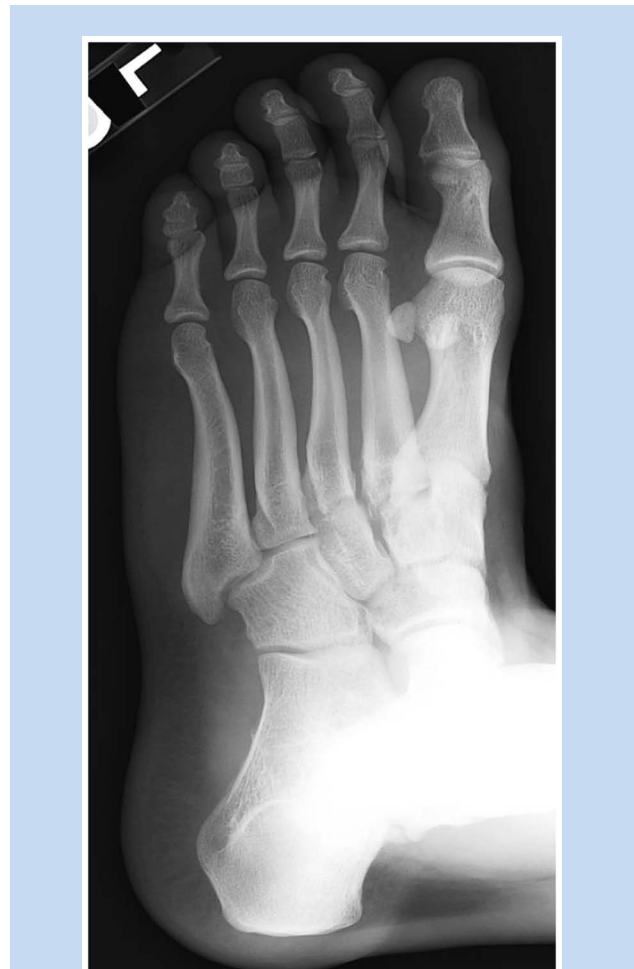

Figure 5. Oblique weightbearing radiograph of the left foot without evidence of fracture or other abnormality.

foot range of motion and strengthening exercises and was allowed to progress with biking, swimming (following wound closure), and the elliptical machine. At approximately 6 months postsurgery, he was able to run, and by 8 months, he ran 3 miles with minimal pain complaints. He returned to limited sports participation (lacrosse) by 1 year and full activity 15 months postsurgery.

DISCUSSION

Lisfranc joint injuries occur from 2 basic mechanisms. Direct force injuries occur from a crushing mechanism (ie, crushed by a vehicle or a weight dropped onto the dorsum of the foot).^{1,5,9,10,13,18} Indirect injuries are most common and occur from forefoot abduction and plantarflexion forces to the TMT joint.¹ This may occur when an athlete plants the cleated foot and turns quickly or if an equinus force is placed through the TMT joint of the fixed foot.^{7,12} The plantarflexion injury mechanism occurs as a result of an axial load through the

hindfoot in a fixed foot, which may occur when a football player lands on the heel of another player whose foot is planted and plantarflexed.²⁶ Lisfranc injuries occur in a spectrum of anatomic variations, and in an effort to properly capture the injury possibilities, classification systems were developed (Table 1).^{3,10,11,18,21}

Diagnosis of a Lisfranc injury is made by a combination of history, physical, and radiographic examinations. The most common findings/symptoms are pain, edema, tenderness over the TMT joint, and ecchymosis at the plantar aspect of the midfoot.⁷⁻⁹ Plantar ecchymosis denotes substantial soft tissue disruption and is suggestive of a Lisfranc injury until proven otherwise.⁶ Increased pain with passive abduction and pronation of the forefoot is specific for TMT injury.^{17,26} Toe gait is impossible, and the patient is typically unable to bear weight secondary to significant pain.^{9,26}

When clinical suspicion exists, immediate use of imaging is warranted since delayed diagnosis is associated with increased morbidity.^{4,6,27} Routine radiographs of the foot

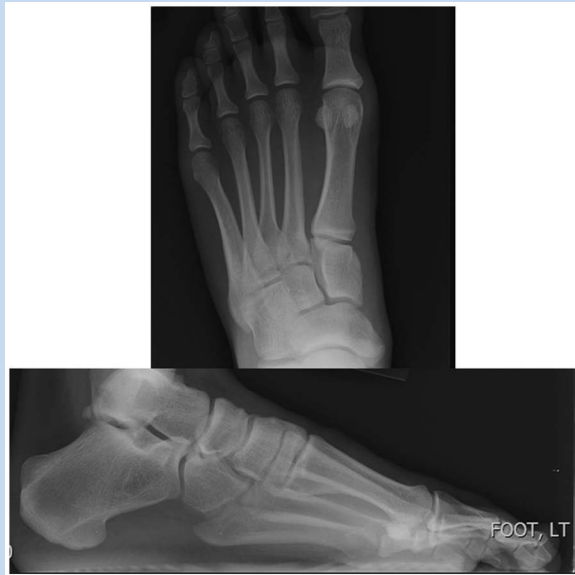

Figure 6. Lateral and anteroposterior weightbearing radiographs of the left foot, without evidence of fracture or other abnormality.

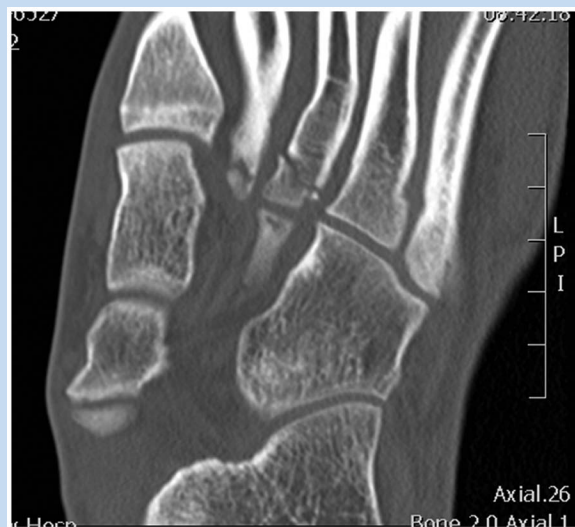

Figure 7. Computed tomography scan axial view of the left foot demonstrating an oblique fracture through the base of the third metatarsal, with extension into the proximal third metatarsal articular surface. A small marginal fracture is also noted at the plantar base of the left second metatarsal.

are often insufficient to detect a Lisfranc injury and may be read as normal in up to 20% to 50% of cases.^{19,28} Standing weightbearing radiographs, if tolerated, are strongly

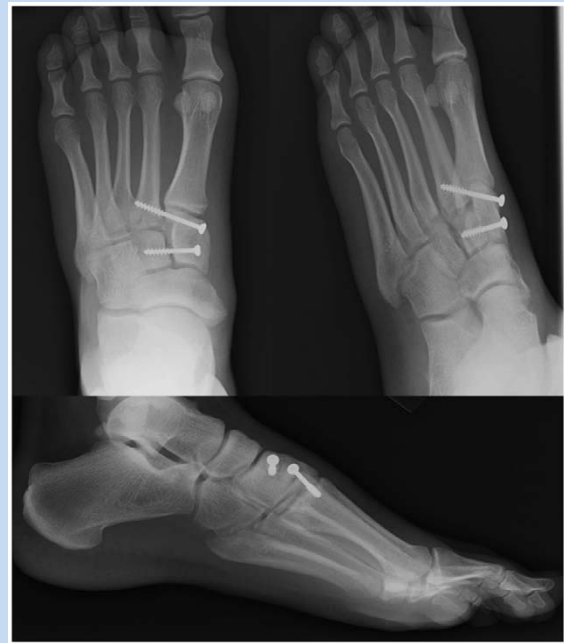

Figure 8. Oblique, lateral, and anteroposterior weightbearing radiographs of the left foot status post–medial midfoot fixation. No evidence of hardware complication.

recommended since they will help emphasize deformities, especially a subtle Lisfranc diastasis.^{6,15,26} Weightbearing images with both feet on a single cassette or a stress view with the forefoot in abduction and pronation may improve sensitivity.^{26,28} CT is superior to MRI for diagnosis and making clinical decisions.²⁶ MRI can be used to assess the Lisfranc ligament and evaluate midfoot soft tissues, especially in low-impact Lisfranc injuries.^{3,11}

If not treated properly and swiftly, midfoot injuries have numerous complications: vascular impairment, skin necrosis, osteoarthritis, nonunion, chronic pain, and chronic instability.^{10,22,25,28} Kuo et al evaluated patient outcome at an average of 52 weeks—status post–open reduction, internal fixation—and found that the main determinant of a good outcome was anatomic reduction.¹⁴

CONCLUSION

Early diagnosis of Lisfranc injuries is imperative for proper management and prevention of a poor functional outcome.¹⁵ These injuries range from a simple sprain to a complete fracture/dislocation through the TMT region and are commonly caused by an axial load through the calcaneus or a twisting/hyperplantarflexion stress applied to the midfoot.¹⁶ If a strong clinical suspicion exists, advanced imaging (ie, CT scan or MRI) may be needed.^{6,15}

Table 1. Classification of Lisfranc injuries

Year	Authors	Classification System
1909	Quenu and Kuss ²¹	Homolateral Isolated Divergent
1982	Hardcastle et al ¹⁰	<i>Type A:</i> Total incongruity of the tarsometatarsal joint—either lateral or dorsoplantar <i>Type B:</i> Partial incongruity—medial or lateral dislocation <i>Type C:</i> Divergent—total or partial displacement
1986	Myerson et al ¹⁸	<i>Type A:</i> Total incongruity of the tarsometatarsal joint—lateral or dorsoplantar <i>Type B1:</i> Medial dislocations—first ray in isolation with or without medial cuneiform displacement <i>Type B2:</i> Lateral dislocations—involving any of the 4 lateral metatarsals <i>Type C1:</i> Partial displacement—medial and middle columns <i>Type C2:</i> Total displacement—involving all metatarsals with the medial column displaced medially and the middle and lateral columns displaced laterally

REFERENCES

- Arntz CT, Hansen ST. Dislocation and fracture dislocations of the tarsometatarsal joints. *Orthop Clin North Am.* 1987;18:105-114.
- Arntz CT, Veith RG, Hansen ST. Fractures and fracture dislocations of the tarsometatarsal joint. *J Bone Joint Surg Am.* 1988;70:173-181.
- Benirschke SK, Meinberg E, Anderson SA, Jones CB, Cole PA. Fractures and dislocations of the midfoot: Lisfranc and Chopart injuries. *J Bone Joint Surg Am.* 2012;94:1326-1337.
- Bennett DL, Daffner RH, Weissman BN, et al. Acute trauma to the foot. <http://www.acr.org/~media/ACR/Documents/AppCriteria/Diagnostic/AcuteTraumaFoot.pdf>. Published 2010.
- Buzzard BM, Briggs PJ. Surgical management of acute tarsometatarsal fracture dislocation in the adult. *Clin Orthop Relat Res.* 1998;353:125-133.
- Coetzee JC. Making sense of Lisfranc injuries. *Foot Ankle Clin.* 2008;13:695-704.
- Curtis MJ, Myerson M, Szura B. Tarsometatarsal joint injuries in the athlete. *Am J Sports Med.* 1993;21(4):497-502.
- Davies MS, Saxby TS. Intercuneiform instability and the "gap" sign. *Foot Ankle Int.* 1999;20(9):606-609.
- Goosens M, Stoop N. Lisfranc's fracture-dislocations: etiology, radiology, and results of treatment. *Clin Orthop Relat Res.* 1983;176:154-162.
- Hardcastle PH, Reschauer R, Kutscha-Lissberg E, Schoffmann W. Injuries to the tarsometatarsal joint. *J Bone Joint Surg Br.* 1982;64(3):349-356.
- Hatem SF. Imaging of Lisfranc injury and midfoot sprain. *Radiol Clin North Am.* 2008;46:1045-1060.
- Hatem SF, Davis A, Sundram M. Your diagnosis? Midfoot sprain: Lisfranc ligament disruption. *Orthopedics.* 2005;28:75-77.
- Komenda GA, Myerson MS, Biddinger KR. Results of arthrodesis of the tarsometatarsal joints after traumatic injury. *J Bone Joint Surg Am.* 1996;78(11):1665-1676.
- Kuo RS, Tejwani NC, Digiovanni CW, et al. Outcome after open reduction and internal fixation of Lisfranc joint injuries. *J Bone Joint Surg Am.* 2000;82(11):1609-1618.
- Latterman C, Goldstein JL, Wukich DK. Practical management of Lisfranc injuries in athletes. *Clin J Sport Med.* 2007;17(4):311-315.
- Mantas JP, Burks RT. Lisfranc injuries in the athlete. *Clin Sports Med.* 1994;13(4):719-730.
- Myerson MS. The diagnosis and treatment of injury to the tarsometatarsal joint complex. *J Bone Joint Surg Br.* 1999;81:756-763.
- Myerson MS, Fisher RT, Burgess AR, Kenzora JE. Fracture dislocations of the tarsometatarsal joints: End results correlated with pathology and treatment. *Foot Ankle.* 1986;6(5):225-242.
- Nunley JA, Vertullo CJ. Classification, investigation, and management of midfoot sprains: Lisfranc injuries in the athlete. *Am J Sports Med.* 2002;30(6):871-878.
- Perron AD, Brady WJ, Keats TE. Orthopedic pitfalls in the ED: Lisfranc fracture-dislocation. *Am J Emerg Med.* 2001;19(1):70-75.
- Quenu E, Kuss G. [Study on the dislocations of the metatarsal bones (tarsometatarsal dislocations) and diastasis between the 1st and 2nd metatarsal]. *Rev Chir.* 1909;39:281-336, 720-291, 1093-1134.
- Rosenbaum A, Dellenbaugh S, DiPrea J, Uhi R. Subtle injuries to the Lisfranc joint. *Orthopedics.* 2011;34(11):882-887.
- Saab M. Lisfranc fracture-dislocation: an easily overlooked injury in the emergency department. *Eur J Emerg Med.* 2005;12:143-146.
- Stiell IG, Greenberg GH, McKnight RD, Nair RC, McDowell I, Worthington JR. A study to develop clinical decision rules for the use of radiography in acute ankle injuries. *Ann Emerg Med.* 1992;21(4):384-390.
- Talarico RH, Hamilton GA, Ford LA, Rush SM. Fracture dislocations of the tarsometatarsal joints: analysis of interrater reliability in using the modified hardcastle classification system. *J Foot Ankle Surg.* 2006;45(5):300-303.
- Thompson MC, Mormino MA. Injury to the tarsometatarsal joint complex. *J Am Acad Orthop Surg.* 2003;11(4):260-267.
- Wadsworth DJ, Eadie NT. Conservative management of subtle Lisfranc injury: a case report. *J Orthop Sport Phys.* 2005;35(3):154-164.
- Watson TS, Shurnas PS, Denker J. Treatment of Lisfranc joint injury: current concepts. *J Am Acad Orthop Surg.* 2010;18(12):718-728.

For reprints and permission queries, please visit SAGE's Web site at <http://www.sagepub.com/journalsPermissions.nav>.