

Autologous Tricortical Iliac Bone Graft for Failed Latarjet Procedures



Maximiliano Ranalletta, M.D., Ignacio Tanoira, M.D., Agustin Bertona, M.D., Gaston Maignon, M.D., Santiago Bongiovanni, M.D., and Luciano A. Rossi, M.D.

Abstract: The high recurrence rates seen in open and arthroscopic Bankart repair in the presence of significant glenoid bone loss, Hill-Sachs lesions, or combined bony deficiencies have led many surgeons to choose bony reconstructions to manage these injuries. Although the Latarjet procedure has proved to be reliable to manage recurrent anterior shoulder instability, there have been concerns of a higher surgical complication rate associated with this procedure. Moreover, some of the complications reported with this procedure such as symptomatic implants, fracture or nonunion of the coracoid graft, and recurrence of instability could need a revision surgery to be solved. The autologous tricortical iliac bone graft is an excellent option for failed bony reconstructions. However, as with any successful surgery, each step requires planning and precise application to limit risks and avoid pitfalls. This Technical Note provides a detailed description of the autologous tricortical iliac bone graft for failed Latarjet procedures.

Recurrent glenohumeral instability is associated with a soft tissue injury to the anterior capsulolabral complex, known as a Bankart lesion. However, analysis of failed capsulolabral repair procedures has demonstrated the important role of bone lesions.^{1,2} Glenoid bone defects and humeral bone defects are seen in up to 90% and 100% of recurrent dislocations.^{3,4} The optimal management of recurrent anterior shoulder instability with significant glenoid bone loss continues to be a challenge. The high recurrence rates seen in open and arthroscopic Bankart repair in the presence of significant glenoid bone loss, Hill-Sachs lesions, or combined bony deficiencies have led many surgeons to choose bony reconstructions to manage these injuries.⁵

Although the Latarjet procedure has proved to be reliable to manage recurrent anterior shoulder instability, there have been concerns of a higher surgical

complication rate associated with this procedure. A large recent review reported an overall complication rate in the open Latarjet procedure of 15%, with a 7% rate of unplanned reoperations.⁶

Augmentation of the anterior glenoid with a tricortical iliac crest graft has proved to be an effective option to manage patients with recurrent glenohumeral instability and glenoid bone loss.⁷⁻¹⁰ This procedure, however, is associated with a unique set of potential complications and failures such as limitation of external rotation, postoperative degenerative changes, bone graft osteolysis, and nonunion. Surgeons must be aware of the complications related to this surgical procedure to take appropriate intraoperative precautions to limit patient risks. This Technical Note reviews in detail each step of the surgery and highlights the key points to avoid complications and have a successful outcome.

From the Shoulder Unit, Hospital Italiano de Buenos Aires, Buenos Aires City, Argentina.

The authors report that they have no conflicts of interest in the authorship and publication of this article. Full ICMJE author disclosure forms are available for this article online, as [supplementary material](#).

Received October 10, 2018; accepted November 2, 2018.

Address correspondence to Luciano A. Rossi, M.D., Peron 4190 (C1199ABB), Buenos Aires, Argentina. E-mail: luciano.rossi@hospitalitaliano.org.ar

© 2018 by the Arthroscopy Association of North America. Published by Elsevier. This is an open access article under the CC BY-NC-ND license (<http://creativecommons.org/licenses/by-nc-nd/4.0/>).

2212-6287/181232

<https://doi.org/10.1016/j.eats.2018.11.002>

Surgical Technique

Anesthesia and Patient Positioning

All procedures are performed with ultrasound-guided interscalene block and general anesthesia. The patient is secured in a beach chair position with a pillow behind the scapula to place the glenoid surface perpendicular to the operating table. The shoulder is prepared and draped in the usual sterile fashion. The arm should remain free to allow for intraoperative manipulation of the upper extremity (Video 1).

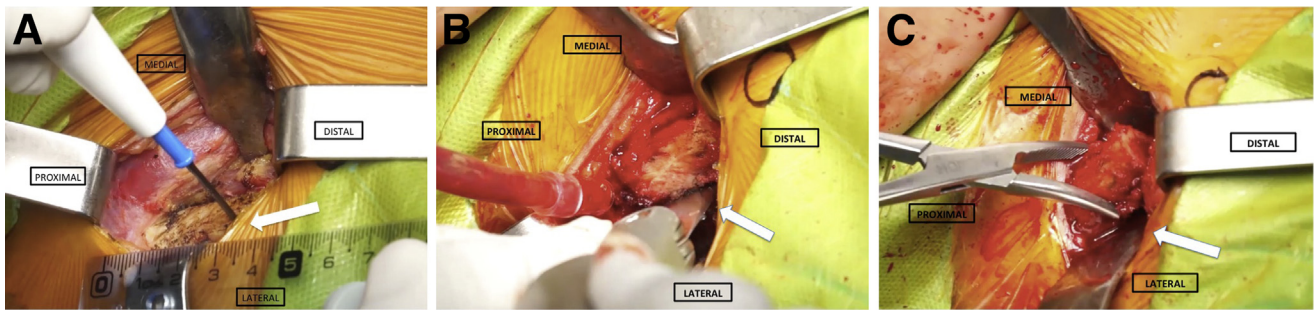


Fig 1. Patient is in the beach chair position, right shoulder. (A) The ipsilateral tricortical iliac crest bone graft can be prepared or harvested in the standard manner. The length of the graft is approximately 2 to 2.5 cm, and it can be measured with the help of a ruler before the cut (white arrow). (B) After the size calculation, the bone graft is cut with a saw blade (white arrow). (C) The length of the graft is approximately 2 to 2.5 cm, based on the size and length of the defect (white arrow).

Harvesting of the Tricortical Iliac Bone Graft

The tricortical iliac crest bone graft can be prepared or harvested in the standard manner. The length of the graft is approximately 2 to 2.5 cm, based on the size and length of the defect. It must be large enough to fully reconstitute the bone defect and still allow for some resorption of the graft over time. This step can be facilitated using specialized drill guides (South American Implants). The guide can be used to calculate the distance between the screws and serves as a guide for evaluating the size of the graft. After the size calculation, the bone graft is cut with a saw blade (Fig 1).

Preparation of the Iliac Bone Graft

The next step is to drill the holes for screw fixation. Grasp the iliac bone graft with the grasping drill guide. Position the guide on the graft with clearance slots adjacent to the surface of the graft that will eventually be in contact with the glenoid. The drill guide allows the drilling of 2 parallel 4-mm holes through the graft. It is important to ensure that the holes are centered on the graft and perpendicular to the prepared surface (Fig 2).

Surgical Approach: Glenoid Exposure and Preparation

A small standard deltopectoral approach is used (Fig 3). The skin is incised 5 to 7 cm starting under the tip of the coracoid process extending distally along the deltopectoral interval to the superior aspect of the axillary fold. The deltopectoral interval is opened, and the cephalic vein is taken laterally with the deltoid. One self-retaining retractor is placed in the deltopectoral interval, and the subscapularis muscle is exposed. With the upper limb in external rotation, the subscapularis muscle is divided horizontally in line with the fibers at the two-thirds superior, one-third inferior junction to expose the anterior capsule that is divided in the same manner (Fig 4). Palpate the biceps before starting the cut and start the incision just medial to the bicipital groove. Next the arm is positioned in internal rotation, and a Fukuda retractor (South American Implants) is

inserted that rests on the posterior margin of the glenoid. The superior two-thirds of the subscapularis are retracted superiorly and maintained in that position with a Steinman pin impacted at the superior part of the scapular neck. The inferior part of the subscapularis is retracted inferiorly with a Hohmann retractor (South American Implants) pushed under the neck of the scapula. This maneuver completely exposes the antero-inferior border of the scapula. At this point, the screws used in the previous surgery are removed (Fig 5). Next the remains of the coracoid graft and capsulolabral tissue are resected. It is important to remove anchors and sutures from previous surgeries that could interfere with proper bone consolidation of the graft. The anterior glenoid neck is then decorticated with a saw blade to be the recipient bed for the autologous tricortical iliac bone graft (Fig 6). The anterior glenoid neck is prepared with microfractures performed with a 2-mm pin to stimulate bleeding and promote graft consolidation (Fig 7).

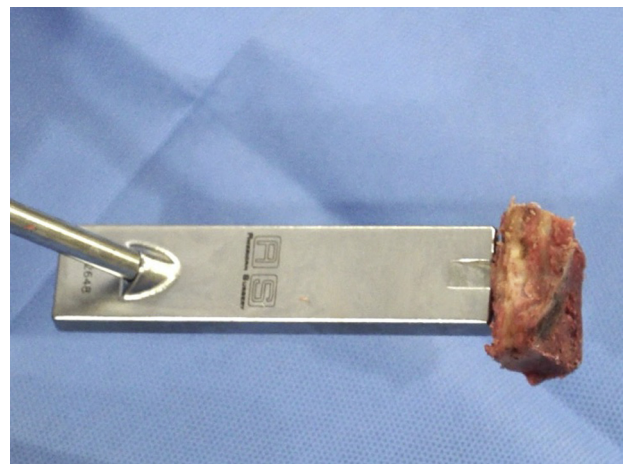


Fig 2. Patient is in the beach chair position, right shoulder. The drill guide allows the drilling of 2 parallel 4-mm holes through the graft. It is important to ensure that the holes are centered on the graft and perpendicular to the prepared surface.

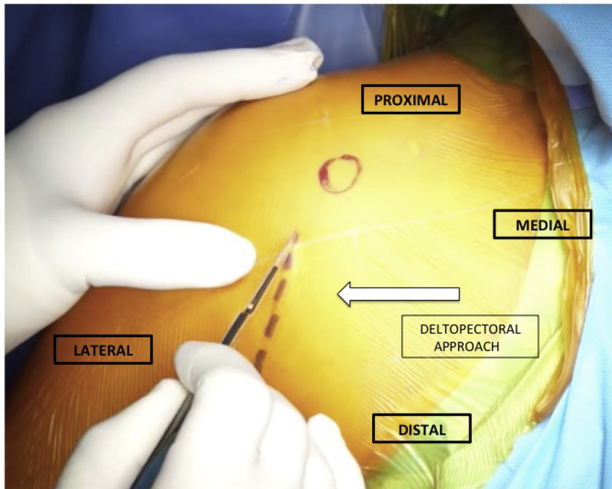


Fig 3. Patient is in the beach chair position, right shoulder. A small standard deltopectoral approach is used (white arrow). The skin is incised 5 to 7 cm starting under the tip of the coracoid process extending distally along the deltopectoral interval to the superior aspect of the axillary fold.

Fixation of the Tricortical Iliac Bone Graft With Screws

Proper position of the iliac bone graft relative to the glenoid is critical. The objective of iliac graft positioning is for the graft to be placed flush with the glenoid articular surface. Placement of the bone graft too far laterally leads to an increased rate of postoperative degenerative arthritis. However, fixation of the graft too far medially places the shoulder at increased risk for recurrent subluxation or dislocation. The pegs on the parallel drill guide mate with the predrilled holes on the iliac graft, facilitating easy control and positioning of the iliac graft onto the glenoid (Fig 8). Two 1.6-mm wires are passed through the drill guide directly through the guide, graft, and glenoid. The parallel drill guide is removed, leaving both wires in place. A 2.75-mm cannulated drill is used to penetrate the near cortex of the native glenoid prior to

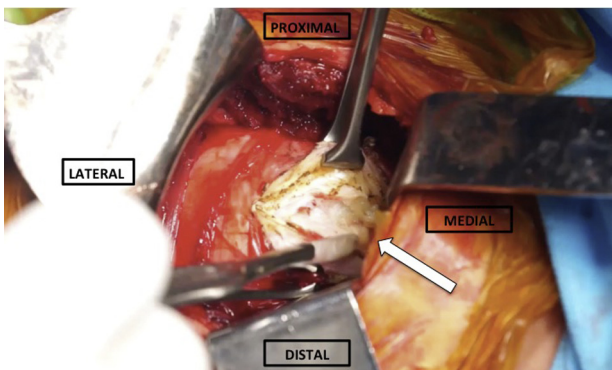


Fig 4. Patient is in the beach chair position, right shoulder. The subscapularis muscle is divided horizontally in line with the fibers at the two-thirds superior, one-third inferior junction to expose the anterior capsule that is divided in the same manner (white arrow).

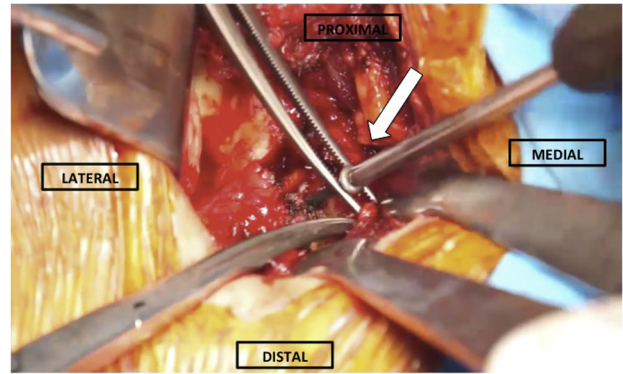


Fig 5. Patient is in the beach chair position, right shoulder. The screws used in the previous surgery are removed so that they do not interfere with bone consolidation (white arrow).

screw insertion. After that, 2 partially threaded, cannulated, self-tapping, 3.75-mm titanium screws are inserted (Figs 9-11).

Wound Closure

We do not perform capsulolabral repair in any patient. The wound is copiously irrigated and closed in a standard layered fashion. The deltopectoral interval is approximated in an interrupted fashion with No. 0 Vicryl (Ethicon, Somerville, NJ). The subcutaneous dermal layer is then closed with interrupted No. 2-0 Monocryl (Ethicon) followed by a running subcuticular stitch with No. 3-0 Monocryl and Steri-Strips (3M, St. Paul, MN) to allow for improved cosmesis. A postoperative dressing is applied in a sterile fashion followed by the application of a sling. Tips and pearls of our procedure are summarized in Table 1, whereas advantages and disadvantages are summarized in Table 2.

Postoperative Rehabilitation

The arm is supported with a sling for 4 weeks. After 1 week, supervised gentle physical therapy consisting of passive pendulum and gradual passive range of motion (ROM) exercises are begun. Active-assisted ROM

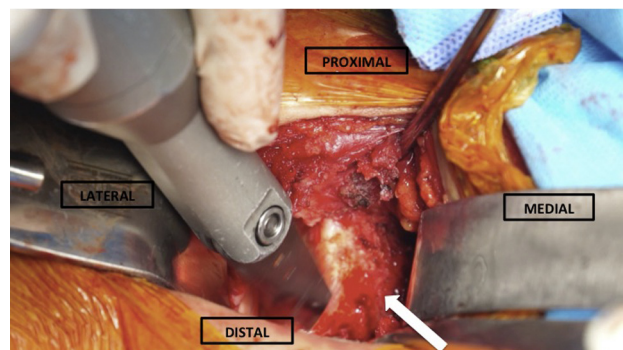


Fig 6. Patient is in the beach chair position, right shoulder. The anterior glenoid neck is decorticated with a saw blade (white arrow).

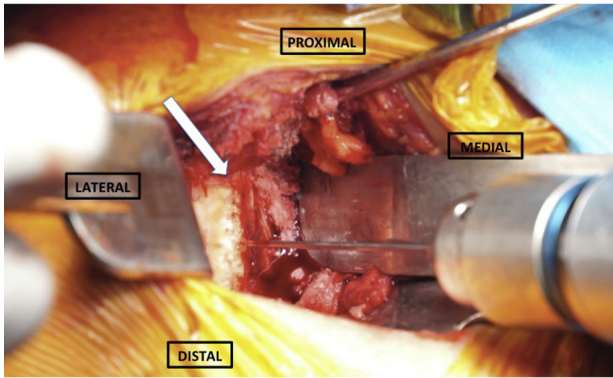


Fig 7. Patient is in the beach chair position, right shoulder. The anterior glenoid neck is prepared with microfractures performed with a 2-mm pin to stimulate bleeding and promote graft consolidation (white arrow).

exercises are started 2 weeks after surgery. When the patient can perform active forward elevation above the shoulder level, strengthening exercises are started. Running is authorized at 8 weeks. Return to sports is allowed when the patient is pain free, full shoulder ROM is achieved, and shoulder strength is near the same as before the injury.

Discussion

The optimal management of recurrent anterior shoulder instability with significant glenoid bone loss continues to be a challenge. The high recurrence rates seen in open and arthroscopic Bankart repair in the presence of significant glenoid bone loss, Hill-Sachs lesions, or combined bony deficiencies have led many

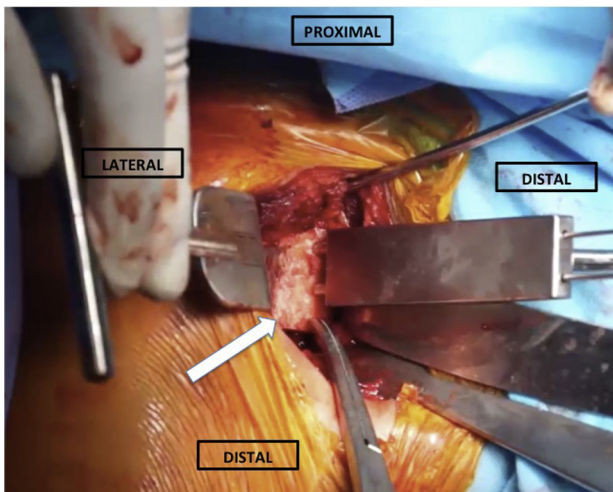


Fig 8. Patient is in the beach chair position, right shoulder. The pegs on the parallel drill guide mate with the predrilled holes on the iliac graft, facilitating easy control and positioning of the iliac graft onto the glenoid. Two 1.6-mm wires are passed through the drill guide directly through the guide, graft, and glenoid (white arrow).

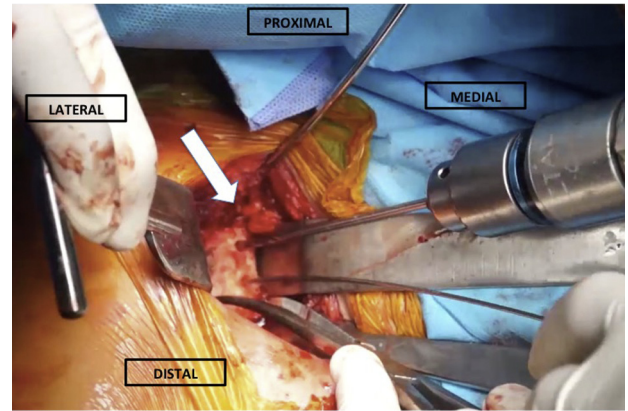


Fig 9. Patient is in the beach chair position, right shoulder. A 2.75-mm cannulated drill is used to penetrate the near cortex of the native glenoid prior to screw insertion (white arrow).

surgeons to choose bony reconstructions to manage these injuries.⁵

Bone loss compromises the function of the glenoid vault as part of the concavity-compression mechanism. The loss of functional arc diminishes the ability of the glenoid to resist axial forces and increases the shear force on the capsulolabral repair.² A biomechanical study indicated that bone defects comprising 21% to 30% of the glenoid fossa substantially decrease glenohumeral stability.¹¹ Similar values have been reported in clinical studies.^{2,3} However, even glenoid bone loss as low as 13.5% has been associated with unacceptable clinical outcomes in a young, active population.¹²

Given the improved understanding of instability and failure rates, bony procedures are on the rise. The Latarjet surgery is the most widespread. Three processes work together to augment anterior shoulder instability, resulting in a “triple-blocking” effect. First, the bony coracoid block extends the glenoid rim, serving as a static restraint that improves the “safe arc” available for translation before dislocation (bony effect). Second, the conjoined tendon acts as a sling over the humerus,

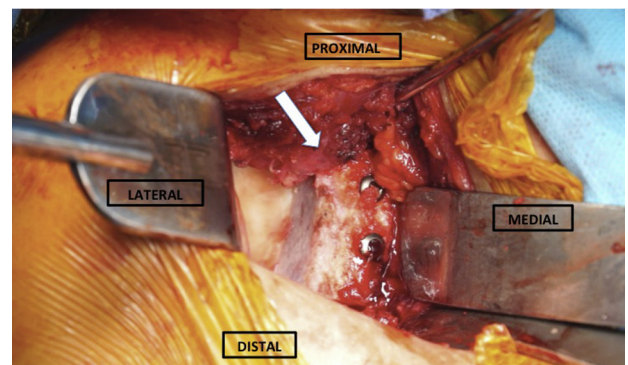


Fig 10. Patient is in the beach chair position, right shoulder. Two 3.75-mm partially threaded, cannulated, self-tapping, titanium screws are inserted to fix the graft to the glenoid (white arrow).

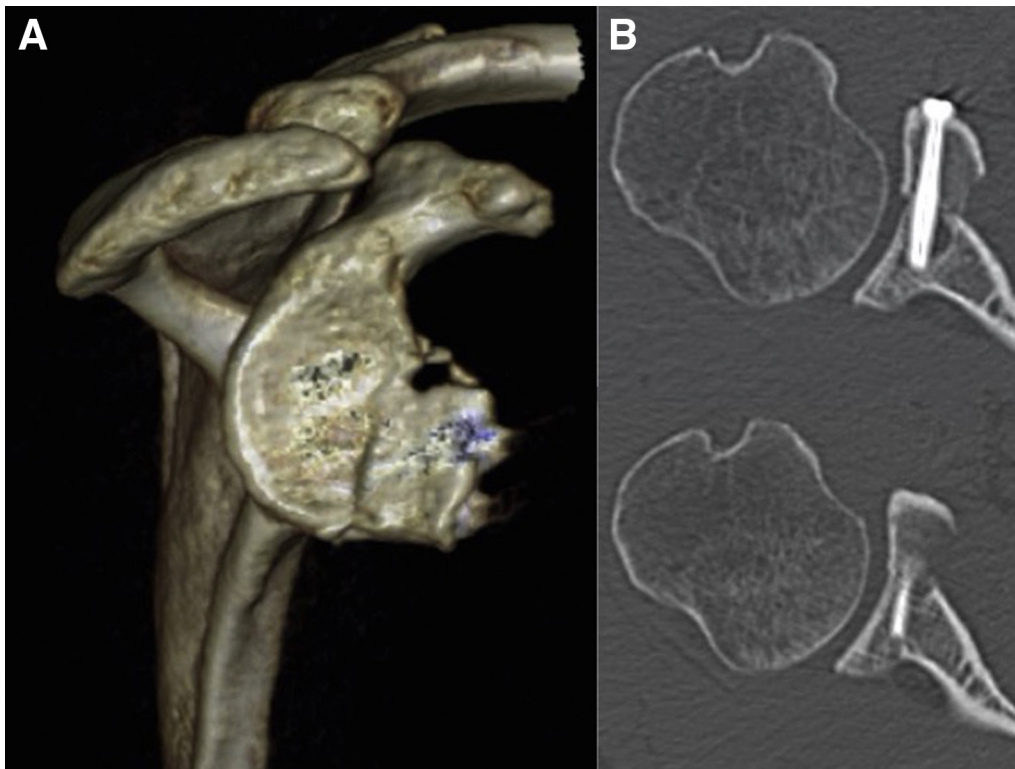


Fig 11. (A) Postoperative 3-dimensional computed tomography coronal view of the right shoulder showing the consolidation of the iliac graft 3 months after surgery. (B) Postoperative computed tomography axial view of the right shoulder showing the consolidation of the iliac graft 3 months after surgery.

resisting anterior translation when the arm is abducted and externally rotated (sling effect). Third, the labrum and anterior capsule are reattached to the glenoid rim and are reinforced with the coracoacromial ligament (bumper effect).¹³

Although the results published with the Latarjet procedure in athletes are encouraging, there is concern over the potential complications associated with these nonanatomic procedures.¹⁴⁻¹⁶ The most common complications include infection, frozen shoulder, hematoma formation, symptomatic implants, fracture or nonunion of the coracoid graft, neurologic complications, arthritis, and recurrence of instability.^{16,17} However, a large recent

review reported an overall complication rate in the open Latarjet procedure of 15%, with 7% of patients requiring an unplanned reoperation following surgery.⁶

Iliac crest graft procedures appear as an option for failed previous Latarjet surgeries. Eden and Hybinette are credited with the first description of free autologous bone grafts in anterior glenoid rim reconstruction.^{18,19} Iliac crest graft reconstruction is biomechanically less advantageous than coracoid transfer procedures because of the absence of a sling effect. However, iliac crest grafts have successfully been used to restore stability in high-risk populations and as a revision method after failed Bristow-Latarjet procedures.^{20,21}

Table 1. Tips and Pearls

Tips	Pearls
A graft of 2.5-3 cm is desirable. This allows the placement of 2 screws separated by 1 cm without risks.	Proper positioning of the iliac graft relative to the glenoid is critical: the pegs on the parallel drill guide allow for easy positioning of the coracoid graft onto the glenoid.
The guide can be used to calculate the distance between the screws and serve as a guide for evaluating the size of the graft.	The optimal position is between the 3- and 5-o'clock positions flush with the articular surface.
It is important to remove anchors and sutures from previous surgeries that could interfere with proper bone consolidation of the graft.	Placement of the bone graft too far laterally leads to an increased rate of postoperative degenerative arthritis. However, fixation of the graft too far medially places the shoulder at increased risk for recurrent subluxation or dislocation.
The anterior glenoid neck is first decorticated with a saw blade and then prepared with microfractures performed with a 2-mm pin to stimulate bleeding and promote graft consolidation.	

Table 2. Advantages and Disadvantages

Advantages	Disadvantages
Deltopectoral approach that is familiar to all shoulder surgeons.	The "sling effect" of a coracoid transfer is not available in the described procedure.
Adequate exposure glenoid defect.	Potential risk of complications associated with screws: loosening, breakage, and intra-articular penetration.
Wide availability of graft sizes.	Potential risk of iatrogenic nerve injury.
If it is properly prepared, the graft is large enough to fully reconstitute the lost bone and still allow for some resorption of the graft over time.	Potential for iliac crest bone graft harvest site complications.
Reliable option for all types of previous failed stabilization procedures.	
By not repairing the capsulolabral complex, the restriction of external rotation is avoided.	

Glenoid reconstruction by iliac crest graft has historically been associated with postoperative degenerative changes. However, a recent study found osteoarthritis progressed only by 1 stage in only 7 of 35 shoulders over an average of 9.2 years (range, 5-19 years) after iliac crest graft glenoid augmentation.⁸

Favorable long-term outcomes with autologous iliac crest graft have been reported. Rahme et al.²² reviewed 87 patients at a mean follow-up time of 29 years (range, 22-37 years). Rate of recurrence was 20%, and reoperation rate for instability was 9%. The Rowe shoulder score was good or excellent, and the global rate of osteoarthritis was 44%.²² Changes such as improved fixation of the grafts with screws and attention to the positioning of the graft have improved the procedure's results.^{8,23} Two recent systematic reviews on different glenoid bony augmentation procedures for chronic anterior shoulder instability confirmed that the Eden-Hybinette procedure had clinical outcomes very similar to those of the Bristow-Latarjet technique, with a lower rate of neurologic complications.^{24,25} It should be noted, however, that the harvest site morbidity causes 10% to 25% of complications (mainly chronic pain and dysesthesia of the lateral cutaneous femoral nerve).²⁶

Other free grafts have been described for glenoid reconstruction. Sayegh et al.²⁷ in a recent systematic review based on 8 studies that was focused on allografts reported a recurrence rate of 2.9% with 100% graft integration. No complications linked to the graft occurred, and results were good for functional outcomes. However, the small number of patients analyzed (61 patients) indicates that these results should be treated with caution. Allograft integration is usually considered to have a lower success rate than autograft integration, depending on how it has been preserved (fresh, cryopreserved, treated, irradiated).²⁷ Currently, the main limitations of allografts remain their availability from a tissue bank, their cost, and the risk of viral transmission. Fresh-frozen distal tibial allograft allows the benefits of a near anatomic chondral surface, but the long-term viability of this surface is not known.

Moreover, this graft is expensive, may not be readily available, and has the inherent risks of graft rejection and infection.^{28,29}

Similar to the arthroscopic Bristow-Latarjet procedure, an arthroscopic Eden-Hybinette procedure was developed to improve diagnostic and therapeutic accuracy and to minimize soft tissue dissection and scar formation.²¹ Additionally, free bone grafts can be introduced through the rotator interval without disturbing the subscapularis muscle.²⁹ Subscapularis injury, a known complication of anterior glenoid bone grafting, can lead to postoperative loss of motion and weakness. However, caution must be exercised regarding these results because bone-block arthroscopic procedures are technically demanding and the learning curve is important to get results similar to those of open procedures.³⁰⁻³³

In conclusion, the tricortical iliac bone graft procedure is a reliable option for failed operative Latarjet surgeries. This procedure, however, is associated with a unique set of potential complications and failures. It is important for the shoulder surgeon to know the potential complications associated with an incorrect surgical technique to avoid failures. This Technical Note reviews in detail each step of the surgery and highlights the key points to avoid complications and have a successful outcome.

References

1. Balg F, Boileau P. The instability severity index score: A simple pre-operative score to select patients for arthroscopic or open shoulder stabilisation. *J Bone Joint Surg Br* 2007;89:1470-1477.
2. Burkhart SS, De Beer JF. Traumatic glenohumeral bone defects and their relationship to failure of arthroscopic Bankart repairs: Significance of the inverted-pear glenoid and the humeral engaging Hill-Sachs lesion. *Arthroscopy* 2000;16:677-694.
3. Griffith JF, Antonio GE, Yung PS, et al. Prevalence, pattern, and spectrum of glenoid bone loss in anterior shoulder dislocation: CT analysis of 218 patients. *AJR Am J Roentgenol* 2008;190:1247-1254.
4. Widjaja AB, Tran A, Bailey M, Proper S. Correlation between Bankart and Hill-Sachs lesions in anterior shoulder dislocation. *ANZ J Surg* 2006;76:436-438.

5. Schrupf MA, Maak TG, Delos D, et al. The management of anterior glenohumeral instability with and without bone loss: AAOS exhibit selection. *J Bone Joint Surg Am* 2014;96(2):e12.
6. Domos P, Lunini E, Walch G. Contraindications and complications of the Latarjet procedure. *Shoulder Elbow* 2018;10(1):15-24.
7. Villatte G, Spurr S, Broden C, Martins A, Emery R, Reilly P. The Eden-Hybbinette procedure is one hundred years old! A historical view of the concept and its evolutions. *Int Orthop*, 10.1007/s00264-018-3970-3.
8. Steffen V, Hertel R. Rim reconstruction with autogenous iliac crest for anterior glenoid deficiency: Forty-three instability cases followed for 5-19 years. *J Shoulder Elbow Surg* 2013;22:550-559.
9. Lunn JV, Castellano-Rosa J, Walch G. Recurrent anterior dislocation after the Latarjet procedure: Outcome after revision using a modified Eden-Hybinette operation. *J Shoulder Elbow Surg* 2008;17:744-750.
10. Warner JJ, Gill TJ, O'Hollerhan JD, Pathare N, Millett PJ. Anatomical glenoid reconstruction for recurrent anterior glenohumeral instability with glenoid deficiency using an autogenous tricortical iliac crest bone graft. *Am J Sports Med* 2006;34:205-212.
11. Itoi E, Yamamoto N, Kurokawa D, Sano H. Bone loss in anterior instability. *Curr Rev Musculoskelet Med* 2013;6(1): 88-94.
12. Shaha JS, Cook JB, Song DJ, et al. Redefining "critical" bone loss in shoulder instability: Functional outcomes worsen with "subcritical" bone loss. *Am J Sports Med* 2015;43(7):1719-1725.
13. Young AA, Maia R, Berhouet J, Walch G. Open Latarjet procedure for management of bone loss in anterior instability of the glenohumeral joint. *J Shoulder Elbow Surg* 2011;20(2 suppl):S61-S69.
14. An VV, Sivakumar BS, Phan K, Trantalis J. A systematic review and meta-analysis of clinical and patient-reported outcomes following two procedures for recurrent traumatic anterior instability of the shoulder: Latarjet procedure vs. Bankart repair. *J Shoulder Elbow Surg* 2016;25:853-863.
15. Bhatia S, Frank RM, Ghodadra NS, et al. The outcomes and surgical techniques of the Latarjet procedure. *Arthroscopy* 2014;30:227-235.
16. Willemot LB, Elhassan BT, Verborgt O. Bony reconstruction of the anterior glenoid rim. *J Am Acad Orthop Surg* 2018;26(10):e207-e218.
17. Griesser MJ, Harris JD, McCoy BW, et al. Complications and re-operations after Bristow-Latarjet shoulder stabilization: A systematic review. *J Shoulder Elbow Surg* 2013;22:286-292.
18. Eden R. Zur operation der habituellen schulterluxation unter Mitteilung eines neues Verfahrens bei Abriss am inneren Pfamnnenrande. *Deutsch Zeitschrift für Chirurgie* 1918;144(3-4):269-280.
19. Hybinette S. De la transplantation d'un fragment osseux pour remedier aux luxations recidivantes de l'épaule: constations et resultats. *Acta Chir Scand* 1932;71:411-445.
20. Moroder P, Blocher M, Auffarth A, et al. Clinical and computed tomography- radiologic outcome after bony glenoid augmentation in recurrent anterior shoulder instability without significant glenoid bone loss. *J Shoulder Elbow Surg* 2014;23:420-426.
21. Bockmann B, Venjakob AJ, Gebing R, Reichwein F, Hagenacker M, Nebelung W. Bone grafts used for arthroscopic glenoid reconstruction restore the native glenoid anatomy. *Knee Surg Sports Traumatol Arthrosc* 2018;26(1):299-305.
22. Rahme H, Wikblad L, Nowak J, Larsson S. Long-term clinical and radiologic results after Eden-Hybbinette operation for anterior instability of the shoulder. *J Shoulder Elbow Surg* 2003;12:15-19.
23. Willems WJ. Reconstruction of glenoid bone defects in shoulder instability with autologous bone. *Curr Rev Musculoskelet Med* 2014;7:12-15.
24. Longo UG, Loppini M, Rizzello G, et al. Latarjet, Bristow, and Eden-Hybinette procedures for anterior shoulder dislocation: Systematic review and quantitative synthesis of the literature. *Arthroscopy* 2014;30:1184-1211.
25. Beran MC, Donaldson CT, Bishop JY. Treatment of chronic glenoid defects in the setting of recurrent anterior shoulder instability: A systematic review. *J Shoulder Elbow Surg* 2010;19:769-780.
26. Dimitriou R, Mataliotakis GI, Angoules AG, et al. Complications following autologous bone graft harvesting from the iliac crest and using the RIA: A systematic review. *Injury* 2011;42:S3-S15 (suppl 2).
27. Sayegh ET, Mascarenhas R, Chalmers PN, et al. Allograft reconstruction for glenoid bone loss in glenohumeral instability: A systematic review. *Arthroscopy* 2014;30:1642-1649.
28. Frank RM, Romeo AA, Richardson C, et al. Outcomes of Latarjet versus distal tibia allograft for anterior shoulder instability repair: A matched cohort analysis. *Am J Sports Med* 2018;46:1030-1038.
29. Frank RM, Romeo AA, Provencher MT. Glenoid reconstruction with distal tibia allograft for recurrent anterior shoulder instability. *Orthopedics* 2017;40(1): e199-e205.
30. Boileau P, Gendre P, Baba M, et al. A guided surgical approach and novel fixation method for arthroscopic Latarjet. *J Shoulder Elbow Surg* 2016;25(1):78-89.
31. Kalogrianitis S, Tsouparopoulos V. Arthroscopic iliac crest bone block for reconstruction of the glenoid: A fixation technique using an adjustable-length loop cortical suspensory fixation device. *Arthrosc Tech* 2016;5(6):e1197-e1202.
32. Fortun CM, Wong I, Burns JP. Arthroscopic iliac crest bone grafting to the anterior glenoid. *Arthrosc Tech* 2016;5(4):e907-e912.
33. Giannakos A, Vezeridis PS, Schwartz DG, Jany R, Lafosse L. All-arthroscopic revision Eden-Hybinette procedure for failed instability surgery: Technique and preliminary results. *Arthroscopy* 2017;33(1):39-48.