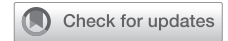

## ERECTILE DYSFUNCTION

# A Modified Surgical Technique for Reservoir Placement During Inflatable Penile Prosthesis Implantation



Ioannis Mykoniatis, MD, MSc,<sup>1</sup> Daniar Osmonov, MD, PhD,<sup>2</sup> and Koenraad van Renterghem, MD, PhD<sup>1,3,4</sup>

## ABSTRACT

**Introduction:** At the moment, there is an ongoing debate regarding the controversial issue of the ideal reservoir placement (RP) surgical technique during implantation of a 3-piece inflatable penile prosthesis, but a definitive winner has not yet emerged.

**Aim:** In this light, we herein describe our modified technique for RP into the space of Retzius through the external oblique muscle fascia and present its results.

**Methods:** In total, 253 inflatable penile prosthesis procedures (110 AMS 700 and 143 Coloplast Titan) via a single transverse penoscrotal incision were retrospectively reviewed. 2 Kocher-Langenbeck retractors were placed over the right side of the penoscrotal incision and were used to retract the incision superior to the pubic bone. Then, the external oblique muscle fascia was incised medially to the spermatic cord which was retracted laterally. Next, a “W”, Vicryl 1, stay suture was placed to the incision, and under direct visualization, external oblique muscle fibers were dissected and fascia transversalis was perforated using a Metzenbaum scissor. A Foerster lung grasping clamp was then used to dissect further into the extraperitoneal space and create the reservoir space. The reservoir was placed into the created space and fascia incision was closed using the prepositioned stay suture. The procedure was then completed in a standard fashion.

**Outcomes:** The main outcome measures were intraoperative or postoperative complications of our modified RP technique.

**Results:** All 253 patients were available for short-term follow-up (average 9.1 months, range 3–22 months). No intraoperative or postoperative complications were reported. Reservoir-related prolonged pain (1 month) was reported by 1 patient, resolving completely after treatment with non-steroidal analgesics.

**Conclusion:** We are, surely, not proposing that our modified RP technique should supplant all other methods; rather, it should be considered another useful option for RP in the implanter’s armamentarium. **Mykoniatis I, Osmonov D, van Renterghem K. A Modified Surgical Technique for Reservoir Placement During Inatable Penile Prosthesis Implantation. Sex Med 2020;8:378–382.**

Copyright © 2020, The Authors. Published by Elsevier Inc. on behalf of the International Society for Sexual Medicine. This is an open access article under the CC BY-NC-ND license (<http://creativecommons.org/licenses/by-nc-nd/4.0/>).

**Key Words:** Erectile Dysfunction; Penile Prosthesis; Reservoir Placement

## INTRODUCTION

The ideal reservoir placement (RP) surgical technique is probably the most controversial issue, at the moment,

Received March 10, 2020. Accepted April 5, 2020.

<sup>1</sup>Department of Urology, Jessa Hospital, Hasselt, Belgium;

<sup>2</sup>Department of Urology and Pediatric Urology, University Hospital Schleswig Holstein, Campus Kiel, Germany;

<sup>3</sup>Faculty of medicine, Hasselt University, Hasselt, Belgium;

<sup>4</sup>University Hospitals Leuven, Leuven, Belgium

Copyright © 2020, The Authors. Published by Elsevier Inc. on behalf of the International Society for Sexual Medicine. This is an open access article under the CC BY-NC-ND license (<http://creativecommons.org/licenses/by-nc-nd/4.0/>).

<https://doi.org/10.1016/j.esxm.2020.04.004>

regarding implantation of the 3-piece inflatable penile prosthesis (IPP) for the treatment of erectile dysfunction. The classic RP in the retropubic space of Retzius (SOR) through an extraperitoneal approach still remains the gold standard technique for men without previous abdominal surgery.<sup>1</sup> However, especially in men whose SOR has been compromised because of prior pelvic or abdominal surgery, rare but severe complications of this RP technique have been reported including bladder, vascular or bowel injuries, reservoir herniation, or intravesical/intrabdominal dislocation.<sup>2</sup> Moreover, in the era of robot-assisted radical prostatectomies and cystectomies resulting to an intraperitonealized “hostile” SOR anatomy, there has been an increasing trend of published studies reporting high efficacy and safety of “ectopic” or “alternative” RP methods,

such as intra-abdominal, high submuscular (HSM), or even subcutaneous, without compromising the functional or cosmetic result.<sup>3–5</sup> Thus, many implanters, empowered by these encouraging evidences along with the unquestionable innovations achieved in IPP design (new reservoir types and lockout valves), have adopted various ectopic RP methods as the standard of care for patients with prior pelvic surgery or even for cases of virgin pelvis.<sup>3,4</sup> Nevertheless, these alternative RP methods are surely not free of complications, and moreover, a recent multiinstitutional study did not report lower overall complication rates compared with classic technique of RP into the SOR.<sup>6</sup> So, it seems that a definitive winner, from the ongoing debate on the best RP method during IPP implantation, has not yet emerged. In this light, we herein describe our modified technique for RP into SOR through the external oblique muscle fascia and present its results in 253 patients.

## METHODS

In total, 253 IPP procedures (110 AMS 700 and 143 Coloplast Titan) via a transverse penoscrotal incision were retrospectively reviewed. A total of 78 patients (31%) have previously undergone major pelvic surgery. Procedures were carried out in a 3-year period (September 2016–September 2019) by a single high-volume surgeon (K.v.R.).

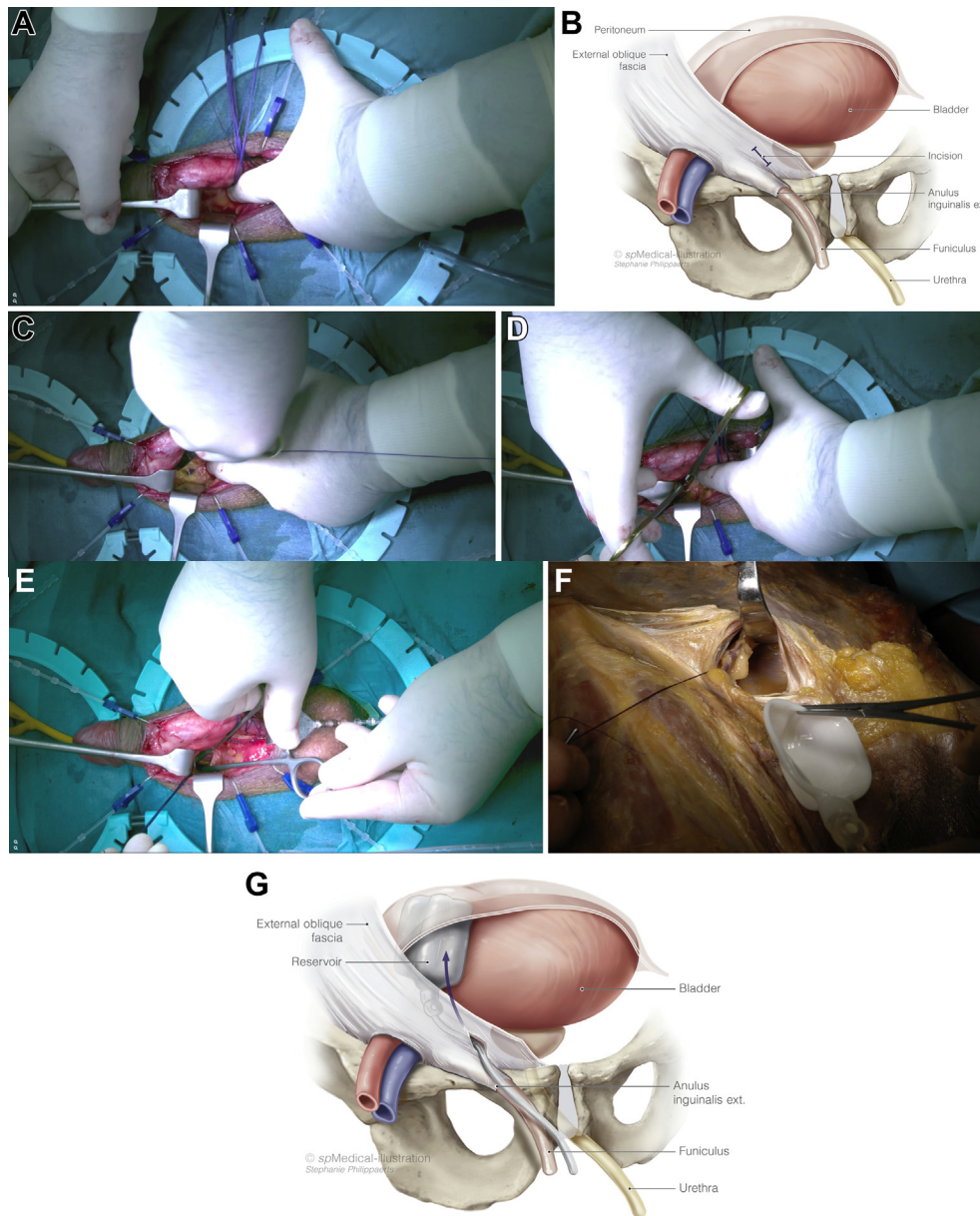
The modified RP method was conducted after the exposure, dilation, and measurement of corporal bodies and while IPP was prepped by a specialized nurse. 2 Kocher-Langenbeck retractors were placed over the right side of the penoscrotal incision and were used to retract the incision superior to the pubic bone. After palpating the pubic tubercle as anatomical landmark and the superficial layers dissection, retractors were slowly advanced, allowing for visualization of the external oblique muscle fascia, which was incised medially to the spermatic cord which was retracted laterally (Figure 1A and B). Then, a stay, Vicryl 1, suture was placed to the incision, to avoid strangulation of the tubing during the subsequent fascia closure, and the needle was cut off (Figure 1C). Then, under direct visualization, external oblique muscle fibers were dissected, and the fascia transversalis was perforated using a Metzenbaum scissor (Figure 1D). The index finger was firstly used for only initial dissection, and a Foerster lung grasping clamp was then used to dissect further into the extraperitoneal space and create the reservoir space (Figure 1E). Afterward, using the Foerster clamp, the reservoir was placed deep into the created space, and the fascia incision was closed using the prepositioned stay suture (Figure 1G and F). Then, the Kocher-Langenbeck retractors were removed. The reservoir was filled as determined by the surrogate reservoir test. The procedure was then completed in a standard fashion. A scrotal “mummy wrap”<sup>7</sup> and Foley catheter were used in all cases and removed on the first postoperative day.

## RESULTS

All 253 patients were available for short-term follow-up (average 9.1 months, range 3–22 months). Mean age of participants was 64.6 (standard deviation [SD] 8.73, range 31–78) years. Patients’ demographic and the preoperative characteristics are presented in Table 1. The mean operative time of total IPP placement (time duration was calculated from the penoscrotal incision until the scrotal “mummy wrap”) was 37.7 min (SD 9.4, range 25–89 min). Our modified RP technique was performed in a mean duration of 8.8 min (SD 1.6, range 6.7–21 min). The hospital length of stay for the vast majority of patients (239 of 253, 94.5%) was 1 day. The reasons for the 14 patients who had a prolonged hospitalization were not RP related (Table 2). In 10 of 253 patients, a synchronous artificial urinary sphincter placement was performed through the same single penoscrotal incision owing to coexisting severe urinary incontinence after radical prostatectomy. The pressure-regulation balloon was placed contralaterally in the SOR using the same technique. No RP-related intraoperative or postoperative complications (with only 1 exception) were reported. More specifically, no cases of bladder, bowel, blood vessel, spermatic cord, or nerve injury were reported. Moreover, not a single case of intravesical reservoir insertion, reservoir herniation, visibility, or palpability was recorded. Reservoir-related prolonged pain (1 month) was reported by 1 patient, resolving completely after treatment with non-steroidal analgesics.

## DISCUSSION

There is no doubt that ectopic and mainly HSM RP, by showing high safety and efficacy results but also an easy learning curve, could be a game changer during IPP placement especially for patients with a non-virgin pelvis.<sup>3,8</sup> On the contrary, there is still some scepticism about HSM RP regarding inadvertent malpositioning proven previously in a cadaver study, higher reservoir palpation rates and a possibly more challenging explantation process, in a potential need of revision, owing to the long distance between the reservoir and the penoscrotal incision.<sup>6,9</sup> Perito et al,<sup>10</sup> in an effort to preserve the advantages of ectopic RP while minimizing the palpability and hernia issues, proposed enhancements to the abdominal wall RP technique. The concept is based on cephalad RP either posterior to transversalis fascia or anterior to transversalis fascia through a penoscrotal or an infrapubic incision. The posterior to transversalis fascia reservoir insertion, between the transversalis fascia and peritoneum, is used in men with no history of significant pelvic surgery, whereas the anterior to transversalis fascia reservoir insertion, between the rectus abdominis musculature and transversalis fascia, is selected for cases in which extended pelvic surgery has preceded. The excellent safety results of these ectopic RP methods led authors to declare that have largely ceased using the classic RP into SOR even in men with unspoiled pelvic anatomy.<sup>4,11</sup> Moreover, subcutaneous RP has been proposed as a viable alternative RP



**Figure 1.** (A) Visualization of the external oblique muscle fascia. (B) Illustration showing the place of incision on the external oblique muscle fascia. (C) Stay suture placement to the incision. (D) External oblique muscle fibers dissection and fascia transversalis perforation by using a Metzenbaum scissor. (E) Reservoir space creation by using a Foerster lung grasping clamp. (F) Reservoir placement through the external oblique muscle fascia in a cadaver (Centre of Clinical Anatomy at the Anatomical Institute of the Christian-Albrechts University of Kiel). (G) Illustration showing the reservoir placement through the external oblique muscle fascia.

option for carefully selected obese men. Nevertheless, this approach was suggested only for those with high body mass index and a thick subcutaneous abdominal fat layer capable to conceal the reservoir because in thinner patients, the reservoir will be visible and/or palpable.<sup>12</sup>

Despite the encouraging results of ectopic RP techniques, classic RP into the SOR still remains the main choice for many implanters. We believe that the RP method we herein present, and which resulted in the aforementioned encouraging safety and functional results, is characterized by some crucial modifications, compared with the classic RP, that could make the choice of

accessing the SOR for RP more appealing for the implanters. First, the more medial fascia incision under direct visualizability offers a greater safety regarding blood vessel injury risk. Moreover, accessing SOR through the external oblique muscle fascia represents another advantage of our RP technique. Through this route, the inguinal ring which is protected by the Kocher-Langenbeck retractor is not compromised avoiding this way complications such inguinal hernia, and inguinal anatomic structures injury. An advantage which is not present to other modifications of the classic RP into the SOR previously presented.<sup>13,14</sup> In addition, the preposition of the stay suture in the

**Table 1.** Patient demographics and preoperative characteristics

|   |             |
|---|-------------|
| Study patients (n)                                | 253         |
| Mean age (SD)                                     | 64.6 (8.73) |
| Mean BMI (SD)                                     | 29.1 (3.1)  |
| Baseline IIEF-EF score (SD)<br>(under ED therapy) | 5.8 (2.3)   |
| Previous ED therapy methods                       | n (%)       |
| PDE5is  | 208 (82.2)  |
| Vacuum device                                     | 9 (3.5)     |
| Intraurethral alprostadil                         | 22 (8.7)    |
| ICI   | 192 (75.9)  |
| Cardiovascular risk factors*                      | 199 (78.7)  |
| Diagnosed with cardiovascular disease             | 98 (38.7)   |
| ED etiology                                       |             |
| Vasculogenic                                      | 159 (62.8)  |
| Post RP   | 68 (26.9)   |
| Post RCP  | 7 (2.8)     |
| Post low anterior resection                       | 3 (1.2)     |
| Hormonal  | 3 (1.2)     |
| Priapism  | 4 (1.6)     |
| Spinal cord injury                                | 7 (2.8)     |
| Pelvic injury                                     | 2 (0.8)     |
| Pelvic Surgical/radiation history                 |             |
| Robotic RP  | 57 (22.5)   |
| Laparoscopic                                      | 7 (2.8)     |
| Retropubic RP                                     | 4 (1.6)     |
| RCP, neobladder                                   | 2 (0.8)     |
| RCP, ileal conduit                                | 5 (2)       |
| Low anterior resection                            | 3 (1.2)     |
| Inguinal hernia repair                            | 35 (13.8)   |
| Open prostatectomy                                | 8 (3.2)     |
| Radiation   | 19 (7.5)    |

BMI = body mass index; ED = erectile dysfunction; ICI = intracavernosal injections; IIEF-EF = International Index of Erectile Function-erectile function domain; n = number; PDE5is = phosphodiesterase-5 inhibitors; RCP = radical cystoprostatectomy; RP = radical prostatectomy; SD = standard deviation.

\*Includes at least 1 of the following: diabetes mellitus, hypertension, hyperlipidemia, obesity, and smoking (current or former).

incision external oblique muscle fascia ensures an easy and tight closure minimizing possibility for reservoir herniation and also prevents the use of needle when device elements are already implanted. Finally, we believe that a main strength of our modified RP method is that it is easily reproducible, making it appealing to especially new implanters because of its clear anatomical steps under continuous direct visualizability.

Nevertheless, for the aforementioned theoretical, so far, advantages of our modified RP method to be proved in the clinical practice, further research is surely needed. Thus, a comparative study of the classic RP method vs our modified approach could be interesting and helpful for the surgeons to compare duration, complications, and satisfaction rates of the 2 RP methods.

Potential limitations of the present study are its retrospective design and its relatively short follow-up. A theoretical higher risk

**Table 2.** Intraoperative and postoperative data (n = 253)

|  |            |
|--|------------|
| Mean total operative time (SD), minutes                      | 37.7 (9.4) |
| Mean RP operative time (SD), minutes                         | 8.8 (1.6)  |
| Type of IPP  |            |
| Coloplast Titan  | 143        |
| AMS 700  | 110        |
| Hospital length stay   |            |
| 1 day  | 239        |
| 2 days   | 8          |
| 3 days   | 4          |
| >3 days  | 2          |
| Mean FU duration (months)                                    | 9.1        |
| Complications  |            |
| None   | 237        |
| Impending infection controlled<br>with prolonged antibiotics | 2          |
| Scrotal hematoma   | 3          |
| UTI  | 4          |
| Floppy glans   | 2          |
| Corporal perforation and crossover*                          | 3          |
| Scrotal pump impending erosion                               | 1          |
| RP-related prolonged pain                                    | 1          |

FU = follow-up; n = number of patients; RP = reservoir placement; SD = standard deviation; UTI = urinary tract infection.

\*Recognized and treated during the operation and not in a reoperation.

of bladder injury, owing to our more medial incision, was not depicted in our results in which no bladder injuries were reported, which maybe because of our routine of emptying the bladder with a catheter.

## CONCLUSION

We are, surely, not proposing that our modified RP technique should supplant all other methods; rather, it should be considered another useful option for RP in the implanter's armamentarium.

**Corresponding Author:** Ioannis Mykoniatis, MD, MSc, Department of Urology, Jessa Hospital, Salvatorstraat 20, 3500, Hasselt, Belgium. Tel: +306936975862; E-mail: [g\\_mikoniatis@hotmail.com](mailto:g_mikoniatis@hotmail.com)

*Conflict of Interest:* The authors report no conflicts of interest.

*Funding:* None.

## STATEMENT OF AUTHORSHIP

### Category 1

- (a) **Conception and Design**  
Koenraad van Renterghem
- (b) **Acquisition of Data**  
Ioannis Mykoniatis
- (c) **Analysis and Interpretation of Data**  
Ioannis Mykoniatis; Koenraad van Renterghem



### Category 2

#### (a) Drafting the Article

Ioannis Mykoniatis; Daniar Osmonov; Koenraad van Renterghem

#### (b) Revising It for Intellectual Content

Daniar Osmonov; Koenraad van Renterghem

### Category 3

#### (a) Final Approval of the Completed Article

Ioannis Mykoniatis; Daniar Osmonov; Koenraad van Renterghem

## REFERENCES

- Henry G, Hsiao W, Hsiao W, et al. A guide for inflatable penile prosthesis reservoir placement: pertinent anatomical measurements of the retropubic space. *J Sex Med* 2014; **11**:273-278.
- Levine LA, Hoeh MP. Review of penile prosthetic reservoir: complications and presentation of a modified reservoir placement technique. *J Sex Med* 2012; **9**:2759-2769.
- Osmonov D, Chomicz A, Tropmann-Frick M, et al. High-submuscular vs. space of Retzius reservoir placement during implantation of inflatable penile implants. *Int J Impot Res* 2019; **1**-6.
- Perito P, Wilson S. The history of Nontraditional or ectopic placement of reservoirs in prosthetic Urology. *Sex Med Rev* 2016; **4**:190-193.
- Morey AF, Cefalu CA, Hudak SJ. High submuscular placement of urologic prosthetic balloons and reservoirs via transscrotal approach. *J Sex Med* 2013; **10**:603-610.
- Hernández JC, Trost L, Köhler T, et al. Emerging complications following alternative reservoir placement during inflatable penile prosthesis placement: a 5-year multi-institutional experience. *J Urol* 2019; **201**:581-586.
- Henry GD. The Henry mummy wrap and the Henry finger sweep surgical techniques. *J Sex Med* 2009; **6**:619-622.
- Karpman E, Sadeghi-Nejad H, Henry G, et al. Current opinions on alternative reservoir placement for inflatable penile prosthesis among members of the Sexual Medicine Society of North America. *J Sex Med* 2013; **10**:2115-2120.
- Ziegelmann MJ, Viers BR, Lomas DJ, et al. Ectopic penile prosthesis reservoir placement: an anatomic cadaver Model of the high submuscular technique. *J Sex Med* 2016; **13**:1425-1431.
- Perito PE, Wilson SK. Traditional (retroperitoneal) and abdominal wall (ectopic) reservoir placement. *J Sex Med* 2011; **8**:656-659.
- Stember DS, Garber BB, Perito PE. Outcomes of abdominal wall reservoir placement in inflatable penile prosthesis implantation: a safe and efficacious alternative to the space of Retzius. *J Sex Med* 2014; **11**:605-612.
- Garber BB, Bickell M. Subcutaneous placement of inflatable penile prosthesis reservoirs. *Urology* 2016; **88**:93-96.
- Garber BB, Gross MS, Stember D. Sub-external oblique placement of inflatable penile prosthesis reservoirs-initial experience. *Int J Impot Res* 2019; **31**:400-403.
- Roth JD, Monn MF, Shelton TM, et al. A novel technique for direct visualization of reservoir placement for penoscrotal inflatable penile prostheses using a single incision. *Indian J Urol IJU J Urol Soc India* 2018; **34**:283-286.