

# Biocompatibility and Adhesion Formation of Different Endoloop Ligatures in Securing the Base of the Appendix

Samir Delibegović, MD, PhD, Muhamed Katica, Ferid Latić, MD, PhD,  
Jasminka Jakić-Razumović, MD, PhD, Anhel Koluh, MD, Mahmoud T. M. Njoum

## ABSTRACT

**Background and Objectives:** The common technique used in securing the base of the appendix is Endoloop ligature (Ethicon, Somerville, NJ, USA). Vicryl (polyglactin 910) (Ethicon) and polydioxanone (PDS) (Ethicon) Endoloop ligatures can be used. There are potential benefits of the use of PDS Plus (Ethicon) Endoloop ligature. However, the use of different materials may vary in terms of inflammation, foreign-body reaction, rate of infection in the surgical area, or rate of adhesion formation. An ideal suture would induce minimal inflammatory response and adhesion formation.

**Methods:** Ninety rats were randomized into 3 groups: group I, in which appendectomy was performed with Vicryl ligature; group II, in which appendectomy was performed with PDS ligature; and group III, in which appendectomy was performed with PDS Plus ligature. The animals were killed on the seventh, 28th, and 60th days after surgery. The secured stump was used for histopathologic and immunohistochemistry analysis, as well as evaluation of the formation of adhesions.

**Results:** Mild and moderate inflammation was more frequent in the PDS and PDS Plus groups than in the Vicryl group on the seventh postoperative day. There were no significant differences in the degree of inflammation on the 28th and 60th postoperative days. The lowest degree

of postoperative adhesions was observed in the PDS group.

**Conclusion:** Milder postoperative inflammatory changes and a lower degree of postoperative adhesions were seen in the PDS ligature group, suggesting that this could be the standard Endoloop used to secure the base of the appendix.

**Key Words:** Laparoscopic appendectomy, Endoloop, Vicryl, PDS, PDS Plus, Ligature.

## INTRODUCTION

The common technique used in securing the base of the appendix is Endoloop ligature.<sup>1-3</sup> Vicryl (polyglactin 910) and polydioxanone (PDS) Endoloop ligatures can be used. There are potential benefits of the use of PDS Plus (Ethicon) Endoloop ligature (Ethicon, Somerville, NJ, USA). The antibacterial properties of PDS Plus ligature have been documented in surgical practice,<sup>4</sup> but we do not know whether the antibacterial agent triclosan affects the inflammation.

Use of different materials may vary in terms of inflammation, foreign-body reaction, rate of infection in the surgical area, or rate of formation of adhesions. These adhesions can cause chronic pain and serious complications, such as intestinal obstruction.<sup>5</sup> The aim of our study was to compare 3 different ligatures, using a rodent animal model, to understand which ligature would induce the minimal inflammatory response and adhesion formation.

## MATERIALS AND METHODS

This study was initiated after approval by the Ethics Review Committee of the Faculty of Veterinary Medicine, University of Sarajevo, Bosnia and Herzegovina. Wistar albino rats weighing 300 to 350 g were kept under standard laboratory conditions before surgery, placed in free-standing cages, and acclimatized to standard laboratory conditions (temperature from 20°C to 24°C, 12 hours of light and 12 hours of dark, and food withdrawn for 24 hours before surgery). Ninety rats were randomized into 3

Department of Surgery, University Clinic Center Tuzla, Tuzla, Bosnia and Herzegovina (Dr. Delibegović).

Faculty of Veterinary Medicine, University of Sarajevo, Sarajevo, Bosnia and Herzegovina (Dr. Katica, Njoum).

Department of Surgery, General Hospital "Dr. Josip Benčević," Slavonski Brod, Croatia (Dr. Latić).

Department of Pathology and Cytology, University Hospital Centre Zagreb, Zagreb, Croatia (Dr. Jakić-Razumović).

Cantonal Hospital Zenica, Zenica, Bosnia and Herzegovina (Dr. Koluh).

Disclosure statement: The authors have no conflicts of interests and no funding from external commercial parties.

Address correspondence to: Samir Delibegović, MD, PhD, Department of Surgery, University Clinic Center Tuzla, Trnovac bb, 75000 Tuzla, Bosnia and Herzegovina. Telephone: +387 61 149 131, Fax: +387 35 250 474, E-mail: delibegovic.samir@gmail.com

DOI: 10.4293/108680813X13654754534116

© 2013 by JSLs, *Journal of the Society of Laparoendoscopic Surgeons*. Published by the Society of Laparoendoscopic Surgeons, Inc.

groups: group I, in which appendectomy was performed with Vicryl (polyglactin 910) ligature (n = 30); group II, in which appendectomy was performed with PDS ligature (n = 30); and group III, in which appendectomy was performed with PDS Plus ligature (n = 30).

### Surgical Procedure

After the rats were anesthetized with ketamine (50 mg/kg), they were secured with an adhesive band and placed on the surgical table in the supine position. The abdomen of the animal was shaved and disinfected by povidone-iodine solution and dried with gauze. Laparotomy was performed through a median incision. The cecum, a dead-end pouch similar to the appendix in humans, was located and then dissected.

In group I (n = 30) the cecum (approximately 0.7 cm in length) was ligated with No. 2-0 Vicryl ligature (Vicryl; Ethicon, Somerville, NJ, USA) and divided. In group II (n = 30) the cecum was ligated with No. 2-0 PDS ligature (PDS II Ethicon) and divided. In group III (n = 30) the cecum was ligated with No. 2-0 PDS Plus ligature (PDS Plus; Ethicon) and divided.

Laparotomy and suturing of the skin were performed with a No. 3-0 continuous suture. No antibiotic treatment was used before, during, or after the experiment. During the entire observational period, all animals were controlled and underwent clinical examination for monitoring of local and systemic complications. On the seventh, 28th, and 60th days after the surgical procedure, 10 animals from each group were killed, and the stump containing the Endoloop was taken for histopathologic and immunohistochemistry analysis, as well as evaluation of the formation of adhesions.

### Histopathologic Procedure

Biopsic material was formalin fixed and paraffin embedded, cut into standard 5- $\mu$ m cuts, colored by application according to the standard procedure for hematoxylin-eosin staining, and then mounted by use of DPX. Microscopic analysis was performed with a Leica DMLB microscope (Leica Microsystems, Wetzlar, Germany).

### Immunohistochemical Analysis

Immunohistochemical analysis of 3-level immunoperoxidase with streptavidin was used to examine the presentation of B and T lymphocytes and histiocytes in inflammatory infiltrate. We used monoclonal mouse anti-rat CD3 and CD20 antibodies for evidence of T and B lympho-

cytes, and for histiocytes, we used a monoclonal mouse anti-rat CD68 antibody. For visualization of reactions, we used chromogen (substrate) diaminobenzidine hydrochloride, which yields a brown product of reaction.

### Formation of Adhesions

Formation of adhesions was assessed with the scoring system of the Surgical Membrane Study Group (MSG) (Table 1), with an average area of the cecum of 1 cm<sup>2</sup> taken as 100% involvement.

### Statistical Analysis

The Fisher exact probability test was used for the analysis of differences between distributions of histopathologic changes. Differences were considered significant at  $P < .05$ .

The Kruskal-Wallis test was used to compare MSG scores in the Vicryl, PDS, and PDS Plus groups. Post hoc analysis was performed by use of the Mann-Whitney test with corrected  $P$  value (Bonferroni correction).

## RESULTS

All the rats that we operated on exhibited a 100% survival rate accompanied by normal food and water intake. No

Adhesion Characteristics	Score
Extent of site involvement	
None	0
<25%	1
<50%	2
<75%	3
100%	4
Type	
None	0
Filmy, transparent, avascular	1
Opaque, translucent, avascular	2
Opaque, capillaries present	3
Opaque, larger vessels present	4
Tenacity	
None	0
Adhesion falls apart	1
Adhesion lysed with traction	2
Adhesion required with sharp dissection	3
Total possible	

**Table 2.**  
Histopathologic Findings of Cecum and Stumps

	Vicryl	PDS	PDS Plus
Seventh postoperative day			
Mild inflammation	—	5	1
Moderate inflammation	4	5	9
Severe inflammation	6	—	—
Twenty-eighth postoperative day			
Mild inflammation	2	7	8
Moderate inflammation	4	2	2
Severe inflammation	4	1	—
Sixtieth postoperative day			
Mild inflammation	7	9	7
Moderate inflammation	2	1	3
Severe inflammation	1	—	—

other complications were observed, including infection of the wound, volvulus, intestinal obstruction, abscess, or wound dehiscence.

### Histopathologic Assessment

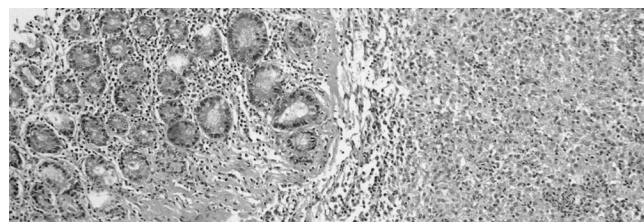
We analyzed the tissue reaction in the field just around the Endoloop. Under the light microscope, on the seventh postoperative day, in groups II and III (PDS and PDS Plus, respectively), mild and moderate inflammation dominated (**Table 2**).

The Fisher exact test identified a statistically significant difference in the degree of mild and moderate inflammation on the seventh postoperative day between the Vicryl and PDS groups and between the Vicryl and PDS Plus groups ( $P = .01$  in both cases,  $P = .03$  after Bonferroni correction) (**Figures 1-3**). There was no statistically significant difference between the PDS and PDS Plus groups ( $P > .09$ ).

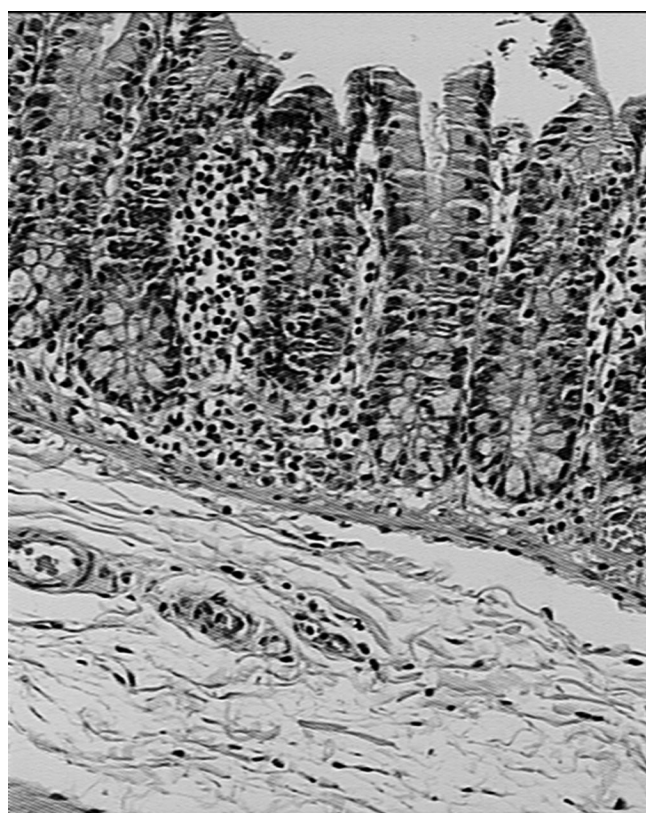The Fisher exact test did not identify statistically significant differences in the degree of mild and moderate inflammation on the 28th and 60th postoperative days among the 3 groups ( $P = 3$ ,  $P = .09$ , and  $P > .99$  for Vicryl, PDS, and PDS Plus, respectively, at 28 days) ( $P > .99$  in all cases at 60 days).

### Immunohistochemistry Analysis

On the seventh and 28th postoperative days in the PDS and PDS Plus groups, sparse and moderate infiltrates dominated, but the Fisher exact test did not identify sta-



**Figure 1.** Vicryl ligature, seventh postoperative day. Severe inflammation is present in the mucosa of the stump appendix (hematoxylin-eosin stain, original magnification  $\times 300$ ).

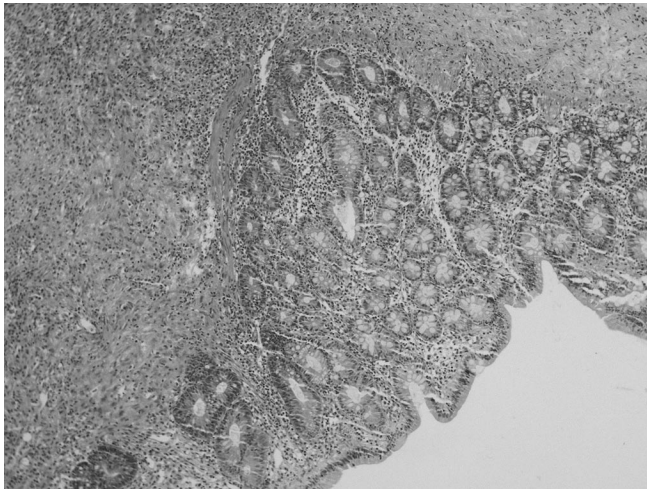


**Figure 2.** PDS ligature, seventh postoperative day. Moderate inflammation is present in the lamina propria of the stump (hematoxylin-eosin stain, original magnification  $\times 200$ ).

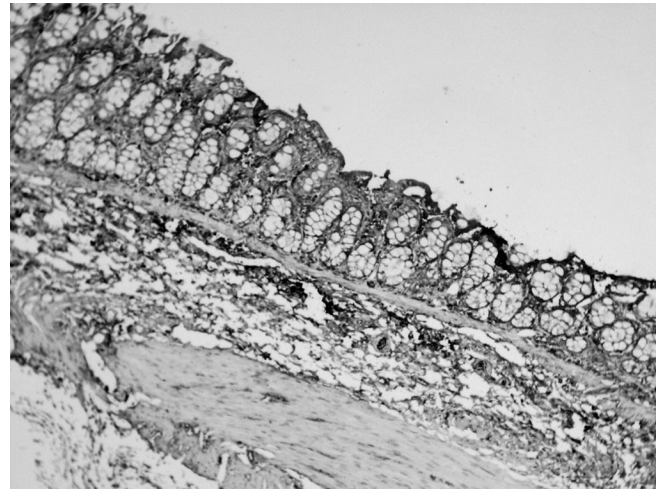
tistically significant differences between groups (**Table 3**, **Figures 4-6**).

### Evaluation of Formation of Adhesions

The Kruskal-Wallis test identified statistically significant differences in the SMSG score among the Vicryl, PDS, and PDS Plus groups on the seventh ( $\chi^2 = 11.134$ ,  $df = 2$ ,  $P = .001$ ), 28th ( $\chi^2 = 7.48$ ,  $df = 2$ ,  $P = .01$ ), and 60th ( $\chi^2 = 18.74$ ,  $df = 2$ ,  $P < .0001$ ) postoperative day.



**Figure 3.** PDS Plus ligature, seventh postoperative day. Moderate to severe inflammation with mixed inflammatory infiltrates is present in the mucosa of the stump (leukocytes, histiocytes, and lymphocytes) (hematoxylin-eosin stain, original magnification  $\times 300$ ).

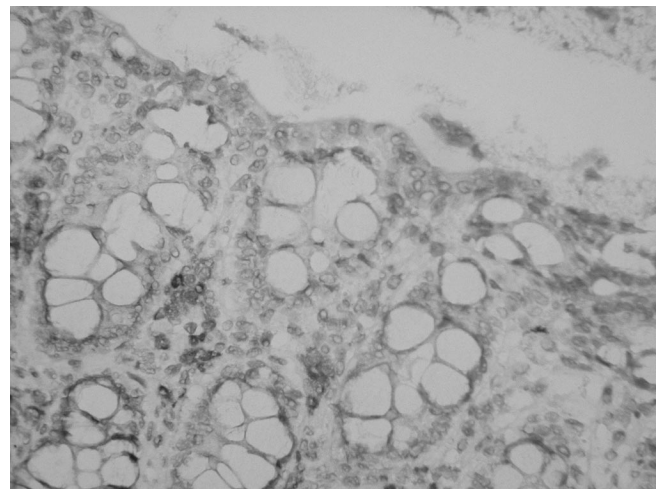


**Figure 4.** Vicryl ligature, seventh postoperative day. Immunohistochemical staining with anti-CD20 (B lymphocytes). Moderate infiltrates of B lymphocytes are present in the mucosa of the stump (contrast hematoxylin-eosin stain, original magnification  $\times 300$ ).

**Table 3.**

Inflammatory Infiltrate of Histiocytes and T Lymphocytes

	Vicryl	PDS	PDS Plus
Seventh postoperative day			
Sparse infiltrates	—	3	3
Moderate infiltrates	7	8	7
Dense infiltrates	3	—	—
Twenty-eighth postoperative day			
Sparse infiltrates	—	7	8
Moderate infiltrates	6	3	2
Dense infiltrates	4	—	—
Sixtieth postoperative day			
Sparse infiltrates	7	7	9
Moderate infiltrates	3	3	1
Dense infiltrates	—	—	—

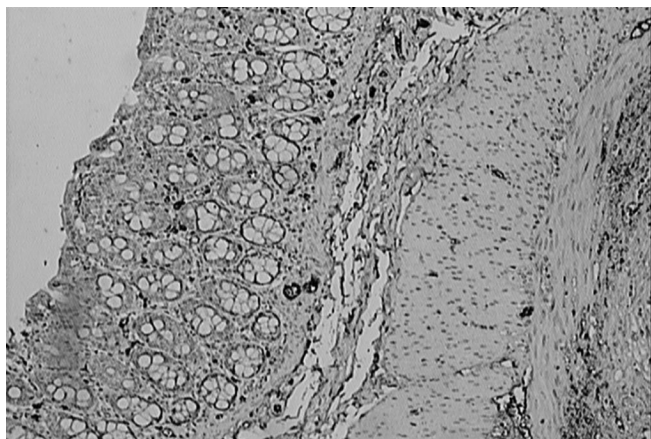


**Figure 5.** PDS ligature, seventh postoperative day. Immunohistochemical staining with anti-CD3 (T lymphocytes). Sparse infiltrates of T lymphocytes are present in the mucosa of the stump (contrast hematoxylin-eosin stain, original magnification  $\times 400$ ).

**Seventh postoperative day.** Comparing each score with the other scores by use of the Mann-Whitney test (1 sided), we found that there was no significant difference in the Vicryl and PDS groups ( $U = 45.5, P = .37$ ). However, the score in the Vicryl group was significantly lower than the score in the PDS Plus group ( $U = 12, P = .0015$ ), and the score in the PDS group was significantly lower than the score in the PDS Plus group ( $U = 17, P = .005$ ).

**Twenty-eighth postoperative day.** There were no statistically significant differences between the Vicryl and PDS groups ( $U = 24, P = .025$ ) or the Vicryl and PDS Plus groups ( $U = 44.5, P = .342$ ). The score in the PDS group was statistically significantly lower than the score in the PDS Plus group ( $U = 17, P = .005$ ).

**Sixtieth postoperative day.** There were no significant differences between the Vicryl and PDS groups ( $U = 33,$



**Figure 6.** PDS Plus group, seventh postoperative day. Immunohistochemical staining with anti-CD68 (macrophages, histiocytes). Sparse infiltrates of histiocytes are present in the mucosa of the stump (contrast hematoxylin-eosin stain, original magnification  $\times 200$ ).

$P = .11$ ). However, the score in the Vicryl group was statistically significantly lower than the score in the PDS Plus group ( $U = 7.5, P < .0001$ ), and the score in the PDS group was significantly lower than the score in the PDS Plus group ( $U = 0, P < .0001$ ).

### Extent of Site Involvement

The Kruskal-Wallis test identified statistically significant differences in site involvement for the Vicryl, PDS, and PDS Plus groups after 7 ( $\chi^2 = 8.24, df = 2, P = .011$ ), 28 ( $\chi^2 = 9.92, df = 2, P = .002$ ), and 60 ( $\chi^2 = 14.50, df = 2, P < .0001$ ) postoperative days.

**Seventh postoperative day.** Comparing each score with the other scores by the Mann-Whitney test (1 sided), we found that site involvement in the Vicryl group was less than that in the PDS and PDS Plus groups, but the difference was not statistically significant ( $U = 25, P = .03$ ). There was also no significant difference in site involvement between the PDS and PDS Plus groups ( $U = 50, P = .5$ ).

**Twenty-eighth postoperative day.** Site involvement in the Vicryl group was greater than that in the PDS group, but not statistically ( $U = 24, P = .025$ ), and there was no statistically significant difference compared with the PDS Plus group ( $U = 44.5, P = .34$ ). Site involvement in the PDS group was statistically significantly less than that in the PDS Plus group ( $U = 17, P = .006$ ).

**Sixtieth postoperative day.** Site involvement in the Vicryl group was statistically greater than that in the PDS group ( $U = 21.50, P = .015$ ), and it was less, although not statistically less, than that in the PDS Plus group ( $U = 25, P = .031$ ). Site involvement in the PDS group was statistically significantly less than that in the PDS Plus group ( $U = 7.5, P < .0001$ ).

### DISCUSSION

During laparoscopic appendectomy, the common technique for securing the base of the appendix uses Vicryl (polyglactin 910) or PDS Endoloop ligatures.

There are potential benefits of the use of PDS Plus Endoloop ligature because of the antibacterial properties of PDS Plus ligature. However, the use of different suture materials may vary in terms of inflammation, foreign-body reaction, rate of infection in the surgical area, or rate of formation of adhesions. Generally speaking, tissues respond to sutures as they would to any foreign material. If the body's response to the suture is intense, the suture itself may be broken down or the tissue surrounding the suture may be destroyed. The possible consequences of a severe tissue reaction include edematous and friable tissue that has less holding capacity for the sutures, infection that enhances the inflammatory response, and formation of adhesions. It would be ideal to use a suture material that would induce minimal tissue responses.

The inflammatory reactions and the formation of adhesions peaked on postoperative day 7.<sup>6</sup> In our study, on the seventh postoperative day, milder inflammation was seen in the PDS and PDS Plus groups. In these groups the sparse and moderate infiltrates of T lymphocytes and histiocytes dominated on the seventh and 28th postoperative days, but this did not reach statistical significance. In the study of Kosan et al.,<sup>7</sup> in which they compared Vicryl (polyglactin 910), PDS, and chromed catgut sutures in the rat model, the lowest level of inflammation was seen in the PDS group.

In our study, on the seventh postoperative day, Vicryl and PDS caused a lower number of adhesions in comparison with PDS Plus. There were no significant differences in the extent of site involvement on the seventh postoperative day among all examined ligatures, but the extent of site involvement for PDS was less than that for Vicryl and PDS Plus on the 28th and 60th postoperative days.

Macroscopically, different grades of adhesions were observed at 7, 28, and 60 days' follow-up. We observed a decrease in the scores at 28 and 60 days, which is in

agreement with the findings of Burger et al.<sup>8</sup> and Emans et al.<sup>9</sup> However, adhesions that have formed before will remain a persistent inflammatory process, even in adhesions aged >20 years.<sup>10</sup>

Because intra-abdominal adhesion formation connecting a visceral organ to a stump can potentially lead to chronic pain, as well as intestinal obstruction, its occurrence should be eliminated or at least reduced as much as possible.<sup>11</sup> In addition, adhesions can complicate future surgery.<sup>12</sup>

The laparoscopic approach appears to decrease the risk of adhesion formation by 45% and the need for adhesion-related reintervention to 0.8% after appendectomy.<sup>13</sup> Appendectomy was associated with a lower rate of readmission related to adhesions (0.9%) but contributed >7% of the total lower abdominal surgery patient readmission burden.<sup>14</sup>

Foreign-body reactions were not observed in this study. A limitation of this study may be the size of sample (with the disadvantages of a small sample), but the findings of this study indicate that the properties of PDS make it more appropriate for Endoloop ligature use during laparoscopic appendectomy. PDS has another advantage observed in surgical practice: It has the ability to hold its shape when becoming moist, in contrast to Vicryl, which becomes difficult to manipulate after it becomes wet.

An ideal suture would provide high tensile strength and knot security, resist infection and contamination, and react minimally with the tissue in which it is embedded. However, that “perfect” suture material may never become available, and surgeons will have to examine each surgical problem and select the appropriate materials accordingly.<sup>15</sup>

## References:

- Neugebauer EAM, Troidl H, Kum CK, Eypasch E, Miserez M, Paul A. The EAES Clinical Practice Guidelines on Laparoscopic Cholecystectomy, Appendectomy, and Hernia Repair (1994). In: Neugebauer EAM, Sauerland S, Fingerhut A, Millat B, Buess G, eds. EAES Guidelines for Endoscopic Surgery. Berlin: Springer; 2006:265–289.
- Kavic MS, Kavic SM, Kavic SM. Laparoscopic Appendectomy. In: Kavic MS, Nezhat C, Winfield H, eds. *Prevention and Management of Laparoendoscopic Surgical Complications*. 3rd ed. Miami, FL: SLS; 2012.
- Soper NJ, Scott-Conner Carol EH, eds. The SAGES Manual. Volume 1. Basic Laparoscopy and Endoscopy. New York, NY: Springer-Verlag; 2012.
- Barbolt TA. Chemistry and safety of triclosan, and its use as an antibacterial coating on Coated Vicryl Plus Antibacterial Suture (coated polyglactin 910 with triclosan). *Surg Infect*. 2002; 3(Suppl):S45–S53.
- van't Riet M, Burger JWA, Bonthuis F, Jeekel J, Bonjer HJ. Prevention of adhesion formation to polypropylene mesh by collagen coating. A randomized controlled study in a rat model of ventral hernia repair. *Surg Endosc*. 2004;18:681–685.
- Baptista ML, Bonsack ME, Felemovicus I, Delaney JP. Abdominal adhesions to prosthetic mesh evaluated by laparoscopy and electron microscopy. *J Am Coll Surg*. 2000;190:271–280.
- Kosan M, Gonulalan U, Ozturk B, et al. Tissue reactions of suture materials (polyglactine 910, chromed catgut and polydioxanone) on rat bladder wall and their role in bladder stone formation. *Urol Res*. 2008;36:43–49.
- Burger JW, Luijendijk RW, Hop WC, Halm JA, Verdaasdonk EG, Jeekel J. Long-term follow-up of a randomized controlled trial of suture versus mesh repair of incisional hernia. *Ann Surg*. 2004;240:578–583; discussion 583–575.
- Emans PJ, Schreinemacher MHF, Gijbels JJM, et al. Polypropylene meshes to prevent abdominal herniation. Can stable coatings prevent adhesions in the long term? *Ann Biomed Eng*. 2008;37:410–418.
- Binnebosel M, Rosch R, Junge K, Lynen-Jansen P, Schumpelick V, Klinge U. Macrophage and T-lymphocyte infiltrates in human peritoneal adhesions indicate a chronic inflammatory disease. *World J. Surg*. 2008;32:296–304.
- Junge K, Binnebosel M, Rosch R, et al. Adhesion formation of a polyvinylidene fluoride/polypropylene mesh for intra-abdominal placement in a rodent animal model. *Surg Endosc*. 2009;23:327–333.
- Suslavich FJ, Turner NA, King PS, Brown HK. Intraabdominal adhesions: intraoperative US. *Radiology*. 1989;172:387–388.
- Ouaïssi M, Gaujoux S, Veyrie N, et al. Post-operative adhesions after digestive surgery: their incidence and prevention: review of the literature. *J Visc Surg*. 2012;149:e104–e114.
- Parker MC, Wilson MS, Menzies D, et al. The SCAR-3 study: 5-year adhesion-related readmission risk following lower abdominal surgical procedures. *Colorectal Dis*. 2005;7:551–558.
- Greenwaid D, Shumway S, Albear P, Gottlieb L. Mechanical comparison of ten suture materials before and after in vivo incubation. *J Surg Res*. 1994;56:372–377.