

CASE REPORT

ADVANCED

CLINICAL CASE

Correction of a Malpositioned Portico Transcatheter Aortic Valve Using a Snare Maneuver



Udaya Prashant Ponangi, MBBS, MD, DM,^a Sumit Yadav, MBBS,^a Virag Kushwaha, BS, MBBS, PhD,^b Riabhan Yadav, MBBS, MD, DNB,^a Krystle Lander, MBBS,^a Lim Eng, MBBS^a

ABSTRACT

A 75-year-old woman with severe aortic stenosis underwent transcatheter aortic valve replacement using a 23-mm self-expanding Portico valve (Abbott). After complete deployment, it was found to be unacceptably low, with significant paravalvular regurgitation. The valve was pulled upward to the correct position successfully by using the snare maneuver. (**Level of Difficulty: Advanced.**) (J Am Coll Cardiol Case Rep 2019;1:838-43) © 2019 The Authors. Published by Elsevier on behalf of the American College of Cardiology Foundation. This is an open access article under the CC BY-NC-ND license (<http://creativecommons.org/licenses/by-nc-nd/4.0/>).

HISTORY AND PHYSICAL EXAMINATION

A 75-year-old woman presented with a history of progressively worsening exertional dyspnea (New York Heart Association functional class III) and intermittent dizziness. She had mild pedal edema, elevated jugular venous pulses, a rough grade 3/6 ejection systolic murmur in the aortic area, and clear

lung fields on auscultation. Other comorbidities were rheumatoid arthritis, cirrhosis of the liver with esophageal varices, type 2 diabetes mellitus, essential hypertension, and recurrent falls.

PAST MEDICAL HISTORY

The patient had a history of stroke, pulmonary embolism, and benign positional vertigo.

LEARNING OBJECTIVES

- Absence of dense annular calcification is a risk factor for device malpositioning during TAVR with self-expanding valves.
- Even though there are no prior reports, our case proves that it is safe and feasible to use the snare maneuver for correction of mispositioned Portico valves.
- The presence of a central stiff wire across the TAVR gives stability during the single snare maneuver.

INVESTIGATIONS

Echocardiogram revealed a calcific tricuspid aortic valve with severely restricted leaflet opening. The peak and mean gradients across the aortic valve were 61 and 36 mm Hg, respectively, and the calculated valve area by continuity equation was 0.82 cm² with a Dimensionless Performance Index (DPI) of 0.2 (Figure 1). The stroke volume index was 30 ml/m². Computed tomography angiogram showed an annulus area of 338.5 mm² and an average annular

From the ^aTownsville Hospital, Townsville, Australia Department of Cardiology and Cardiothoracic Surgery, Douglas, Australia; and the ^bDepartment of Cardiology, Prince of Wales Hospital, Sydney, Australia. Dr. Kushwaha works as a proctor for Abbott. The other authors have reported that they have no relationships relevant to the contents of this paper to disclose. Takashi Matsukage, MD, served as Guest Associate Editor for this paper.

Informed consent was obtained for this case.

Manuscript received November 3, 2019; accepted November 5, 2019.

diameter of 20.8 mm with an eccentricity index of 0.11 (Figure 2). Computed tomography of the abdomen showed cirrhosis of the liver. The Society of Thoracic Surgeons score was 6.2% with predicted mortality and morbidity of 20.5%. Gastroenterology team assessment predicted surgical mortality of 10% as a result of liver cirrhosis.

INTERVENTION

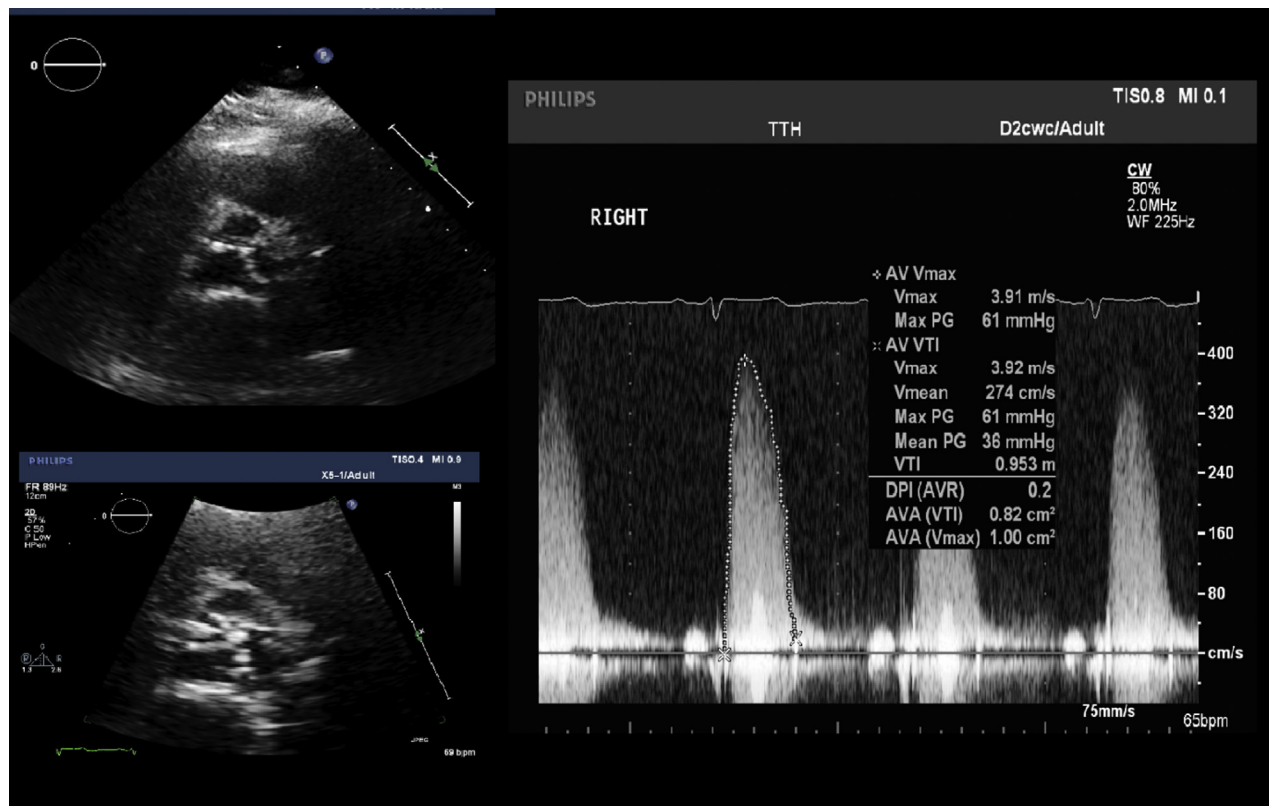Bilateral femoral access was obtained using ultrasound imaging. The aortic valve was initially crossed with a 0.0035-inch straight-tip wire that was later exchanged for a 0.0035-inch Safari 2 stiff wire (Boston Scientific, Burlington, Massachusetts) using an Amplatzer left (AL) catheter. After pre-dilatation, a 23-mm self-expanding Portico valve (Abbott, Abbott Park, Illinois) was positioned across the aortic

annulus and slowly released under fluoroscopic guidance (Figure 3). Once the delivery cable was released from the valve attachment post, the deployed valve was found to be implanted low, with moderate to severe paravalvular regurgitation (Figure 4). The diastolic pressure dropped to 40 mm Hg with a calculated aortic regurgitation (AR) index of 21. The malpositioned valve was recrossed with a pigtail catheter, and the same Safari 2 wire was used to stabilize the valve. A 25-mm Amplatzer Gooseneck Snare was introduced through a 6-F Judkins right (JR) 4 guide catheter through contralateral femoral access and looped around a valve attachment post toward the greater curvature of the aorta (Figure 5). The valve was then pulled toward the ascending aorta by using steady moderate traction. Repeat aortogram demonstrated that the valve was well positioned in the

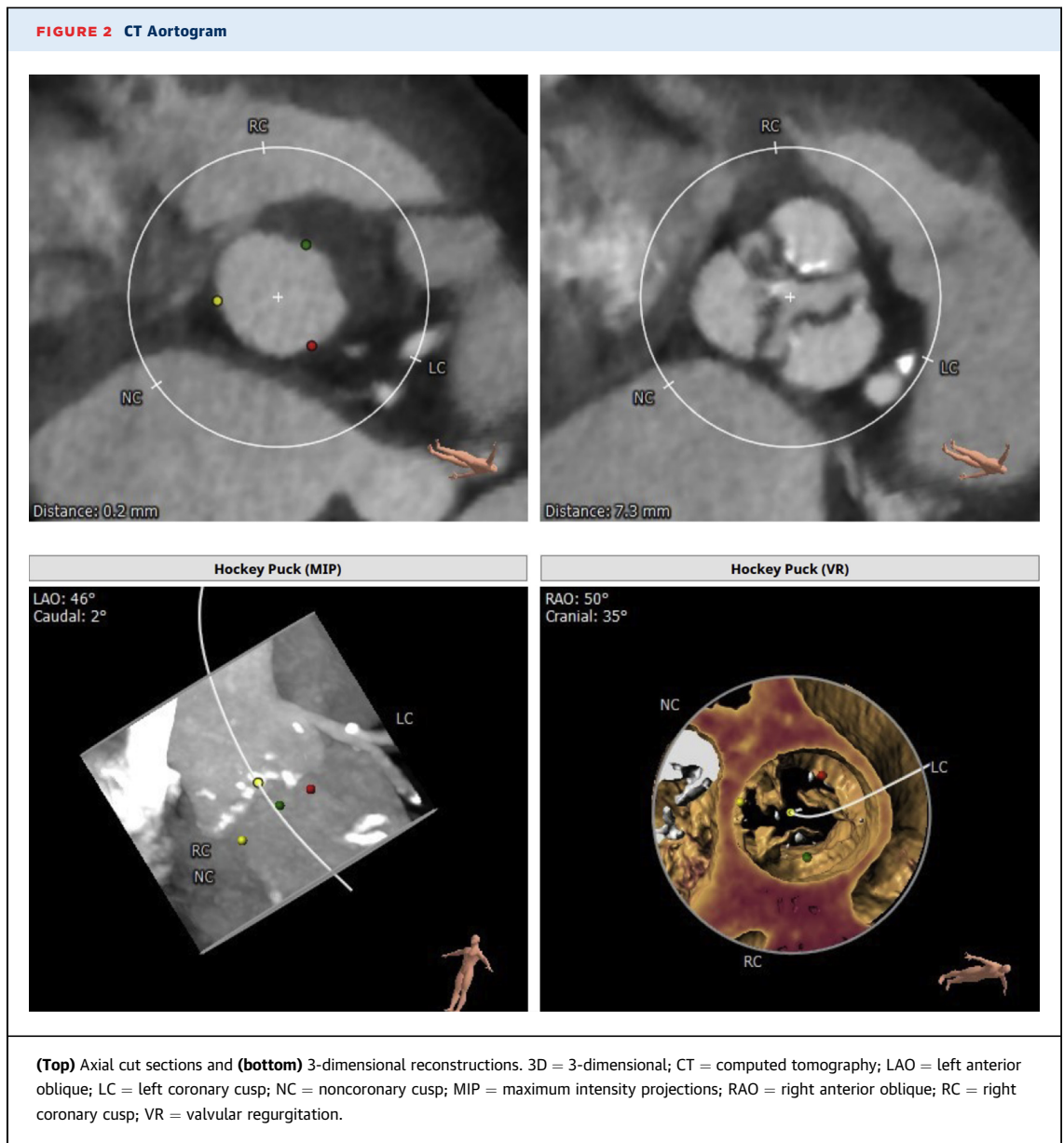
ABBREVIATIONS AND ACRONYMS

- AR = aortic regurgitation
- TAVR = transcatheter aortic valve replacement

FIGURE 1 Short-Axis View of Aorta on Echocardiogram Showing Tricuspid Calcified Leaflets and CW Doppler Analysis of the Aortic Valve



AV = aortic valve; AVA = aortic valve area; AVR = aortic valve replacement; DPI = Dimensionless Performance Index; Max PG = maximum pressure gradient; Vmax = maximum velocity; Vmean = mean velocity; VTI = velocity-time integral.



aortic root with no residual AR (Figures 6 and 7). The diastolic pressure rose to 60 mm Hg, and the calculated AR index increased to 34. During the snare maneuver the patient did not develop any conduction disturbances, and no pacing was required.

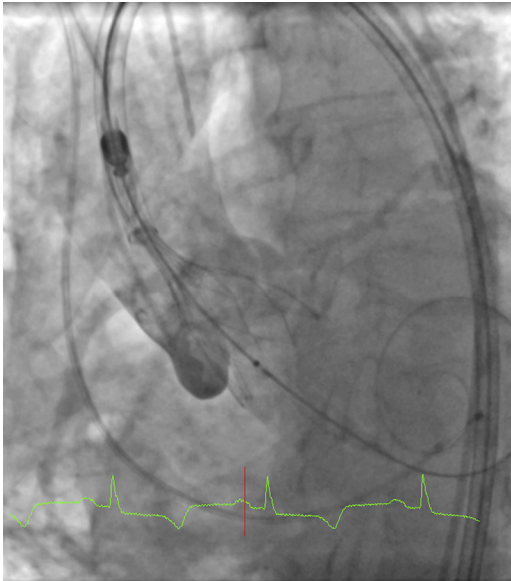
DISCUSSION

In a recent publication, Stundl et al. (1) showed that the occurrence of greater than mild paravalvular regurgitation occurred less frequently in patients

treated with “newer-generation” transcatheter valves (0% to 5%) when compared with older-generation valves (9% to 12%) (1).

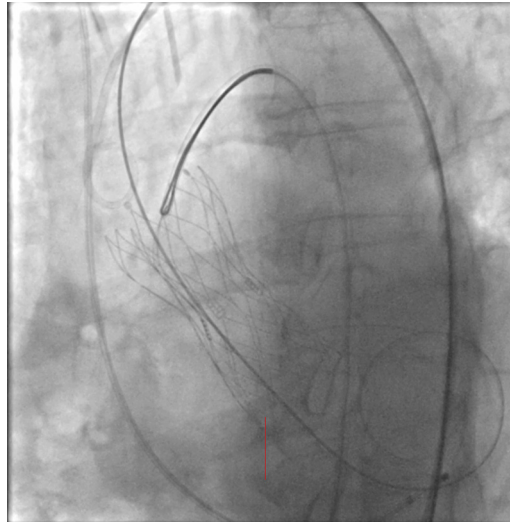
Post-deployment, besides low implant position, we noted moderate to severe paravalvular regurgitation. Our patient also had a very low AR index that improved after correction. AR index is the ratio of the gradient between diastolic blood pressure and left ventricular end-diastolic pressure to systolic blood pressure $\{[(\text{diastolic blood pressure} - \text{left ventricular end-diastolic pressure}) / \text{systolic blood pressure}] \times 100\}$,

FIGURE 3 Aortogram Showing Partial Deployment of the Portico (Abbott) TAVR in Ideal Position



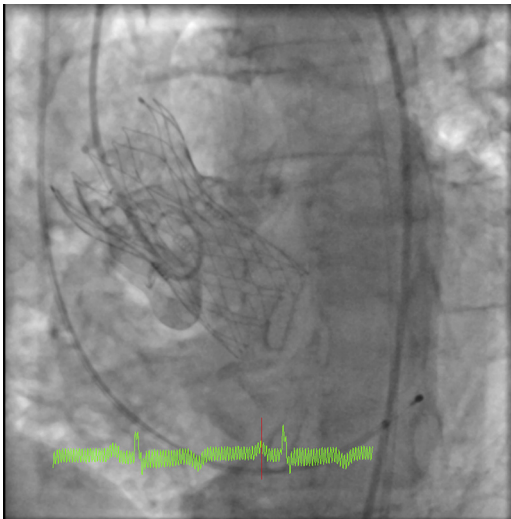
The **red line** denotes the time of cardiac cycle in relation to electrocardiogram as to when the snapshot was taken.
TAVR = transcatheter aortic valve replacement.

FIGURE 5 Amplatz Gooseneck Snare Hooked Onto the Greater Curvature of the Valve Post



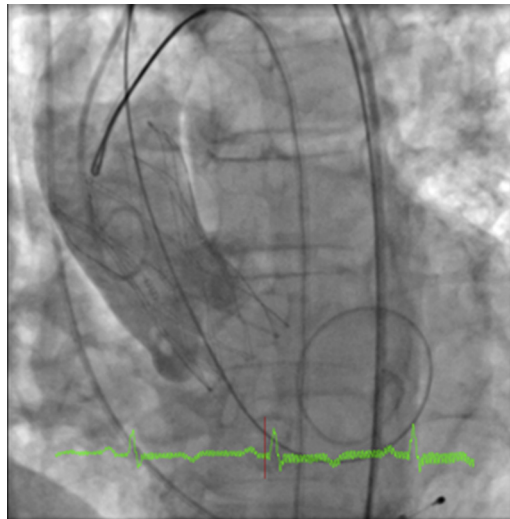
The **red line** denotes the time of cardiac cycle in relation to electrocardiogram as to when the snapshot was taken.

FIGURE 4 Low Implantation of TAVR After Complete Deployment With Paravalvular Regurgitation

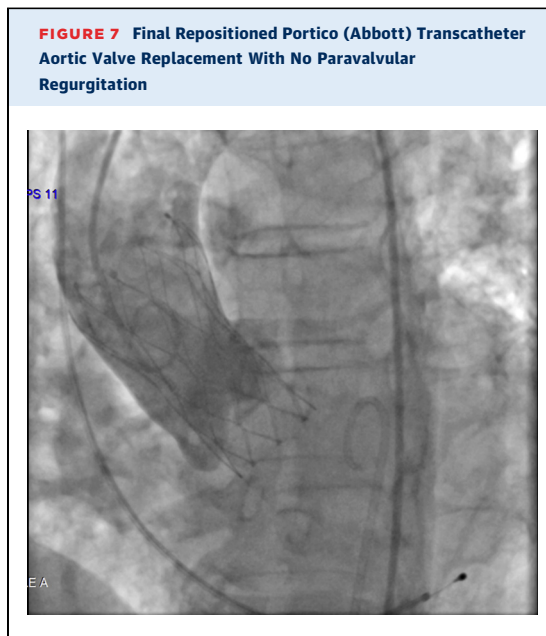


The **red line** denotes the time of cardiac cycle in relation to electrocardiogram as to when the snapshot was taken.
TAVR = transcatheter aortic valve replacement.

FIGURE 6 Correction of Valve Position by Snare Maneuver



The **red line** denotes the time of cardiac cycle in relation to electrocardiogram as to when the snapshot was taken.



and it independently predicts 1-year mortality after TAVR (2).

Recapturing and repositioning the Portico transcatheter heart valve can be easily accomplished when the valve is deployed up to 80%. Once it is fully deployed, recapturing of the valve is no longer possible.

Our patient did not have a dense aortic root or annular calcification and could have primarily contributed to low implantation, but the repositioned valve retained the optimum position even after 6 months of follow-up. Valve deployment of self-expanding valves requires slow release of the tension that builds up in the delivery system, and any undesirable motion from the patient or operators during the procedure can lead to malpositioning. Throughout the deployment process, we ensured that the valve was in the correct position relative to the pigtail catheter parked in the non-coronary cusp. However, during the final step just after the detachment of delivery cable from the valve post, it unexpectedly slipped to a lower level below the annulus.

Portico valves have fewer and larger cells and cylindrical base when compared with Evolute valves, which have a smaller cell size diameter and a

larger number of cells with a slightly conical base. Because of this valve design, Portico valves have less chance of conduction disturbances and greater success for percutaneous coronary interventions later if required (3).

The snare maneuver was first described by Vavuranakis in 2010, and since then multiple case reports have been published (4-6). Various types of snare maneuvers have been described. This maneuver can be done using a single snare either from the femoral or radial access, 2 snares both from femoral routes, or 1 snare from the femoral route and another by radial artery cannulation (4).

Ideal snaring options would be a double-snare technique, hooking to both inner and outer tabs or valve posts (6). In our case we already had bilateral femoral access, and once the valve was stabilized by repositioned Safari wire into left ventricular cavity, it was snared through contralateral femoral access. If we were not successful with a single-snare technique, we had the backup options of using double snaring from additional radial access or implanting another valve percutaneously. The aorta was angulated and not vertically aligned in relation to the left ventricular outflow tract. Hence the valve post toward the greater curvature of the aorta was hooked onto, and constant traction force was applied until a desired valve position was attained. Potential complications of the snare maneuver are valve embolization, traumatic dissection of the aorta, and stroke (6).

FOLLOW-UP. A transthoracic echocardiogram after 6 months demonstrated a well-positioned Portico valve with no significant gradients or valvular regurgitation. The patient's dyspnea had reduced significantly.

CONCLUSIONS

Repositioning of fully deployed, misplaced, self-expanding TAVR valves can be successfully achieved percutaneously by using simple snare equipment.

ADDRESS FOR CORRESPONDENCE: Dr. Udaya Prashant Ponangi, The Townsville Hospital, 100 Angus Smith Drive, Douglas, Queensland 4814, Australia. E-mail: udayprashant79@gmail.com.

REFERENCES

1. Stundl A, Lucht H, Shamekhi J, et al. Early versus newer generation transcatheter heart valves for transcatheter aortic valve implantation: echocardiographic and hemodynamic evaluation of an all-comers study cohort using the dimensionless aortic regurgitation index (AR index). *PLoS One* 2019;14:e0217544.
2. Sinning JM, Hammerstingl C, Vasa-Nicotera M, et al. Severity of peri-prosthetic regurgitation and predicts outcome in patients after transcatheter aortic valve implantation. *J Am Coll Cardiol* 2012;59:1134-41.
3. Kumar S, Moseman B, Vietmeier K, et al. Stent geometry and radial force comparison of Portico vs CoreValve (abstr). *Circulation* 2014;130 Suppl 2: A16952.
4. Vavouranakis M, Vrachatis DA, Toutouzas KP, Chrysohoou C, Stefanadis C. "Bail out" procedures for malpositioning of aortic valve prosthesis (CoreValve). *Int J Cardiol* 2010;145:154-5.
5. Valkov V, Kalchev D, Kostadinov A, et al. Snare maneuver for management of low TAVI implantation: clinical case. *J IMAB* 2018;24: 2034-7.
6. Beute TJ, Nolan MA, Merhi WM, Leung Wai Sang S. Use of EN Snare device for successful repositioning of the newest self-expanding transcatheter heart valve. *SAGE Open Med1 Case Rep* 2018;6:2050313X18819933.

KEY WORDS aorta, aortic valve, valve replacement