

# A Typical but Rare Case of Solitary Tinea Auricularis

Wenting Hu , Xiujiào Xia, Yangyang Ma, Ai-E Xu

Department of Dermatology, Hangzhou Third People's Hospital, Affiliated Hangzhou Dermatology Hospital of Zhejiang University School of Medicine, Hangzhou, People's Republic of China

Correspondence: Ai-E Xu, Hangzhou Third People's Hospital, 38 Xihu Ave, Hangzhou, 310009, People's Republic of China, Email xuaiehz@hotmail.com

**Abstract:** Tinea auricularis is a rare superficial fungal infection, which is easily ignored in clinic due to its atypical clinical symptoms or being accompanied with tinea capitis. In this study, a case of annular erythema with scales around the ear canal orifice was reported. After fungal culture and identification, the patient was diagnosed with *Trichophyton rubrum* infection, and was cured after 3 weeks of topical use of clotrimazole cream.

**Keywords:** tinea auricularis, ear, infection, *Trichophyton rubrum*

## Introduction

Tinea auricularis refers to the uncommon and neglected dermatophytosis. Most of the tinea auricularis cases have tinea capitis or tinea faciei involving the ears,<sup>1</sup> with the clinical manifestations of imitated eczematous erythema.<sup>2</sup> Solitary tinea auricularis is rarely seen in clinic. Here, a case of typical tinea auricularis that might be related to previous infection and antimicrobial treatment was reported.

## Case Presentation

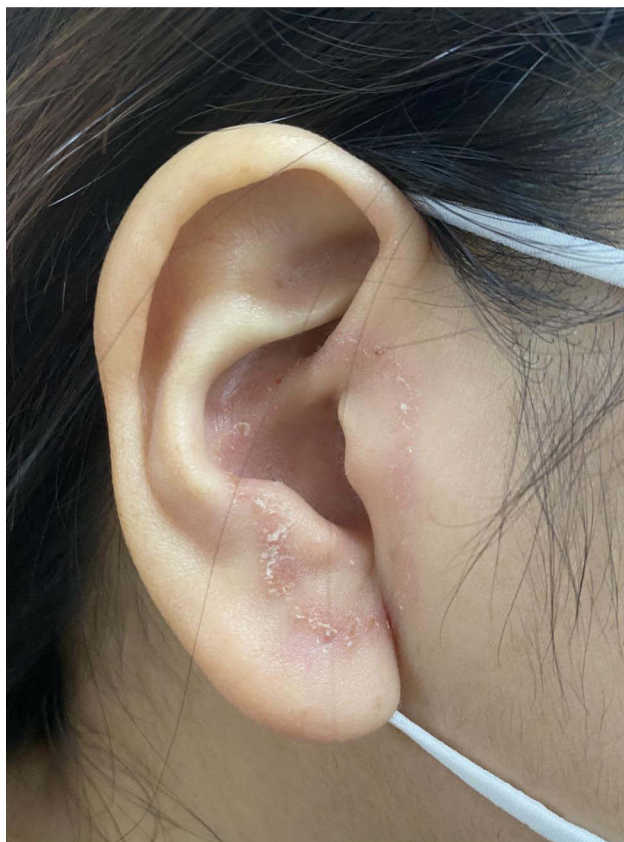An otherwise healthy, 35-year-old woman presented to the dermatology clinic with a 2-week history of rash on her right ear. She was previously diagnosed with eczema and topical use of desonide cream failed. On physical examination, there was annular erythema with scaly borders centered around the external acoustic pore ([Figure 1](#)), with no retro-auricular, scalp or face involvement. Skin scrapings were collected from the patient. Direct microscopic examination was positive ([Figure 2](#)), and all fungal cultures grew colonies of *Trichophyton rubrum* (GenBank accession number: OP856520 [isolated from the patient, 629bp]). The patient was diagnosed with tinea auricularis.

After inquiry, the patient reported experiencing suppurative otitis media one month ago, which was treated with levofloxacin combined with dexamethasone under endoscopic irrigation. Local infection or external drug application may change the local skin immune situation and microbiota, which then becomes one of the causes of fungal infection. Treatment with topical clotrimazole cream was initiated and after 3 weeks of therapy the skin lesions had resolved. The patient was contacted 3 months after the completion of therapy, and she confirmed that there had been no recurrence of the rash.

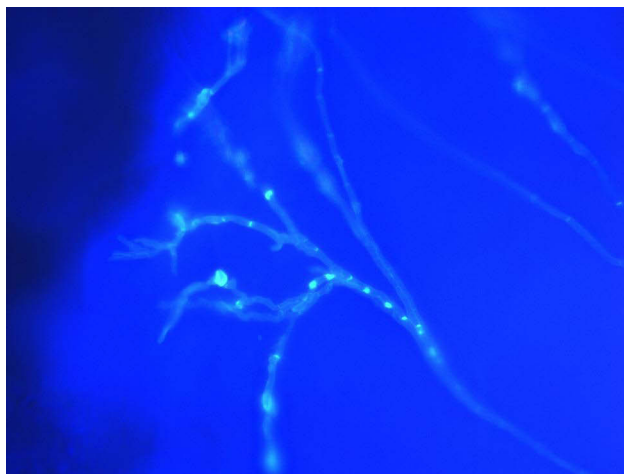
## Discussion

Superficial fungal infection of auricle is rarely reported, and there is no typical annular erythema in the reported cases of tinea auricularis at present, with itching and accumulation of cerumen being the most common symptoms. One study performed microscopic examination of fungi on patients with skin symptoms in the ear, and discovered positive results in 19 (35%) out of 54 patients, over the age of 44 years.<sup>2</sup> It reminds us that for old patients with skin symptoms in the ear, microscopic examination of fungi should be actively performed to exclude the possibility of infection. Thus, tinea auricularis was rarely occurs in young adults.

According to a recent study, tinea auricularis mostly coexists with tinea faciei or capitis.<sup>1</sup> It has been found that most children with tinea capitis also have ear involvement, which is also called the “ear sign”.<sup>3</sup> Solitary tinea auricularis is uncommon. Zhi et al reported a case of child with unidentifiable ear auricularis, which manifested as persistent erythematous papules and pruritus in the left ear.<sup>4</sup> Hamzelou et al reported an 80-year-old man with fungal



**Figure 1** Annular erythema on the right ear.



**Figure 2** Numerous septate hypha could be detected under calcofluor white staining (magnification  $\times 400$ ).

infection on the ear who presented with the clinical manifestations of erythema, scales and pustules. Tinea auricularis is uncommon and easily misdiagnosed; however, the notable observation is the sole involvement of the ear.

## Conclusion

In conclusion, we reported a case of annular erythema with scales around the ear canal orifice. For young and middle-aged patients with ear skin symptoms, previous histories of infection and treatment should be taken into consideration. Typically, microscopic examination of fungi is recommended for those with related history of infection and treatment.

## Patient Consent and Ethics Statement

The patient provided informed consent for publication of the case. No ethical committee approval was required for this study as the data had been analyzed in a retrospective manner.

## Author Contributions

All authors contributed to data analysis, drafting or revising the article, have agreed on the journal to which the article will be submitted, gave final approval of the version to be published, and agree to be accountable for all aspects of the work.

## Funding

This study was supported by Health Science and Technology Projects of Hangzhou (A20220451 and A20220441).

## Disclosure

The authors report no conflicts of interest in this work.

## References

1. Verma SB, Panda S, Nenoff P, et al. The unprecedented epidemic-like scenario of dermatophytosis in India: I. Epidemiology, risk factors and clinical features. *Indian J Dermatol Venereol Leprol.* 2021;87:154–175. doi:10.25259/IJDVL\_301\_20
2. Morinaka S. Dermatophytosis of the ear. *Otolaryngol Head Neck Surg.* 2005;133:113–115. doi:10.1016/j.otohns.2005.03.029
3. Agarwal U, Sitaraman S, Panse GG, Bholra K, Besarwal RK. Useful sign to diagnose tinea capitis-'ear sign'. *Indian J Pediatr.* 2012;79:679–680. doi:10.1007/s12098-011-0571-1
4. Zhi HL, Xia XJ, Liu ZH. Tinea auricularis: a neglected tinea incognito. *Clin Exp Dermatol.* 2022;47:1179–1180. doi:10.1111/ced.15109
5. Hamzelou S, Jafari M, Aminizadeh E, Allameh SF. An 80-year-old man with erythema, scales and pustules on the left ear auricle. *BMJ Case Rep.* 2014;2014:bcr-2014-203758–bcr-2014–203758. doi:10.1136/bcr-2014-203758

Infection and Drug Resistance

Dovepress

### Publish your work in this journal

Infection and Drug Resistance is an international, peer-reviewed open-access journal that focuses on the optimal treatment of infection (bacterial, fungal and viral) and the development and institution of preventive strategies to minimize the development and spread of resistance. The journal is specifically concerned with the epidemiology of antibiotic resistance and the mechanisms of resistance development and diffusion in both hospitals and the community. The manuscript management system is completely online and includes a very quick and fair peer-review system, which is all easy to use. Visit <http://www.dovepress.com/testimonials.php> to read real quotes from published authors.

Submit your manuscript here: <https://www.dovepress.com/infection-and-drug-resistance-journal>