

REVIEW ARTICLE

Maculopapular skin eruptions associated with Covid-19: A systematic review

Saad Shams¹ | Sawai Singh Rathore²  | Priyanka Anvekar³ | Manush Sondhi⁴  |
Neeraj Kancharla⁵ | Sohaib Tousif⁶ | Gianpier Alonzo Rojas^{7,8}  |
Noman Khurshid Ahmed⁹ | Mehwish Munawwar¹⁰ | Muhammad Noman¹¹

¹Internal Medicine, Ross University School of Medicine, Miramar, Florida

²Internal Medicine, Dr. Sampurnanand Medical College, Jodhpur, India

³Internal Medicine, MGM Medical College and Hospital, Aurangabad, India

⁴Internal Medicine, Kasturba Medical College, Manipal, India

⁵Internal Medicine, Andhra Medical College, Visakhapatnam, India

⁶Internal Medicine, Ziauddin Medical University, Karachi, Pakistan

⁷Internal Medicine, School of medicine, Universidad Peruana Cayetano Heredia, Lima, Peru

⁸Scientific Society of Medical Students, Cayetano Heredia, Lima, Peru

⁹Internal Medicine, Dow Medical College, Karachi, Pakistan

¹⁰Internal Medicine, Liaquat College of Medicine and Dentistry, Karachi, Pakistan

¹¹Internal Medicine, Ziauddin Medical College, Karachi, Pakistan

Correspondence

Sawai Singh Rathore, Medical student, Dr. Sampurnanand Medical College, Shastri Nagar, Residency Road, Jodhpur, India.
Email: sawais.rathore77@gmail.com

Abstract

In this systematic review, we anticipated in summarizing clinical features, histopathological hallmarks, and possible pathology behind the maculopapular skin eruptions occurring in Covid-19 patients. A literature search was executed using MEDLINE/PubMed and Embase databases for articles published till 20 November 2020. All eligible articles including observational studies, case reports, and case series reporting the maculopapular skin lesion in Covid-19 patients were included. Data were obtained for 354 Covid-19 patients presenting with maculopapular lesions from 40 studies. The mean age of these patients was 53 years, and with 42% of them being male. These maculopapular lesions differed considerably in terms of distribution and appearance, ranging from diffuse erythematous maculopapular lesions to scattered erythematous macules coalescing into papules to maculopapular lesions in plaques. The mean duration of the lesion was 8 days. These lesions were frequently localized on trunks and extremities. Superficial perivascular dermatitis with lymphocytic infiltrate was a histopathological hallmark of these lesions. As these skin lesions may have a possible association with diagnosis, management, prognosis, and severity of the disease, all health practitioners need to be well acquainted with these Covid-19 skin lesions. Also, in the middle of this worldwide pandemic, early identification of this eruption may help manage this infection's further spread.

KEYWORDS

Covid-19, SARS-CoV-2, skin, skin diseases, viral exanthema

1 | INTRODUCTION

A new infectious pathogen called severe acute respiratory syndrome (SARS-CoV-2) came into view in Wuhan, China, in December 2019¹. It was associated with an unconventional cause of pneumonia. The disease was later entitled Coronavirus disease 2019 (Covid-19). Following then it has quickly disseminated across the globe. Due to its asymptomatic transmission, high infectivity rate, and high mortality rate among the elderly and immunocompromised, it was declared a pandemic by the world health organization on March 11. By through

end of November, 63 million cases of Covid-19 have been documented worldwide, accompanied by 1.34 million deaths.²

SARS-CoV-2 is a β -Coronavirus, which is an enveloped, positive-sense, single-stranded RNA virus.³ SARS-CoV-2 enters the human cell via protein receptor angiotensin-converting enzyme 2 (ACE2) and causes infection. Despite the fact that this virus predominantly targets the respiratory tract, several human tissues, including gastrointestinal and skin tissue have been discovered to have ACE2 expression, this may contribute to dermatologic finding present in Covid-19.⁴

The clinical manifestation of Covid-19 is pretty diverse, extending from mild symptoms to critical lethal respiratory failure, septic shock, ultimately to multiorgan failure. The most common clinical symptoms of SARS-CoV-2 infection include fever, dry cough, fatigue, sore throat, and dyspnea, and headache; less commonly, vomiting, diarrhea, and anosmia or ageusia.¹ Besides these typical symptoms, new symptoms including a range of cutaneous manifestations have been recorded globally. The first record of cutaneous signs was documented in a study from China, in this study out of 1099 Covid-19 patients only, 2 (0.2%) presented with cutaneous manifestation.⁵ Later another report from Italy reported a higher prevalence of about 21% of the patient out of 88 presenting with cutaneous manifestation.⁶ Subsequently, many case reports and case series have been published reporting this manifestation in Covid-19 patients. These cutaneous lesions vary greatly in terms of clinical features of which maculopapular eruptions seem to be one of the most common lesions occurring in about 22% to 47% of Covid-19 cases presenting with cutaneous manifestation.⁷⁻⁹

As these lesions may provide a sooner and more reliable diagnosis and management of the infection, It is important for all health practitioners to be well acquainted with these Covid-19 skin lesions. Also, in the middle of this worldwide pandemic, early identification of this eruption may also help in managing the further spread of this infection. In this systematic review, we aim to summarize clinical features, histopathological hallmarks, and possible pathology behind the maculopapular skin lesion occurring in Covid-19 patients.

2 | METHODS

The existing systematic review is accomplished and reported in conjunction with preferred reporting items for systematic reviews and meta-analyses (PRISMA) guidelines.¹⁰

2.1 | Search strategy

A literature search was executed using MEDLINE/PubMed and Embase databases for articles published from December 2020 till 20 November 2020. Following search terms were used, ([Coronavirus] or [Covid-19] or [SARS-CoV-2] and [skin] or [cutaneous] or [rash] or [maculopapular]OR [exanthem]). Studies from all over the world without any language constraints were included. On the basis of the title and abstract, eligibility for the article was determined. Reference lists of the incorporated studies and associated literature were manually inspected for additional qualifying studies. PRISMA flow diagram is illustrated in Figure 1.

2.2 | Eligibility criteria

All eligible articles including observational studies, case reports, and case series reporting the maculopapular skin lesion in Covid-19

patients were included. Articles like review articles, hypothesis articles, and commentaries were discarded.

2.3 | Study selection and data extraction

The title and abstract of studies from formerly investigated databases were evaluated by three authors (S. T., N. K.). These authors ascertained studies, on the basis of predetermined eligibility criteria. From these selected studies, three authors (S. S. R., P. A., M. S.) retrieved data manually. For every report, subsequent details were extracted, author, country of origin, study design, sample size, mean age, clinical features of skin lesions, mean duration, location of skin lesion, sign, and symptoms, laboratory findings, histopathological findings, treatment of Covid-19, and outcome of the lesion.

3 | RESULT

A total of 354 patients with Maculopapular eruption were included from 40 studies. The average age of these patients was 53 years (which ranged from 6 months to 84 years) with 42% of them being male. Most of the published cases were from Spain (224 patients,63%) followed by France (33 patients, 9.3%), Italy (31 patients, 8.7%), Turkey (14 patients, 3.9%), United States (5 patients, 1.4%), India (3 patients, 0.8%), Thailand (2 patients, 0.5%).There was one case each from the UK, Portugal, Russia, Poland, Japan. 38(10.7%) patients were from the multinational registry. Considering many cutaneous manifestation cases might not have been documented in the literature for numerous reasons, these data are not consistent with the actual cutaneous lesion occurrence in Covid-19 patients from different countries. Table 1 compiles the study characteristics and patient demographics information.

3.1 | Clinical characteristics of maculopapular lesion

Maculopapular lesions are one of the most frequent skin manifestations observed during the Covid-19 pandemic. Adverse drug reactions or viral infections(eg, HHV-6, HIV-1, HHV-4) are important triggers for this type of lesion.¹¹ When caused by viral or bacterial infections they are often linked with fever, myalgia, headache, and fatigue. Ebstein Barr virus infection, Herpes, scarlet fever, Measles, Ebola, Zika, and HIV are common viral infections associated with maculopapular rash.¹² The maculopapular eruption is prominent on the chest, back, abdomen, and extremities and can range from confluent lesions to erythematous, scattered blanching rash.

Article stating the association of maculopapular rash with Covid-19 infection has diverse clinical depiction. Distribution and appearance of maculopapular eruption ranged from diffuse erythematous maculopapular lesions to scattered erythematous macules coalescing into papules to maculopapular lesions in plaques to erythematous

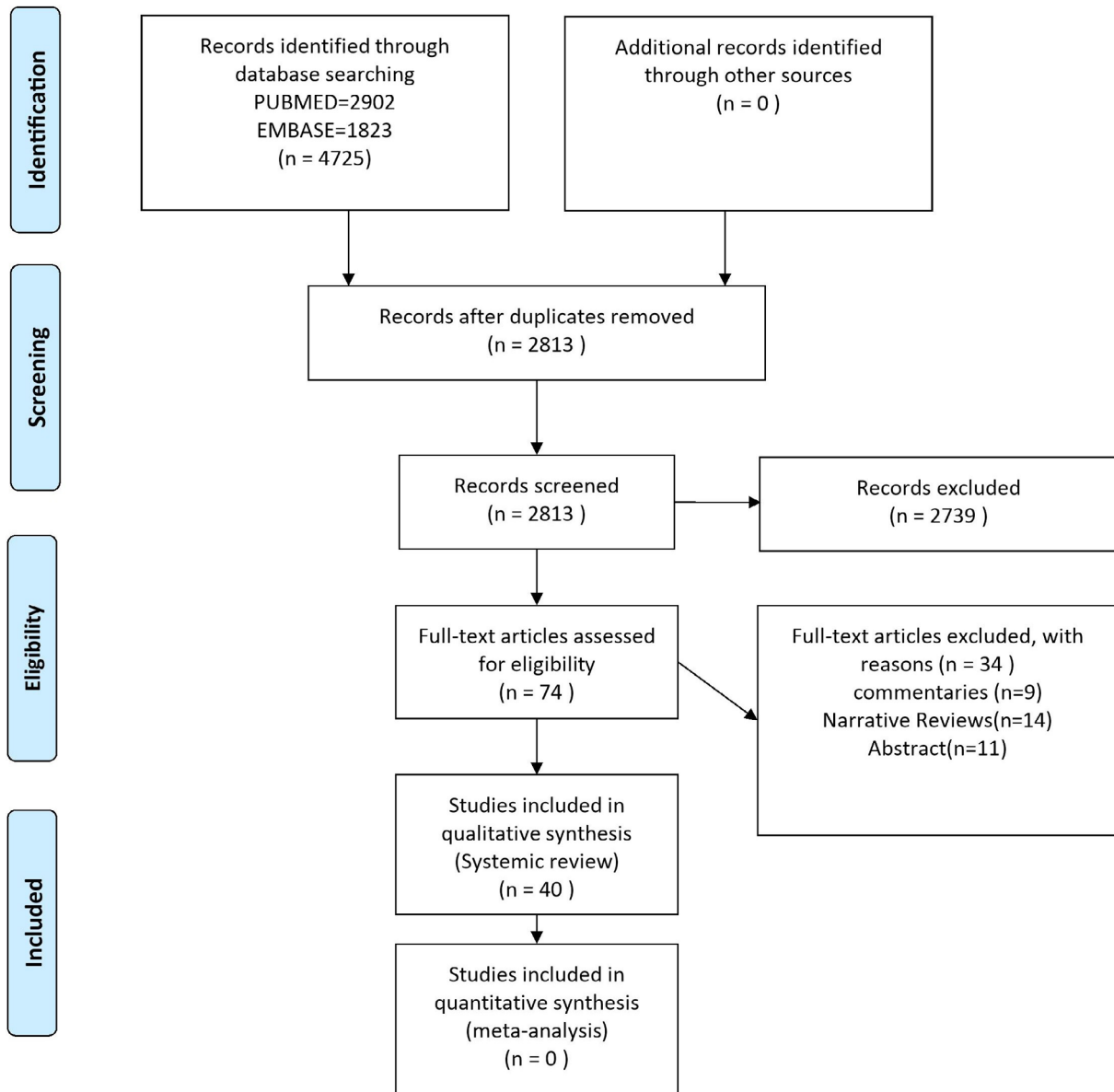


FIGURE 1 Preferred reporting items for systematic reviews and meta-analyses (PRISMA) flow diagram

macules and plaques with a violaceous targetoid appearance. Some maculopapular lesions associated with Covid-19 were marked by a petechial portion.¹³⁻¹⁶ Detailed clinical characteristics features of the lesion from each study are compiled in Table 2.

Many lesions presented with itching while in few cases manifested with a burning sensation.^{9,17} Two reports described the painful character of maculopapular lesion.^{8,18} Some reports have identified a substantial craniocaudal development of a rash, involving the folds without the engagement of the palmar-plantar area and the mucous membranes.^{15,19} Dalal et al reported the centripetal distribution of maculopapular lesions.²⁰

These maculopapular eruptions vary based on the location of the lesion and are most commonly localized in trunks and extremities. However, these lesions have been reported from on the head and face, on the neck, and in periaxillary areas.^{9,15,19,21-24} These eruptions

are diverse in the duration for which they remain on the skin. While not all studies commented on the mean length of these cutaneous manifestations, with available data for 249 patients, the lesion's mean duration was 8 days with a range of 2 to 14 days.

In most of the studies, lesions appeared either at onset or after the onset of other symptoms of Covid-19 however, few studies reported the appearance of rash 2 to 3 days before the onset of symptoms.^{8,9,25,26} One observational study suggested an increased severity of Covid-19 illness in patients with maculopapular lesions, which was established by a 2% mortality rate recorded in those patients.⁸

The most frequent medication used in these patients with maculopapular lesions were hydroxychloroquine/chloroquine (46.5% patients), paracetamol (31.8% patients), lopinavir/ritonavir (28.8% patients), and azithromycin (20.7%). No medication was used in about

TABLE 1 Study characteristics and patients demographics

First author	Location	Study type	Covid-19 status (diagnostic technique)	Sample size(n) ^a	Mean age (years) and gender (male or female)	Cases having maculopapular eruptions
Ahouach et al ¹⁷	France	Case report	Positive (PCR)	1	57/F	1
Diaz-Guimaraens et al ¹³	Spain	Case report	Positive (PCR)	1	48/M	1
Galvan Casas et al ⁸	Spain	Retrospective study	Positive (n/m): 122/176 (69.3%), suspected: 54/176 (30.6%)	375	55.3/44% Male	176
Gianotti et al ²⁵	Italy	Case series	Positive (PCR)	3	68/33% Male	3
Hunt et al ³⁹	United States	Case report	Positive (PCR)	1	20/M	1
Najarian et al ⁴⁰	United States	Case report	Positive (PCR)	1	58/M	1
Sachdeva et al ³⁰	Italy	Case series	Positive (PCR)	3	74/100% Female	2
Askin et al ²⁹	Turkey	Cohort	Positive (PCR): 34/52 (65.4%) negative: 18/52 (34.6%)	52	N/M	12
Dalal et al ²⁰	India	Cohort	Positive (PCR)	102	49/66% Male	3
Herrero-Moyano et al ²¹	Spain	Case series	Positive (n/m)	8	72.2/50% Male	8
Reymundo et al ³⁸	Spain	Case series	Positive (PCR)	7	66.57/28.6% Male	7
Rubio-Muniz et al ²⁸	Spain	Case series	Positive PCR: 6/10 (60%) positive radiology: 3/10 (30%) negative PCR: 1/10 (10%)	34	53/40% Male	10
Bouaziz et al ⁴¹	France	Case series	Positive (PCR)	14	N/M	4
Recalcati et al ⁶	Italy	Case series	Positive (n/m)	18	N/M	14
Mahe et al ²²	France	Case report	Positive (PCR)	1	64/F	1
Hedou et al ⁴²	France	Prospective study	Positive (PCR)	103	N/M	2
Morey-Olivé et al ⁴³	Spain	Case report	Positive (PCR)	1	6/Male	1
Rivera-Oyola et al ¹⁴	United States	Case report	Positive (PCR)	1	60/Male	1
Avellana Moreno et al ¹⁵	Spain	Case report	Positive (PCR)	1	32/Female	1
Jimenez-Cauhe et al ¹⁶	Spain	Case report	Positive (n/m)	1	84/Female	1
Gaspari et al ²³	Italy	Case series	Positive (n/m)	20	N/M	9
Rosell-Diaz et al ²⁷	Spain	Case series	Positive (PCR)	12	66.3/50% Male	12
Olisova et al ⁴⁴	Russia	Case report	Positive (PCR)	1	12/Female	1
Klimach et al ¹⁸	UK	Case report	Positive (PCR)	1	1/Male	1
Jones et al ³¹	United States	Case report	Positive (n/m)	1	6 mo/Female	1
De Masson et al ²⁴	France	Retrospective study		277	29/48% Male	25
Freeman et al ⁹	Multinational	Case series from an international registry	Positive (PCR):135(78.9%), positive (serology);19(11.1%), positive (unspecified testing);17(10%)	171	N/M	38
Carbrera-Hernandez et al ⁴⁵	Spain	Case report	Positive (PCR)	1	58/Female	1
Paolino et al ¹⁹	Italy	Case report	Positive (n/m)	1	37/Female	1
Zengarini et al ⁴⁶	Italy	Case report	Positive (PCR)	1	67/Female	1

TABLE 1 (Continued)

First author	Location	Study type	Covid-19 status (diagnostic technique)	Sample size(n) ^a	Mean age (years) and gender (male or female)	Cases having maculopapular eruptions
Mendez-Maestro et al ⁴⁷	Spain	Cohort	Positive (PCR or serology)	75	N/M	4
Öksüm Solak et al ⁴⁸	Turkey	Case report	Positive (radiological)	1	24/Female	1
Farabi et al ⁴⁹	Turkey	Case report	Positive (PCR)	1	55/Female	1
Rossi et al ⁵⁰	Italy	Case report	Positive(PCR)	1	34/Male	1
Mazan et al ⁵¹	Poland	Case report	Positive (PCR)	1	35/Male	1
Goncalves et al ³⁷	Portugal	Case report	Positive (PCR)	1	57/Male	1
Motahashi et al ⁵²	Japan	Case report	Positive (PCR)	1	52/Male	1
Punyaratabandhu et al ⁵³	Thailand	Case series	Positive(PCR)	2	51/100 %Female	2
Lopez et al ²⁶	Spain	Case report	Positive (PCR)	1	31/Female	1
Beaupre et al ⁵⁴	United States	Case report	Positive (PCR)	1	42/Female	1

Abbreviations: Covid-19, Coronavirus disease 2019; PCR, polymerase chain reaction; N/M, not mentioned.

^aSample size denotes total COVID-19 infected patients in a each study.

16.3% of patients. The summary of medications used across all patients is consolidated in Table 3.

3.2 | Histopathological hallmarks

From the histological perspective, several features of the maculopapular lesion have been recognized. Maculopapular lesions exhibit superficial perivascular dermatitis with lymphocytic infiltrate and dilated vessels in the papillary and mid dermis with neutrophils, eosinophils, and nuclear debris. Epidermis revealed dispersed foci of hydropic changes, accompanied by minimum acanthosis, subcorneal pustules, slight spongiosis, Basal cell vacuolation, and foci of parakeratosis. One study by Rosell-Diaz et al showed a lichenoid pattern with eosinophils' presence on biopsy of skin lesions.²⁷ Table 4 summarizes histopathological features reported from different studies.

Rubio-Muniz et al described the histology of rashes according to the onset of lesion. Early-onset lesions exhibited perivascular lymphocytic infiltrate with eosinophils in the dermis with moderate epidermal spongiosis. In comparison, perivascular lymphocytic infiltrate and histiocytes contained in collagen fibers were seen in the histology of late-onset cases. These late-appearing lesions lack mucin deposits.²⁸

4 | DISCUSSION

The consequences of the SARS-CoV-2 pandemic are severe, as it had health-related, economic, and social impacts on millions of peoples around the globe. Owing to asymptomatic transmission, high infectivity rate, and droplet infection of SARS-COV-2, it has become horribly challenging to control this virus. Dermatological interpretation of

Covid-19 originally thought not to be very important has proved to be diverse and sophisticated. Regardless of rapidly evolving research, the number of skin manifestations of Covid-19 remains largely unexplained. Owing to the absence of large-scale prospective studies, the true prevalence of skin manifestations in Covid-19 is hard to interpret. Incidents of dermatological lesions in Covid-19 highly vary according to published literature and extent from 0.6% to 20.4%.^{5,6}

Maculopapular eruptions seem to be one of the most common cutaneous manifestations occurring in Covid-19 patients.⁸ Although there are reports of maculopapular lesions associated with Covid-19 patients in published literature, they remain to be appraised systematically. This systematic review aims to fill that gap, by compiling the characteristics of 354 patients from 40 studies originating from 12 different countries. Investigators have variedly characterized maculopapular lesions in Covid-19 patients as erythematous, purpuric rash, and morbilliform. This lesion appears after the onset of other symptoms of Covid-19 in most cases, however, few studies reported the appearance of eruptions before any other symptoms. Since Covid-19 infection has the propensity to remain asymptomatic for 10 to 14 days, these signs can assist in early detection of Covid-19 and prevent the spread of this highly contagious illness.

As stated in the result, these lesions vary in distribution and appearance. Other than that, a few peculiar patterns of the maculopapular lesion have been reported. Few studies reported perifollicular lesions coupled with scaling and confluence, which may lead to an appearance similar to pityriasis rosea.^{8,29} Similarly, In a study by Galvan Casas et al few patients exhibited infiltrated papules on the extremities, principally the dorsum of the hands, that resemble pseudovesicular just like erythema elevatum diutinum or erythema multiforme.⁸ Sachdeva et al reported a Maculopapular pruritic rash resembling that of Grover disease in one patient.³⁰ One of the studies

TABLE 2 The clinical characteristic feature of the maculopapular lesions

Author	Clinical features of maculopapular lesions	Mean duration of the lesion	Location of lesions	Relation to the onset of other Covid-19 symptoms	Outcome of lesion	Treatments for Covid-19	Signs, symptoms, laboratory, and radiological findings
Ahouach et al ¹⁷	Diffuse erythematous blanching maculopapular lesions, with the burning sensation only on the palm	9 d	Trunk and limbs	After	Slowly resolved	Paracetamol	Fever (39°C) and dry cough
Diaz-Guimaraens et al ¹³	Mildly pruritic, confluent erythematous macules, papules, and petechiae in symmetric perifflexural distribution	5 d	Buttocks and legs	3 d after	Slowly resolved	Hydroxychloroquine, lopinavir/ritonavir, and azithromycin	Fever (up to 39°C), pleuritic chest pain, and shortness of breath. Increased C-reactive protein and D-dimer level, ground-glass opacities on chest radiograph
Galvan Casas et al ⁸	Maculopapular eruptions with itching (99 patients), pain (4 patients), and burning (9 patients). Few maculopapular lesions were interpreted as resembling pityriasis rosea.	8.6 d	Generalized	Before-3 patients, At onset-108, After -60 patients	Slowly resolved	Paracetamol, NSAIDs, Chloroquine, Hydroxychloroquine, Lopinavir/ritonavir, Tocilizumab, systemic corticosteroid, Azithromycin	Fever, Cough, dyspnea, asthenia, headache, nausea, vomiting, diarrhea, anosmia, Pneumonia
Gianotti et al ²⁵	Widespread erythematous macules with the presence of pruritis in one patient	7.7 d	Trunk-3 patients, Arms-2 patients, Legs-1 patient	Before (1 patient), After (2 patients)	Slowly resolved	Lopinavir/ritonavir, heparin and levofloxacin, Ceftriaxone and azithromycin, Hydroxychloroquine	Fever, headache, cough and arthralgias, elevated transaminase and fibrinogen level in one patient
Hunt et al ³⁹	Non-pruritic, Diffuse morbilliform maculopapular rash sparing the face	N/M	Trunk and limbs	At onset	N/M	N/M	Fever, pneumonia, elevated C-reactive proteins
Najarian et al ⁴⁰	A pruritic diffuse morbilliform rash	2 d	Limbs, shoulders, trunk, chest, and abdomen	After	Slowly resolved	Azithromycin and benzonatate	Cough, pain in legs and hands, no fever
Sachdeva et al ³⁰	A maculopapular pruritic rash appearing like that of Grover disease in one patient while Morbilliform rash and hemorrhagic macular rash on legs in another	N/M	Trunk and limbs	After in one patient while at onset in another	Slowly resolved	Lopinavir/ritonavir and hydroxychloroquine and subcutaneous low molecular weight heparin	Cough, fever, lymphadenopathy, arthralgia, headache, and myalgia

TABLE 2 (Continued)

Author	Clinical features of maculopapular lesions	Mean duration of the lesion	Location of lesions	Relation to the onset of other Covid-19 symptoms	Outcome of lesion	Treatments for Covid-19	Signs, symptoms, laboratory, and radiological findings
Askin et al ²⁹	Diffused Maculopapular rash, with one of the lesions on the trunk resembling pityriasis rosea	N/M	Trunk (most of the patients), on the extremities in one patient	N/M	N/M	N/M	N/M
Dalal et al ²⁰	Maculopapular rash with centripetal distribution	N/M	Trunk and limbs	After	Slowly resolved	Hydroxychloroquine, Azithromycin	Sore throat, cough, fatigue, headache, fever, cough and, dyspnoea
Herrero-Moyano et al ²¹	Indistinct erythematous patches to coalescent maculopapules, some with a violaceous center, in one patient progressed into pustules and desquamation	12 d	Trunk-7 patients, Flexures-4 patients, Proximal extremities-2 patients, Face-2 patients	N/M	N/M	Hydroxychloroquine, lopinavir/ritonavir, ceftriaxone, metformin, linezolid, piperacillin-tazobactam, amiodarone, furosemide	N/M
Reymundo et al ³⁸	Diffused maculopapular rash	11 d	Trunk-7 patients, Proximal upper limb involvement-6 patients, Lower limb involvement-1 patient	After	Slowly resolved	Systemic corticosteroid	Pneumonia
Rubio-Muniz et al ²⁸	Erythematous Maculopapular exanthems	N/M	N/M	After	N/M	N/M	Pneumonia in 8 patients
Bouaziz et al ⁴¹	Maculopapular exanthema	N/M	N/M	N/M	N/M	N/M	N/M
Recalcati et al ⁶	Mild itching or asymptomatic rash	N/M	Mainly trunk	N/M	Resolved a few days later	N/M	N/M
Mahe et al ²²	An erythematous rash resembling as remniscent of symmetrical drug-related intertriginous and flexural exanthema (SDRIFE)	5 d	Trunk and Flexors	N/M	Resolved a few days later	Paracetamol	Fever (up to 40° C) and asthenia
Hedou et al ⁴²	Maculopapular rash with Itching	N/M	Trunk and neck that gradually spanning to the cheeks and upper and lower extremities	N/M	Resolved a few days later	N/M	N/M
Morey-Olivé et al ⁴³	Erythematous, confluent, non-pruritic maculopapular rash	5 d	Generalized	After	Resolved a few days later	N/M	The fever increased bilirubin and transaminases

(Continues)

TABLE 2 (Continued)

Author	Clinical features of maculopapular lesions	Mean duration of the lesion	Location of lesions	Relation to the onset of other Covid-19 symptoms	Outcome of lesion	Treatments for Covid-19	Signs, symptoms, laboratory, and radiological findings
Rivera-Oyola et al ¹⁴	Scattered erythematous macules coalescing into papules, 1 wk later purpuric round macules developed in the areas of the previous eruption.	N/M	Back, bilateral aspect of the flanks, groin, and proximal lower limb	After	Resolved a few days later	None	Low-grade fever (38°C), myalgias, fatigue, mild cough
Avellana Moreno et al ¹⁵	Generalized, itching morbilliform lesions with cephalocaudal growth, characterized as a petechial and erythematous maculopapular lesion. A scaly reaction observed on the fourth day	4 d	Face, neck, thorax, abdomen, buttocks, extremities, including folds and scalp	After	N/M	N/M	Fever, myalgia, asthenia, cough, and diarrhea
Jimenez-Cauhe et al ¹⁶	Erythematous purpuric, coalescing macules	N/M	Periaxillary regions	After	N/M	Hydroxychloroquine and lopinavir/ritonavir	N/M
Gaspari et al ²³	Erythematous exanthema	N/M	Trunk and face	N/M	N/M	N/M	N/M
Rosell-Diaz et al ²⁷	Generalized maculopapular confluent exanthema with itching	N/M	Generalized	After	Slowly resolved	Hydroxychloroquine, Lopinavir/Ritonavir, ceftriaxone, azithromycin	Fever, pneumonia
Olisova et al ⁴⁴	Purpuric eruptions and erythematous macula rash and swollen tongue with lingual papillae	3 d	Upper eyelids, above the eyebrows, and in the temporal region	After	Slowly resolved	Paracetamol	Fever, fatigue, and headache
Klimach et al ¹⁸	Erythematous papular rash in the axillae. Multiple painful, erythematous papules on plantar surface of lower limb	14 d	Axillae and lower extremities	After	N/M	Paracetamol	Fever, myalgia, and headache
Jones et al ³¹	Blanching, polymorphous maculopapular rash	N/M	Generalized	N/M	N/M/N/M	N/M	Fever, limbic sparing conjunctivitis, hand, and feet swelling
De Masson et al ²⁴	Maculopapular rash	N/M	Trunk and limbs 25, face (in 2 patients)	N/M	N/M	N/M	Fever, Respiratory symptoms, Anosmia/ageusia, Digestive symptoms

TABLE 2 (Continued)

Author	Clinical features of maculopapular lesions	Mean duration of the lesion	Location of lesions	Relation to the onset of other Covid-19 symptoms	Outcome of lesion	Treatments for Covid-19	Signs, symptoms, laboratory, and radiological findings
Freeman et al ⁹	Pruritic to burning Morbilliform rash	7 days	Head and Face- 10 patients, Trunk- 76 patients, Upper limb-28, Lower limb-31 patients and generalized in 4 patients	Before-3 patients, after-29, at onset-5	N/M	Antimalarial agents, antibiotics, bevacizumab, remdesivir, serpin inhibitors, IL-6 inhibitors, lopinavir/ritonavir	Fever, cough, shortness of breath, sore throat, headache, myalgia, diarrhea, vomiting, ARDS in 4 patients, thrombotic event in 3 patients
Carbrera-Hernandez et al ⁴⁵	Confluent, erythematous macules and plaques with a violaceous targetoid appearance	N/M	Trunk and proximal limbs	After	Resolved	Hydroxychloroquine, Azithromycin, Lopinavir/Ritonavir	Fever, cough, dyspnea, myalgia, pneumonia
Paolino et al ¹⁹	Erythematous maculopapular lesions without itching	8 d	Trunk, neck, and face	After	Resolved		Fever (up to 39°C), dry cough, myalgia, and arthralgia
Zengarini et al ⁴⁶	Itching erythematous confluent lesion, with ill-defined border	7 d	Neck, trunk, and proximal portions of upper and lower extremities	After	Resolved	Hydroxychloroquine, omeprazole, piperacillin/tazobactam, and remdesivi	Dyspnoea and fever
Mendez-Maestro et al ⁴⁷	Maculopapular exanthemas	N/M	Trunk and proximal extremities, one case of flexural involvement	After	N/M	Hydroxychloroquine, omeprazole, piperacillin/tazobactam, and remdesivir	N/M
Öksüm Solak et al ⁴⁸	Erythematous maculopapular, eruptions 1–2 mm in caliber, scattered on the body and separated from each other, while some advanced into patches and plaques	N/M	Generalized, more prominent on extremities	After	N/M	Hydroxychloroquine, oseltamivir, and azithromycin	Cough and fever, Pneumonia, Peripheral ground-glass appearance in both lungs on CT
Farabi et al ⁴⁹	Erythematous, maculopapular lesions, 2 to 5 mm diameter lesions	3 d	Bilateral jawline and periauricular area	After	N/M	Favirapir and hydroxychloroquine	Malaise and fatigue
Rossi et al ⁵⁰	Non-pruritic erythematous maculopapular rash	5 d	Generalized	After	Resolved	Acetaminophen, Hydroxychloroquine, and Tocilizumab	Fever, Dyspnoea
Mazan et al ⁵¹	Itchy, maculopapular rash with non-tender erythematous macules and papules	10 d	Trunk and arms	After	Resolved	Lopinavir/ritonavir	Optic neuritis

(Continues)

TABLE 2 (Continued)

Author	Clinical features of maculopapular lesions	Mean duration of the lesion	Location of lesions	Relation to the onset of other Covid-19 symptoms	Outcome of lesion	Treatments for Covid-19	Signs, symptoms, laboratory, and radiological findings
Goncalves et al ³⁷	An erythematous papular rash with irregular borders	N/M	Elbows and Abdomen	After	N/M	None	Fever, cough, diarrhea, and, malaise. Bilateral pulmonary opacities on CT
Motahashi et al ⁵²	Non-pruritic, miliary-sized, maculopapular exanthem and erythematous confluent rash	10 d	Trunk and on the flexor surfaces of limbs	After	resolved	N/M	Fever
Punyaratabandhu et al ⁵³	Itchy maculopapular rash without mucosal involvement	5 and 7 d	Trunk and extremities	After	resolved	Favipiravir, lopinavir/ritonavir, hydroxychloroquine (HCO), azithromycin, meropenem and tocilizumab, ertapenem	Fever, cough, and muscle pain
Lopez et al ²⁶	Non-pruritic erythematous maculopapular lesions in plaques, discretely palpable	7 d	Abdomen, neckline, the inner side of the arm	Before	N/M	N/M	Fever, cough, and parenchymal consolidation in the right middle lobe on X-ray
Beaupre et al ⁵⁴	Non-blanching maculopapular rash with a concomitant non-blanching purpuric rash	N/M	Abdomen	After	N/M	N/M	Abdominal pain, nausea, vomiting, dyspnoea, diabetic ketoacidosis

Abbreviations: Covid-19, Coronavirus disease 2019; N/M, not mentioned.

TABLE 3 Summary of medications used in patients with maculopapular lesion

Medication	Total patients with available data - 271(%)
No medication	44 (16.3)
Paracetamol	86 (31.8)
Hydroxychloroquine/ chloroquine	126 (46.5)
Azithromycin	56 (20.7)
Lopinavir/ritonavir	78 (28.8)
Tocilizumab	15 (5.5)
NSAIDS	16 (5.9)
Corticosteroids	27 (10)
Ceftriaxone	14 (5.1)
Piperacillin/tazobactam	7 (2.6)
Antibiotics (other than AZ and CFT)	13 (4.8)
Heparin	5 (1.8)
Interferon-beta	9 (3.4)
Remdesivir	7 (2.6)

on Covid-19 patient-reported polymorphous maculopapular rash linked with fever, conjunctivitis, raised tongue papillae, dry cracked lips, swelling of the hands, and lower limbs satisfying the criteria for Kawasaki disease.³¹ Mahe et al described an erythematous rash involving flexors as similar to symmetrical drug-related intertriginous and flexural exanthema (SDRIFE).²² Further studies are needed to undertake to explain these lesions as, considering the diverse morphological representations, they are potentially a variegated collection of manifestations.

In Covid-19 patients, pathological pathways behind the skin lesions are poorly recognized. According to published literature, the Pathological mechanism behind Skin manifestation in SARS-COV-2 may be categorized into:

1. An immune response to viral nucleotides, clinical characteristics like viral exanthem.
2. Secondary cutaneous lesions expedited by the systemic effect of Covid-19, in particular, vasculitis and thrombotic vasculopathy.
3. Due to adverse drug reactions.

SARS-CoV-2 is a single-stranded RNA virus consisting of 16 non-structural proteins designated as NSP1 to NSP1 with unique functions in the replication of Coronaviruses (CoVs). For instance, NSP3 can block the innate immune reaction of the host and facilitate cytokine expression. Similarly, interferon (IFN) signaling is inhibited by NSP5 and NSP16 prevents MAD5 (melanoma differentiation-associated gene 5) recognition, damping innate immunity.³² Some investigations have recognized SARS-like viral particles and SARS-CoV RNA in T lymphocytes indicating direct T cell viral infection.³³ This direct T cell

TABLE 4 Histopathological features of the maculopapular lesion

Author	Histopathological hallmarks
Ahouach et al ¹⁷	Slight spongiosis and basal cell vacuolation and moderate perivascular lymphocytic infiltrate
Diaz-Guimaraens et al ¹³	Superficial perivascular lymphocytic infiltrate with a surplus of red cell extravasation and focal dermal papillary edema, accompanying by focal parakeratosis and isolated dyskeratotic cells
Gianotti et al ²⁵	Superficial perivascular dermatitis with slight lymphocytic exocytosis, patchy, swollen thrombosed vessels in the mid dermis with neutrophils, eosinophils, and nuclear debris
Herrero-Moyano et al ²¹	Subcorneal pustules, spongiosis, papillary edema, dense perivascular and neutrophilic interstitial infiltrate with the decent presence of eosinophils
Reymundo et al ³⁸	Mild superficial perivascular lymphocytic infiltrate and spongiosis
Rubio-Muniz et al ²⁸	In early-onset cases-moderate epidermal spongiosis and perivascular lymphocytic infiltrate with eosinophils in the dermis. In late-onset, cases-perivascular lymphocytic infiltrate and histiocytes within collagen fibers devoid of mucin deposits
Rivera-Oyola et al ¹⁴	Mild perivascular infiltrate with paramount of mononuclear cells around the superficial blood vessels, epidermis exhibited dispersed foci of hydropic changes, accompanying with minimal acanthosis, minor spongiosis, and foci of parakeratosis
Gaspari et al ²³	Superficial perivascular dermatitis with lymphocytic infiltrate, a dilated vessel in the papillary and mid dermis
Rosell-Diaz et al ²⁷	Superficial perivascular inflammation with eosinophils in one patient and the other displayed a lichenoid pattern with eosinophils
Freeman et al ⁹	Interface dermatitis in one patient
Carbrera-Hernandez et al ⁴⁵	Mixed interface pattern with dilated vessels filled with neutrophils, recurrent blood extravasation, and dispersed necrotic keratinocytes
Zengarini et al ⁴⁶	Superficial perivascular lymphocytic infiltrate, a remarkably dilated vessel in the papillary and mid dermis

infection may lead to a strong immune response and may be responsible for skin lesions occurring Covid-19 illness.

Hyperactive immune responses in Covid-19 patients can contribute to the induction "cytokine storm" (in particular, IL-6); these cytokines could enter the skin and trigger dermal dendritic cells, lymphocytes, macrophages, mast cells, and neutrophils, and can assist in the development of lesions such as maculopapular rash.³⁴ This representation of cutaneous lesion has been described earlier in diseases having an overactive immune response and excessive cytokine release

(example, systemic lupus erythematosus, adult Still's a disease, antiphospholipid syndrome).³⁵

Several drug therapies have been used to manage Covid-19 patients. A couple of these drugs may be involved in maculopapular eruptions. A sub-analysis done on the study by Galvan Casas et al reported that 78% of maculopapular lesions had concurrent drug consumption.³⁶ The most common drug taken by these patients was chloroquine/hydroxychloroquine, followed by lopinavir/ritonavir, tocilizumab, and azithromycin.³⁶ A case report by Mazan et al described the development of Itchy, maculopapular rash with non-tender erythematous macules and papules following 10 days of lopinavir/ritonavir administration.³⁷ In spite of this, in case series with the patients taking no new medications, the maculopapular rash has been recognized, hinting that these lesions may not just be associated with drugs.³⁸

As can be observed, Covid-19 related maculopapular rash can occur in various appearances, affect patients of all ages and genders, and affect any part of the body. For maculopapular lesions, topical corticosteroid and moisturization of skin remain the primary mode of treatment. Systemic corticosteroid therapy may be needed in extensive involvement of the body surface.

In this literature review, one of the limitations that must be taken into account is that since research related to Covid-19 and skin manifestation is rapidly evolving, these reports are small-scale studies based on early restricted understanding, rather than large-size clinical trials, hence these data may not be decisive and relevant for the entire population. Further large-scale studies, addressing maculopapular eruptions and their clinical characteristics and pathology behind them are warranted.

5 | CONCLUSION

In this article, a systematic review of the cutaneous maculopapular eruptions associated with SARS-COV-2 is provided. Covid-19 patients most typically have respiratory symptoms, but multiple organ involvement with various cutaneous signs like maculopapular rash may occur. These maculopapular lesions differ considerably in terms of distribution and appearance, ranging from diffuse erythematous maculopapular lesions to scattered erythematous macules coalescing into papules to maculopapular lesions in plaques and may resemble other well-known dermatological disorders. Even though these results do not suggest that Covid-19 is the absolute cause of these maculopapular eruptions, they indicate these lesions should be regarded in the context of possible presentations associated with this illness. As these lesions may have a possible association with diagnosis, management, prognosis, and severity of the disease, all health practitioners need to be well acquainted with these Covid-19 skin lesions. Also, in the middle of this worldwide pandemic, early identification of this eruption may help manage this infection's further spread.

CONFLICT OF INTEREST

The authors declare no potential conflict of interest.

AUTHOR CONTRIBUTIONS

All authors contributed equally to this work.

DATA AVAILABILITY STATEMENT

The data that support the findings of this study are available within the article, in the reference list. The data that support the findings of this study are available from the corresponding author upon reasonable request.

ORCID

Sawai Singh Rathore  <https://orcid.org/0000-0003-1954-094X>

Manush Sondhi  <https://orcid.org/0000-0002-3910-1189>

Gianpiero Alonzo Rojas  <https://orcid.org/0000-0002-4937-0227>

REFERENCES

- Zhu N, Zhang D, Wang W, et al. A novel coronavirus from patients with pneumonia in China, 2019. *N Engl J Med*. 2020;382(8):727-733. <https://doi.org/10.1056/NEJMoa2001017>.
- Dong E, Du H, Gardner L. An interactive web-based dashboard to track COVID-19 in real time. *Lancet Infect Dis*. 2020;20(5):533-534. [https://doi.org/10.1016/S1473-3099\(20\)30120-1](https://doi.org/10.1016/S1473-3099(20)30120-1).
- Guo YR, Cao QD, Hong ZS, et al. The origin, transmission and clinical therapies on coronavirus disease 2019 (COVID-19) outbreak - an update on the status. *Mil Med Res*. 2020;7(1):11. <https://doi.org/10.1186/s40779-020-00240-0>.
- Li MY, Li L, Zhang Y, Wang XS. Expression of the SARS-CoV-2 cell receptor gene ACE2 in a wide variety of human tissues. *Infect Dis Poverty*. 2020;9(1):45. <https://doi.org/10.1186/s40249-020-00662-x>.
- Guan WJ, Ni ZY, Hu Y, et al. Clinical characteristics of coronavirus disease 2019 in China. *N Engl J Med*. 2020;382(18):1708-1720. <https://doi.org/10.1056/NEJMoa2002032>.
- Recalcati S. Cutaneous manifestations in COVID-19: a first perspective. *J Eur Acad Dermatol Venereol*. 2020;34(5):212-213. <https://doi.org/10.1111/jdv.16387>.
- Jia JL, Kamceva M, Rao SA, Linos E. Cutaneous manifestations of COVID-19: a preliminary review. *J Am Acad Dermatol*. 2020;83(2):687-690. <https://doi.org/10.1016/j.jaad.2020.05.059>.
- Galván Casas C, Català A, Carretero Hernández G, et al. Classification of the cutaneous manifestations of COVID-19: a rapid prospective nationwide consensus study in Spain with 375 cases. *Br J Dermatol*. 2020;183(1):71-77. <https://doi.org/10.1111/bjd.19163>.
- Freeman EE, McMahon DE, Lipoff JB, et al. The spectrum of COVID-19-associated dermatologic manifestations: an international registry of 716 patients from 31 countries. *J Am Acad Dermatol*. 2020;83(4):1118-1129. <https://doi.org/10.1016/j.jaad.2020.06.1016>.
- Moher D, Liberati A, Tetzlaff J, Altman DG, PRISMA Group. Preferred reporting items for systematic reviews and meta-analyses: the PRISMA statement. *BMJ*. 2009;339:2535. <https://doi.org/10.1136/bmj.b2535>.
- Ely JW, Seabury SM. The generalized rash: part I. Differential diagnosis. *Am Fam Physician*. 2010;81(6):726-734.
- Kang JH. Febrile illness with skin rashes. *Infect Chemother*. 2015;47(3):155-166. <https://doi.org/10.3947/ic.2015.47.3.155>.
- Diaz-Guimaraens B, Dominguez-Santas M, Suarez-Valle A, et al. Petechial skin rash associated with severe acute respiratory syndrome coronavirus 2 infection. *JAMA Dermatol*. 2020;156(7):820-822. <https://doi.org/10.1001/jamadermatol.2020.1741>.
- Rivera-Oyola R, Koschitzky M, Printy R, et al. Dermatologic findings in 2 patients with COVID-19. *JAAD Case Rep*. 2020;6(6):537-539. <https://doi.org/10.1016/j.jdc.2020.04.027>.
- Avellana Moreno R, Estela Villa LM, Avellana Moreno V, Estela Villa C, Moreno Aparicio MA, Avellana Fontanella JA. Cutaneous

- manifestation of COVID-19 in images: a case report. *J Eur Acad Dermatol Venereol.* 2020;34(7):307-309. <https://doi.org/10.1111/jdv.16531>.
16. Jimenez-Cauhe J, Ortega-Quijano D, Prieto-Barrios M, Moreno-Arrones OM, Fernandez-Nieto D. Reply to "COVID-19 can present with a rash and be mistaken for dengue": petechial rash in a patient with COVID-19 infection. *J Am Acad Dermatol.* 2020;83(2):141-142. <https://doi.org/10.1016/j.jaad.2020.04.016>.
 17. Ahouach B, Harent S, Ullmer A, et al. Cutaneous lesions in a patient with COVID-19: are they related? *Br J Dermatol.* 2020;183(2):31. <https://doi.org/10.1111/bjd.19168>.
 18. Klimach A, Evans J, Stevens J, Creasey N. Rash as a presenting complaint in a child with COVID-19. *Pediatr Dermatol.* 2020;37(5):966-967. <https://doi.org/10.1111/pde.14257>.
 19. Paolino G, Canti V, Mercuri SR, Rovere Querini P, Candiani M, Pasi F. Diffuse cutaneous manifestation in a new mother with COVID-19 (SARS-CoV-2). *Int J Dermatol.* 2020;59(7):874-875. <https://doi.org/10.1111/ijd.14919>.
 20. Dalal A, Jakhar D, Agarwal V, Beniwal R. Dermatological findings in SARS-CoV-2 positive patients: an observational study from North India. *Dermatol Ther.* 2020;33:e13849. <https://doi.org/10.1111/dth.13849>.
 21. Herrero-Moyano M, Capusan TM, Andreu-Barasoain M, et al. A clinicopathological study of eight patients with COVID-19 pneumonia and a late-onset exanthema. *J Eur Acad Dermatol Venereol.* 2020;34(9):e460-e464. <https://doi.org/10.1111/jdv.16631>.
 22. Mahé A, Birckel E, Krieger S, Merklen C, Bottlaender L. A distinctive skin rash associated with coronavirus disease 2019? *J Eur Acad Dermatol Venereol.* 2020;34(6):246-247. <https://doi.org/10.1111/jdv.16471>.
 23. Gaspari V, Neri I, Misciali C, Patrizi A. COVID-19: how it can look on the skin. Clinical and pathological features in 20 COVID-19 patients observed in Bologna, North-Eastern Italy. *J Eur Acad Dermatol Venereol.* 2020;34(10):552-553. <https://doi.org/10.1111/jdv.16693>.
 24. de Masson A, Bouaziz JD, Sulimovic L, et al. Chilblains is a common cutaneous finding during the COVID-19 pandemic: a retrospective nationwide study from France. *J Am Acad Dermatol.* 2020;83(2):667-670. <https://doi.org/10.1016/j.jaad.2020.04.161>.
 25. Gianotti R, Veraldi S, Recalcati S, et al. Cutaneous clinico-pathological findings in three COVID-19-positive patients observed in the metropolitan area of Milan, Italy. *Acta Derm Venereol.* 2020;100(8):124. <https://doi.org/10.2340/00015555-3490>.
 26. Falkenhain López D, Sánchez-Velázquez A, Ortiz de Frutos J. Maculopapular rash as initial manifestation of SARS-coronavirus-2 infection. Maculopapular rash as the initial manifestation of SARS-coronavirus-2 infection. *Med Clin.* 2020;155(2):92. <https://doi.org/10.1016/j.medcli.2020.04.003>.
 27. Rosell-Díaz AM, Mateos-Mayo A, Nieto-Benito LM, et al. Exanthema and eosinophilia in COVID-19 patients: has viral infection a role in drug induced exanthemas? *J Eur Acad Dermatol Venereol.* 2020;34(10):561-563. <https://doi.org/10.1111/jdv.16709>.
 28. Rubio-Muniz CA, Puerta-Peña M, Falkenhain-López D, et al. The broad spectrum of dermatological manifestations in COVID-19: clinical and histopathological features learned from a series of 34 cases. *J Eur Acad Dermatol Venereol.* 2020;34(10):574-576. <https://doi.org/10.1111/jdv.16734>.
 29. Askin O, Altunkalem RN, Altinisik DD, Uzuncakmak TK, Tursen U, Kutlubay Z. Cutaneous manifestations in hospitalized patients diagnosed as COVID-19. *Dermatol Ther.* 2020;33:e13896. <https://doi.org/10.1111/dth.13896>.
 30. Sachdeva M, Gianotti R, Shah M, et al. Cutaneous manifestations of COVID-19: report of three cases and a review of literature. *J Dermatol Sci.* 2020;98(2):75-81. <https://doi.org/10.1016/j.jdermsci.2020.04.011>.
 31. Jones VG, Mills M, Suarez D, et al. COVID-19 and Kawasaki disease: novel virus and novel case. *Hosp Pediatr.* 2020;10(6):537-540. <https://doi.org/10.1542/hpeds.2020-0123>.
 32. Chen Y, Liu Q, Guo D. Emerging coronaviruses: genome structure, replication, and pathogenesis. *J Med Virol.* 2020;92(4):418-423. <https://doi.org/10.1002/jmv.25681>.
 33. Li H, Liu L, Zhang D, et al. SARS-CoV-2 and viral sepsis: observations and hypotheses. *Lancet.* 2020;395(10235):1517-1520. [https://doi.org/10.1016/S0140-6736\(20\)30920-X](https://doi.org/10.1016/S0140-6736(20)30920-X).
 34. Li G, Fan Y, Lai Y, et al. Coronavirus infections and immune responses. *J Med Virol.* 2020;92(4):424-432. <https://doi.org/10.1002/jmv.25685>.
 35. Criado PR, de Carvalho JF, Ayabe LA, Brandt HR, Romiti R, Maruta CW. Urticaria and dermatographism in patients with adult-onset Still's disease. *Rheumatol Int.* 2012;32(8):2551-2555. <https://doi.org/10.1007/s00296-011-2025-5>.
 36. Català A, Galván-Casas C, Carretero-Hernández G, et al. Maculopapular eruptions associated to COVID-19: a subanalysis of the COVID-Piel study. *Dermatol Ther.* 2020;33:e14170. <https://doi.org/10.1111/dth.14170>.
 37. Sousa Gonçalves C, Reis Carreira N, Passos D, et al. Erythematous papular rash: a dermatological feature of COVID-19. *Eur J Case Rep Intern Med.* 2020;7(7):1768. https://doi.org/10.12890/2020_001768.
 38. Reymundo A, Fernández-Bernáldez A, Reolid A, et al. Clinical and histological characterization of late appearance maculopapular eruptions in association with the coronavirus disease 2019. A case series of seven patients. *J Eur Acad Dermatol Venereol.* 2020;34:755-757. <https://doi.org/10.1111/jdv.16707>.
 39. Hunt M, Koziatek C. A case of COVID-19 pneumonia in a young male with full body rash as a presenting symptom. *Clin Pract Cases Emerg Med.* 2020;4(2):219-221. <https://doi.org/10.5811/cpcem.2020.3.47349>.
 40. Najarian DJ. Morbilliform exanthem associated with COVID-19. *JAAD Case Rep.* 2020;6(6):493-494. <https://doi.org/10.1016/j.jidcr.2020.04.015>.
 41. Bouaziz JD, Duong TA, Jachiet M, et al. Vascular skin symptoms in COVID-19: a French observational study. *J Eur Acad Dermatol Venereol.* 2020;34(9):451-452. <https://doi.org/10.1111/jdv.16544>.
 42. Hedou M, Carsuzaa F, Chary E, Hainaut E, Cazenave-Roblot F, Masson Regnault M. Comment on "cutaneous manifestations in COVID-19: a first perspective" by Recalcati S. *J Eur Acad Dermatol Venereol.* 2020;34(7):299-300. <https://doi.org/10.1111/jdv.16519>.
 43. Morey-Olivé M, Espiau M, Mercadal-Hally M, Lera-Carballo E, García-Patos V. Cutaneous manifestations in the current pandemic of coronavirus infection disease (COVID 2019). *An Pediatr.* 2020;92(6):374-375. <https://doi.org/10.1016/j.anpede.2020.04.002>.
 44. Olisova OY, Anpilogova EM, Shnakhova LM. Cutaneous manifestations in COVID-19: a skin rash in a child. *Dermatol Ther.* 2020;33:e13712. <https://doi.org/10.1111/dth.13712>.
 45. Cabrera-Hernández R, Solano-Solares E, Chica-Guzmán V, et al. SARS-CoV-2, skin lesions and the need of a multidisciplinary approach. *J Eur Acad Dermatol Venereol.* 2020;34:659-662. <https://doi.org/10.1111/jdv.16745>.
 46. Zengarini C, Orioni G, Cascavilla A, et al. Histological pattern in COVID-19-induced viral rash. *J Eur Acad Dermatol Venereol.* 2020;34(9):453-454. <https://doi.org/10.1111/jdv.16569>.
 47. Méndez Maestro I, Peña Merino L, González U, Del Tánago B. Skin manifestations in patients hospitalized with confirmed COVID-19 disease: a cross-sectional study in a tertiary hospital. *Int J Dermatol.* 2020;59:1353-1357. <https://doi.org/10.1111/ijd.15180>.
 48. Öksüm Solak E, Baran Ketencioglu B, Çınar SL, Kartal D, Borlu M. Coronavirus disease 2019 (COVID-19) accompanied by maculopapular rash: a case study. *Cureus.* 2020;12(9):10414. <https://doi.org/10.7759/cureus.10414>.

49. Farabi B, Atak MF. Isolated maculopapular eruption localized to head and neck: a cutaneous sign of COVID-19 infection. *Dermatol Ther.* 2020;33:e14468. <https://doi.org/10.1111/dth.14468>.
50. Rossi E, Lasagni C, Trakatelli M, Wertzberger Rowan S, Magnoni C. Acute maculopapular eruption in Covid-19 patient: a case report. *Dermatol Ther.* 2020;33:e13812. <https://doi.org/10.1111/dth.13812>.
51. Mazan P, Lesiak A, Skibińska M, et al. Maculopapular rash in COVID-19 patient treated with lopinavir/ritonavir. *Postepy Dermatol Alergol.* 2020;37(3):435-437. <https://doi.org/10.5114/ada.2020.95029>.
52. Motohashi I, Takano T, Ie K, Hashimoto Y, Akino S, Okuse C. Development of maculopapular exanthem in a COVID-19 patient. *J Dermatol.* 2020;47(12):426-427. <https://doi.org/10.1111/1346-8138.15579>.
53. Punyaratabandhu P, Chirachanakul P. Cutaneous eruption in COVID-19-infected patients in Thailand: an observational descriptive study. *J Dermatol.* 2020;48:14-20. <https://doi.org/10.1111/1346-8138.15625>.
54. second BR, Petrie C, Toledo A. Mixed purpuric and maculopapular lesions in a patient with COVID-19: a case report. *Clin Pract Cases Emerg Med.* 2020;4(3):349-351. <https://doi.org/10.5811/cpcem.2020.6.48617>.

How to cite this article: Shams S, Rathore SS, Anvekar P, et al. Maculopapular skin eruptions associated with Covid-19: A systematic review. *Dermatologic Therapy.* 2021;34:e14788. <https://doi.org/10.1111/dth.14788>