

SCFE: clinical aspects, diagnosis, and classification

M. B. Millis

Abstract

Purpose This article seeks to improve treatment outcomes in slipped capital femoral epiphysis (SCFE) by outlining advances in diagnosis, understanding of pathomechanics, and mechanically-based classification.

Methods Review of clinical experience with SCFE at our high-volume centre, interaction with other clinical experts, and literature review has allowed a current perspective to be articulated

Results SCFE remains an important clinical problem, with late diagnosis still frequent. Improved understanding of the ubiquity of femoroacetabular impingement has guided current classification and treatment protocols

Conclusion SCFE is an important clinical problem, with high historical rates of impaired hip function both in childhood and adulthood. Great opportunities exist for improved outcomes following earliest possible clinical diagnosis, modern imaging, and mechanically-based classification of involved hips to allow optimal treatment.

Cite this article: Millis MB. SCFE: clinical aspects, diagnosis, and classification. *J Child Orthop* 2017;11:93-98. DOI 10.1302/1863-2548.11.170025

Keywords: Slipped capital femoral epiphysis; SCFE; hip impingement; femoroacetabular impingement; hip pathomechanics

Introduction

Slipped capital femoral epiphysis (SCFE) is a major paediatric orthopaedic challenge. Its incidence is increasing. There is no clear method of prevention other than prophylactic pinning. There is no accepted animal model. There is persistently frequent late diagnosis, with frequent short-term and long-term dysfunction, even in many so-called

“mild” cases.^{1,2} Despite powerful new methods of treatment, great controversy regarding treatment choice exists.

Clinical Aspects

Importance

SCFE is of importance because in much of the world, it is an increasingly common condition^{3,4} which often causes both short-^{1,5} and long-term morbidity.² Aronson reported in 1986 that as many as 22% of hips coming to total hip arthroplasty (THA) in North America had SCFE associated with their osteoarthritis (OA).⁶ Given the increasing employment of THA,⁷ the increasing incidence of SCFE, and no clear evidence that contemporary methods have yet improved long-term outcomes, it seems prudent to focus attention on the various aspects of SCFE that may allow reduction in SCFE-associated morbidity.

A brief discussion of SCFE's primary anatomic pathology, pathomechanics, and associated articular damage may emphasise the clinical and imaging findings that should allow timely accurate diagnosis, and classification, both of which are essential to optimal treatment.

Aetiology

The aetiology of the omnipresent physeal disruption is likely multifactorial, but in most cases, a relatively weak physis is subjected to loads beyond tolerance. This typically occurs at the time of the pre-adolescent/adolescent growth spurt, when a combination of hormonal and macroscopic physical factors may be causative.⁸

Obesity is a clear risk factor in most population studies,^{3,4} though there is an interesting subgroup of “skinny SCFE” patients of less than average BMI with relatively high risk of unstable SCFE.⁹

Prevention

Prevention of disease is ideal.¹⁰ There are however no established programs directed primarily at SCFE prevention. Theoretically, reducing the incidence of obesity and correction of metabolic/endocrine factors predisposing to epiphysiolysis could be steps toward prevention. Nasreddine noted that patients who lost weight after suffering a unilateral SCFE had much lower risk of second slip than a control group with unilateral SCFE who did not lose weight, or who gained weight after surgical treatment.⁴ Prophylactic pinning is employed¹¹ but its use is not universal after unilateral SCFE and remains controversial.

Child and Young Adult Hip Program, Boston Children's Hospital, Department of Orthopaedic Surgery, Harvard Medical School, Boston, USA

Correspondence should be sent to Michael B. Millis, Child and Young Adult Hip Program, Boston Children's Hospital, Department of Orthopaedic Surgery, Harvard Medical School, Boston, USA
E-mail: Michael.Millis@childrens.harvard.edu

Young age, obesity, and certain other factors like increased alpha angle or posterior epiphyseal tilt on the contralateral unslipped hip may be risk factors for subsequent slip.¹²

Pathology

A universal and pathognomonic finding in SCFE is disruption of the capital femoral physis, with varying degrees of displacement of the epiphysis from its physiological position proximal to the femoral neck. Failure occurs through the zone of provisional calcification.

The deformity in SCFE is almost always anterior and external rotational translation of the femoral neck, with variable posterior tilt of the femoral epiphysis in more severe cases. A rare subtype, the so-called “valgus slip” involves antero-medial neck translation and postero-valgus inclination of the femoral head.^{13,14}

The usual SCFE-related deformity exposes the anterior metaphysis and edge of neck to the anterolateral rim and labrum, causing impingement.

Damage to the anterior acetabular cartilage, labrum, and rim is universal and occurs very early.⁵ The amount of articular damage is quite variable, but is likely related to the duration of the slip, the severity of the deformity, and the activity level of the patient.

Remodeling of the deformity at the level of the femoral neck and metaphysis variably occurs.^{15,16} Gradual neck remodeling after both single partially threaded screw fixation¹⁷ and hook-pin fixation¹⁸ has been reported. It is likely, that even if gradual remodeling occurs, damage to the anterolateral intraarticular structures still occurs.

Aside from the SCFE-related deformity of the proximal femur, there is frequent pre-existing acetabular retroversion,¹⁹ acetabular overcoverage^{20,21} and either low femoral anteversion or true femoral retroversion.

Pathomechanics of the hip with SCFE

There are several potential sources of mechanical abnormality in the SCFE hip. These include physeal instability, deformity at the neck/metaphysis level, and pre-existing deformity of proximal femur and/or acetabulum

Whether the capital femoral physis is open or closed is the initial consideration in classifying and treating SCFE, since an open physis carries the risk of variable instability and further displacement which can be acute, severe, and threatening to the vascularity of the femoral head. Stabilisation of the head on the neck is therefore a crucial step in treating any SCFE hip in which the physis is open.

The metaphyseal prominence that is always present in SCFE is the next consideration after considering the stability of the physis. Ganz's seminal work established femoroacetabular impingement, as a major mechanism of coxarthrosis.²² The FAI paradigm makes clear the relationship between the cam deformity in SCFE and the anterior

joint damage reported by Leunig first and many others since.^{5,23} Retrotorsion of femur and acetabulum commonly precede the slip and may exacerbate impingement.^{24,8}

Diagnosis

Early diagnosis of SCFE is associated with statistically better outcomes. Unfortunately, late diagnosis, with more severe deformity and articular damage at presentation remains frequent in many countries.²⁵ There is also evidence that many, if not all, unstable SCFE are preceded by weeks of symptoms.²⁶ This suggests that the incidence of the problematic unstable SCFE could be reduced by uniform earlier diagnosis of SCFE.

Timely diagnosis, however, awaits achievement of a high level of awareness by all health care providers, teachers, sports coaches, and parents of the possibility of SCFE in the preadolescent and adolescent population-at-risk.

Diagnosis of SCFE is often delayed because the symptoms usually are vague, often not located at the hip level, and may not even involve pain. Additionally, in the overweight patient, other possible causes of lower extremity dysfunction may be present.²⁷ The diagnosis usually is not made at the initial medical evaluation.

Screening

Large scale screening for SCFE has not been practiced. Screening for limited internal rotation might be a test of screening value in certain at-risk subgroups.

History

Symptoms are the key to correct timely diagnosis of many orthopaedic conditions. Unfortunately, in SCFE, pain is variable, and when present, the pain is often not localised to the hip.²⁸ Pain may occasionally not be present at all in stable SCFE.²⁹ That said, even so-called acute SCFE patients usually report weeks or more of ache in the groin, thigh or knee, or limp. At time of diagnosis, there is a wide spectrum of clinical dysfunction ranging from none to profound—even pain severe enough to prevent ambulation. History of an endocrinopathy or obesity should heighten awareness of the possibility of SCFE. In truth, though, every child from early preadolescence through skeletal maturity is at risk for SCFE.

Physical Examination

Limited internal rotation of the involved hip is the most frequent abnormality on physical exam of the SCFE patient,

noted in 64 of 66 patients in Cowell's well-studied series.²⁹ Limited passive hip flexion and limp are also common. There is however no perfectly sensitive or specific physical finding in SCFE.

The diagnosis of SCFE must be considered for the confirmatory imaging to be ordered.

Imaging

The gold standard diagnostic test for SCFE is the biplanar radiographic examination.

Detailed discussion of imaging is beyond the scope of this manuscript, but the supine anteroposterior (AP) pelvis and Lauenstein or frog lateral view demonstrate the classical anterior displacement of the anterior femoral neck, with simultaneous relative posterior displacement of the capital femoral epiphysis. In the so-called pre-slip, slight widening of the physis may be present.

Ultrasound^{30,31} may show a small effusion and may demonstrate a small metaphyseal setoff, even in cases in which orthogonal radiographs show no epiphyseal displacement. In the so-called "pre-slip", MRI can show physeal abnormalities characteristic of a physis at risk to slip.³²

Classification

Classification of the patient and hip afflicted with SCFE is important in optimising treatment selection and subsequent outcome.

Important variables to consider at initial diagnosis include stability of the physis, degree of slip deformity as a surrogate for risk of cumulative mechanical damage, and certain other anatomic and mechanical factors, which include anatomic version, acetabular depth, and activity level.

Historical clinical classification has often divided untreated SCFE hips into the temporally-based categories of Acute, Acute-on-Chronic, and Chronic. We suggest discarding this classical schema, which has little correlation with the pathomechanics found in SCFE.

Mechanical stability of the physis is the first important clinical factor to consider in treatment selection. Contemporary understanding of SCFE suggest that onset of symptoms usually is indefinite, and that duration of symptoms is not related closely to physeal stability. Useful modern classification should be based on mechanical and morphological parameters.

Physeal stability

The degree of physeal stability in SCFE can range from complete disruption of the physis to total stability in the healed slip. The clinical presentation—specifically the inability to ambulate—has been the classical definition of the so-called unstable or acute SCFE.¹³ Recent information

Table 1. Slipped capital femoral epiphysis classification by mechanical stability

Status of Physis	Open	Closed
Mechanical stability of capital femoral physis and femoral head	Uncertain, regardless of ability to ambulate or duration of symptoms (33)	Stable

suggests, however, that the mechanical stability of the physis in the hip with SCFE is often different from what one would suspect as judged by the ability to ambulate³³ (Table 1). Ziebarth reported a series of 82 hips with varying degrees of SCFE treated by the surgical dislocation approach and modified Dunn osteotomy. Specifically, 13 of 24 hips in which the patients were unable to bear weight prior to surgery had physes which were found to be mechanically stable intra-operatively. Perhaps more significant and worrisome is the fact that of 17 of 58 hips in which the patients were able to weight-bear prior to surgery had physes which were not stable intra-operatively (Fig. 1). This suggests that every SCFE hip with an open physis should be considered at risk for acute disruption.

Morphological Classification/Degree of deformity

Classical morphological classifications have been based on AP and lateral radiographic views, with the deformity usually best demonstrated on a lateral view. The schema have used either linear displacement of the head on the neck or slip angle (angle between shaft and perpendicular to physis per Southwick) as the major parameter. The groups:

1. Pre-slip (widening of the physis; no displacement)
2. Mild slip (up to 1/3 displacement, or up to 30° of head tilt)
3. Moderate slip (1/3 to 1/2 displacement; or 30° to 60° degrees slip angle)
4. Severe slip (> 1/2 displacement; > 60° of slip angle)

Routine orthogonal radiographs, however, rarely demonstrate the full deformity.

More precise definition of SCFE-associated deformity requires CT or MRI with radial sequences.^{34,35}

The contemporary concept of long-term SCFE-associated joint deterioration invokes FAI as the major mechanical abnormality.^{22,5} Precise definition of deformity allows design of surgical treatment programs to minimise the deformity and the structural contributors to FAI by surgical realignment, recontouring, or combinations.³⁶

There is a relationship between severity and impingement in SCFE, though it seems clear that any SCFE deformity is associated with FAI.³⁷

Much of the SCFE-related impingement is secondary to intra-articular deformity that cannot be corrected by extra-articular surgery. That said, we have limited information about the long-term outcome of contemporary methods of impingement relief by intra-articular surgery.

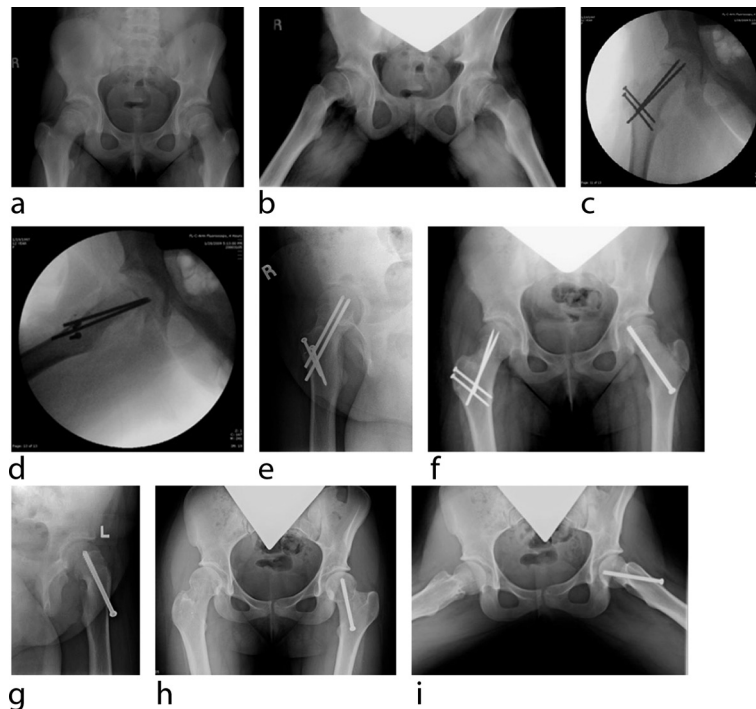


Fig. 1 A 12-year-old female with six months of right knee pain and limp. Normal right knee radiographs and normal knee MRI. Physiotherapy for knee did not help knee pain. There were three weeks of groin pain. Crutches were prescribed. She was able to walk with crutches. First hip radiographs show severe bilateral SCFE. On examination she can lift both legs off table, but the right hip is painful. (a and b) Anteroposterior and Lauenstein lateral radiographs at presentation. (c and d) At modified Dunn osteotomy surgery, right femoral head was very unstable, despite abundant posterior callus, and preoperative ability to ambulate with crutches. (e, f and g) one year post-operatively right Dunn osteotomy, left ISP. Groin pain only in left hip. (h and i) five years post right Dunn osteotomy, three years post left hip anterior arthrotomy and neck osteoplasty. Asymptomatic in both hips.

Classification by Degree of Articular Damage

Articular damage may be the most important factor in determining long-term outcomes in SCFE (Fig. 2). Until recently, the interior of the SCFE hip—particularly the acetabulum, was terra incognita for pediatric orthopaedists.

The advent of the surgical dislocation approach and the increasing use of hip arthroscopy have provided a startling and sobering view of the degree of articular damage that is present in virtually every hip with any degree of SCFE deformity, even if of short duration.^{5,23}

In addition, recent advances in MR imaging provide valuable noninvasive information on cartilage health.³⁸ These advanced imaging techniques are needed not only for assessing joint condition and function in planning initial treatment, but also for assessing intra-articular structures over time.³⁹

Types of mechanical dysfunction (Table 2)

SCFE-related metaphyseal prominence is a classic generator of the inclusion type of FAI, with anterior acetabulum and rim wear as a consequence.^{5,40,23}

In very severe SCFE, the metaphyseal prominence may become so large as to block the entry of the cam into the acetabulum, creating an impaction (pincer) damage pattern that usually is superimposed on an environment

with preexisting cam-type intra-articular damage from the period of time when the deformity was less severe.

Pre-existing femoral and/or acetabular retroversion³⁴ and coxa profunda^{20,21} are also common in SCFE, each predisposing to impaction impingement.

Rarely, associated acetabular dysplasia may be present in the presence of long-standing SCFE—usually noted well after healing. SCFE hips with acetabular dysplasia may present with combined impingement and instability.

Though a metaphyseal prominence is present in every hip with SCFE deformity, with associated inclusion-type FAI, there is great variability in degree and type of other mechanical abnormalities which may be active.

Issues Beyond the Hip

Classifying the SCFE patient and the hip affected by SCFE have not traditionally considered more global patient-related factors outside the hip. Clinical dysfunction in a patient with an orthopaedic problem depends also on factors outside the musculoskeletal system, and even outside the patient. Recognising the relevance of the bio-sychosocial model of disease is helpful in designing treatment programs that are most effective for the particular patient in his environment.⁴¹

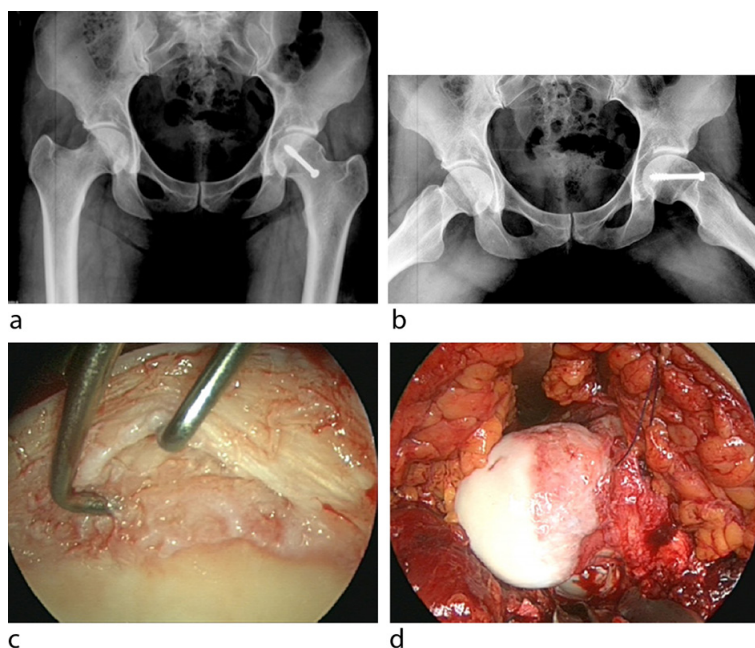


Fig. 2 A 27-year-old-female 16 years post *in situ* pinning for stable SCFE. She had four years of pain with sitting. Flexion possible to 90°. Internal rotation in flexion only to neutral. On imaging, slip angle is only about 25°. Slip deformity classified as mild, but there is a large metaphyseal prominence. (a and b) AP and Lauenstein lateral radiographs at presentation. (c) Severe anterior acetabular damage found at time of surgical dislocation and neck osteoplasty. (d) Large metaphyseal prominence

Table 2. Slipped capital femoral epiphysis classification by pathomechanics

	Mild Deformity	Moderate Deformity	Severe Deformity
Cam-Type FAI	Always	Always	Always
Pincer-Type FAI	Rare	Common	Common
Instability	Variable	Variable	Variable

FAI, femoroacetabular impingement.

SCFE remains an important cause of hip-related morbidity. In both children and adults. Increasing incidence, delayed primary diagnosis, and incomplete understanding of the consequences of SCFE-related deformity are factors.

Early diagnosis of SCFE before extensive cartilage damage occurs is essential for timely treatment to have a chance to optimise long-term hip function.

Relevant classifications based on SCFE-related mechanical abnormalities and intra-articular damage will allow the studies which will lead to improved treatment outcomes.

Received 2 February 2017; accepted 13 March 2017.

COMPLIANCE WITH ETHICAL STANDARDS

FUNDING STATEMENT

No benefits in any form have been received or will be received from a commercial party related directly or indirectly to the subject of this article.

OA LICENCE TEXT

This article is distributed under the terms of the Creative Commons Attribution-Non Commercial 4.0 International (CC BY-NC 4.0) licence (<https://creativecommons.org/licenses/by-nc/4.0/>) which permits non-commercial use, reproduction and distribution of the work without further permission provided the original work is attributed.

ACKNOWLEDGEMENT

We would like to thank Emily Schon, MLIS, for editorial assistance.

ETHICAL STATEMENT

This article does not contain any studies with human participants performed by the author.

REFERENCES

1. **Fraitz CR, Käfer W, Nelitz M, Reichel H.** Radiological evidence of femoroacetabular impingement in mild slipped capital femoral epiphysis: a mean follow-up of 14.4 years after pinning in situ. *J Bone Joint Surg [Br]* 2007;89-B:1592-1596.
2. **Carney BT, Weinstein SL, Noble J.** Long-term follow-up of slipped capital femoral epiphysis. *J Bone Joint Surg [Am]* 1991;73-A:667-674.
3. **Nguyen AR, Ling J, Gomes B, et al.** Slipped capital femoral epiphysis: rising rates with obesity and aboriginality in South Australia. *J Bone Joint Surg [Br]* 2011;93-B:1416-1423.
4. **Nasreddine AY, Heyworth BE, Zurakowski D, Kocher MS.** A reduction in body mass index lowers risk for bilateral slipped capital femoral epiphysis. *Clin Orthop Relat Res* 2013;471:2137-2144.
5. **Leunig M, Casillas MM, Hamlet M, et al.** Slipped capital femoral epiphysis: early mechanical damage to the acetabular cartilage by a prominent femoral metaphysis. *Acta Orthop Scand* 2000;71:370-375.

6. **Aronson J.** Osteoarthritis of the young adult hip: etiology and treatment. *Instr Course Lect* 1986;35:119-128.
7. **Wolford M, Palso K, Bercovitz A.** Hospitalization for total hip replacement among inpatients aged 45 and over: United States, 2000-2010. *NCHS Data Brief* 2015;186:1-8.
8. **Liu RW, Fraley SM, Morris WZ, Cooperman DR.** Validity and Clinical Consequences of a Rotational Mechanism for Slipped Capital Femoral Epiphysis. *J Pediatr Orthop* 2016;36:239-246.
9. **Goldstein RY, Dawicki E, Broom A, et al.** The "Skinny" SCFE. *Pediatrics* 2016;137:555A-555A.
10. **Bialik V.** Prevention of Developmental Displacement of the Hip Editorial. *J Pediatr Orthop B* 1993;2:103.
11. **Clement ND, Vats A, Duckworth AD, Gaston MS, Murray AW.** Slipped capital femoral epiphysis: is it worth the risk and cost not to offer prophylactic fixation of the contralateral hip? *Bone Joint J* 2015;97-B:1428-1434
12. **Boyle MJ, Lirola JF, Hogue GD, et al.** The alpha angle as a predictor of contralateral slipped capital femoral epiphysis. *J Child Orthop* 2016;10:201-207.
13. **Loder RT, Richards BS, Shapiro PS, Reznick LR, Aronson DD.** Acute slipped capital femoral epiphysis: the importance of physeal stability. *J Bone Joint Surg [Am]* 1993;75-A:1134-1140.
14. **Shank CF, Thiel EJ, Klingele KE.** Valgus slipped capital femoral epiphysis: prevalence, presentation, and treatment options. *J Pediatr Orthop* 2010;30:140-146.
15. **Sibinski M, Synder M, Borowski A, Grzegorzewski A.** [Remodeling after in situ pinning for slipped capital femoral epiphysis]. *Pol Orthop Traumatol* 2004;69:321-324. (In Polish)
16. **Akiyama M, Nakashima Y, Kitano T, et al.** Remodelling of femoral head-neck junction in slipped capital femoral epiphysis: a multicentre study. *Int Orthop* 2013;37:2331-2336.
17. **Sailhan F, Courvoisier A, Brunet O, Chotel F, Berard J.** Continued growth of the hip after fixation of slipped capital femoral epiphysis using a single cannulated screw with a proximal threading. *J Child Orthop* 2011;5:83-88.
18. **Örtegren J, Björklund-Sand L, Engbom M, Siversson C, Tiderius CJ.** Unthreaded Fixation of Slipped Capital Femoral Epiphysis Leads to Continued Growth of the Femoral Neck. *J Pediatr Orthop* 2016;36:494-498.
19. **Ezoe M, Naito M, Inoue T.** The prevalence of acetabular retroversion among various disorders of the hip. *J Bone Joint Surg [Am]* 2006;88-A:372-379.
20. **Sankar WN, Brighton BK, Kim YJ, Millis MB.** Acetabular morphology in slipped capital femoral epiphysis. *J Pediatr Orthop* 2011;31:254-258.
21. **Podeszwa DA, Gurd D, Riccio A, De La Rocha A, Sucato DJ.** Increased acetabular depth may influence physeal stability in slipped capital femoral epiphysis. *Clin Orthop Relat Res* 2013;471:2151-2155.
22. **Ganz R, Parvizi J, Beck M, et al.** Femoroacetabular impingement: a cause for osteoarthritis of the hip. *Clin Orthop Relat Res* 2003;417:112-120.
23. **Sink EL, Zaltz I, Heare T, Dayton M.** Acetabular cartilage and labral damage observed during surgical hip dislocation for stable slipped capital femoral epiphysis. *J Pediatr Orthop* 2010;30:26-30.
24. **Tönnis D, Heinecke A.** Acetabular and femoral anteversion: relationship with osteoarthritis of the hip. *J Bone Joint Surg [Am]* 1999;81-A:1747-1770.
25. **Schur MD, Andras LM, Broom AM, et al.** Continuing Delay in the Diagnosis of Slipped Capital Femoral Epiphysis. *J Pediatr* 2016;177:250-254.
26. **McPartland TG, Sankar WN, Kim YJ, Millis MB.** Patients with unstable slipped capital femoral epiphysis have antecedent symptoms. *Clin Orthop Relat Res* 2013;471:2132-2136.
27. **Smith SM, Sumar B, Dixon KA.** Musculoskeletal pain in overweight and obese children. *Int J Obes (Lond)* 2014;38:11-15
28. **Matava MJ, Patton CM, Luhmann S, Gordon JE, Schoenecker PL.** Knee pain as the initial symptom of slipped capital femoral epiphysis: an analysis of initial presentation and treatment. *J Pediatr Orthop* 1999;19:455-460.
29. **Cowell HR.** The significance of early diagnosis and treatment of slipping of the capital femoral epiphysis. *Clin Orthop Relat Res* 1966;48:89-94.
30. **Terjesen T.** Ultrasonography for diagnosis of slipped capital femoral epiphysis. Comparison with radiography in 9 cases. *Acta Orthop Scand* 1992;63:653-657.
31. **Castriota-Scanderbeg A, Orsi E.** Slipped capital femoral epiphysis: ultrasonographic findings. *Skeletal Radiol* 1993;22:191-193.
32. **Khaladkar SM, Sherawat P, Jantre MN, Thakkar DK, Kulkarni VM.** Early diagnosis of slipped capital femoral epiphysis on magnetic resonance imaging: A case report with review of literature. *Medical Journal of Dr DY Patil University* 2015;8:72-76
33. **Ziebarth K, Domayer S, Slongo T, Kim YJ, Ganz R.** Clinical stability of slipped capital femoral epiphysis does not correlate with intraoperative stability. *Clin Orthop Relat Res* 2012;470:2274-2279.
34. **Monazzam S, Dwek JR, Hosalkar HS.** Multiplanar CT assessment of femoral head displacement in slipped capital femoral epiphysis. *Pediatr Radiol* 2013;43:1599-1605.
35. **Cooper AP, Salih S, Geddis C, et al.** The oblique plane deformity in slipped capital femoral epiphysis. *J Child Orthop* 2014;8:121-127.
36. **Milone MT, Bedi A, Poultsides L, et al.** Novel CT-based three-dimensional software improves the characterization of cam morphology. *Clin Orthop Relat Res* 2013;471:2484-2491.
37. **Novais EN, Millis MB.** Slipped capital femoral epiphysis: prevalence, pathogenesis, and natural history. *Clin Orthop Relat Res* 2012;470:3432-3438.
38. **Stelzener D, Mamisch TC, Kress I, et al.** Patterns of joint damage seen on MRI in early hip osteoarthritis due to structural hip deformities. *Osteoarthritis Cartilage* 2012;20:661-669.
39. **Zilkens C, Miese F, Bittersohl B, et al.** Delayed gadolinium-enhanced magnetic resonance imaging of cartilage (dGEMRIC), after slipped capital femoral epiphysis. *Eur J Radiol* 2011;79:400-406.
40. **Millis MB, Lewis CL, Schoenecker PL, Clohisy JC.** Legg-Calvé-Perthes disease and slipped capital femoral epiphysis: major developmental causes of femoroacetabular impingement. *J Am Acad Orthop Surg* 2013;21:S59-S63.
41. **Ayers DC, Franklin PD, Ring DC.** The role of emotional health in functional outcomes after orthopaedic surgery: extending the biopsychosocial model to orthopaedics: AOA critical issues. *J Bone Joint Surg [Am]* 2013;95:e165.