

Case Report

©2020 NRITLD, National Research Institute of Tuberculosis and Lung Disease, Iran

ISSN: 1735-0344 Tanaffos 2020; 19(3): 267-271

TANAFFOS 

Diagnosis and Treatment Process of Tracheobronchopathia Osteochondroplastica with Concurrent Chronic Eosinophilic Pneumonia: a Case Report

Rama Bozorgmehr¹, Besharat Rahimi²

¹ Clinical Research Development Unit, Shohadaye Tajrish Hospital, Shahid Beheshti University of Medical Sciences, Tehran, Iran, ² Advanced Thoracic Research Center, Tehran University of Medical Sciences, Tehran, Iran.

Received: 30 June 2019

Accepted: 6 May 2020

Correspondence to: Rahimi B

Address: Advanced Thoracic Research Center, Tehran University of Medical Sciences, Tehran, Iran.

Email address: besharatrahimi@yahoo.com

Background: Tracheobronchopathia Osteochondroplastica (TBPO) is a rare disease with a benign period affecting the bronchial system. It is characterized by the presence of numerous osseous submucosal nodules or cartilaginous protruding into the tracheobronchial lumen. These wounds are diagnosed incidentally during bronchoscopy. We reported the stages of diagnosis and treatment of a 46-year-old patient with TBPO and concurrent chronic eosinophilic pneumonia.

Case presentation: A 46-year-old non-smoking Afghan male exposed to adhesives and chemicals in Iran for more than 25 years was admitted to a pulmonary ward with symptoms of exertional dyspnea, dry coughing, occasional nocturnal sweating for 6 years, tachycardia, hypoxia, and generalized wheezing during expiration. A symbicort inhaler and Montelukast pills were prescribed for him with the probable diagnosis of asthma. High-resolution computed tomography (HRCT) was performed on the patient and the results showed non-significant multiple lymph nodes with maximum diameters (SAD = 7 mm). HRCT also showed that the patient had protuberances on the trachea surface and thus underwent bronchoscopy for further examination. The results indicated numerous protuberances of white cartilage from the proximal part of the trachea to the distal part without the involvement of the posterior membrane. The biopsy result confirmed TBPO. Prednisolone was prescribed for the patient to treat the chronic eosinophilic pneumonia. However, we had to continue the daily dose of 5mg prednisolone due to the recurrence of the symptoms.

Conclusion: The lack of response to a bronchodilator in a patient suspicious to asthma must make us think about other causes of respiratory wheezing such as TBPO.

Key words: Tracheobronchopathia Osteochondroplastica, Eosinophilic Pneumonia, Diagnosis

INTRODUCTION

Tracheobronchopathia osteochondroplastica (TBPO) is a rare disease with a benign period affecting the bronchial system. This complication is characterized by the presence of osseous submucosal nodules or multiple cartilaginous protruding into the tracheo-bronchial lumen. The tracheal

lesions are concentrated in the anterolateral wall of the trachea and are generally distributed in the membranous posterior wall. The volume of high-diameter nodules can cause the stiffness and obstruction of the airways (1-3). The prevalence of TBPO is often accompanied with non-

specific signs. The incidence of this disease is estimated to be 0.10 to 4.2 per 100,000 people and gender does not make any differences. Meanwhile, the mean age for the diagnosis of this disease has been reported 50 years (4, 5). People with TBPO usually present with cough, hemoptysis, and respiratory infections (6, 7). The low incidence of TBPO may cause the misdiagnosis and neglect of the disease. Therefore, considering the possibility of developing this disease in cases of intractable cough and chronic inflammation is highly valuable. Due to the ambiguous and debatable etiology of TBPO, adapted methods are necessary to prevent the progression of the disease and improve its diagnosis (3). In the present study, we reported the stages of diagnosis and treatment of a 46-year-old patient with TBPO and concurrent chronic eosinophilic pneumonia (CEP).

CASE SUMMARIES

The case was a 46-year-old non-smoking Afghan male who had lived in Iran for 28 years. He was married and had three children. He was a bag and shoe manufacturer and thus had been exposed to adhesives and chemicals for more than 25 years. The patient reported to suffer from exertional dyspnea, dry coughing, and occasional nocturnal sweating for 6 years. The symptoms were typical of asthma and thus salbutamol was prescribed, but the patient did not consume it. The patient was admitted to the Emergency Department of the Imam Khomeini Hospital, Tehran, Iran, 3 years ago with severe onset of dyspnea, tachycardia (PR=110), tachypnea (RR=38), hypoxia (O₂ saturation in room air=88%), and normal blood pressure. The patient's axillary temperature was 36.7 degrees and he had generalized wheezing during expiration. Heart auscultation and organs were normal in the patient (Figure 1). In the hospital, an asthma treatment plan was provided to the patient. Accordingly, antibiotics and intravenous corticosteroid were prescribed and, with the suspicion of tuberculosis, PPD and sputum smear regarding Acid Fast Bacilli (three consecutive times) were performed, which were negative. A chest x-ray was taken, showing a slight

opacity in the lower lobes of the patient's lungs. A severe obstructive airway disease was observed in spirometry, which did not respond to the bronchodilator. After 2 days, the patient was discharged with asthma diagnosis. A Symbicort inhaler and Montelukast pills were prescribed for him.

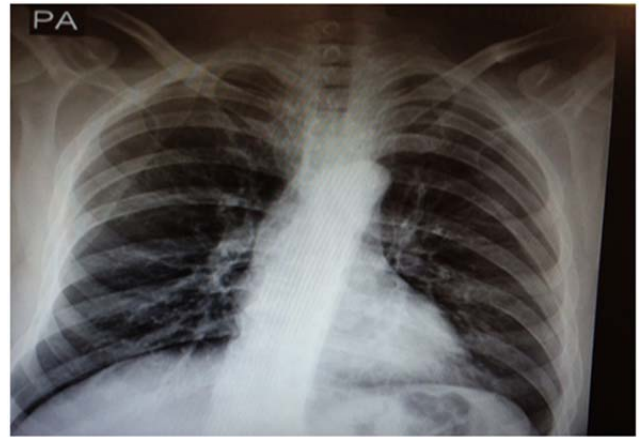


Figure 1. Chest X-ray of the patient in the first referral to Emergency department

After 2 months, the patient was admitted to the pulmonary ward of the Imam Khomeini Hospital. Due to the peripheral blood eosinophilia (3,300) with a clear increase of IgE (2860 IU/ml) and also with the presence of shortness of breath, coughing, and wheezing, the patient was diagnosed to have possible CEP. Churg-Strauss syndrome (vasculitis) was assessed using required tests, but the result was negative.

Moreover, other tests were performed on the patient and their results were normal. Then, a stool exam was asked to investigate other eosinophilic causes, which were negative for all parasites. Subsequently, with the probability of allergic bronchopulmonary aspergillosis (ABPA), a Prick skin test was carried out on the patient, which also had negative results. Afterward, high-resolution computed tomography (HRCT) was performed (Figure 2) on the patient and the results showed non-significant multiple lymph nodes with maximum diameters (SAD = 7 mm) and peripheral ground glass opacity in the left lower lobe, suggesting eosinophilic pneumonia. HRCT also showed that the patient had protuberances on the trachea surface and thus underwent

bronchoscopy for further examination and diagnostic lavage.

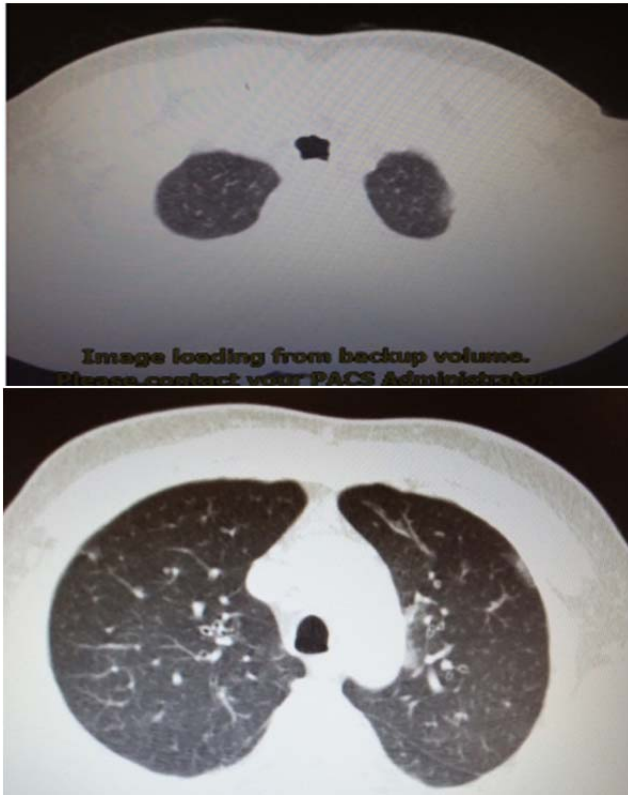


Figure 2. First CT scan cuts

In bronchoscopy, numerous protuberances of white cartilage were observed in the patient from the proximal part of the trachea to the distal part without the involvement of the posterior membrane and with an inflamed appearance of red mucous membrane (Figure 3). Further, diagnostic lavage was performed to investigate probable tuberculosis, fungal infection, and galactomannan to examine aspergillosis. The BAL result showed *Klebsiella pneumoniae* (10000/ml) and was sensitive to cefixime and ciprofloxacin, but BK and galactomannan were reported negative for fungal infection. Before obtaining the patient's biopsy result, he was diagnosed with CEP and treated with oral prednisolone 50 mg and a Symbicort inhaler.

After 10 days, the general condition of the patient was clearly improved and wheezing was not heard. The biopsy result showed TBPO (Figure 4). Subsequently, the oral

dose of prednisolone decreased and the peripheral blood eosinophil level was continuously monitored, with the reduction of eosinophil and the patient's shortness of breath and cough. After 3 months, the patient received a daily dose of 5 mg prednisolone. As soon as the dose of prednisolone was reduced, the patient's symptoms and wheezing in lung auscultation returned and thus we had to continue the daily dose of 5mg prednisolone.

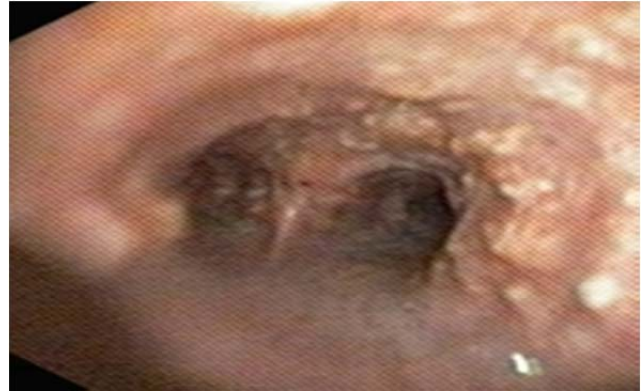

Figure 3. Protuberances of white cartilage with an inflamed appearance in

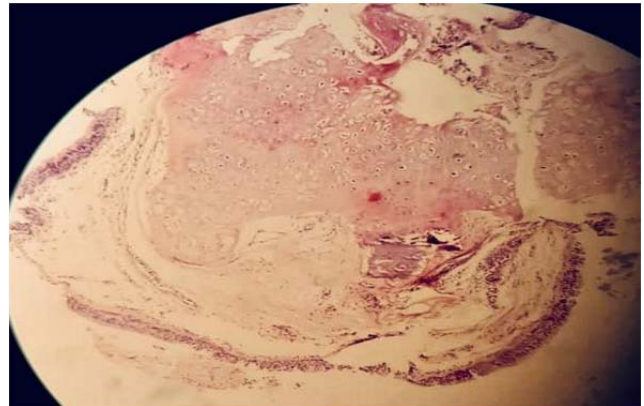


Figure 4. Biopsy of the tracheal protuberances

After 3 years, the patient was again admitted to the Pulmonary Ward for a retrospective investigation. In the follow-up, HRCT was performed on the patient (Figure 5) and the results showed mucosal prominences in the trachea. Thus, the patient underwent bronchoscopy, showing white-colored lesions throughout the trachea. Unlike the first bronchoscopy, the mucous membranes in the second bronchoscopy were not inflamed and the lesions were less severe. The results indicated that

corticosteroid therapy reduced the inflammation and the levels of IgE and peripheral blood eosinophil returned to normal. Therefore, the patient continued the treatment of 5 mg prednisolone with a Symbicort inhaler.

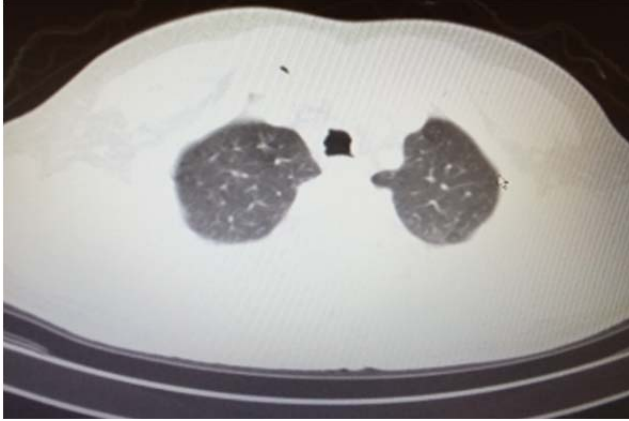

Figure 5. Patients CT scan in Follow up

The results indicated that corticosteroid therapy reduced the inflammation and the levels of IgE and peripheral blood eosinophil returned to normal. Therefore, the patient continued the treatment of 5 mg prednisolone with a Symbicort inhaler.

DISCUSSION

Non-neoplastic diseases of the central airway are uncommon, but can be localized or diffuse. Stenosis after intubation, stenosis after infection, post-transplant stenosis, and systemic diseases such as Crohn's disease, sarcoidosis, and Behcet's syndrome can lead to the focal stenosis of the airways. Wagner's granulomatosis, recurrent polycondritis, TBPO, amyloidosis, papillomatosis, and rhinocluroma can involve the airways (8). If patients with asthma and chronic obstructive pulmonary disease do not adequately respond to a treatment, and especially, if they do not have a family history of asthma and allergies and also do not have risk factors for chronic obstructive pulmonary diseases, they are suspicious of other chronic obstructive diseases such as TBPO (9). Lesions often occur in the lower two-thirds of the trachea. Lobar bronchi are often involved and lesions rarely extend to segmental bronchi (10). Halvani et al. observed nodular lesions in two patients. However, they reported that the lesions started

from the subglottic region in the first patient and from the two-thirds of the lower tracheal region in the second patient. They also reported that these lesions involved bilateral bronchial tubes in the both patients (9). In our case report, lesions were spread to the distal part of the trachea. Moreover, in our report, bronchoscopy showed numerous protuberances of white cartilage from the proximal part of the trachea to the distal part without the involvement of the posterior membrane and with an inflamed appearance of red mucous membrane. A majority of patients are in the fifth decade of their life (4, 5). This fact can be observed in both Halvani et al.'s report (9) and ours. Most of TBPO patients are asymptomatic, but may present with dry coughing, wheezing, exertional dyspnea, recurrent lung infections, and hemoptysis since nodules contact each other with mucus degradation (6-8). The mentioned symptoms were also observed in the reports of Barthwal et al. (10) and Zack and Rozenshtein (11). Our report also manifested similar symptoms including exertional dyspnea, dry coughing, occasional nocturnal sweating, tachycardia, tachypnea, hypoxia, and generalized wheezing during expiration.

CONCLUSION

In conclusion, in the lack of the response to a bronchodilator in a patient suspicious to asthma, we must look for other causes of respiratory wheezing and it is very vital to be differentiated with rare infectious diseases. When CT scan results are equivocal, we need to consider the possible diagnosis of TBPO with bronchoscopy and biopsy.

Conflict of interest

The authors declare that there is no conflict of interest in this study.

REFERENCES

1. Foiss AG, Arcadu A, Santoru L, Trisolini R, Marras V, Ginesu GC, et al. Tracheobronchopathia Osteochondroplastica: a rare case report of a non-smoker and non-atopic patient, with a

- long history of wheezing since childhood. *Multidiscip Respir Med* 2016;11:16.
2. Ulasli SS, Kupeli E. Tracheobronchopathia osteochondroplastica: a review of the literature. *Clin Respir J* 2015;9(4):386-91.
 3. Wang N, Long F, Jiang S. Tracheobronchopathia Osteochondroplastica: Two Cases Reports and Review of Literature. *Medicine (Baltimore)* 2016;95(19):e3396.
 4. Zhu Y, Wu N, Huang HD, Dong YC, Sun QY, Zhang W, et al. A clinical study of tracheobronchopathia osteochondroplastica: findings from a large Chinese cohort. *PLoS One* 2014;9(7):e102068.
 5. Lundgren R, Stjernberg NL. Tracheobronchopathia osteochondroplastica. A clinical bronchoscopic and spirometric study. *Chest* 1981;80(6):706-9.
 6. Restrepo S, Pandit M, Villamil MA, Rojas IC, Perez JM, Gascue A. Tracheobronchopathia osteochondroplastica: helical CT findings in 4 cases. *J Thorac Imaging* 2004;19(2):112-6.
 7. Leske V, Lazor R, Coetmeur D, Crestani B, Chatté G, Cordier JF; Groupe d'Etudes et de Recherche sur les Maladies "Orphelines" Pulmonaires (GERM"O"P). Tracheobronchopathia osteochondroplastica: a study of 41 patients. *Medicine (Baltimore)* 2001;80(6):378-90.
 8. Prince JS, Duhamel DR, Levin DL, Harrell JH, Friedman PJ. Nonneoplastic lesions of the tracheobronchial wall: radiologic findings with bronchoscopic correlation. *Radiographics* 2002;22 Spec No:S215-30.
 9. Halvani A, Karimi M, Noorani F. Tracheobronchopathia Osteochondroplastica. *SSU_Journals* 2008;16(1):168-.
 10. Barthwal MS, Chatterji RS, Mehta A. Tracheobronchopathia osteochondroplastica. *Indian J Chest Dis Allied Sci* 2004;46(1):43-6.
 11. Zack JR, Rozenshtein A. Tracheobronchopathia osteochondroplastica: report of three cases. *J Comput Assist Tomogr* 2002;26(1):33-6.