

## Clinical Efficacy of Endovascular Abdominal Aortic Aneurysm Repair

Bong-Su Son, M.D.\*, Sung Woon Chung, M.D.\*, Chungwon Lee, M.D.\*, Hyo Yeong Ahn, M.D.\*, Sangpil Kim, M.D.\*, Chang Won Kim, M.D.\*\*

**Background:** Endovascular aortic aneurysm repair (EVAR) has come into use and been widely extended because of the low complication rate and less-invasiveness. This article aimed to describe our experience in the treatment of abdominal aortic aneurysm with EVAR. **Materials and Methods:** A retrospective review was conducted for the 22 patients who underwent EVAR in a single hospital December 2001 to June 2009. **Results:** The mean age of the patients was 68.5±7.6 years. There were several risk factors and comorbidities in 20 patients (90.9%). The mean diameter of the aortic aneurysms was 61.2±12.9 mm. The mean length, diameter, and angle of the aneurysmal neck were 30.5±15.5 mm, 24.0±4.5 mm, and 43.9±16.0°, respectively. The mean follow-up period of the patients was 28.8±29.5 months. The 30-day postoperative mortality was none. Seven patients (31.8%) had endoleaks during the hospital stay and three patients (13.6%) had endoleaks during the follow-up period. One patient (4.5%) died due to a ruptured aortic aneurysm. The cumulative patient survival rates were 88.2%, 88.2%, and 70.6% at 1, 3, and 5 years of follow-up, respectively. **Conclusion:** EVAR is currently a safe, feasible procedure for high risk patients with abdominal aortic aneurysm because of low postoperative complication and mortality if patients are selected properly and followed up carefully.

Key words: 1. Aneurysm  
2. Aorta, abdominal  
3. Endovascular surgery

### INTRODUCTION

Since Dubost et al. [1] performed successful abdominal aortic replacement using the homograft of a thoracic aorta in 1952, surgery for aortic aneurysms has become common. Nevertheless, except some aortic aneurysms caused by vasculitis, abdominal aortic aneurysms are caused by atherosclerosis in most cases, and thus primarily develop in elderly patients. Because many elderly patients have associated un-

derlying comorbidities, such as diabetes and hypertension, surgical outcomes are occasionally poor. To overcome such problems, Parodi et al. [2] performed endovascular aortic aneurysm repair (EVAR) in 1991, and suggested as an alternative treatment method for aortic aneurysms in high risk patients. As the rate of early morbidities or mortality after EVAR has been proven lower [3,4], it has been replacing the conventional surgery especially in high risk patients. However, there have a small number of reports on the out-

\*Department of Thoracic and Cardiovascular Surgery, School of Medicine, Pusan National University

\*\*Department of Radiology, School of Medicine, Pusan National University

†This study was supported by Pusan National University Hospital grant (2009).

Received: October 5, 2010, Revised: February 7, 2011, Accepted: February 9, 2011

Corresponding author: Sung Woon Chung, Department of Thoracic and Cardiovascular Surgery, School of Medicine, Pusan National University, 10, Ami-dong, Seo-gu, Busan 602-739, Korea  
(Tel) 82-51-240-7263 (Fax) 82-51-243-9389 (E-mail) chungsungwoon@hanmail.net

© The Korean Society for Thoracic and Cardiovascular Surgery. 2011. All right reserved.

© This is an open access article distributed under the terms of the Creative Commons Attribution Non-Commercial License (<http://creativecommons.org/licenses/by-nc/3.0>) which permits unrestricted non-commercial use, distribution, and reproduction in any medium, provided the original work is properly cited.

come of EVAR in Korea.

Therefore, we conducted this study to assess the clinical usefulness by determining the characteristic and treatment outcomes of abdominal aortic aneurysm patients treated by EVAR in a single hospital comparing with the results of other investigators.

## MATERIALS AND METHODS

### 1) The subject patients

Among patients diagnosed with abdominal aortic aneurysms between December 2001 and June 2009, the study was conducted on the 22 patients treated by EVAR. The outcomes were assessed retrospectively. Aortic aneurysms were diagnosed by performing 3-dimensional computed tomography on all patients.

The indications for EVAR were as follows: the maximal diameter of the abdominal aneurysm is  $>5$  cm; even if the maximal diameter of the abdominal aneurysm is  $<5$  cm, the size increased by  $>0.5$  cm in the last 6 months; patients with symptoms of an abdominal aneurysm; patients who previously underwent abdominal surgery; patients at high risk for surgery due to associated diseases as well as old age; and patients reluctant to undergo surgery. The contraindications for EVAR were as follows: patients with ruptured abdominal aortic aneurysms; the angulation of the proximal aneurysmal neck was large and thus unsuitable for the procedure; the length of the proximal aneurysmal neck is  $<10$  mm; and patients with a tortuous iliac artery in whom the installation of stent grafts would be difficult. The adequate proximal neck length and angulation are more than 15 mm and less than  $60^\circ$ . However, even if the length and angulation of the aneurysmal neck was less than 15 mm or more than  $60^\circ$ , EVAR was performed in cases in which the risk for open surgical repair was determined high and EVAR was technically feasible.

### 2) Procedural methods

Prior to EVAR, the morphological characteristics of the aneurysm were assessed by 3-dimensional computed tomography and the size of the stent grafts was determined. Conventional angiography was occasionally performed if needed.

For cases in which a common iliac artery aneurysm was demonstrated by preprocedural computed tomography prior to or during procedure, the internal iliac artery was occluded by embolization to prevent a postprocedural endoleak.

Patients were placed in the supine position on the operating table, and after skin preparation and draping, local anesthesia was administered to the inguinal area with 2% lidocaine. Under duplex sonography monitoring, the femoral artery was assessed, a catheter was inserted into the abdominal aorta by Seldinger's method. By angiography, the location and size of the abdominal aorta were assessed again. Through the catheter, stent grafts were deployed and the presence or absence of endoleak was assessed immediately. If endoleak was detected, balloon dilatation and insertion of another stent graft was added. After completion of the deployment, the location of stent grafts and the presence or absence of endoleaks was assessed and the procedure was terminated. Whereas mild endoleak was observed by follow-up, persistent or severe endoleak was managed with a secondary intervention.

### 3) Follow-up observations

Computed tomography was performed 1 and 6 months after the intervention, and subsequently follow-up observations were performed annually. We conducted a telephone survey with each patient to obtain information on their physical status.

### 4) Research methods

The medical records of the patients were examined retrospectively, and demographic characteristics, clinical characteristics, morphologic characteristics of the aortic aneurysms, characteristics of the procedure, and postprocedural outcomes were assessed. To determine the demographic characteristics and clinical characteristics, the gender and age distributions were examined, and the symptoms and associated diseases were examined.

In addition, to examine the morphologic characteristics of the aortic aneurysms, the location and diameter of the aneurysm, the diameter of the proximal aneurysmal neck, the angle and length of the aneurysmal neck, the shape of the aortic aneurysm, and the diameter of the iliac artery were measured. The type and number of stent grafts used, anesthesia meth-

**Table 1.** Patient demographic data and comorbidity

	Number of patients (%)
Age (mean±SD year)	68.5±7.6
Symptoms	
Asymptomatic (incidental)	10 (45.4)
Abdominal pain	5 (22.7)
Palpable mass	4 (18.1)
Claudication and leg pain	3 (13.6)
Back pain	1 (4.5)
Impotence	1 (4.5)
Comorbidity	
Hypertension	13 (59.0)
Smoking	9 (40.9)
Pulmonary disease	8 (36.3)
Diabetes melitus	5 (22.7)
Heart disease	3 (13.6)
Hyperlipidemia	1 (4.5)
Cerebrovascular accident	3 (13.6)
Idiopathic thrombocytopenic purpura	1 (4.5)
Prior abdominal surgery	6 (27.2)

ods, and operative times were assessed.

To assess the outcomes of the procedure, the success rate of the procedure, the incidence of endoleaks and reintervention, and mortalities were examined.

### 5) Statistics

The statistical analysis of this study was performed using SPSS 17.0 for Windows (SPSS Inc., Chicago, IL, USA). Consecutive variable data were presented as the mean±deviation or the median (range), and compared by a chi-square test.  $p$ -value < 0.05 were considered statistically significant.

## RESULTS

The mean age of patients was 68.5±7.6 years, and the ratio of males-to-females was 17 : 5. With respect to symptoms, there were 10 (45.4%) asymptomatic incidentally found cases and 5 (22.7%) cases had abdominal pain. Among all the patients, 15 (68.1%) had nonspecific symptoms. Hypertension was the most prevalent associated disease (59.0%), followed by smoking (40.9%), lung diseases (36.3%), diabetes (22.7%), heart diseases (13.6%), and cerebrovascular diseases (13.6%). Among all of the patients, 20 (90.9%) had associated diseases (Table 1).

**Table 2.** Morphology of aneurysm

Morphology of aneurysm	
Location of disease	
Infrarenal	n=22
Diameter of aneurysm (mean±SD)	61.2±12.9 mm
Diameter of proximal neck (mean±SD)	24.0±4.5 mm
Angle of neck (mean±SD)	43.9±16.0°
Length of neck	
> 15 mm	n=18 (81.8%)
≤ 15 mm	n=4 (18.2%)
Shape of aneurysm	
Fusiform	18 (81.8%)
Saccular	4 (18.2%)
Size of Iliac artery (mean±SD)	23.1±10.3 mm

All of the patients had infra-renal abdominal aortic aneurysms. Eighteen patients (81.8%) had fusiform aortic aneurysms, and 4 patients (18.2%) had saccular aortic aneurysms. The mean diameter of the aortic aneurysm was 61.2±12.9 mm. The proximal aneurysmal neck was more than 15 mm in length in 18 cases (81.8%), and the mean length was 30.5±15.5 mm. The mean diameter and angle of the aneurysmal neck was 24.0±4.5 mm and 43.9±16.0°, respectively. The mean diameter of the iliac artery was 23.1±10.3 mm, and in most patients, the diameter of the iliac artery was greater than in healthy individuals (Table 2).

The Separate stent graft Y-type<sup>®</sup> (S&G Biotech, Sung Nam, Gyung Gi Do, Korea) was used in 1 case, the conventional stent graft I-type<sup>®</sup> (S&G Biotech) was used in 4 cases, the Excluder<sup>®</sup> (W. L. Gore, Flagstaff, AZ, USA) was used in 6 cases, and the Zenith<sup>®</sup> (Cook, Inc., Minneapolis, MN, USA) was used in 11 cases. EVAR was performed under local anesthesia with 2% lidocaine except one case. The one case was performed under epidural anesthesia for femoro-femoral bypass graft simultaneously, because of total occlusion of the common iliac artery. The average operative time was 136.1±28.7 minutes, and during the procedure, no significant hemorrhage or acute complications developed.

The hospitalization period after the procedure was 7.9±5.4 days, the average follow-up period was 28.8±29.5 months, and none of patients died within 30 days.

The deployment success rate of the procedure was 100%. The complete technical success rate, defined as cases without endoleak, was 68.2% and partial technical success rate, de-

**Table 4.** Patients with endoleak

Patient	Primary/ Secondary	Type of endoleak	Device	Length of neck (mm)	Angle of neck (°)	Follow-up period (month)	Progression
1	Secondary	III	Separate stent graft Y-type <sup>®</sup>	10	47.1	88	Reintervention due to disruption of left iliac arm
2	Primary	IV	Zenith <sup>®</sup>	30	52.1	25	Spontaneous resolved
3	Primary	IV	Zenith <sup>®</sup>	32	50	19	Spontaneous resolved
4	Primary	Ib	Excluder <sup>®</sup>	28	49.4	12	Mild endoleak, Observation
	Secondary	II					Mild endoleak, Observation
5	Primary	Ib	Zenith <sup>®</sup>	12	35	10	Spontaneous resolved
6	Primary	Ia	Excluder <sup>®</sup>	14	74.1	10	Resolved after rearrangement of the stent graft during procedure
7	Primary	II	Zenith <sup>®</sup>	10	45.6	4	Mild endoleak, Observation
8	Primary	II	Excluder <sup>®</sup>	76	46.1	4	Spontaneous resolved
9	Secondary	II	Excluder <sup>®</sup>	25	60	3	Mild endoleak, Observation

**Table 3.** Outcome of endovascular aortic aneurysm repair

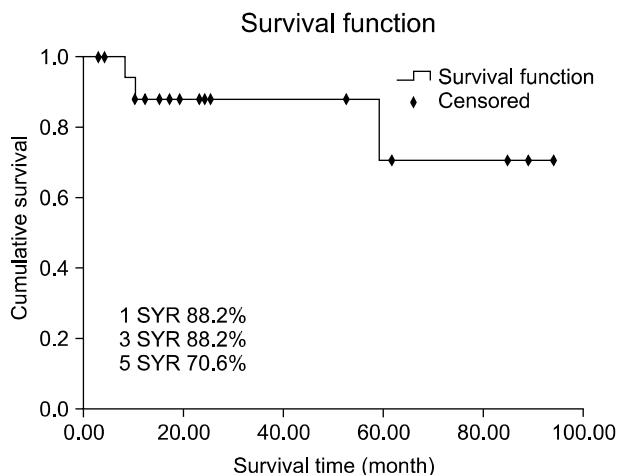
	Number of patients (%)
Deployment success rate	22 (100)
Technical success rate	
Partial	7 (31.8)
Complete	15 (68.2)
Primary endoleak	
Type I	3 (13.6)
Type II	2 (9.0)
Type IV	2 (9.0)
Secondary endoleak	
Type II	2 (9.0)
Type III	1 (4.5)
Reintervention	1 (4.5)*
Open repair during follow-up period	2 (9.0) <sup>†</sup>

\*=Due to type III endoleak; <sup>†</sup>=Due to ruptured aortic aneurysm.

defined as cases with endoleak was 31.8%. Endoleaks occurred in 7 patients (31.8%) immediately after the intervention or during the hospitalization period. In one patient with a type Ia endoleak, the endoleak resolved by rearrangement of the stent graft during the intervention. In four cases (one type Ib patient, one type II patient, and two type IV patients), the endoleak resolved during the follow-up observation period. Among the four cases, two patients with type IV endoleaks had Zenith<sup>®</sup> stent grafts (Cook, Inc.), and on the imaging obtained immediately after deployment of the stent grafts, mild endoleak was detected, which had resolved on the imaging obtained 1 month after the intervention. In the remaining two

cases (one type Ib patient and one type II patient), mild endoleak was persistent and they are currently under follow-up observation. Depending on the clinical course, reintervention may be considered. Endoleaks during the follow-up observation period occurred in 3 patients (13.6%). In one patient with a type III endoleak, reintervention with stent graft deployment was performed after 19 months of follow-up observation due to an endoleak in the left iliac artery; after 5 years 4 months of follow-up observation, an emergency axillo-bifemoral bypass graft was performed due to a ruptured aorta. For the remaining 2 cases (type II), because the endoleak was mild, the patients are currently under follow-up observation. After the intervention, surgical treatment was performed on 2 patients (9.0%) after 5 years 4 months and 4 years 1 month due to a ruptured aorta (Table 3, 4). The incidence of endoleaks in 9 patients (the one patient has both primary and secondary endoleak) in whom the length of the proximal aneurysmal neck was short (<15 mm) and the angle was large (>60°) was compared with 13 other patients. In the our study, a significant difference was not detected (p=0.135).

Three deaths (13.6%) occurred during follow-up observation. One patient underwent emergency surgery for a ruptured aorta after 4 years 1 month of follow-up observation and died of pneumonia 2 months after surgery. The other 2 patients died of renal failure and heart failure after 10 months and 8 months of follow-up observation, respectively. These patients



**Fig. 1.** Kaplan-Meier plot of patient survival. 1YSR=1 year survival rate; 3YSR=3 year survival rate; 5YSR=5 year survival rate.

were not associated with endoleak. The 1-, 3-, and 5-year survival rates were 88.2%, 88.2%, and 70.6%, respectively (Fig. 1).

## DISCUSSION

Surgical treatment for abdominal aortic aneurysms is a method of curative treatment. Although the surgery reduces the risk of rupture of the aortic aneurysm, the mortality pertinent to surgery has been reported to be approximately 2~8% [5]. In fact, in the high risk group for surgery, the morbidity is as high as 30% [6]. Thus, for high risk patients, surgical treatment for abdominal aortic aneurysms is a corresponding high risk treatment method. In 1991, Parodi et al. [2] performed EVAR on high risk patients and reported good results. Subsequently, EVAR was approved by the Food and Drug Administration (FDA) for the purpose of treating abdominal aortic aneurysm. From the 2000s when an education involving the procedure was actively promoted, treatment of abdominal aortic aneurysms with EVAR increased rapidly. Recently, with the development of smaller and more precise devices, EVAR is accepted as a useful treatment method for patients at high risk for postoperative complications and patients refusing open surgery.

This procedure is suitable for cases in which the length of the proximal aneurysmal neck is more than 1~2 cm, the

common iliac artery is suitable to distal immobilization, the aorta is without excessive twisting, and the approach to the appropriate iliac artery is easy. According to a Korean study reported in 2005 [7], it has been reported that 11.7% of non-ruptured abdominal aortic aneurysm patients were treated by the endovascular abdominal aortic aneurysm repair procedure.

The advantages of EVAR are the decrease in mortality, reduction in morbidity, shortening of the operative time, reduction of hemorrhage during the procedure, rapid recovery, reduction of the admission period to the intensive care unit, and less surgical stress. In our study, mortality directly related to EVAR was not detected and significant complications were not detected except minor endoleaks. The complications directly related to the procedure included renal infarctions, endoleaks, dislocation of the stent grafts, infections, ruptures, and thrombi within stent grafts. Among the complications, endoleaks are the most prevalent complication, and re-intervention for this has been shown to be the greatest shortcoming of EVAR.

Endoleaks can be diagnosed by the leakage of contrast to the outside of stent grafts and the inside of aneurysms. Immediately after the procedure, the incidence is more than 20~30%. Nonetheless, approximately one-half of endoleaks resolve spontaneously within the first 6 months. After 1 year, endoleaks are detected in approximately 10% of cases [8]. In several studies, the incidence of endoleaks and consequent re-intervention were examined. Sampaio et al. [9] have reported that the endoleak rate immediately after the intervention was approximately 35.7%. The EUROSTAR group [10,11] reported the incidence as 4.9~15%. May et al. [12] have reported that the incidence of endoleaks and the rate of re-intervention were 5.4% and 4.7%, respectively. Matsumura et al. [13] reported the incidence of endoleaks and the rate of re-intervention to be 20% and 11% after 24 months of follow-up observations. In our study, the rate of primary endoleaks was 31.8% and the rate of secondary endoleaks was 13.6%, which are comparable to the aforementioned studies.

According to May et al. [12], in the early postintervention period the mortality rate was 5.6%. Recently, due to the improvement in stent grafts and techniques, the mortality rate has decreased. Matsumura et al. [13] used the Excluder and

reported no mortality. The EUROSTAR group [10,11] reported a mortality rate of 1.6~3.2%. Greenberg et al. [14], who used the Zenith, reported a 0.2% mortality rate. In comparison with the mortality of open surgery, in which the mortality rate is 5%, the mortality rate of EVAR is comparatively low, thus confirming the safety of EVAR. In the our study, early mortality related to the intervention was 0%, and mortality related to rupture of the aorta after 30 days was 4.5%. In the DREAM and EVAR-1 trials, it has been reported that the early mortality of EVAR was significantly low, but the 2- and 4-year mortality rates were not different from open surgery, and the incidence of performing reintervention was higher in patients receiving intervention [15].

Currently, the results of long-term follow-up observation with EVAR have not been reported, and in comparison with open surgical treatments, the incidence of reintervention is high, and even after successful intervention, the necessity of the test for the development of endoleak and consequent financial problems have not been resolved. By considering the advantages as well as shortcomings of EVAR, it is thought that treatments applying the procedure should be performed for elderly patients in the high risk group whose life expectancy is more than 1 year or cases not suitable to surgical treatment.

## CONCLUSION

To obtain superior treatment outcomes of EVAR compared to surgery, precise evaluation of patients and aneurysms prior to the intervention, selection of patients, and the regular follow-up observation are essential. The size of the sample group was small and the follow-up observation period was short, and thus it may be required to revise and complement the findings by additional studies in the future.

Provided that appropriate evaluation and intervention are performed, EVAR is considered to be a safe and useful treatment method for the high risk surgical group

## REFERENCES

- Dubost C, Allary M, Oeconomos N. *Resection of an aneurysm of the abdominal aorta: reestablishment of the continuity by a preserved human arterial graft, with results after five months.* *AMA Arch Surg* 1952;64:405-8.
- Parodi JC, Palmaz JC, Barone HD. *Transfemoral intraluminal graft implantation for abdominal aortic aneurysms.* *Ann Vasc Surg* 1991;5:491-9.
- Shi DB, Fu WG, Wang YQ, et al. *Short to midterm results of endovascular for 105 case of infrarenal abdominal aortic aneurysms.* *Zhonghua Wai Ke Za Zhi* 2008;46:1638-41.
- Brewster DC, Jones JE, Chung TK, et al. *Long-term outcomes after endovascular abdominal aortic aneurysm repair: the first decade.* *Ann Surg* 2006;244:426-38.
- Hovsepian DM, Hein AN, Pilgram TK, et al. *Endovascular abdominal aortic aneurysm repair in 144 patients: correlation of aneurysm size, proximal aortic neck length, and procedure-related complications.* *J Vasc Interv Radiol* 2001;12:1373-82.
- Ahn SS, Rutherford RB, Johnston KW, et al. *Reporting standards for infrarenal endovascular abdominal aortic aneurysm repair.* *J Vasc Surg* 1997;25:405-10.
- Kim YW. *Report of nation-wide Questionnaire survey for abdominal aortic aneurysm treatment in Korea.* *J Korean Soc Vasc Surg* 2005;21:10-5.
- Baum RA, Stavropoulos SW, Fairman RM, Carpenter JP. *Endoleaks after endovascular repair of abdominal aortic aneurysms.* *J Vasc Interv Radiol* 2003;14:1111-7.
- Sampaio SM, Shin SH, Panneton JM, Andrews JC, Bower TC, Cherry KJ. *Intraoperative endoleak during EVAR: frequency, nature, and significance.* *Vasc Endovascular Surg* 2009;43:352-9.
- Peppelenbosch N, Buth J, Harris PL, Van Marresijk C, Franssen G. *EUROSTAR Collaborators. Diameter of abdominal aortic aneurysm and outcome of endovascular aneurysm repair: does size matter? A report from EUROSTAR.* *J Vasc Surg* 2004;39:288-97.
- Harris PL, Vallabhaneni SR, Desgranges P, Becquemin JP, Van Marrewijk C, Laheij RJ. *Incidence and risk factors of late rupture, conversion, and death after endovascular repair of infrarenal aortic aneurysms: the EUROSTAR experience. European Collaborators on Stent/graft techniques for aortic aneurysm repair.* *J Vasc Surg* 2000;32:739-49.
- May J, White GH, Yu W, et al. *Endovascular grafting for abdominal aortic aneurysms: changing incidence and indication for conversion to open operation.* *Cardiovasc Surg* 1998;6:194-7.
- Matsumura JS, Brewster DC, Makaroun MS, Naftel DC. *A multicenter controlled clinical trial of open versus endovascular treatment of abdominal aortic aneurysm.* *J Vasc Surg* 2003;37:262-71.
- Greenberg RK, Lawrence-Brown M, Bhandari G, et al. *An update of the Zenith endovascular graft for abdominal aortic aneurysms: initial implantation and mid-term follow-up data.* *J Vasc Surg* 2001;33:S157-64.
- Becquemin JP. *The ACE trial: A randomized comparison of open versus endovascular repair in good risk patients with abdominal aortic aneurysm.* *J Vasc Surg* 2009;50:222-4.