

➤ **Original Article** ◀

Natural History and Chronological Growth Rate of Renal Artery Aneurysms

Michihisa Umetsu, MD, Hitoshi Goto, MD, PhD, Masato Ohara, MD, PhD, Munetaka Hashimoto, MD, PhD, Takuya Shimizu, MD, PhD, Daijiro Akamatsu, MD, PhD, Ken Tsuchida, MD, PhD, Yuta Tajima, MD, PhD, Shunya Suzuki, MD, Keisuke Yamamoto, MD, Shigehito Miyagi, MD, PhD, Michiaki Unno, MD, PhD, and Takashi Kamei, MD, PhD

Objective: Renal artery aneurysm (RAA) is an uncommon disease, the natural course of which is still not well known. The objective of this study is to define factors that affect the growth rate of RAAs.

Materials and Methods: We retrospectively reviewed 32 aneurysms in 26 patients at our institute between January 2010 and March 2016. Basal demographics, comorbidities, reason for diagnosis, and details of the aneurysms and interventions were recorded. The chronological changes in the diameter of the RAA using multiplanar reconstructions of computed tomography images were measured and analyzed.

Results: The baseline mean diameter was 20.1 ± 8.4 mm (range: 9.9–41). The mean follow-up period was 3.13 ± 2.1 y (range: 0.5–7.1). The median growth rate was 0.35 mm/y (interquartile range: 0.05, 0.62). The growth rate was slower when the initial diameter was <20 mm than when it was >20 mm ($p=0.036$). Also, whole-completed calcification was a significant factor for slower growth ($p=0.016$). We performed ex-vivo surgery in two cases and coil packing with stenting in one. No ruptures occurred during the study period.

Conclusion: Our results suggest that cases with an RAA diameter <20 mm do not require intervention. The interval period can be longer in whole-completed calcification types.

Keywords: renal artery aneurysm, growth rate, natural history, expansion rate

Division of Vascular Surgery, Department of Surgery, Tohoku University, Sendai, Miyagi, Japan

Received: July 7, 2017; Accepted: August 25, 2017
Corresponding author: Michihisa Umetsu, MD. Division of Vascular Surgery, Department of Surgery, Tohoku University, 1-1 Seiryomachi, Aoba-ku, Sendai, Miyagi 980-8574, Japan
Tel: +81-22-717-7214, Fax: +81-22-717-7217
E-mail: mumetsu@med.tohoku.ac.jp

Introduction

Renal artery aneurysm (RAA) is an uncommon disease with an estimated incidence of 0.01% in autopsy findings.¹⁾ Recently, assisted by the remarkable developments in diagnostic imaging, the frequency of RAA detection has been increasing; it is reported to occur in 0.7% of all examinations using multidetector computed tomography (MDCT).²⁾ The natural course of RAA is still not well known. Indications for intervention are said to be rupture, symptoms such as hydronephrosis or hematuria, intractable hypertension, pregnancy, or renal artery diameter >20 mm.^{3,4)} Among these indications, the basis for diameter is unclear because few reports elucidate this indication. Therefore, we aimed to survey RAA patients at our institute.

Materials and Methods

We retrospectively surveyed RAA patients from January 2010 to March 2016 at our institute, Tohoku University Hospital, Sendai, Japan. We extracted demographics, comorbidities, reason for diagnosis, and laboratory data from the medical records. Hypertension was defined as blood pressure over 140/90 mmHg or the use of medication for hypertension. The location, shape, and diameter of the RAAs were confirmed using MDCT. The types were categorized by location as main trunk, main bifurcation, primary branch, and intrarenal types. The main trunk type was defined as an aneurysm located in the main renal artery but not reaching the branches: the main bifurcation type, an aneurysm involving the main renal artery and its first branch; the primary branch type, an aneurysm located in the first branch but not involving the main renal artery; and the intrarenal type, an aneurysm in a kidney or in the renal pelvis. The aneurysm shapes were categorized as saccular, lobed, or fusiform. Calcification of the RAA was measured and classified as a non- or incomplete-



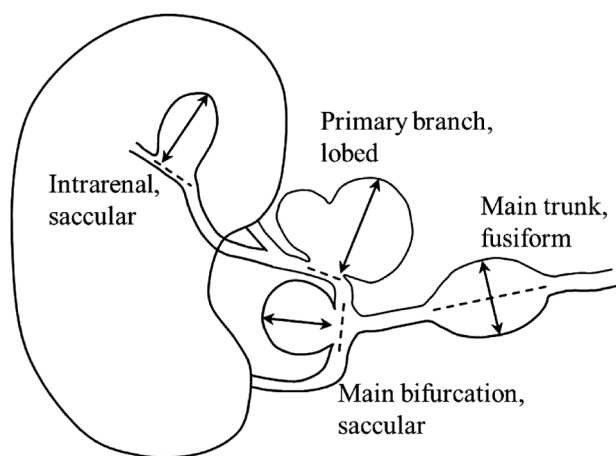


Fig. 1 Location, shape, and mode of measuring the diameter of RAAs.

calcification type or as a whole-completed calcification type. Non- or incomplete-calcification was defined as calcification <80% of the aneurysm's circumference, and whole-completed calcification was defined as calcification >80% of the circumference as detected by MDCT. Follow-up was performed by ultrasound or MDCT; MDCT examinations were performed at least once a year. The chronological order of change of the diameter was determined using multiplanar reconstructions, with the diameter defined as the maximum width perpendicular to the original artery. **Figure 1** depicts the measurements of the aneurysm diameters. Our measurement data approximately matched the report of a radiologist. We achieved good reproducibility. All radiological data were viewed with a Ziocube DICOM viewer (Ziosoft, Osaka, Japan).

For the statistical analyses, the percentage, mean \pm standard deviation, or median [interquartile range (IQR)] in patients' basal characteristic data were calculated. Growth rates were assessed from the diameter of the aneurysm on initial arrival, the calcification type, shape, location, and patient's gender, age, hypertension, and side using the t-test. A p value <0.05 was considered significant. All statistical analyses were performed with JMP pro 12.2.0 software (SAS Institute Inc., Cary, NC, USA).

This study was approved by the Institutional Review Board of Tohoku University Graduate School of Medicine.

Results

We identified 32 RAAs in 26 patients at our institute from January 2010 to March 2016. **Table 1** shows baseline characteristics of the patients. The baseline mean age was 61.5 ± 15.4 years (range: 27–84). Females were in the majority (males, 10; females, 16). The mean follow-up period was 3.13 ± 2.12 years (range: 0.5–7.1 years). One-half of the patients had hypertension; however, other

Table 1 Baseline characteristics

Demographics	
Mean age \pm S.D.	61.5 ± 15.4 year (range: 27–84)
Gender	Male: 10 Female: 16
Comorbidities	
Hypertension	13 (50.0%)
Diabetes mellitus	5 (19.2%)
Dyslipidemia	5 (19.2%)
Coronary artery disease	1 (3.8%)
Cerebral vascular disease	1 (3.8%)
Opportunity of diagnosis	
Incidental finding	16 (61.5%) (All by CT)
Abdominal or back pain examination	6 (23.1%) (All by CT)
Health examination	4 (15.4%) (3 by Ultrasound, 1 by CT)
Aneurysm	
Mean follow-up period	3.13 ± 2.12 year (range: 0.5–7.1)
Mean diameter on initial arrival	20.1 ± 8.4 mm (range: 9.9–41)
Median growth rate	0.35 mm/y (IQR 0.05, 0.62)
Side	Right 17/Left 15
Multiple RAA	3 (11.5%)
Bilateral RAA	1 (3.8%)
Location	
Main trunk	13 (40.6%)
Main bifurcation	11 (34.4%)
Primary branch	5 (15.6%)
Intrarenal	3 (9.4%)
Shapes	
Saccular	27 (84.4%)
Lobed	4 (12.5%)
Fusiform	1 (3.1%)
Calcification	
Non- or incomplete-calcification	26 (81.3%)
Whole-completed calcification	6 (18.8%)

SD: standard deviation; IQR: interquartile range; CT: computed tomography

risk factors for arteriosclerosis such as dyslipidemia and diabetes mellitus were infrequent. The most frequent reason for diagnosis was incidental findings on computed tomography done to investigate other symptoms (22 cases, 84.6%). Three cases were detected on ultrasound imaging for health examinations (11.5%). No patients were symptomatic.

The baseline mean diameter of RAAs was 20.1 ± 8.4 mm (range: 9.9–41). The most frequent location was the main bifurcation (13 cases, 40.6%), and the next was the primary branch (11 cases, 34.4%). These two locations accounted for 75% of RAAs. There were three intrarenal

Table 2 Analysis of the growth rate

		Median growth rate (IQR) mm/y	p value
Initial diameter	<20 mm	0.21 (-0.01, 0.38)	p=0.036
	>20 mm	0.82 (0.33, 1.76)	
Calcification	Non- or incomplete	0.36 (0.20, 0.62)	p=0.016
	Whole-completed	-0.09 (-0.23, 0.26)	
Gender	Female	0.21 (0.0, 0.48)	p=0.70
	Male	0.35 (0.08, 0.82)	
Age	Under 70-year-old	0.21 (0.03, 1.02)	p=0.15
	Over 70-year-old	0.35 (-0.13, 0.47)	
Hypertension	Yes	0.28 (-0.01, 0.50)	p=0.96
	No	0.31 (0.01, 0.58)	
Side	Right	0.27 (-0.1, 0.48)	p=0.49
	Left	0.46 (0.13, 0.82)	
Shape	Saccular	0.35 (0.05, 0.50)	p=0.55
	Lobed	0.78 (-0.04, 1.6)	
	Fusiform	-0.17 (-0.17, -0.17)	
Location	Intrarenal	0.46 (0.46, 0.46)	p=0.48
	Primary branch	0.21 (-0.01, 0.4)	
	Main bifurcation	0.36 (-0.11, 0.76)	
	Main trunk	1.06 (0.51, 1.61)	

IQR: interquartile range

(9.4%) and five main trunk RAAs (15.6%). Saccular types were the most frequent RAA shape (27 cases, 84.4%). Among the others, four were lobed (12.5%) and only one was fusiform. RAA calcification was also investigated. The whole-completed calcification type observed in six cases (18.8%), and non- or incomplete-calcification type was observed in 26 cases (81.3%).

Figure 2 shows changes in diameter. We defined the diameter of the saccular type as the maximum length perpendicular to the artery. We calculated the growth rate from the size measured on initial arrival to the most recent measurement. The median growth rate was 0.35 mm/y (IQR: 0.05, 0.62).

Table 2 shows the median growth rate for each factor, such as diameter, calcification, gender, age, hypertension, side, shape, and location. The growth rate of RAAs with a baseline diameter <20 mm was significantly slower (p=0.036), as was the growth rate for the whole-completed calcification type (p=0.016). The diameter of the whole-completed calcification type remained mostly unchanged. Growth rate with hypertension or at normal blood pressure was independently similar (0.42 vs 0.41 mm/y). For the other factors, the growth rate was not significantly different.

Surgical intervention was performed in three cases; details are shown in Table 3. Case 1 describes a 42-year-old female patient with an intrarenal RAA of 35 mm, which was indicated for coil packing and stenting. Case 2

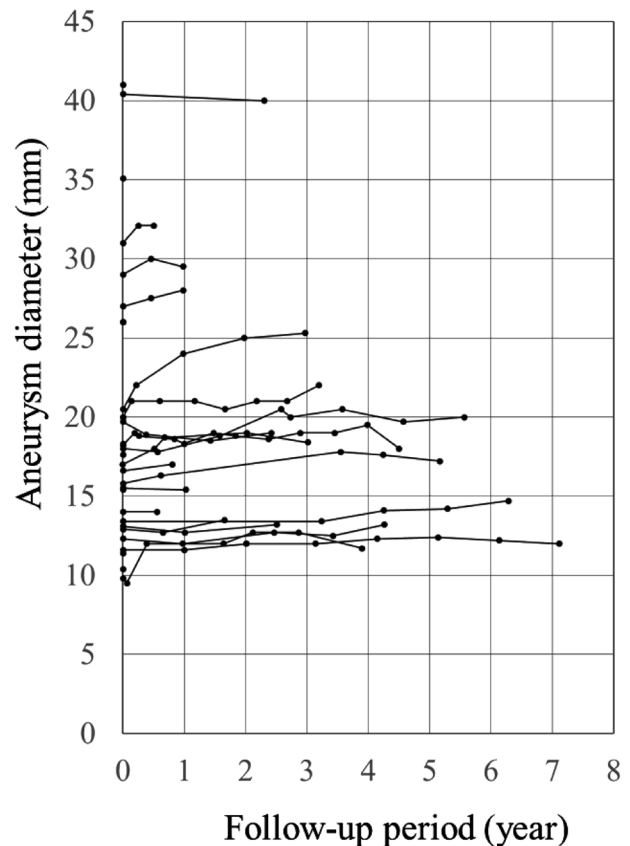


Fig. 2 Chronological change in aneurysm diameter. The horizontal axis reflects the time of follow-up; the vertical axis reflects the diameter of RAA.

Table 3 Cases that required intervention

No.	Age	Gender	Diameter	Shape	Location	Intervention	Complication
1	42	Female	35mm	Saccular	Intrarenal	Stent+Coil packing	Mild renal infarction
2	43	Male	41mm	Saccular	Main bifurcation	Ex vivo Surgery	Mild renal infarction
3	76	Female	40mm	Fusiform	Main bifurcation	Ex vivo Surgery	None

describes a 43-year-old male patient, and case 3 describes a 76-year-old female patient. Ex-vivo surgery was performed on cases 2 and 3. In cases 1 and 2 a small renal infarction occurred; however, renal functions were maintained after surgery. None of the patients had any recurrence. In addition, there was no ruptured case during the follow-up period.

Discussion

One of the accepted indications of RAA is a diameter over 20mm, except in female expectation of pregnancy or in cases with symptomatic RAA; these need to be considered independently. As majority of the reports are from Western countries, this study is meaningful because we investigated chronological changes of RAA in an Asian population.

The median growth rate in this study was 0.35 mm/y. This is similar to that found in previous studies.^{5,6)} We discovered that the growth rate is faster when the baseline diameter is >20 mm ($p=0.036$). However, some aneurysms grow slowly even though their diameter is >20 mm: these aneurysms belong to the whole-completed calcification type. In all cases of this type, growth was slow regardless of the diameter. In previous reports, there was no significant difference in the growth rates between calcified and non-calcified aneurysms.^{5,7)} However, in aneurysms classified as whole-completed calcification, growth was quite slow ($p=0.016$). In one case of great interest, calcification progressed steadily during the entire study period. Even though the calcification extended over the entire aneurysm, the growth rate was a constant 0.5 mm/y. Follow-up will be conducted to further monitor the growth rate for slowing.

A former study reported that aneurysms with circumferential calcification were unlikely to rupture.⁸⁾ Using high-detailed imaging, we discerned at a high level of accuracy that whole-completed calcification types were significantly slower growing. The walls of whole-completed calcifications are less flexible, but the intensity of their aneurysmal wall would be equal. Our results suggest that a longer follow-up interval could be provided in the whole-completed calcification type. As we do not have a large enough number of cases to check for the rupture rate of the whole-completed calcification type, the intervention of a large cohort of whole-completed calcification type of

RAAs based on the diameter should be planned.

Decades ago, intervention was recommended for diameters of 15–20mm regardless of blood pressure status.⁹⁾ Presently, a diameter of 20 mm is accepted in most medical institutions as indication for intervention. A recent study has suggested that asymptomatic RAAs with diameter >30 mm should be considered for intervention, as all ruptured cases were >30 mm.⁷⁾ Thus, the indication diameter for RAA is changing over time. Our study suggests that for asymptomatic RAAs with diameter <20 mm, non-operative management is reasonable. Intervention for asymptomatic RAA with diameter <20 mm is no longer realistic. Also, for asymptomatic RAAs with diameter of 20–30 mm, observation could be acceptable. Diameters >20 mm were seldom included in previous studies. More investigation of larger aneurysms is required to reveal their natural history and their risk of rupturing. Such studies could be helpful in regulating when to decide to intervene. Also, records of whole-completed calcification types should be collected to identify the relationship between the progress of calcification with the growth rate and the risk of rupture. It should be noted that rupture under observation is very rare, ranging from 0% to 1.2% of cases.^{5,9)} We also had no rupture among our cases during the follow-up period. The low risk of rupture makes it difficult to shed light on it as a risk factor or how that changes based on optimal diameter.

Also, it is remarkable that cases of rupture of small sizes have been reported during pregnancy, especially in the third trimester. The etiology of RAA during pregnancy has not been reported previously. Hemodynamic and hormonal changes facilitate rupture, and rupture during pregnancy comes with a high rate of fetal mortality and morbidity.^{4,10)} It is thought to be rare, but it cannot be overlooked.

Broadly, there are several approaches for the treatment of RAA, such as endovascular and open surgical approach. Open surgical approaches for aneurysm include the venous patch or ex-vivo surgery, whereas endovascular approaches are coil packing with stenting, embolization, or stent grafts.^{11–13)} The outcomes of each approach are similar.^{7,14–17)} Recently, a report described the use of a multilayer flow modulator, which has the potential to modulate the aneurysm without critical shuttering or loss of native side branches.¹⁸⁾ We need to select strategies according to the shape or location of the aneurysm and the

patient's general condition.

In addition, we tend to consider the difficulty of intervention. As main bifurcation or primary branch RAAs are more common, larger aneurysms would involve more branches. Distal branches will more frequently be of a smaller diameter, and we should consider sacrificing a small branch in endovascular treatment or increase anastomosis in open surgery. However, we must be aware that sacrificing small vessels has at least a slight effect on renal function. At present, we are using renoscintigraphy to evaluate differential renal function. However, there is some risk of being over-concerned regarding interventional difficulty, but earlier interventions may result in an increase in the number of unnecessary interventions. We need evidence for both the diameter that warns regarding the increases in the risk of rupture and the safe diameters at which unnecessary interventions can be avoided.

We acknowledge that this study has some limitations. First, it is a single-center retrospective study. We recognize that some data is missing and bias exists. As longer durations are needed to evaluate aneurysms, our mean follow-up period of 3.13 year was insufficient. Further, it is unavoidable that small or slow-growing aneurysms are outnumbered in a study cohort. However, in our study, 30% of RAAs were >20 mm. This is a relatively high ratio compared with that in previous reports. Also, we used growth rates expressed in mm/y. Our report suggests that the growth rates would increase more rapidly relative to the original diameter. However, expressed in mm/y, the value would be smaller in small aneurysms. Expressed as percentages, growth rates would be more equal; however, we used mm/y because this parameter has been used in most reports of aneurysms.

Conclusion

This report is the first to present the natural history of RAA. At diameters <20 mm their growth was significantly slow. Also, regardless of the diameter, growth rate was significantly slow in whole-completed calcification types of RAA. Our study supports non-operative management for diameters of <20 mm. The interval period can be longer in whole-completed calcification types. A study with a larger number of RAAs with diameters >20 mm is required to make an appropriate indication.

Disclosure Statement

The authors have no conflicts of interest to disclose.

Author Contributions

Study conception: HG

Data collection: KY, MU

Analysis: MU

Investigation: MU

Writing: MU

Critical review: all authors

Final approval of the manuscript: all authors

Accountability for all aspects of the work: all authors

References

- 1) Tham G, Ekelund L, Herrlin K, et al. Renal artery aneurysms. Natural history and prognosis. *Ann Surg* 1983; **197**: 348-52.
- 2) Zhang LJ, Yang GF, Qi J, et al. Renal artery aneurysm: diagnosis and surveillance with multidetector-row computed tomography. *Acta Radiol* 2007; **48**: 274-9.
- 3) Jibiki M, Inoue Y, Kudo T, et al. Surgical procedures for renal artery aneurysms. *Ann Vasc Dis* 2012; **5**: 157-60.
- 4) Schulte W, Rodriguez-Davalos M, Lujic M, et al. Operative management of hilar renal artery aneurysm in a pregnant patient. *Ann Vasc Dis* 2015; **8**: 242-5.
- 5) Klausner JQ, Harlander-Locke MP, Plotnik AN, et al. Current treatment of renal artery aneurysms may be too aggressive. *J Vasc Surg* 2014; **59**: 1356-61.
- 6) Wayne EJ, Edwards MS, Stafford JM, et al. Anatomic characteristics and natural history of renal artery aneurysms during longitudinal imaging surveillance. *J Vasc Surg* 2014; **60**: 448-53.
- 7) Klausner JQ, Lawrence PF, Harlander-Locke MP, et al. The contemporary management of renal artery aneurysms. *J Vasc Surg* 2015; **61**: 978-84.e1.
- 8) González J, Esteban M, Andres G, et al. Renal artery aneurysms. *Curr Urol Rep* 2014; **15**: 376.
- 9) Henke PK, Cardneau JD, Welling TH 3rd, et al. Renal artery aneurysms: a 35-year clinical experience with 252 aneurysms in 168 patients. *Ann Surg* 2001; **234**: 454-63; discussion, 462-3.
- 10) Hellmund A, Meyer C, Fingerhut D, et al. Rupture of renal artery aneurysm during late pregnancy: clinical features and diagnosis. *Arch Gynecol Obstet* 2016; **293**: 505-8.
- 11) Eskandari MK and Resnick SA. Aneurysms of the renal artery. *Semin Vasc Surg* 2005; **18**: 202-8.
- 12) Ching CB, Tiong HY, Lee UJ, et al. Renal artery aneurysm treated with ex vivo reconstruction and autotransplantation. *Urology* 2010; **75**: 1067-8.
- 13) Laser A, Flinn WR, Benjamin ME. Ex vivo repair of renal artery aneurysms. *J Vasc Surg* 2015; **62**: 606-9.
- 14) Elaassar O, Auriol J, Marquez R, et al. Endovascular techniques for the treatment of renal artery aneurysms. *Cardiovasc Intervent Radiol* 2011; **34**: 926-35.
- 15) Tsilimparis N, Reeves JG, Dayama A, et al. Endovascular vs open repair of renal artery aneurysms: outcomes of repair and long-term renal function. *J Am Coll Surg* 2013; **217**: 263-9.
- 16) Buck DB, Curran T, McCallum JC, et al. Management and outcomes of isolated renal artery aneurysms in the endovascular era. *J Vasc Surg* 2016; **63**: 77-81.
- 17) Duprey A, Chavent B, Meyer-Bisch V, et al. Editor's choice—ex vivo renal artery repair with kidney autotransplantation

for renal artery branch aneurysms: long-term results of sixty-seven procedures. *Eur J Vasc Endovasc Surg* 2016; 51: 872-9.

18) Sultan S, Basuoniy Alawy M, Flaherty R, et al. Endovascular management of renal artery aneurysms using the multilayer flow modulator. *Open Heart* 2016; 3: e000320.