

Special Focus Review

Congenital adrenal hyperplasia

Clio Dessinioti* and A.D. Katsambas

Department of Dermatology; Andreas Sygros Hospital; University of Athens; Athens, Greece

Key words: congenital adrenal hyperplasia, acne, hirsutism

Congenital adrenal hyperplasia consists of a heterogeneous group of inherited disorders due to enzymatic defects in the biosynthetic pathway of cortisol and/or aldosterone. This results in glucocorticoid deficiency, mineralocorticoid deficiency and androgen excess. 95% of CAH cases are due to 21-hydroxylase deficiency. Clinical forms range from the severe, classical CAH associated with complete loss of enzyme function, to milder, non-classical forms (NCAH). Androgen excess affects the pilosebaceous unit, causing cutaneous manifestations such as acne, androgenetic alopecia and hirsutism. Clinical differential diagnosis between NCAH and polycystic ovary syndrome may be difficult. In this review, the evaluation of patients with suspected CAH, the clinical presentation of CAH forms, with emphasis on the cutaneous manifestations of the disease and available treatment options, will be discussed.

Introduction

The human adrenal glands synthesize three main classes of hormones, namely mineralocorticoids, glucocorticoids and sex steroids, through a series of enzymatic steps from the cholesterol precursor molecule. In particular, the human adrenal cortex consists of three zones, the zona glomerulosa where aldosterone is produced, the zona fasciculata where glucocorticoids are produced and the zona reticularis where adrenal androgens are produced.¹

The earliest case of congenital adrenal hyperplasia (CAH) was reported in 1865 by the Neapolitan anatomist De Crecchio.² CAH is defined as a group of inherited autosomal recessive disorders which result from an enzyme defect in the biosynthetic pathway of cortisol and/or aldosterone.³

The anterior pituitary regulates adrenal steroidogenesis via adrenocorticotrophic hormone (ACTH). The circulating level of plasma cortisol is a key player in the hypothalamic-pituitary-adrenal feedback system and exerts a negative feedback effect on the secretion of ACTH. So, in case of a decrease in cortisol secretion, increased ACTH secretion will follow.⁴ In most forms of CAH, an enzyme defect blocks cortisol synthesis, thus impairing cortisol-mediated negative feedback control of ACTH secretion. Oversecretion of ACTH ensues, which results in overstimulation of the adrenals and

causes their hyperplasia.³ Also, ACTH oversecretion stimulates excessive synthesis of the adrenal products of those pathways unimpaired by an enzyme deficiency and causes an accumulation of precursor molecules in pathways blocked by an enzyme deficiency.⁴

95% of CAH cases are due to 21-hydroxylase (21OH) deficiency, caused by mutations in the 21-hydroxylase gene (CYP21A2). CAH due to 21-hydroxylase deficiency (21OHD CAH) is one of the most commonly known autosomal recessive disorders in humans.³ 21-OH is a cytochrome P450 that is required for the conversion of 17-hydroxyprogesterone to 11-deoxycortisol, and when deficient results in impaired synthesis of cortisol. Also, 21OH is required for mineralocorticoid production and when deficient, results in impaired synthesis of aldosterone. On the other hand, it does not participate in the pathway of androgen production (Fig. 1). Consequently, the loss of the cortisol-mediated negative feedback control of ACTH secretion results in oversecretion of ACTH and overproduction of adrenal androgens.⁴ Different CYP21 mutations result in varying degrees of impaired 21-OH activity and cause a spectrum of disease expression.⁵

The clinical forms of 21OHD CAH are typically classified as classical, the severe form (CAH), or non-classic (21OHD-NCAH), the mild or late-onset form. Sometimes congenital adrenal hyperplasia may remain asymptomatic (cryptic form). Classic congenital adrenal hyperplasia is subclassified as salt-wasting (SW) or simple-virilizing (SV) forms, depending on the presence of aldosterone deficiency (Fig. 2).³

Classical and Nonclassical 21-Hydroxylase Deficiency

Epidemiology. Classical congenital adrenal hyperplasia occurs in approximately 1/15,000 births, while 21OH-NCAH is much more frequent and occurs in approximately 1% of the general population, with an incidence of 1:500 to 1:1,000 in various Caucasian populations.⁶ Some ethnic groups are at higher risk, such as Ashkenazi Jews (prevalence: one in 27), Hispanics (one in 40) and Slavs (one in 50).⁷⁻⁹ NCAH has been found in less than 5% of hyperandrogenic women in the general population.⁹

Genetics. The most frequent CAH variant, accounting for 95% of all affected patients, is 21-hydroxylase deficiency, caused by deletions and deleterious mutations in the active 21-hydroxylase gene (CYP21). The CYP21 gene was decoded in 1986 and the molecular genetic mutations specific for the nonclassical form of 21 OHD have later been deciphered.¹⁰⁻¹³ The CYP21 gene is located on chromosome 6p21.3, forming tandemly repeated units with the pseudogene, CYP21P. The CYP21 and CYP21P genes present 98% homology in their nucleotide coding sequence.^{14,15}

*Correspondence to: Clio Dessinioti; A. Sygros Hospital; Department of Dermatology; 5, I. Dragoumi Street; Kaisariani, Athens 16121 Greece; Email: il5@hotmail.com

Submitted: 01/09/09; Accepted: 01/13/09

Previously published online as a *Dermato-Endocrinology* E-publication:
<http://www.landesbioscience.com/journals/dermatoendocrinology/article/7818>

The clinical spectrum ranges from classical congenital adrenal hyperplasia associated with complete loss of enzyme function with presentation in the neonatal period, to milder or non-classical forms presenting in adolescence or adulthood. Mutations producing enzymes retaining 20 to 60% of normal activity are associated with NCAH, while more serious mutations resulting in totally ablate enzyme activity or 1–2% of normal activity, are associated with classic disease.¹⁴

DNA-based prenatal diagnosis and treatment of 21OH-CAH has been used for over 15 years and is indicated in case of a family history of CAH, making CAH the first inborn metabolic disorder to be successfully treated prenatally.^{4,16} Also, neonatal screening for CAH is possible.¹⁷

Clinical manifestations of classical CAH. Clinical manifestations in classical CAH are due to glucocorticoid deficiency, mineralocorticoid deficiency and androgen excess.

Also, the deficiency of cortisol secretion is associated with abnormalities in the secretion of other pituitary hormones, namely growth hormone (GH) and thyroid stimulating hormone (TSH).^{18,19}

Both the SV and the SW forms of 21OH CAH are characterized by prenatal virilization of the female genitalia and postnatal virilization of both boys and girls, due to excessive adrenal androgen secretion.⁴ The SW form of CAH, without treatment will lead to death, due to electrolyte abnormalities and vascular collapse.^{5,20}

Postnatally, in untreated boys and girls, androgen excess results in rapid growth, advanced epiphyseal maturation, and ultimately, early epiphyseal closure and short stature (tall children, short adults). Also, untreated patients present early appearance of facial, axillary and pubic hair and acne.⁵

Fertility in female CAH patients is reduced, due to surgical (inadequate vaginal introitus), endocrinologic (elevated follicular phase progesterone concentrations) or psychological reasons. However, the prospects for achieving fertility have improved markedly and young women can be reassured that it is often possible.²¹

In male patients, suppression of gonadotrophins by adrenal testosterone and adrenal 'rests' stimulated by ACTH lead to infertility, as a result of poor compliance with glucocorticoid treatment. Male infertility is potentially reversible with increased glucocorticoid suppression.^{3,5,6}

Clinical manifestations of non-classical CAH. NCAH is a widely underdiagnosed disorder in children and adults; a few NCAH cases are detected by newborn-screening programs but most are missed because of the relatively low baseline levels of 17-hydroxyprogesterone (17OHPG). NCAH may be associated

with a variety of hyperandrogenic symptoms presenting either in childhood (precocious puberty), or sometimes later in adulthood (acne, infertility).^{20,22}

Precocious puberty may present in childhood, with advanced bone age, accelerated growth and premature development of pubic or axillary hair. Nevertheless, growth is eventually arrested because of early epiphyseal fusion which compromises final height (tall children, short adults).²³ Also, a high incidence of molecular defects of CYP21 gene has been shown in a series of Greek children with premature adrenarche.²⁴

Androgenic alopecia may be the sole symptom in young women with NCAH.²⁵

Moreover, women with 21OHD-NCAH may present with hirsutism which is the most common symptom. The prevalence of hirsutism may increase with age, highlighting the progressive nature

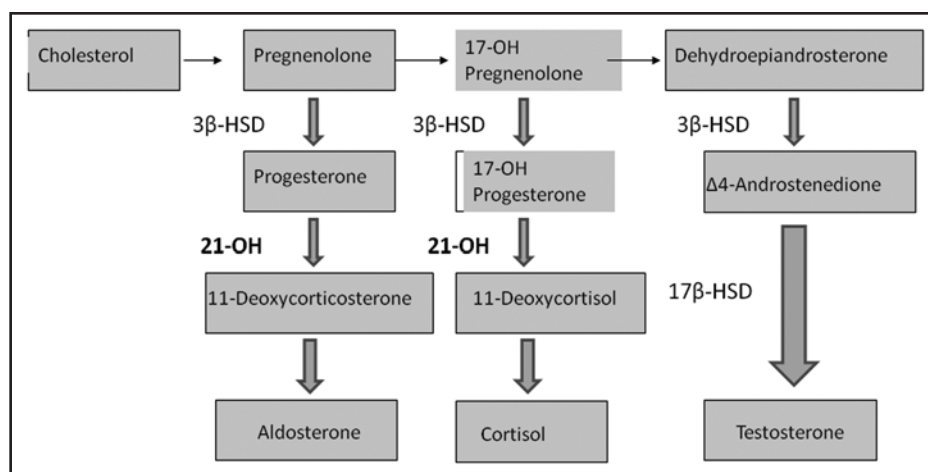


Figure 1. Simplified scheme of the role of 21-hydroxylase in the adrenal steroidogenesis pathway.

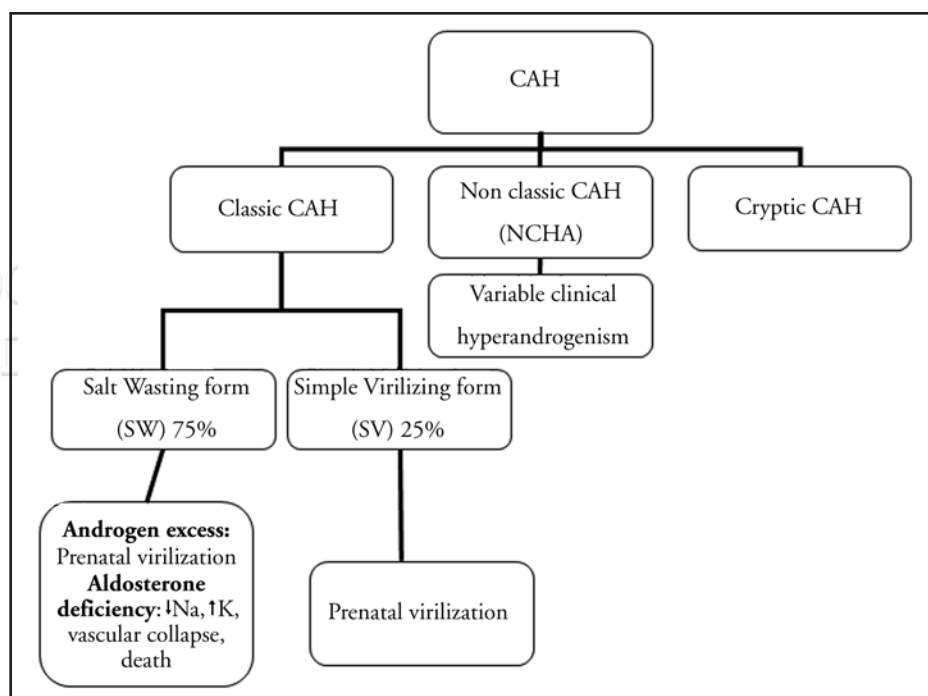


Figure 2. Clinical forms of CAH.

Table 1 Cutaneous manifestations of CAH forms due to 21-hydroxylase deficiency

Classic form	Non classic form
<ul style="list-style-type: none"> • Virilization: female pseudohermaphroditism • Early appearance of facial, axillary and pubic hair • Acne • Hirsutism 	<ul style="list-style-type: none"> • Acne • Hirsutism • Androgenic alopecia • PCOS

Table 2 Investigations for suspected congenital adrenal hyperplasia in patients with acne

- Thorough medical history: age of pubarche, infertility, acne, use of androgenic medications
- Physical examination
- Serum luteinizing hormone (LH), follicle-stimulating hormone (FSH)
- Testosterone, DHEA-S, androstenedione
- Basal plasma 17-OH progesterone (8.00 am): >15 nmol/l (>2 ng/ml)
- ACTH-stimulation test
- Pelvic ultrasonography: to detect polycystic ovaries
- Computed tomography: for the exclusion of adrenal tumor
- Molecular gene analysis

of NCAH.²⁶ NCAH was reported in 14% of young women with hirsutism and oligomenorrhea in a retrospective study,²⁷ and in 1.2–30% of hirsute, oligomenorrheic women in other published series.^{28–32}

Furthermore, studies in female patients show that NCAH may present with menstrual irregularities, obesity, short stature, infertility or subfertility and skin disorders, including hirsutism, seborrhea and/or acne in the peripubertal period. These clinical characteristics of NCAH do not differ from those in female patients with polycystic ovary syndrome (PCOS), or hyperinsulinemia.^{23,33,34} Insulin insensitivity in females with NCAH has been described, but it has not been established whether an association with acne exists in these patients.³⁵ Nevertheless, insulin resistance results in compensatory hyperinsulinemia which, in turn, may increase the responsiveness of the pilosebaceous unit to androgens.³⁶

Some women with NCAH present with PCOS. In these cases, either the cyclicality of gonadotropin release is disrupted, or the ovary is directly affected by adrenal androgen excess. As a result, ovarian cysts are formed, which begin to autonomously produce androgens.^{4,23} The frequency of NCAH in PCOS has been reported in some studies. A prospective study of 107 Greek women with hirsutism and PCOS, showed that 10% were affected by NCAH.³⁴ A prevalence of 9.52% and 33% have been reported in women suffering from hirsutism and PCOS in Turkey.^{37,38} In a study of Spanish women with hirsutism, irregular menses, acne or androgenic alopecia, NCAH was found in 2.2%, based on biochemical evidence or molecular genotype analysis.³⁹

Male patients with NCAH may be asymptomatic or present with acne or infertility.⁴⁰ Severe cystic acne refractory to oral antibiotics

and isotretinoin has been associated with NCAH due to 21-OH deficiency.^{41–43} Most of the men with NCAH are fertile (Table 1).⁵

In NCAH, cortisol synthesis during stress is not impaired and there is no risk of adrenal insufficiency.⁵

Evaluation of the Patient with Suspected CAH

Biochemical diagnosis of CAH relies on the determination of 17-OH PG, the immediate substrate for 21-OH. A basal 17-OH PG level >6.1 nmol/L (>2 ng/mL or 200 ng/dl) can serve for screening for NCAH.⁵

The ACTH stimulation test is the best screening test for evaluating adrenal gland function, and it is valuable in cases of mild forms of congenital adrenal hyperplasia with normal basal adrenal steroids.⁴⁴ It has been used for the biochemical diagnosis of NCAH due to other enzyme deficiencies.⁴⁵ The test should be performed in the early follicular phase (day 3–7 of the menstrual cycle). Blood samples are obtained before (0 min) and 60 min following intravenous injection of Tetracosactid, 25 IU (hormonally active ACTH fragment, Synacten, Novartis, Nürnberg, Germany). Basal and stimulated 17-OH PG levels are determined and the possibility of CAH is considered if basal 17-OH PG levels are elevated and/or ACTH-stimulated 17-OH PG is more than 260 ng/dL (7.87 nmol/L) above the basal level.^{44,46} Furthermore, the diagnosis of 21-OH deficient NCAH is established by the response of 17-OH progesterone to adrenocortical stimulation with levels >30.3 nmol/L (>10 ng/mL).^{5,26} Further investigations for CAH are summarized in Table 2.⁵

Borderline biochemical data may make diagnosis of NCAH challenging.²⁰ So, NCAH should be differentiated from other disorders, including PCOS, Cushing's syndrome, hyperprolactinemia, thyroid dysfunction and androgen-secreting tumors.⁹ In women, NCAH presenting with skin manifestations of androgen excess such as acne, androgenic alopecia or hirsutism, should be differentiated from polycystic ovary syndrome; oligomenorrhea or amenorrhea are uncommon in NCAH.⁴⁷ Polycystic ovary syndrome has been defined, based on an international agreement (The Rotterdam Consensus Group in 2003), by the presence of at least two of the following: (1) oligomenorrhea or amenorrhea, (2) clinical hyperandrogenism or serum androgen excess, (3) polycystic ovaries by a pelvic ultrasound (ovarian volume ≥ 10 cm³, multiple follicle (≥ 12) distributed peripherally, stroma increased).⁴⁸ In patients with hirsutism and suspected NCAH, such as those with a positive family history of CAH or in high-risk ethnic groups (Ashkenazi Jews, Hispanics, Slavics), an early morning, follicular phase level of 17-OHPG should be measured to facilitate diagnosis.⁹

Molecular diagnosis. The utility of genotype analysis of the 21-OH gene has been proposed in hyperandrogenic women presenting symptoms ranging from hirsutism, acne and amenorrhea, to decreased fertility, in order to distinguish heterozygous from wild-type individuals and to characterize biochemically borderline individuals.²⁰ Nevertheless, in clinical practice, molecular biology is not routinely available.

Management of the CAH Patient

General considerations. Current treatment of classical CAH is intended to reduce excessive ACTH and the consequent increase in androgen production, by substituting for cortisol

(with oral glucocorticoids, including prednisolone, hydrocortisone or dexamethasone) and, when necessary, aldosterone deficiency (with fludrocortisone).³ During childhood, the main aims of medical treatment of 21OH CAH are to prevent salt loss and virilization, to achieve normal stature and to undergo normal puberty. In adulthood, the aims of medical treatment are to ensure normal fertility and to avoid the long-term consequences of glucocorticoid use.³

Treatment of non-classical late onset form depends on the main problem of the patient, such as acne, hirsutism or androgenetic alopecia.⁴⁰

Management of cutaneous manifestations of CAH. Adolescents or adult CAH patients represent the group that may need dermatologic attention, as acne and hirsutism, the main skin manifestations of CAH, usually develop during adolescence.

For the treatment of acne associated with NCAH, oral glucocorticoids are administered in order to counteract adrenal androgen production.⁴⁴ Low-dose prednisone (2.5–5 mg/day) or low-dose dexamethasone (0.25–0.75 mg) can be given orally at bedtime, although the latter incurs a higher risk of adrenal suppression.^{44,49} Oral methylprednisolone (initial dose of 1 mg/kg/day) in combination with oral isotretinoin was a successful treatment for acne fulminans in a boy with NCAH.⁴⁶ In order to ensure that glucocorticoids are efficacious, the serum DHEAS level can be monitored for a decrease or normalization. To check for adrenal suppression, an ACTH stimulation test should be performed two to three months after initiation of therapy. This involves assessing the plasma cortisol level 30 minutes following an injection of 250 µg/m² ACTH. A raise in plasma cortisol by appropriate amounts (>16 µg/dL) indicates that the adrenal gland is not suppressed.⁵⁰

The risk of osteoporosis associated with long-term administration of glucocorticoids is even more prominent in teenagers whose bone development is still ongoing. Therefore, low-dose glucocorticoids should not be taken for a time period longer than six months.⁴⁴

Treatment of hirsutism is reviewed elsewhere, and includes physical methods to remove excess hair and/or anti-androgens (spironolactone, cyproterone acetate, drospirenone), or finasteride.⁵¹ Cyproterone acetate was found better than hydrocortisone in the treatment of hirsutism in women with NCAH.⁵²

Conclusions

CAH is generally considered to be an endocrine disease. However, the hyperandrogenism associated with CAH (classical or non-classical form) can have a major impact on the skin of affected patients.⁵³ One should keep in mind that although hyperandrogenism is a major cause of concern for women, it may also affect men, with acne being the sole presenting symptom. Dermatologists should be able to evaluate for CAH forms and provide therapeutic options for acne and hirsutism associated with CAH. In order to provide the CAH patient with optimal care, a multidisciplinary approach comprising endocrinologists, gynecologists, plastic surgeons, as well as dermatologists, is therefore essential.

References

- Demirci C, Feldman-Witchel S. Congenital adrenal hyperplasia. *Dermatol Ther* 2008; 21:340-53.
- De Crecchio L. Sopra un caso di apparenzi virili in una donna. *Morgagni* 1865; 7:154-88.
- Bachelor A, Chakthoura Z, Rouxel A, Dulon J, Touraine P. Classical forms of congenital adrenal hyperplasia due to 21-hydroxylase deficiency in adults. *Horm Res* 2008; 69:203-11.
- New MI. An update of congenital adrenal hyperplasia. *Ann NY Acad Sci* 2004; 1038:14-43.
- Dessinioti C. Congenital adrenal hyperplasia and acne in male patients. In: Zouboulis CC, Katsambas AD, Kligman AM, eds. *Acne vulgaris and Rosacea: Pathogenesis and treatment*. Springer, in press.
- Wedell A, Ritzén EM, Haglund-Stengler B, Luthman H. Steroid 21-hydroxylase deficiency: Three additional mutated alleles and establishment of phenotype-genotype relationships of common mutations. *Proc Natl Acad Sci USA* 1992; 89:7232-6.
- Speiser PW. Congenital adrenal hyperplasia owing to 21-hydroxylase deficiency. *Endocrinol Metab Clin North America* 2001; 30:31-59.
- Speiser PW, Dupont B, Rubinstein P, Piazza A, Kastelan A, New MI. High frequency of nonclassical steroid 21-hydroxylase deficiency. *Am J Hum Gen* 1985; 37:650-67.
- Rosenfield RL. What every physician should know about polycystic ovary syndrome. *Dermatol Ther* 2008; 21:354-61.
- Higashi Y, Yoshioka H, Yamane M, Gotoh O, Fujii-Kuriyama Y. Complete nucleotide sequence of two steroid 21-hydroxylase genes tandemly arranged in human chromosome: A pseudogene and a genuine gene. *Proc Natl Acad Sci USA* 1986; 83:2841-5.
- Tusie-Luna MT, Speiser PW, Dumic M, New MI, White PC. A mutation (Pro-30 to Leu) in CYP21 represents a potential nonclass steroid 21-hydroxylase deficiency allele. *Mol Endocrinol* 1991; 5:685-92.
- Helmborg A, Tusie-Luna M, Tabarelli M, Kofler R, White PC, R339H and P453S. CYP21 mutations associated with nonclass steroid 21-hydroxylase deficiency that are not apparent gene conversions. *Mol Endocrinol* 1992; 6:1318-22.
- Speiser PW, New MI, White PC. Molecular genetic analysis of nonclass steroid 21-hydroxylase deficiency associated with HLA-B14,DR1. *N Engl J Med* 1988; 319:19-23.
- Speiser PW, White PC. Congenital adrenal hyperplasia. *N Engl J Med* 2003; 349:776-88.
- Levine LS, Zachmann M, New MI, Prader A, Pollack MS, O'Neill GJ, et al. Genetic mapping of the 21-hydroxylase-deficiency gene within the HLA linkage group. *N Engl J Med* 1978; 299:911-5.
- Speiser PW, Laforgia N, Kato K, Pareira J, Khan R, Yang SY, et al. First trimester prenatal treatment and molecular genetic diagnosis of congenital adrenal hyperplasia (21-hydroxylase deficiency). *J Clin Endocrinol Metab* 1990; 70:838-48.
- Therrell BL. Newborn screening for congenital adrenal hyperplasia. *Endocrinol Metab Clin North Am* 2001; 30:15-30.
- Ghizzoni L, Mastorakos G, Vottero A, Magiakou MA, Chrousos GP, Bernasconi S. Spontaneous cortisol and growth hormone secretion interactions in patients with nonclass steroid 21-hydroxylase deficiency (NCCAH) and control children. *J Clin Endocrinol Metab* 1996; 81:482-7.
- Ghizzoni L, Mastorakos G, Street ME, Vottero A, Mazzardo G, Vanelli M, et al. Spontaneous thyrotropin and cortisol secretion interactions in patients with nonclass steroid 21-hydroxylase deficiency and control children. *J Clin Endocrinol Metab* 1997; 82:3677-83.
- Blanché H, Vexiau P, Clauin S, Le Gall I, Fiet J, Morner E, et al. Exhaustive screening of the 21-hydroxylase gene in a population of hyperandrogenic women. *Hum Genet* 1997; 101:56-60.
- Conway GS. Congenital adrenal hyperplasia: Adolescence and transition. *Horm Res* 2007; 68:155-7.
- Kuttann F, Couillin P, Girard F, Billaud L, Vincens M, Boucekkine C, et al. Late-onset hyperplasia in hirsutism. *N Engl J Med* 1985; 313:224-31.
- New MI. Extensive clinical experience. Nonclassical 21-hydroxylase deficiency. *J Clin Endocrinol Metab* 2006; 91:4205-14.
- Dacou Voutekakis C, Drakopoulou M. High incidence of molecular defects of the CYP21 gene in patients with premature adrenarche. *J Clin Endocrinol Metab* 1999; 84:1570-4.
- Odrescolli J, Anderson D. Untreated congenital adrenal hyperplasia. *J Ral Soc Med* 1993; 86:229.
- Moran C, Azziz R, Carmina E, Dewailly D, Fruzzetti F, Ibañez L, et al. 21-hydroxylase-deficient nonclass adrenal hyperplasia is a progressive disorder: A multicenter study. *Am J Obstet Gynecol* 2000; 183:1468-74.
- Pang SY, Lerner AJ, Stoner E, Levine LS, Oberfield SE, Engel I, et al. Late-onset adrenal steroid 3 β-hydroxysteroid dehydrogenase deficiency I. A cause of hirsutism in pubertal and postpubertal women. *J Clin Endocrinol Metab* 1985; 60:428-39.
- Child D, Bu'Lock D, Anderson D. Adrenal steroidogenesis in hirsute women. *Clin Endocrinol (Oxf)* 1980; 12:595-601.
- Gibson M, Lackritz R, Schiff I, Tulchinsky D. Abnormal adrenal responses to adrenocorticotrophic hormone in hyperandrogenic women. *Fertil Steril* 1980; 33:43-8.
- Lobo R, Goebelsmann U. Adult manifestation of congenital adrenal hyperplasia due to incomplete 21-hydroxylase deficiency mimicking polycystic ovarian disease. *Am J Obstet Gynecol* 1980; 138:720-6.
- Chrousos GP, Loriaux DL, Mann D, Cutler GB Jr. Late-onset 21-hydroxylase deficiency is an allelic variant of congenital adrenal hyperplasia characterized by attenuated clinical expression and different HLA haplotype associations. *Horm Res* 1982; 16:193-200.
- Kuttann F, Couillin P, Girard F, Billaud L, Vincens M, Boucekkine C, et al. Late-onset adrenal hyperplasia in hirsutism. *N Engl J Med* 1985; 313:224-31.
- Chrousos GP, Loriaux DL, Mann DL, Cutler GB Jr. Late onset 21-hydroxylase deficiency mimicking idiopathic hirsutism or polycystic ovarian disease. *Ann Int Med* 1982; 96:43-8.

34. Trakakis E, Rizos D, Loghis C, Chryssikopoulos A, Spyropoulou M, Salamalekis E, et al. The prevalence of non-classical congenital adrenal hyperplasia due to 21-hydroxylase deficiency in Greek women with hirsutism and polycystic ovary syndrome. *Endocr J* 2008; 55:33-9.
35. Speiser PW, Serrat J, New MI, Gertner JM. Insulin insensitivity in adrenal hyperplasia due to nonclassical steroid 21-hydroxylase deficiency. *J Clin Endocrinol Metab* 1992; 75:1421-4.
36. Rosenfield RL. Polycystic ovary syndrome and insulin-resistant hyperinsulinemia. *J Am Acad Dermatol* 2001; 45:95-104.
37. Kamel N, Tonyukuk V, Emral R, Corapçioğlu D, Baştemiş M, Güllü S. The prevalence of late onset congenital adrenal hyperplasia in hirsute women from Central Anatolia. *Endocrine J* 2003; 50:815-23.
38. Yarman S, Dursun A, Oguz F, Alagol F. The prevalence, molecular analysis and HLA typing of late-onset 21-hydroxylase deficiency in Turkish women with hirsutism and polycystic ovary. *Endocrine J* 2004; 51:31-6.
39. Escobar-Morreale HF, Snachon R, San Millan JL. A prospective study of the prevalence of nonclassical congenital adrenal hyperplasia among women presenting with hyperandrogenic symptoms and signs. *J Clin Endocrinol Metab* 2008; 93:5275-83.
40. Kelestimir F. Non-classic congenital adrenal hyperplasia. *Pediatr Endocrinol Rev* 2006; 3:451-4.
41. Marynick SP, Chakmakjian ZH, McCaffree DL, Herndon JH Jr. Androgen excess in cystic acne. *N Engl J Med* 1983; 308:981-6.
42. Ostlere LS, Rumsby G, Holownia P, Jacobs HS, Rustin MH, Honour JW. Carrier status for steroid 21-hydroxylase deficiency is only one factor in the variable phenotype of acne. *Clin Endocrinol (Oxf)* 1998; 48:209-15.
43. Lucky AW, Rosenfield RL, McGuire J, Rudy S, Helke J. Adrenal androgen hyperresponsiveness to adrenocorticotropin in women with acne and/or hirsutism: Adrenal enzyme defects and exaggerated adrenarche. *J Clin Endocrinol Metab* 1986; 62:840-8.
44. Degitz K, Placzek M, Arnold B, Schmidt H, Plewig G. Congenital adrenal hyperplasia and acne in male patients. *Br J Dermatol* 2003; 148:1263-6.
45. Azziz R, Rafi A, Smith BR, Bradley EL Jr, Zacur HA. On the origin of the elevated 17-hydroxyprogesterone levels after adrenal stimulation in hyperandrogenism. *J Clin Endocrinol Metab* 1990; 70:431-6.
46. Placzek M, Degitz K, Schmidt H, Plewig G. Acne fulminans in late-onset congenital adrenal hyperplasia. *The Lancet* 1999; 354:739-40.
47. Lowenstein EJ. Diagnosis and management of the dermatologic manifestation of the polycystic ovary syndrome. *Dermatol Ther* 2006; 19:210-23.
48. Fauser B. Revised 2003 consensus on diagnostic criteria and long-term health risks related to polycystic ovary disease (PCOS). *Hun Reprod* 2003; 19:41-7.
49. Gollnick H, Cunliffe W, Berson D, Dreno B, Finlay A, Leyden JJ, et al. Management of acne. *J Am Acad Dermatol* 2003; 49:20-5.
50. Thiboutot D. Acne: Hormonal concepts. *Clin Dermatol* 2004; 22:419-28.
51. Blume-Peytavi U, Hahn S. Medical treatment of hirsutism. *Dermatol Ther* 2008; 21:329-39.
52. Spritzer P, Billaud L, Thalabard JC, Birman P, Mowszowicz I, Raux-Demay MC, et al. Cyproterone acetate versus hydrocortisone treatment in late-onset congenital hyperplasia. *J Clin Endocrinol Metab* 1990; 70:642-6.
53. Heymann WR. Hyperandrogenism and the skin. *J Am Acad Dermatol* 2004; 50:937-8.