

A Tale of Too Many Ulcers: Simultaneous Crohn's and Behçet Overlap Syndrome

Andrew Elton, BS¹, Bryant Megna, MD², Byron Vaughn, MD^{2,3}, and Aasma Shaukat, MD MPH^{3,4}

¹University of Minnesota Medical School, Minneapolis, MN

²Department of Internal Medicine, University of Minnesota, Minneapolis, MN

³Division of Gastroenterology, Hepatology, and Nutrition, Department of Internal Medicine, University of Minnesota, Minneapolis, MN

⁴Gastroenterology Section, Minneapolis Veterans Affairs Medical Center, Minneapolis, MN

CASE REPORT

A 25-year-old white woman with no pertinent medical history presented with 2 weeks of fever, hematochezia, and scattered mucocutaneous ulcers. Physical examination was notable for fever (100.6°F, 38.1°C), tachycardia, tenderness of the right wrist and metacarpophalangeal joints, diffuse abdominal tenderness, and multiple clean-based ulcerations of the trunk, orolabial mucosa, vaginal introitus, perianal, and gluteal regions. Pathergy findings were present at peripheral intravenous sites (Figure 1). Constitutional and mucocutaneous findings were initially highly suspicious for a systemic vasculitis, and more specifically, the patient met a number of the International Criteria for the Behçet disease.¹

Initial laboratories indicated anemia, leukocytosis, and elevated C-reactive protein. Infectious workup was negative for *Clostridioides difficile*, hepatitis B virus, syphilis, human immunodeficiency virus, yeast, *Trichomonas*, *Chlamydia/Neisseria*, herpes simplex virus 1/2, cytomegalovirus, and varicella-zoster virus. Computed tomography showed inflammatory changes and wall thickening from the distal ileum through the large bowel, including the distal transverse colon and rectum (Figure 2).

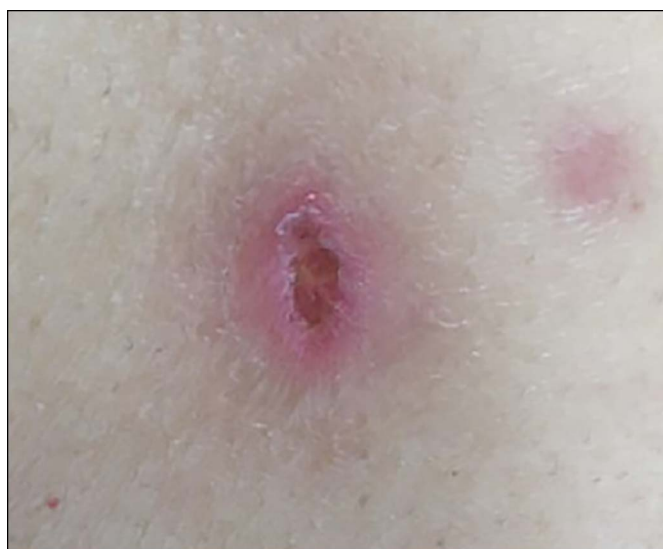

Figure 1. Pathergy findings were present at peripheral intravenous sites.

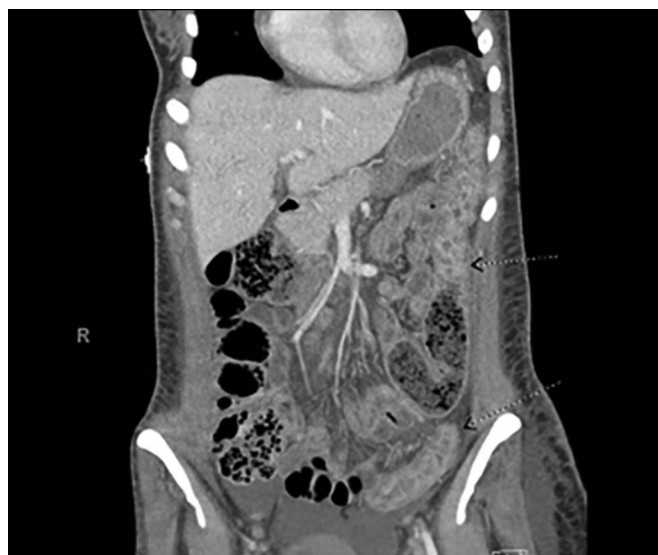

Figure 2. Computed tomography showing inflammatory changes and wall thickening from the distal ileum to the large bowel including the distal transverse colon and rectum.

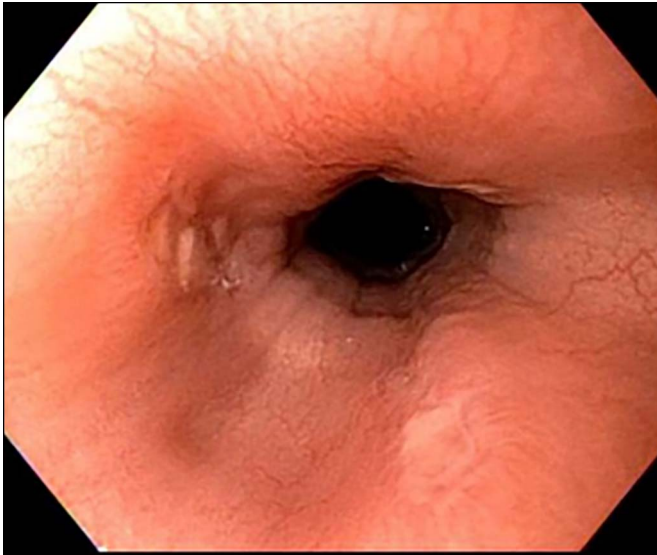


Figure 3. An esophagogastroduodenoscopy showing nonbleeding ulcers along the middle third of the esophagus with erythema of the gastric body.

An esophagogastroduodenoscopy showed nonbleeding ulcers along the middle third of the esophagus with erythema of the gastric body (Figure 3). Pathology of these ulcers demonstrated acute and chronic inflammation, focal ulceration, and granulation tissue formation. Colonoscopy demonstrated longitudinal, deep, serpiginous ulcers with cobblestone appearance scattered throughout the rectum, sigmoid colon, and descending colon (Figure 4). This distribution and appearance of ulcerations on endoscopy supported a Crohn's phenotype in

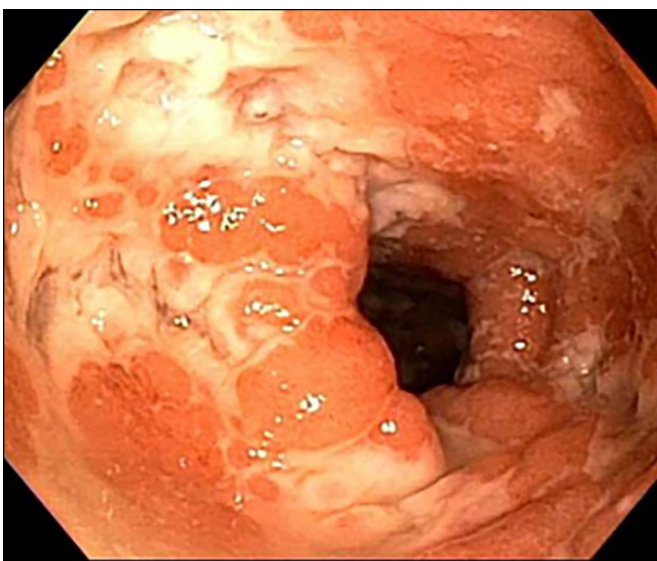


Figure 4. Colonoscopy showing longitudinal, deep, serpiginous ulcers scattered throughout the rectum, sigmoid colon, and descending colon.

the large bowel, as opposed to the intestinal Behçet disease which tends to manifest as round, focal ulcerations.²

Biopsies showed moderate chronic active colitis with significant crypt distortion, cryptitis, and crypt abscess formation with no granulomas noted. The patient was subsequently diagnosed with overlap syndrome including Crohn's disease and Behçet disease, an exceedingly rare entity with multiple opportunities for clinical mimicry.³ A regimen of colchicine, corticosteroids, infliximab, and azathioprine resolved her symptoms, and the patient now demonstrates quiescent disease at 22 months of follow-up. Thankfully, a refractory Behçet disease (especially cases with intestinal involvement) and severe Crohn's disease both share a proven response to infliximab.⁴ This case demonstrates the importance of appreciating extracolonic manifestations of inflammatory bowel disease, vasculitides presenting with gastrointestinal phenotypes, and situations when both entities exist.

DISCLOSURES

Author contributions: A. Elton and B. Megna wrote and edited the article, and reviewed the literature. B. Vaughn and A. Shaukat edited the article and approved the final article. A. Shaukat is the article guarantor.

Financial disclosure: B. Vaughn has received personal compensation for speaking/consulting from Abbvie and grant support from Genentech, Takeda, Celgene, and Diasorin.

Previous presentation: This case was presented at the American College of Physicians, November 8-9, 2018; Minneapolis, Minnesota.

Informed consent was obtained for this case report.

Received June 23, 2020; Accepted February 16, 2021

REFERENCES

1. Davatchi F, Chams-Davatchi C, Shams H, et al. Behçet's disease: Epidemiology, clinical manifestations, and diagnosis. *Expert Rev Clin Immunol.* 2017;13(1):57-65.
2. Lee SK, Kim BK, Kim TI, Kim WH. Differential diagnosis of intestinal Behçet's disease and Crohn's disease by colonoscopic findings. *Endoscopy.* 2009;41(1):9-16.
3. Rodrigues-Pinto E, Magro F, Pimenta S, Guimaraes J, Macedo G. Mimicry between intestinal Behçet's disease and inflammatory bowel disease. *J Crohns Colitis.* 2014;8(7):714-5.
4. Lee JH, Cheon JH, Jeon SW, et al. Efficacy of infliximab in intestinal behçet's disease: A Korean multicenter retrospective study. *Inflamm Bowel Dis.* 2013;19(9):1833-8.

Copyright: © 2021 The Author(s). Published by Wolters Kluwer Health, Inc. on behalf of The American College of Gastroenterology. This is an open access article distributed under the terms of the Creative Commons Attribution-Non Commercial-No Derivatives License 4.0 (CCBY-NC-ND), where it is permissible to download and share the work provided it is properly cited. The work cannot be changed in any way or used commercially without permission from the journal.