

# Primary epithelioid angiosarcoma of right hip joint

## A case report and literature review

Jin Wang, MS, Min Zhao, BS\*, Jin Huang, MS, Lin Ang, MS, Li Zheng, MS

### Abstract

**Rationale:** Epithelioid angiosarcoma (EA) is a rare, highly invasive tumor. The histopathological features of EA are not distinct and less reported in the literature, and most of the medical records are incomplete.

**Patient concerns:** A 61-year-old woman who came to the hospital because of pain in her right hip. This patient had had surgery for right hip tuberculosis 30 years ago.

**Diagnoses:** The present study reports a case of primary EA of bone with aneurysmal bone cyst (ABC) that was diagnosed by 3 experienced pathologists.

**Interventions:** The patients had undergone 2 surgeries; however, an early recurrence of the tumor was caused the death of the patient.

**Outcomes:** Ten EA cases from other literature were reviewed in this article; all the symptoms were found in different parts of bone, and the case data were relatively complete. The primary clinical features and nonspecific histopathological morphology of the disease were summarized from the 11 cases mentioned in the literature, and the main immunohistochemistry characteristics and diagnostic traps of EA were reviewed.

**Lessons:** Because the tumor has no characteristic diagnostic index in imaging and laboratory examination, the histopathologic features are not typical, especially in the case of obvious secondary lesions. It is easy to miss and misdiagnose. If possible, the diagnosis should be combined with immunohistochemical results.

**Abbreviations:** ABC = aneurysmal bone cyst, EA = epithelioid angiosarcoma, IHC = immunohistochemistry.

**Keywords:** aneurysmal bone cyst, bone, epithelioid angiosarcoma, immunohistochemistry

### 1. Introduction

The epithelioid angiosarcoma (EA) originating from bone is extremely rare in the primary bone tumors; a majority of them originate in the deep soft tissues including adrenal gland, thyroid, skin, and bone. Due to the diversity of the occurrence site, the clinical manifestations are not identical. EA are prone to locoregional recurrence, nodal and distant metastases, and have notoriously poor prognoses.<sup>[1]</sup> Due to its epithelioid histological features, the diagnosis of EA is putatively considered as epithelium-originated tumors, which has a higher incidence,

while the bone-originated EA is rather rare.<sup>[2]</sup> The data from clinical statistics state that EA was predominantly diagnosed in aged males. In addition, malignant tumors with distinct vascular differentiation should be distinguished from lower aggressive vascular tumors. In our case, in the same site, the patient had other diseases decades ago. Because of the obvious secondary changes, the tumor tissue was highly differentiated, and imaging could not provide accurate diagnosis and valuable hints. Makes the diagnosis and treatment process complicated.

### 2. Case report

The study was approved by the biomedical ethics committee of Hefei No.2 People's Hospital and informed consent of the patients' family was obtained.

The patient is a 61-year-old Han race female. She visited our hospital on April 4, 2012, complaining of pain in the right hip for 1 month. Physical examination revealed shortening deformity in the right lower limb, 5 cm shortening as compared to the left lower limb. Right hip was slightly swollen, she suffered from local pressing pain and percussion pain (+), and a pulmonary surgery scar was visible. Past medical history revealed that at the age of 30 years, the patient had right hip arthrodesis because of right hip joint tuberculosis. First X-ray examination (Fig. 1A) showed a right hip fusion, swollen osteolytic bone destruction was found in the fusion area, cortical thinning, several incomplete bone crests were found inside the area, and no obvious hardened edge. CT image (Fig. 1B) revealed a slightly saccular fusion area, expansion of osteolytic osteolysis, cortical thinning, patchy high density and a few punctate calcifications inside the sac, and see divided into

Editor: N/A.

Funding: The study was supported by the Fifth Cycle of Medical Key Specialist Construction Funds of Hefei [grant no. 2016(256)]. Special thanks to the funding support of key disciplines and research projects.

The authors have no conflicts of interest to disclose.

Department of Pathology, The second people's hospital of Hefei, Hefei, Anhui, China.

\* Correspondence: Min Zhao, Department of Pathology, The second people's hospital of Hefei, Hefei 230011, Anhui, China (e-mail: martina82cn@163.com).

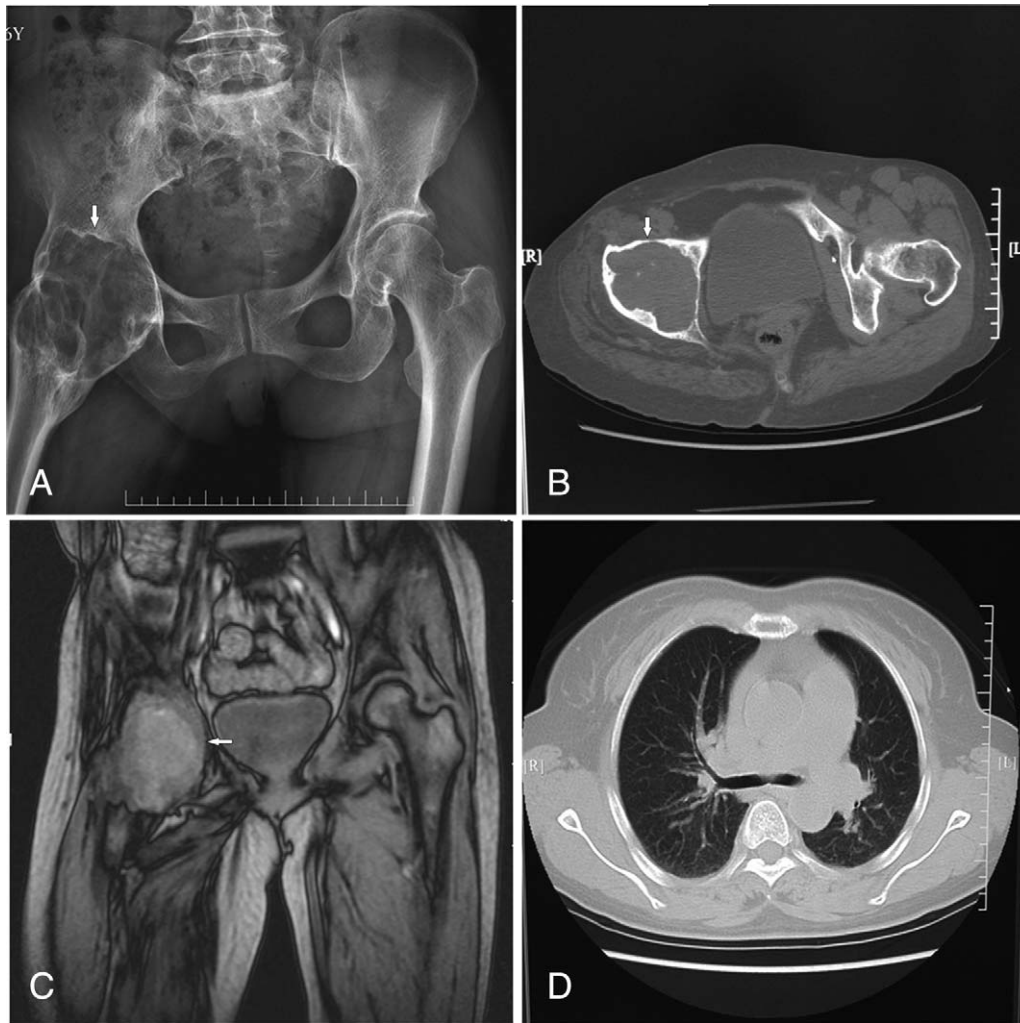
Copyright © 2018 the Author(s). Published by Wolters Kluwer Health, Inc. This is an open access article distributed under the terms of the Creative Commons Attribution-Non Commercial-No Derivatives License 4.0 (CCBY-NC-ND), where it is permissible to download and share the work provided it is properly cited. The work cannot be changed in any way or used commercially without permission from the journal.

Medicine (2018) 97:15(e0307)

Received: 25 December 2017 / Received in final form: 2 March 2018 /

Accepted: 12 March 2018

<http://dx.doi.org/10.1097/MD.000000000010307>

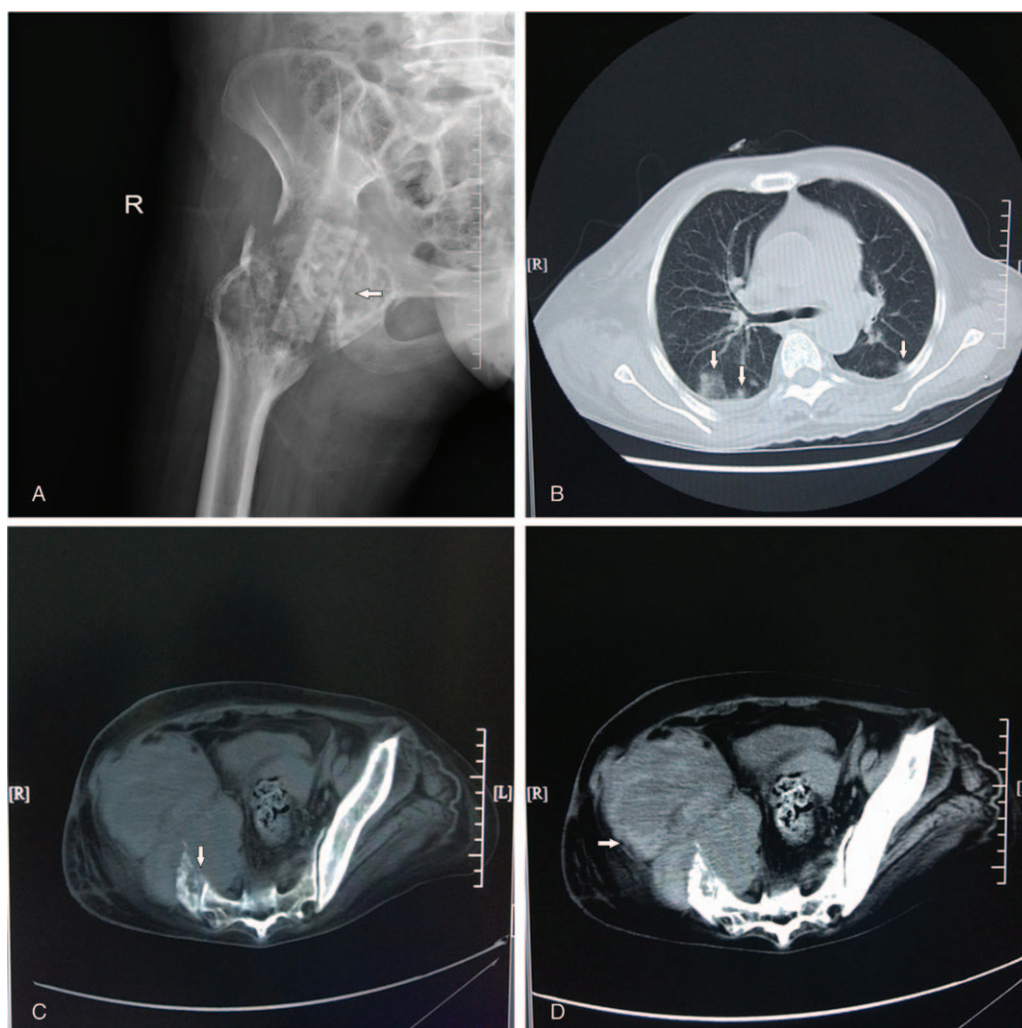


**Figure 1.** (A) X-ray before the first operation: right hip fusion, fusion area was swollen, osteolytic bone destruction, cortical thinning, many incomplete bone crests could be seen inside, no obvious hardening side was found. (B) Slightly cystic expansion osteolytic bone destruction appeared in the infundibulum area, the cortical was thinning, patchy, slightly high-density shadow, and a few punctate calcifications were seen inside the sac. (C) MRI before the first operation: right hip lesions showed expansion changes and the normal shape of the femoral head disappeared. The hip space narrowed, and the local bone destruction could be seen on the acetabular bone. (D) Before the first operation, the CT showed no obvious abnormalities in the lung examination.

multiroom, the room showed a low density shadow. A slightly hardened edge was noted around the lesions, and muscle atrophy was found around the hip joint. MRI (Fig. 1C) showed right hip lesions with expanded changes, lesions with equisignal or slightly lower signal on T1WI, centrally scattered or frequently occurring patchy and slightly high signal, the lesions exhibited a high signal on T2WI, whereas mixed uneven signal was found in the center. No obvious abnormality was detected in the chest CT examination (Fig. 1D). The preliminary clinical diagnosis revealed a space-occupying lesion in the right hip that might suffer from the aneurysmal bone cyst (ABC). A biopsy was performed on April 11, 2012, and tumor strike-off plus bone transplantation was carried out. During operation, bone expansion was found in the right hip joint infundibulum area, cystic-like changes were found after opening as well as a large number of bean-curd-like substances, and a layer of cyst wall was attached to the bone marrow. Then, scraping off the tissues inside the cavum medullare for the pathological test during surgery was conducted. An intraoperative frozen pathology suggested ABC, and thus, tuberculosis was excluded. Due to the clearance of the

lesions, a huge cavity was formed in the hip joint. A complete removal of the lesions and phase I bone graft surgery was concluded after combing the pathological results. The bone graft was taken from the left side of the patient's iliac bone together with some artificial bone, and the bone window was covered by the surrounding muscle. The first surgical examination sample was grayish yellow broken tissues observed by naked eyes; the size was approximately  $11\text{ cm} \times 2\text{ cm} \times 7.5\text{ cm}$  and partially cystic-like. Microscopically, the broken tissue appeared as a nonstructural substance with homogeneous red dye, and the capsule wall composed of fibrous connective tissue, rich in blood vessels without any bone or cartilage lesions. The postoperative pathology diagnosis considered ABC in the right hip. Phase I incision healing occurred during this treatment; no specific treatment was administered. The patient left the hospital on April 26, 2012, although was asked bed rest for 2 months, followed by a reexamination at the hospital.

One month postoperatively, the patient suffered from a sudden burst of pain in the right hip without any obvious inducement, following which, she revisited the hospital on May 19, 2012.



**Figure 2.** (A) X-ray display of 1 month after the operation: Pathological fractures on right hip fusion area, lesions were invasively expanded, part of the lesions were broken through the cortical bone area into surrounding soft tissue, a lump was formed, and the lesion border became blurred. (B) Shortly after the second operation, CT indicated that tumor metastasis could be seen in both lungs. (C and D) Shortly after the second operation, CT indicated a recurrence of the tumor in the hip, and the tumor was seen to disrupt the adjacent bone tissue.

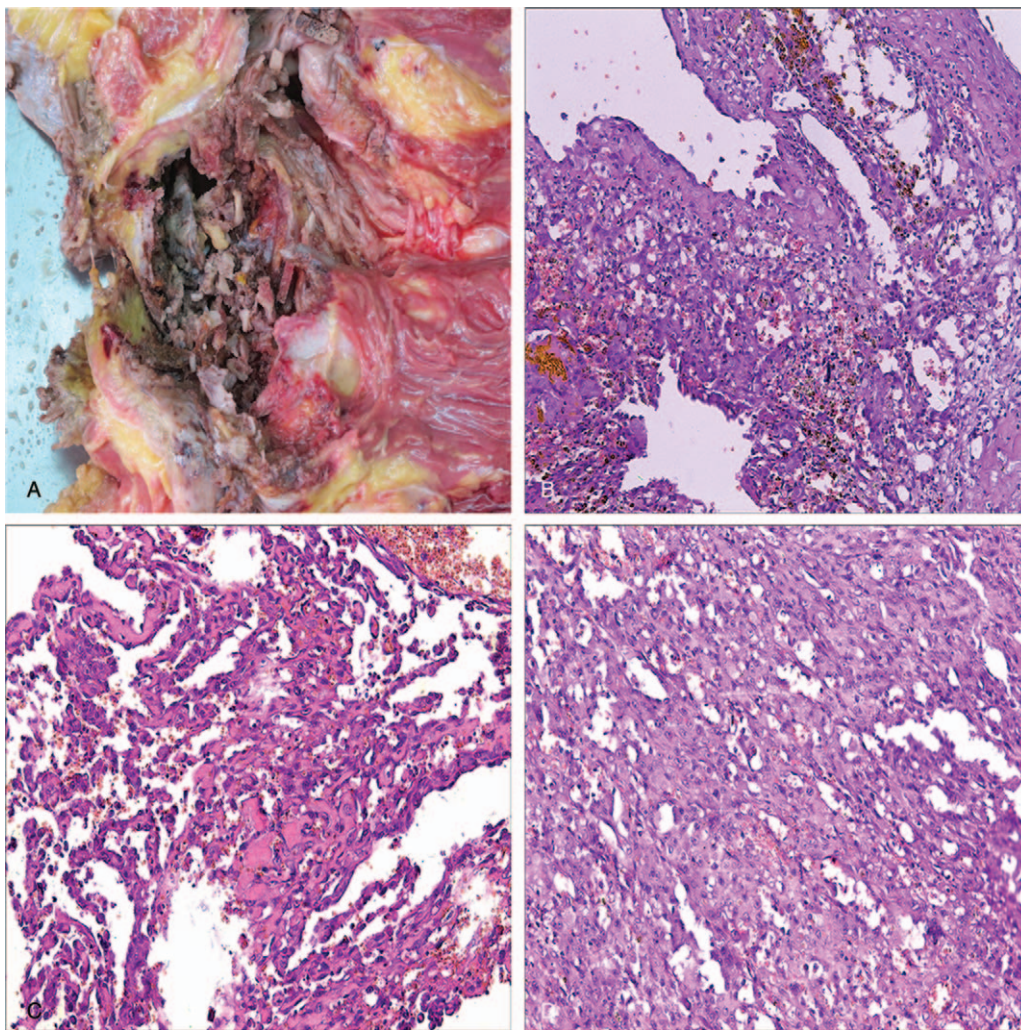
Review of X-ray (Fig. 2A): right hip fusion area exhibited a pathological fracture, the lesion had an invading extension, part of the cortical bone had broken through the bone cortex into the surrounding soft tissue, forming a lump, and the boundary of the lesion became fuzzy. Since the case was rapid-development, rare, and atypical, an expert group consultation of the HE tissue specimen results, after the first operation, was held among 3 pathology experts at the hospital. It was concluded that this tumor arises from blood vessels based on histological morphology and the latest condition. Since the specimen had no IHC results, they made 2 diagnostic opinions (well-differentiated angiosarcoma potential and angioendothelioma potential. However, the secondary ABC and vascular malformations cannot be completely excluded). Thus, the right pelvic amputation was conducted in June 2012. The tissue specimen in the second operation was excised from the lower limbs of the patients, 89.0cm long, the largest root diameter was approximately 21.5cm, and the size of the attached part of the hip was 20.5 cm × 13.0 cm × 9.0 cm. The operative incision of the root part was 19.0 cm long, and a 5.0 cm cystic cavity was observed in the femoral head and upper femur bone destruction that

contained a large number of broken bone tissues (Fig. 3A). The pathological results suggested that the vascular lumen-like structure was formed by single or multiple heterotypic cells, a few red blood cells were found in the lacuna, and a focal region-shaped cell formed a micropapillary structure (Fig. 3B–D). Immunohistochemistry (IHC) (Fig. 4A–F) revealed that the tumor cells were CD31-positive, vimentin-positive, CD34-negative, F VIII factor-negative, CK-negative, and EMA-negative. *Pathological diagnosis:* (right hip joint) EA with ABC changes. Due to the rapid progression of the disease, the patient was frail such that only symptomatic treatment could be administered.

*Postoperative follow-up:* August 2012, the patient died of local tumor recurrence and multiple lung metastases (Fig. 2B–D).

### 3. Discussion

Angiosarcoma is a rare type of soft tissue tumors, accounting for <2% of all soft tissue tumors.<sup>[1]</sup> EA is a subtype of angiosarcoma that can occur in different parts such as thyroid, skin, adrenal gland, and deep soft tissue. However, its origin as the bone EA is



**Figure 3.** (A) General specimens after second surgery: femoral head, bone destruction at the top of the femoral head, and 5.0 cm size cyst cavity was found containing a large number of bone tissues. (B–D) HE after second surgery (40 $\times$ , 100 $\times$ , 200 $\times$ ) images: the vascular lumen-like structure was formed by single or multiple heterogeneous cells, a few red blood cells was observed within the gap, the micropapillary structure was formed by regional focal cells.

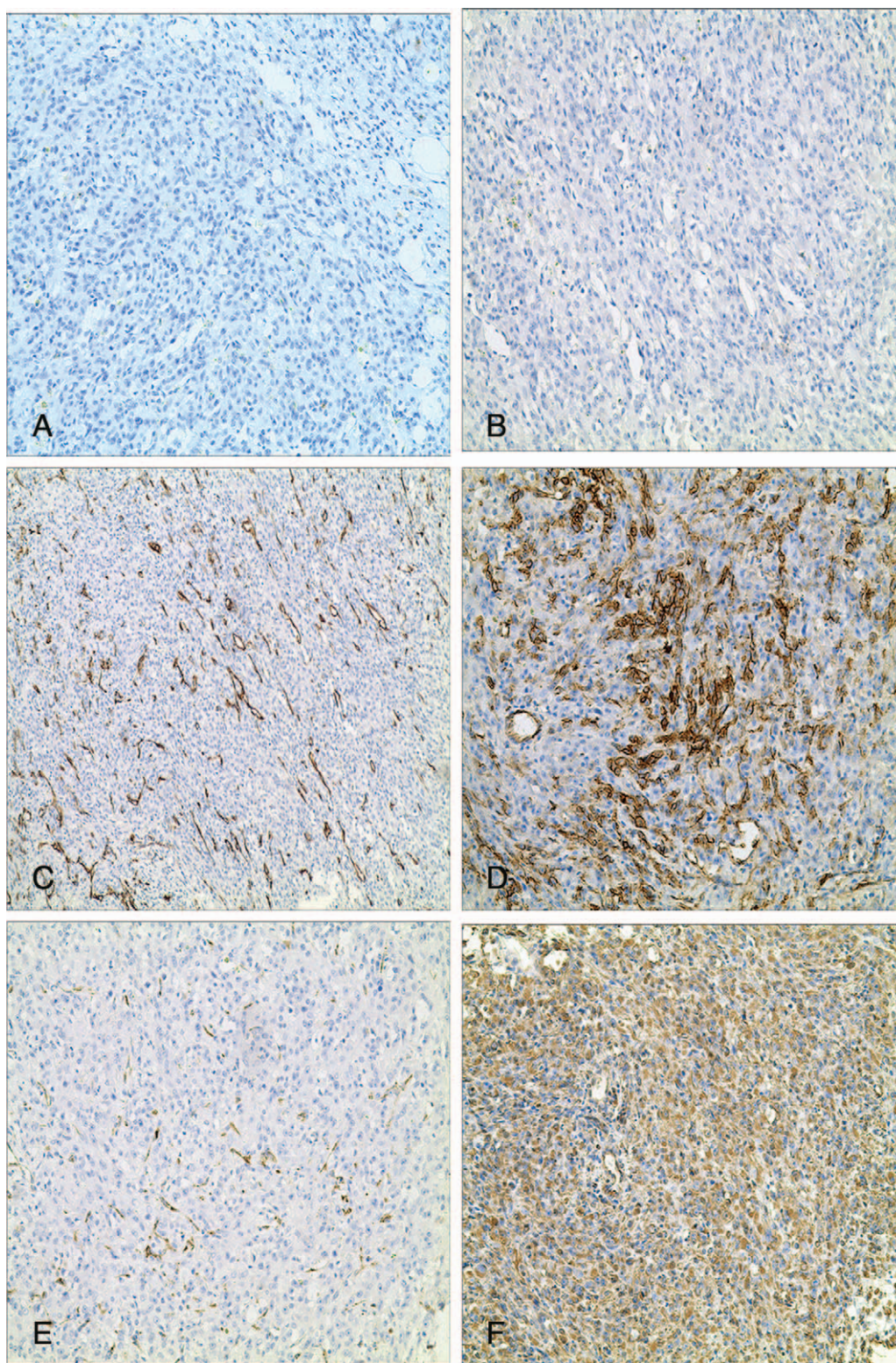
relatively rare and only accounts for <1% of the primary bone tumor.<sup>[3]</sup> Due to the diversity is the origin site, clinical manifestations are not identical. Because of the epithelial-like histological features, EA has a high propensity to be diagnosed as epithelial-originated tumors, which have a high incidence. We searched for almost 10 years on the primary bone of EA cases reported in the literature, review the information relative to complete 10 cases,<sup>[4–13]</sup> combined with our case summarized in Table 1.

The literature reported that primary EA of bone was prevalent in males. However, in this study, the ratio of male to female was proportional and did not show any significant gender differences. Although there have been reports of sick children, the disease occurred mainly in adults (22- to 76-year-old), and the median age was 61 years. The lesions could be solitary (n=10 cases) or focal (1 case), and occur in different parts of the body. More than half of the cases presented the disease in the lower limb (7 cases); however, there are other reports that the disease also occurred in the skull and mandible.

Due to the different sites of onset of the incidence and the high invasive characteristic of the tumor, a majority of the initial symptoms exhibited by patients included unalleviated pain, local

swelling, limitation of activity, and pathological fracture, all of which, did not show any specific symptoms and signs. The results showed that the incubation period of the multifocal tumor was longer; the solitary lesions had a higher degree of malignancy, rapid progression, easier to transform into distant metastasis.<sup>[14]</sup> According to the previous reports, the pathogenic factors that may cause this disease include radiation exposure and original bone disease (inflammation, necrosis, tumor, trauma, the etiology of the disease).<sup>[5,7]</sup> Some reports stated that only 11% to 17% of the patients had these etiologic factors, while most of the angiosarcomas occurred sporadically.<sup>[15,16]</sup> Of the cases listed in Table 1, only 1 patient was diagnosed of angiosarcoma in the primary site after 10 years of radiation therapy to the giant cell tumor. The current patient presented a history of hip tuberculosis 31 years ago; the rate of etiology was 18%, which was similar to that reported in the literature.

Since EA did not show a characteristic performance in imaging, it could not be diagnosed easily by conventional radiography; however, it may prompt the characteristics of lesions and multiple lesions, thereby assisting the diagnosis. The imaging examination mainly revealed the dissolution of bone lesions with bone expansion, the surrounding boundary was irregular and not



**Figure 4.** (A–F) Results of IHC: CK-negative, CD31-positive, FVIII-negative, VIM-positive, paraffin section, SP method, the antibody was obtained from the Fuzhou Maixinhe Luoshi Company.

clear, most of them did not have a periosteum reaction, and the deep lesions could be violated in the bone cortex and the surrounding soft tissue. Compared to the other vascular tumors, primary bone angiosarcoma may be prone to multiple lesions; and the diagnosis may only be suggestive. In the case of a patient

whose lesion developed slowly, due to limitations in initial imaging, only nonspecific soft tissue damage was observed. This also indicated that it could be easily mistaken for benign lesions from the radiological point of view. Especially, the honeycomb shape cysts, formed by expansive growth and osteolytic changes,

**Table 1****Eleven cases of bone-originated EA in literature with data.**

No.	Sex	Age	Region	First symptoms	IHC	Follow-up and results
1	Male	68	Left patella	Left knee joint has swollen and pain for 3 mo	F VIII+, CK+, CD31+, CD34+	Patient died after 3 mo posttreatment follow-up
2	Male	48	Left shoulder blade	Left shoulder pain with activity restriction for 5 mo	F VIII+, CK portion+, CD31+	No recurrence after 6 wk of follow-up
3	Female	70	Right calcaneal	Pain for 6 mo after right leg damage	F VIII focal+, CK+, CD31+	Death after treatment for 6 wk
4	Female	22	Left shoulder blade	Left shoulder pain for 1 wk	AE1/AE3-, CD31+, CD34+, CD68-, S100-	Unknown
5	Female	64	Left calcaneal first and multiple sites	Left heel pain with limitation of activity for 2 mo	F VIII+, CD31+, vimentin+, NSE+	Die because of pulmonary metastasis after follow-up for 4 mo
6	Male	76	L4	Sustained aggravation in lumbago for 5 mo	Vimentin, CD31+, CD34+, EMA-	No recurrence for 6 mo follow-up
7	Female	69	Right knee joint	Right knee pain for 6 mo	F VIII weak+, AE1/AE3+, CD31+, CD34-	Whole body transferred after 3 mo of treatment
8	Female	62	Right ilium	pain aggravated for 1 mo in sprain of waist hip	Fl-1+, CD31+, CD34+, CK+, vimentin+, EMA-	Unknown
9	Male	67	Right humerus	The pain and swelling of the original site at 10 y after radiotherapy of the giant cell tumor of the bone	F VIII+, CD31+, vimentin+	Recurrence after 1 y of operation, then chemotherapy was given and follow-up for 6 mo without recurrence
10	Male	62	Left tibia	Left leg pain and swelling 20 d	CD34+	Death after 1 mo of follow-up
11	Female	61	Right hip joint	Right hip discomfort and pain for 1 mo	F VIII-, CK-, CD31+, CD34-, EMA-	4 mo after the first visit, the patient died

IHC=immunohistochemistry.

with similar imaging findings as the ABC. In terms of imaging, it is not easy to distinguish from other diseases that cause osteolytic changes. Among the 10 cases reported in this paper, there are cases of misdiagnosis at the first diagnosis. Moreover, the patient in our case probably had bone giant cell tumor or ABC according to the first preoperative imaging diagnosis.

A histological biopsy is essential for the diagnosis of this disease. Degeneration, necrosis, hemorrhage, and fibrous wall-like structured were observed under light microscope, and weakly stained eosinophilic epithelioid cells could be seen inside the structure. The shape of the nuclei was round or oval, vacuoles were present in the cytoplasm, nucleoli were prominent, and some cells aggregated to form cracks or small tube-like structures, containing red blood cells. The segmentation of tumor cells with fibrous tissue could be seen in the tumor tissue. IHC plays an irreplaceable role in the current diagnosis of EA. CD31/CD34/F VIII and other vascular endothelial cell markers express differentially in different cases; CD31 has the highest sensitivity and specificity, with 90% positive rate in the diagnosis of angiosarcoma.<sup>[17]</sup> Among the 11 cases in this article, 10 cases were CD31-positive, agreed with the literature. Recently, FLI-1 has been reported as a new antibody with high vascular tumor sensitivity and specificity. FLI-1 is a new marker of benign and malignant vascular tumors with 94% sensitivity and 100% specificity that exceeds that of the conventional vascular markers CD31, CD34, and F VIII.<sup>[18]</sup> Despite that the histological tumor cells are similar to the epithelial cells, the epithelial cell markers (CK/EMA) are not expressed 100%; some cases show only focal expression. Both CK and EMA exhibited negative expression in the current case, and hence, we speculated that the positive expression of the epithelial markers was not essential for diagnosis. However, positive expression of CK is useful in differentiation of metastasis carcinomas. Furthermore, malignant tumors with distinctive vascular differentiation should be distinguished from lower aggressive vascular tumors. In this case, EA occurred in the original disease elsewhere in the patient, the tumor differentiation

was relatively high, and imageology could not provide a clear diagnosis. Therefore, the pathological diagnosis should be based on histological characteristics coupled with IHC.

EA has a low incidence and is often difficult to diagnose; it does not have specific diagnostic criteria in any from hematology to imageology. If the patient did not undergo pathological biopsy before the operation, occasionally, it could lead to misdiagnosis or the disease would be considered as lesions or benign hyperplastic diseases. Only in the case of patients with larger lesions, the diagnosis is easy for the invasive growth or distant metastasis. In the present case, the first specimen submitted was cystic, with a large number of red-colored similar structures observed under the microscope, small lumen-like structures separated by fibrous tissue were also seen, and the number of abnormal cells was not significant. Considering that there are few tissue components of diagnostic significance and that the possibility of secondary lesions is not taken into account. Owing to the high possibility ABC during the initial diagnosis, IHC was not considered after the first operation. This is also a reason for missed diagnosis. In the histological examination, bone angiosarcoma and ABC exhibited similarities, ABC was filled with cystic blood cavity lined with rich, fat endothelial-like cells, and good prognosis after treatment. In our cases, the patients' condition deteriorated rapidly, which was inconsistent with the disease progression in ABC. Angiosarcoma was considered as a serious event during the patients' second visit postdiagnosis. Subsequently, consultation with several experts in pathology and further IHC confirmed that the disease was diagnosed as well-differentiated EA. Depending on whether clear early lesions could be found in ABC, the condition was divided into 2 categories: primary and secondary. About 33% of the secondary lesions occurred after the occurrence of giant cell tumor of bone and osteoblastoma.<sup>[19]</sup> Especially, a distinct neoplastic lesion area was not observed in the tissue sections, but secondary lesions were rather significant. Therefore, these would mask the initial postoperative diagnosis of tumors.

#### 4. Conclusion

Bone-originated EA is a relatively rare and highly malignant tumor. Also, it has high metastasis and recurrence rate. Although the range of morbidity age is wide, the maximal occurrence is in 60-year-olds. Although treated with surgery, radiotherapy, and chemotherapy, the prognosis of the patient remains poor. Nearly half of the patients died within a short duration posttreatment after the first diagnosis. Either due to the disease or disease metastasis, the 5-year survival rate was 33%.<sup>[20]</sup> More than half of the patients among the 11 cases mentioned in this article presented recurrent metastasis or died within 1 year or in a short period after diagnosis and treatment. The prognostic factors may include age, whether the lesion is solitary or multifocal, tumor size, and the extent of surgery. In addition to microscopic features in typical cases, the diagnosis of EA requires an overall consideration and combination of clinical, radiological, and pathological aspects to avoid misdiagnosis and missed diagnosis.

#### Author contributions

**Data curation:** Jin Wang.

**Investigation:** Jin Wang, Min Zhao, Jin Huang, Lin Ang.

**Methodology:** Jin Wang, Min Zhao, Lin Ang, Li Zheng.

**Validation:** Jin Wang.

**Writing – original draft:** Jin Wang, Min Zhao.

**Writing – review & editing:** Jin Wang, Min Zhao, Jin Huang, Lin Ang, Li Zheng.

#### References

- [1] Buehler D, Stephanie RR, Moody JS, et al. Angiosarcoma outcomes and prognostic factors: a 25-year single institution experience. *Am J Clin Oncol* 2014;37:473–9.
- [2] Li Y, Zou X, Chang X, et al. Right femoral pathological fracture caused by primary bone epithelioid angiosarcoma: Case report. *Medicine (Baltimore)* 2017;96:e6951doi:10.1097/MD.0000000000006951.
- [3] Deshpande V, Rosenberg AE, O’Connell JX, et al. Epithelioid angiosarcoma of the bone: a series of 10 cases. *Am J Surg Pathol* 2003;27:709–16.
- [4] Burk J, Gerlach U, Baumann T, et al. Epithelioid angiosarcoma of the scapula. *In Vivo* 2010;24:783–6.
- [5] Ma YP, Su RG. Patellar epithelioid angiosarcoma of X-ray and pathological comparison (with a case report and literature review). *Chin J Radiol* 2000;34:618–20.
- [6] Mendeszoon MJ, Mendeszoon ERJr, Rasmussen S, et al. Epithelioid angiosarcoma of the talus. *J Foot Ankle Surg* 2011;50:87–92.
- [7] Xu J, Ma RF, Li D, et al. Epithelioid angiosarcoma of bone: a neoplasm with potential pitfalls in diagnosis. *Open J Orthop* 2012;8:80–4.
- [8] Yang Z, Tao H, Ye Z, et al. Multicentric epithelioid angiosarcoma of bone. *Orthopedics* 2012;35:e1293–6.
- [9] Lang J, Chen L, Chen B, et al. Epithelioid angiosarcoma of the spine: a case report of a rare bone tumor. *Oncol Lett* 2014;7:2170–4.
- [10] Sakamoto A, Takahashi Y, Oda Y, et al. Aggressive clinical course of epithelioid angiosarcoma in the femur: a case report. *World J Surg Oncol* 2014;12:281doi: 10.1186/1477-7819-12-281.
- [11] Chen M, Zhang W, Qu J, et al. Epithelioid angiosarcoma of the ilium: a case report. *Int J Clin Exp Pathol* 2014;7:9099–103.
- [12] Mittal S, Goswami C, Kanoria N, et al. Post-irradiation angiosarcoma of bone. *J Cancer Res Ther* 2007;3:96–9.
- [13] Kudva R, Perveen S, Janardhana A. Primary epithelioid angiosarcoma of bone: a case report with immunohistochemical study. *Indian J Pathol Microbiol* 2010;53:811–3.
- [14] Koch M, Nielsen GP, Yoon SS. Malignant tumors of blood vessels: angiosarcomas, hemangioendotheliomas, and hemangiopericytomas. *J Surg Oncol* 2008;97:321–9.
- [15] Abraham JA, Hornicek FJ, Kaufman AM, et al. Treatment and outcome of 82 patients with angiosarcoma. *Ann Surg Oncol* 2007;14:1953–67.
- [16] Sasaki R, Soejima T, Kishi K, et al. Angiosarcoma treated with radiotherapy: impact of tumor type and size on outcome. *Int J Radiat Oncol Biol Phys* 2002;52:1032–40.
- [17] Song JG, Shi YQ. *Soft Tissue Oncology*. 2012; Tianjin Science and Technology Translation Publishing Company, Tianjin, China:544.
- [18] Folpe AL, Chand EM, Goldblum JR, et al. Expression of Fli-1, a nuclear transcription factor, distinguishes vascular neoplasms from potential mimics. *Am J Surg Pathol* 2001;25:1061–6.
- [19] Lu ZH, Yao WW, Yang SX, et al. The imaging diagnosis of primary and secondary aneurysm bone cyst. *Chin J Med Imaging* 2008;14:144–9.
- [20] Verbeke SL, Bertoni F, Bacchini P, et al. Distinct histological features characterize primary angiosarcoma of bone. *Histopathology* 2011;58:254–64.