

# Inflammatory immune response in rabbits with *Staphylococcus aureus* biofilm-associated sinusitis

Xianmin Wu, MD, Yue Zhang, MM, Xiaoyun Chen, MB, Jun Chen, MB and Minghui Jia, MD 

**Background:** *Staphylococcus aureus* is the most commonly isolated bacterium from patients with surgically recalcitrant chronic rhinosinusitis (CRS). Understanding the immune responses to *S aureus* biofilms will provide insights into how the host response may be manipulated by therapeutic agents to improve the chances of successfully preventing and treating these infections. In this study, we investigated the inflammatory immune response in a rabbit model of *S aureus* biofilm-related sinusitis by analyzing the levels of some major inflammatory cytokines.

**Methods:** Eighteen New Zealand white rabbits were randomly divided into 3 groups: a blank-control group; a negative-control group; and a model group. Four weeks after the biofilm-associated sinusitis models were established, the sinus mucosa was harvested and examined using hematoxylin-eosin (H&E) staining, scanning electron microscopy (SEM), reverse transcription polymerase chain reaction (RT-PCR), and western blotting. The expression levels of inflammatory cytokines were analyzed statistically.

**Results:** Interleukin (IL)-1 $\beta$ , IL-8, and tumor necrosis factor (TNF)- $\alpha$  expression levels were significantly higher in the model group than in the blank-control group ( $p < 0.05$ ); mRNA levels were increased by 1600%, 230%,

and 130%, respectively, and the protein levels were increased by 180%, 100%, and 100%, respectively. In contrast, IL-4 and IL-5 mRNA levels were reduced by 44% and 70%, respectively, compared with the blank-control group ( $p < 0.05$ ).

**Conclusion:** *S aureus* biofilms in the rabbit maxillary sinus mucosa were associated with increased IL-1 $\beta$ , IL-8, and TNF- $\alpha$  expression, and decreased IL-4 and IL-5 expression.

© 2018 The Authors International Forum of Allergy & Rhinology, published by ARSAAOA, LLC.

This is an open access article under the terms of the Creative Commons Attribution-NonCommercial License, which permits use, distribution and reproduction in any medium, provided the original work is properly cited and is not used for commercial purposes.

## Key Words:

bacterial biofilm; chronic rhinosinusitis; cytokine; *Staphylococcus aureus*; inflammatory response

## How to Cite this Article:

Wu X, Zhang Y, Chen X, Chen J, Jia M, Inflammatory immune response in rabbits with *Staphylococcus aureus* biofilm-associated sinusitis. *Int Forum Allergy Rhinol.* 2018;8:1226–1232.

Bacterial biofilms are believed to be common causes of persistent infections and chronic inflammatory diseases that are difficult to cure.<sup>1,2</sup> In recent years, biofilms have been consistently identified from the nasal mucosa of patients with chronic rhinosinusitis (CRS), and have

been associated with more severe disease after reoperation and poorer outcomes after endoscopic sinus surgery.<sup>3,4</sup> Although bacterial biofilms have been implicated in recalcitrant CRS, little is known about the specific host immune response to bacterial biofilms in CRS.

*Staphylococcus aureus* is the most commonly isolated bacterium from patients with surgically recalcitrant CRS.<sup>5–7</sup> Some experts believe that studies evaluating therapeutic intervention in CRS should specifically target *S aureus* biofilms.<sup>8,9</sup> However, to our knowledge, few studies have examined the inflammatory responses to *S aureus* biofilms, and most of these have been conducted in vitro.<sup>10–12</sup> Therefore, additional studies are needed to advance our understanding of the crosstalk between *S aureus* biofilms and the mucosal host inflammatory response they elicit.

Department of Otolaryngology–Head and Neck Surgery, The First Affiliated Hospital of Wenzhou Medical University, Wenzhou, China

Correspondence to: Minghui Jia, MD, Department of Otorhinolaryngology–Head and Neck Surgery, The First Affiliated Hospital of Wenzhou Medical University, Nanbaixiang, Ouhai District, Wenzhou 325000, China; e-mail: entjmh@126.com

Funding sources for the study: Zhejiang Provincial Natural Science Foundation of China (LY17H130002).

Potential conflicts of interest: None disclosed.

Received: 8 April 2018; Revised: 21 May 2018; Accepted: 8 June 2018

DOI: 10.1002/alr.22175

View this article online at [wileyonlinelibrary.com](http://wileyonlinelibrary.com).

In our previous experiments, we created a rabbit model of *S aureus* biofilms and found that the biofilms existed stably on the maxillary sinus mucosa after 4 weeks of bacterial inoculation.<sup>13</sup> This model enables us to evaluate staphylococcal biofilms under in vivo conditions. In the present study, we aimed to determine the cytokine patterns associated with staphylococcal biofilms in a rabbit model in order to provide insights into the immune responses that characterize *S aureus* biofilm-associated CRS and, possibly, further clarify the pathogenic role of *S aureus* biofilms in this disease.

## Materials and methods

### Animals

Eighteen male New Zealand white rabbits (age, ~6 months; weight, 2.5–3.5 kg) were obtained from the Laboratory Animal Center at Fudan University (Shanghai, China). All experimental protocols were approved by the Animal Care and Use Committee of Fudan University, and the animal studies were carried out in accordance with the Ethical Guidelines for Animal Experiments established by Fudan University. The animals were acclimatized to the laboratory for 1 week and then randomly divided into 3 groups (6 rabbits per group): a blank-control group; a negative-control group; and a model group.

### Bacterial preparation

The biofilm-forming *S aureus* strain (clinical isolate Sa006, as determined by the traditional crystal violet biofilm assay)<sup>14,15</sup> was chosen owing to its relatively strong biofilm-formation capacity. The night before the modeling surgery, a single colony of Sa006 was inoculated in tryptic soy broth supplemented with 0.5% glucose (TSBg) and incubated overnight at 37°C with shaking. Then, the bacterial suspension was diluted 200-fold with TSBg to achieve a concentration of approximately  $1 \times 10^6$  colony-forming units/mL and kept on ice until further use.

### Modeling surgery and tissue harvesting

For the model group, the rabbit model of *S aureus* biofilm-associated sinusitis was established surgically, as previously described by our group.<sup>13</sup> Briefly, a laterally based periosteal flap was elevated from the midline to the right side, and then a small hole (1.5 mm in diameter) was drilled to enter the right maxillary sinus. A piece of compressed absorbable gelatin sponge was inserted into the maxillary sinus through the hole, and the sinus was inoculated with 0.5 mL of bacterial suspension. In the negative control groups, the animals only underwent maxillotomy and gelfoam placement, without bacterial inoculation. The rabbits in the blank-control group did not receive any treatment. The rabbits were caged individually in an air-conditioned room with dark-light cycles of 12 hours and free access to water and food.

Four weeks after the modeling surgery, the rabbits were euthanized by air injection through the ear vein. The maxillary sinuses were resected and opened with a pair of scissors. The sinus mucosa was carefully removed, washed with saline, and divided into 4 segments. Two of the segments were rapidly frozen with liquid nitrogen and subsequently used for reverse transcription polymerase chain reaction (RT-PCR) and western blot analyses. The third segment was placed in 2.5% glutaraldehyde for scanning electron microscopy (SEM) specimen preparation, and the remaining segment was placed in 4% paraformaldehyde for routine histologic examination by hematoxylin and eosin (H&E) staining.

### H&E specimen preparation and analysis

The mucosal specimens were fixed in 4% paraformaldehyde for 24 hours, paraffin-embedded, sectioned at 5- $\mu$ m intervals, stained with H&E, and analyzed with a light microscope (Nikon Eclipse 80i epifluorescence microscope; Nikon, Tokyo, Japan). Images were acquired with a CCD digital camera at 400 $\times$  magnification.

### SEM specimen preparation and analysis

The specimens were fixed in 2.5% glutaraldehyde for 24 hours at 4°C, rinsed 3 times with 1 $\times$  phosphate-buffered saline (PBS), fixed with 1% osmium tetroxide for 2 hours, rinsed 3 times with PBS again, and dehydrated through a graded ethanol series (50%, 70%, 90%, and 100%, for 15 minutes each). The dehydrated specimens were immersed in a mixture of 100% ethanol and isoamylacetate (2:1) for 15 minutes and then in pure isoamylacetate for another 15 minutes. All specimens were dried in a carbon dioxide critical point dryer, sputter-coated with gold, and examined by SEM (SU8010; Hitachi, Tokyo, Japan) at an accelerating voltage of 10 kV. Images were obtained at 2000 $\times$  magnification.

### Quantitative real-time PCR

Total RNA was isolated with an RNA isolation kit (DP431; Tiangen Biotech, Beijing, China). The concentration and quality of RNA were evaluated using ultraviolet absorbance at wavelengths of 260 and 280 nm ( $A_{260}/A_{280}$  ratio). Then, cDNA was synthesized from 1000 ng total RNA using the PrimeScript RT Master Mix Kit (DRR036A; Takara Biotechnology, Dalian, China) according to the manufacturer's instructions. An aliquot of cDNA equivalent to 100 ng total RNA was used to perform quantitative PCR. Real-time PCR assays were carried out on a real-time PCR system (ABI Prime 7500; Applied Biosystems, Foster City, CA) with the SYBR<sup>®</sup> Premix Ex Taq<sup>™</sup> II kit (DRR820A; Takara Biotechnology). The primers used in this study (Table 1) were designed with Primer Premier v5.0 software according to target gene sequences obtained from GenBank and were analyzed using BLAST on the NCBI website (<http://blast.ncbi.nlm.nih.gov/blast.cgi>). All primers were synthesized by Sangon Biotechnology

TABLE 1. Primer sequences

Gene	Primer sequence (5'-3')	Product size (bp)	GenBank ID
IL-1 $\beta$	F: GTC TTC CTA AAG CAA GCC TTA C	92	100008990
	R: GGG GTG TCA CAA TCT GTT TC		
IL-4	F: GAA GGA AGC CAG ACA GAC TA	80	100302454
	R: GAC GCT TTG AGT ATT TCT CTT G		
IL-5	F: CCC TGA CAC TGC TCT CAA CT	173	100358075
	R: GTT TTG GAA CAG ATT GTC CAT AG		
IL-8	F: GCA TAA AGA CAC ACT CCA CAC	131	100009129
	R: GTC CAG GCA GAG TTC TCT TC		
TNF- $\alpha$	F: CCT GTG CCT CCC TTC ACT TAT	157	100009088
	R: TTT CTC GCC ACT GAC CAG TAG		
GAPDH	F: TAA CTC TGG CAA AGT GGA TGT	92	100009074
	R: CGT GGG TGG AAT CAT ACT G		

IL = interleukin; F = forward; GAPDH = glyceraldehyde 3-phosphate dehydrogenase; R = reverse; TNF- $\alpha$  = tumor necrosis factor-alpha.

(Shanghai, China). The reaction was performed at 95°C for 30 seconds, followed by 40 cycles at 95°C for 5 seconds and 60°C for 34 seconds, and then ramped from 60°C to 95°C for 15 seconds, 60°C for 60 seconds, 95°C for 15 seconds, and finally 60°C for 15 seconds, to obtain the melting curve. The expression of the glyceraldehyde 3-phosphate dehydrogenase (GAPDH) housekeeping gene served as an internal control. Relative gene expression was quantified using the  $2^{-\Delta\Delta C_t}$  method.

### Western blot analysis

Frozen specimens (20 mg) of each sample were homogenized in 200  $\mu$ L of lysis buffer (radioimmunoprecipitation assay:phenylmethylsulfonylfluoride: 100:1; Beyotime, Shanghai, China). The supernatant containing total protein from the tissue homogenate was separated by centrifugation for 10 minutes at 12,000g. Protein concentrations were determined by the bicinchoninic acid assay (P0010; Beyotime). Samples containing equal amounts of proteins (40  $\mu$ g/sample) were separated using 15% sodium dodecylsulfate polyacrylamide gel electrophoresis and then electrophoretically transferred to polyvinylidene fluoride membranes. After being washed with a washing solution for western blotting (P0023C; Beyotime) and blocked with a blocking solution for western blotting (P0023B; Beyotime) for 1 hour at room temperature, the membranes were incubated overnight with the primary antibodies at 4°C. The following primary antibodies were used: interleukin (IL)-1 $\beta$  (1:100; orb101745; Biorbyt, Cambridge, UK); IL-8 (1:1000; ab34100; Abcam, Cambridge, UK); IL-10 (1:100; orb10892; Biorbyt); tumor necrosis factor (TNF)- $\alpha$  (1:500; MAB56701; R&D Systems, Minneapolis, MN); and GAPDH (1:2000; M20006; Abmart, Shanghai, China). After washing, the blots were incubated with the

following horseradish peroxidase-conjugated secondary antibodies: goat anti-rat immunoglobulin G (IgG; 1:3000; M21001L; Abmart) or goat anti-rabbit IgG (1:3000; M21002S; Abmart) at room temperature for 2 hours. After thorough washing, the membranes were detected with an electrochemiluminescence detection kit (Model 32132 ECL kit; Pierce Biotechnology, Rockford, IL) according to the manufacturer's instructions. The ratios of the relative gray values of IL-1 $\beta$ , IL-8, and TNF- $\alpha$  to that of GAPDH were taken to represent their activity, which was analyzed using Gel-Pro Analyzer version 4.0 software (Media Cybernetics, Rockville, MD).

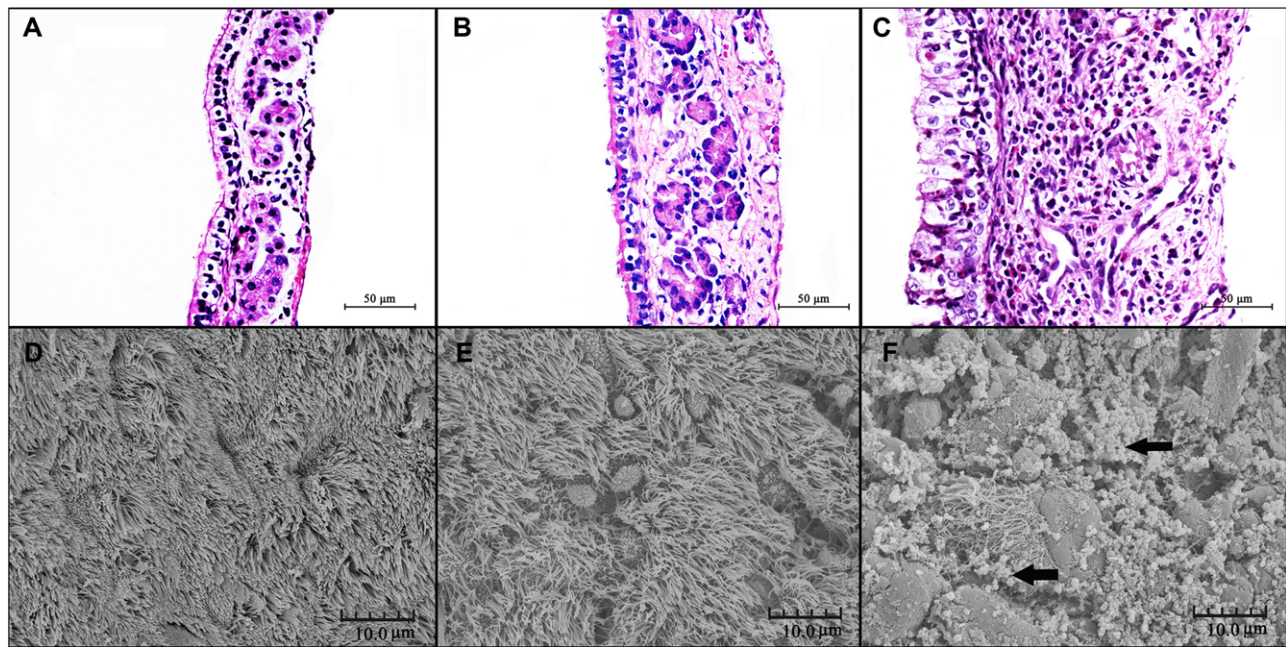
### Statistical analysis

All values are shown as mean  $\pm$  standard deviation. Data were first analyzed using one-way analysis of variance, followed by the Newman-Keuls multiple comparison test.  $p < 0.05$  was considered statistically significant. SPSS version 16.0 (SPSS, Inc, Chicago, IL) was used for all statistical analyses.

### Results

Overall, the animals tolerated the surgical procedures well. All rabbits in the model group developed sinusitis as confirmed by the observation of mucopurulent secretions in the maxillary sinus after the animals had been euthanized. In the negative-control group, 4 rabbits had a slightly runny nose during the first 2 weeks, but the gelatin sponge completely disappeared, and no pus was found in the maxillary sinus at 4 weeks after the modeling surgery.

H&E staining revealed that histologic structure and inflammatory cell infiltration were very different between the different groups. In the model group, the epithelial cells



**FIGURE 1.** H&E staining (A-C) (400 $\times$ ) and SEM images (D-F) (2000 $\times$ ) of the sinus mucosa. (A, D) Blank-control group, (B, E) negative-control group, and (C, F) model group. The black arrows show the bacterial biofilms. H&E = hematoxylin-eosin; SEM = scanning electron microscopy.

were swollen with large nuclei, and many were damaged or disintegrated. Massive inflammatory cell infiltration, including neutrophils, eosinophils, and lymphocytes, was observed in the subepithelial layer and lamina propria, and was accompanied by submucosal gland hypertrophy (Fig. 1C). In contrast to the model group, the negative-control group (Fig. 1B) showed similar histologic features to those of the blank-control group (Fig. 1A), in particular normal respiratory mucosa with columnar ciliated epithelium and no significant inflammatory cell infiltration in the subepithelial layer.

In the model group, SEM showed that biofilms were presented in all of the rabbits. The epithelium had been destroyed, and there were no normal cilia; only some spheroidal structures of encapsulated cilia remained (Fig. 1F). However, in the negative-control group, the integrity of the epithelium was maintained, and there was no evidence of bacterial biofilm formation (Fig. 1E). The mucosal surface was similar to that in the blank-control group, and appeared normal with intact cilia (Fig. 1D).

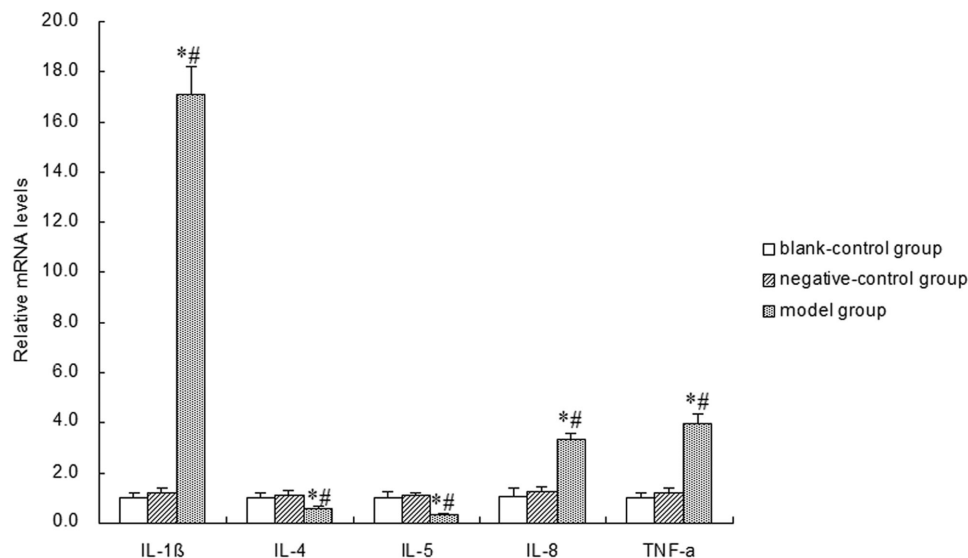
The mRNA expression levels of IL-1 $\beta$ , IL-4, IL-5, IL-8, and TNF- $\alpha$  in the sinus mucosa in the different groups are shown in Figure 2. The expression of IL-1 $\beta$ , IL-8, and TNF- $\alpha$  was significantly higher in the model group than in the blank- and negative-control groups, whereas expression of IL-4 and IL-5 was significantly lower in the model group than in the blank- and negative-control groups. There was no significant difference in the expression levels of these inflammatory factors between the blank- and negative-control groups.

The results of the western blot analysis are shown in Figure 3. The gray values of each band were quantified,

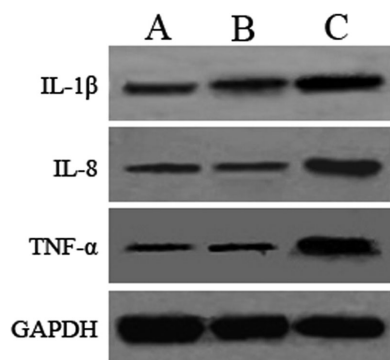
and the ratios of the relative gray values of IL-1 $\beta$ , IL-8, and TNF- $\alpha$  vs that of GAPDH were statistically analyzed. The analysis shows that IL-1 $\beta$ , IL-8, and TNF- $\alpha$  expression was significantly higher in the model group than in the blank- and negative-control groups (Fig. 4), which is consistent with mRNA expression levels of the corresponding cytokines. Compared with the blank-control group, the negative-control group exhibited slightly higher expression of IL-1 $\beta$ , IL-8, and TNF- $\alpha$ , although these differences were not statistically significant (Fig. 4).

## Discussion

CRS is now considered to be a cytokine-based inflammatory disease of the nose and paranasal sinuses.<sup>16,17</sup> However, the type of inflammatory changes in bacterial biofilm-related CRS remains controversial. For example, Hekiert et al found that biofilm-positive mucosa exhibited a robust pro-T-helper 1 (Th1) inflammatory profile as indicated by significantly elevations in interferon- $\gamma$ , granulocyte colony-stimulating factor, and macrophage inflammatory protein-1, and a nonsignificant elevation in IL-8.<sup>18</sup> However, Foreman et al reported that bacterial biofilm-related sinusitis mainly involved the increased expression of Th2-type inflammatory factors, such as IL-5 and eosinophil cationic protein.<sup>19</sup> Cantero et al found that initial *S aureus* biofilm infection of the sinonasal mucosa triggers cytokines associated with a Th1/Th17 polarizing immune response, in which IL-1 $\beta$ , IL-10, TNF, IL-17A, and interferon- $\gamma$  expression levels were upregulated.<sup>20</sup> The results of these studies were based on the evaluation of clinical specimens. Therefore, the differences between these studies can be



**FIGURE 2.** Quantitative RT-PCR assay of inflammatory cytokines in the different study groups. \* $p < 0.01$  compared with the blank-control group ( $p = 0.000$  for all), and # $p < 0.01$  compared with the negative-control group ( $p = 0.000$  for all). The mRNA expression levels of the inflammatory cytokines did not differ between the blank- and negative-control groups ( $p = 0.629, 0.209, 0.567, 0.323,$  and  $0.283$  for IL-1 $\beta$ , IL-4, IL-5, IL-8, and TNF- $\alpha$ , respectively). RT-PCR data were normalized to GAPDH mRNA levels. GAPDH = glyceraldehyde 3-phosphate dehydrogenase; IL = interleukin; RT-PCR = reverse transcription polymerase chain reaction; TNF- $\alpha$  = tumor necrosis- $\alpha$ .



**FIGURE 3.** Western blot analysis of various inflammatory cytokines in the different study groups. (A) Blank-control group, (B) negative-control group, and (C) model group.

explained by differences in factors such as patient constitution, immunologic properties, pathogen species, disease characteristics, and drug treatment history. In this study, we assessed multiple major inflammatory cytokines in a rabbit model of *S aureus* biofilm-related sinusitis, which minimized the effects of various confounding factors.

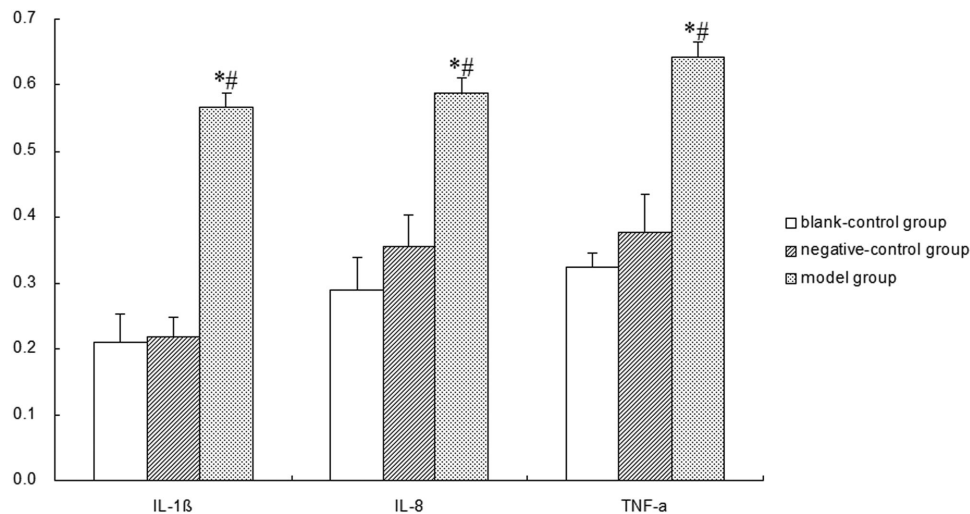
To rule out the effect of the gelatin sponge placed within the maxillary sinuses, a negative-control group was set up, in which just a gelatin sponge was placed within the maxillary sinus without the injection of pathogens. At 4 weeks after the modeling surgery, the sponge had been completely absorbed, and there was no evidence of inflammation in the sinus on SEM or H&E staining. In contrast, in the model group, the maxillary sinus was filled with purulent nasal discharge, and the mucosa was swollen. In addition, SEM

showed epithelial destruction and biofilm clusters, whereas H&E staining showed epithelial swelling, damage, and disintegration, along with massive inflammatory infiltration in the subepithelial layer and lamina propria.

Both the mRNA and protein expression of IL-1 $\beta$ , IL-8, and TNF- $\alpha$  were significantly higher in the model group than in the blank- or negative-control groups. In contrast, the mRNA expression of IL-4 and IL-5 was significantly lower in the model group (protein expression was not evaluated due to a lack of specific antibodies). Because the negative-control group excluded the effect of gelatin sponge implantation on the expression of inflammatory cytokines, we considered that the aforementioned changes in cytokine levels reflected the mucosal immune response to *S aureus* biofilms.

We believe that the increased expression of IL-1 $\beta$  and TNF- $\alpha$  may be directly related to planktonic *S aureus* infections. Studies have shown that *S aureus* infection can lead to a significant increase in IL-1 $\beta$  expression.<sup>21,22</sup> Staphylococcal enterotoxin A can induce the production of TNF- $\alpha$ .<sup>23</sup> Similarly, protein A of *S aureus* is also a potent inducer of TNF- $\alpha$  and IL-1.<sup>24</sup> Considering that the bacterial biofilm may act as a nidus for planktonic bacteria dispersing into the mucosa, the studies just described can very well explain our findings. Thus, we believe that the increased expression of IL-1 $\beta$  and TNF- $\alpha$  was mainly caused by planktonic bacteria dispersed from the *S aureus* biofilms.

Of the aforementioned inflammatory factors, IL-8 is a neutrophil chemoattractant, which can be secreted by nasal epithelial cells and nasal gland duct cells.<sup>25</sup> The sinonasal mucosal surfaces are lined by epithelial cells that form a barrier between potentially pathogenic microorganisms and



**FIGURE 4.** The relative gray values of inflammatory cytokines evaluated using western blot analysis. \* $p < 0.01$  compared with the blank-control group ( $p = 0.000$  for all), and # $p < 0.01$  compared with the negative-control group ( $p = 0.000$  for all). There were no significant differences in the expression levels of the inflammatory cytokines between the blank-control and negative-control groups ( $p = 0.845, 0.224,$  and  $0.072$  for IL-1 $\beta$ , IL-8, and TNF- $\alpha$ , respectively). IL = interleukin; TNF- $\alpha$  = tumor necrosis-alpha.

host tissues. The recognition of pathogens by the sinonasal epithelial cells is likely an important initial step in the inflammatory response, in which neutrophils play a crucial role when the invading organism is *S aureus*. Indeed, a hallmark of *S aureus* infection is the local accumulation of neutrophils. This characteristic is consistent with our findings that *S aureus* biofilms were associated with extensive destruction of the mucosal epithelial cells (as observed on SEM) as well as abundant neutrophil infiltration in the mucosa (as noted on H&E staining). Therefore, we suggest that the increased level of IL-8 may be a sensitive indicator of the development and maintenance of *S aureus* biofilms related to CRS.

Unfortunately, studies have indicated that increased expression of IL-1 $\beta$ , IL-8, and TNF- $\alpha$  not only fails to remove the biofilm but also causes tissue damage, converts acute inflammation to chronic inflammation, and facilitates the formation of *S aureus* biofilms. For example, although IL-1 $\beta$  and IL-8 can play a protective role in *S aureus* infection by recruiting neutrophils,<sup>21,22,25-27</sup> the neutrophils themselves are limited in their ability to clear biofilm-embedded *S aureus*, and the tissue damage resulting from the proinflammatory cytokines, reactive oxygen species, and lysosomal enzymes that are released upon neutrophil lysis and death can lead to a predisposition toward biofilm development.<sup>10</sup> Therefore, we believe that the increased expression of IL-1 $\beta$  and IL-8 may simply reflect the body's active immune response associated with *S aureus* biofilm infection, in which the recruited neutrophils help to control the bacterial burden and biofilm formation in the sinus mucosa. *S aureus* can induce epithelial cells to release TNF- $\alpha$ ,<sup>28</sup> which in turn activates leukocytes to prevent the spread of bacterial infections.<sup>29,30</sup> However, the overexpression of TNF- $\alpha$  plays a key role in tissue damage and epithelial cell necrosis.<sup>31</sup> In this study, the mRNA and protein levels of

TNF- $\alpha$  were significantly higher in the model group, which is consistent with the extensive destruction of mucosal epithelial cells. Therefore, we believe that increased TNF- $\alpha$  expression may be involved in promoting the destruction of the mucosal epithelium.

It was believed that Th2-type inflammatory factors have a crucial effect on the clearance of bacterial biofilms.<sup>32</sup> However, in this study, we found that expression of the Th2-type inflammatory factors (IL-4 and IL-5) was lower in the model group than in the control groups. The mechanism by which *S aureus* biofilms lead to the reduction of Th2-type inflammatory factors is not yet clear. We believe it may be related to the following reasons. First, *S aureus* biofilms increase the expression of Th1 inflammatory factors, such as IL-12 and interferon- $\gamma$ ,<sup>10</sup> and down-regulate Th2-type inflammatory responses by blocking the expression of IL-4.<sup>33</sup> Second, Th2-type inflammatory responses are antibody-mediated responses, which may be downregulated both by the early host cytokine response to *S aureus* infection and by the *S aureus* superantigens, capsule, and other toxins.<sup>34</sup> As Th2-type inflammatory factors play a crucial role in the removal of bacterial biofilms, we suspect that the formed bacterial biofilms may consume a large number of these inflammatory factors, but this view needs further research to be confirmed.

Taken together, our findings suggest that *S aureus* biofilms lead to a complex inflammatory response in the rabbit maxillary sinus mucosa, which is characterized by the increased expression of IL-1 $\beta$ , IL-8, and TNF- $\alpha$  and the decreased expression of IL-4 and IL-5. This skewing not only influences the propensity of *S aureus* infection to progress from an acute infection to a biofilm infection but also reflects, to a certain extent, the growth trend of the bacterial biofilms and the damage it inflicts on the mucosal epithelium.

## Acknowledgment

The authors thank Huayong Liu from the Institute of Medical Microbiology and Institutes of Biomedical Sciences, Shanghai Medical College, Fudan University, for helping with the bacteriologic experiments; Yang Wang from the Department of Human Anatomy, Histology and

Embryology, Shanghai Medical College, Fudan University, for preparing paraffin-embedded maxillary sinus tissue sections and slides; and Hongyang Gao from the Electron Microscopy Center, Shanghai Medical College, Fudan University, for helping with specimen preparation and photography.

## References

- Costerton JW, Stewart PS, Greenberg EP. Bacterial biofilms: a common cause of persistent infections. *Science*. 1999;284:1318–1322.
- Chicurel M. Bacterial biofilms and infections. *Slimebusters*. *Nature*. 2000;408:284–286.
- Bendouah Z, Barbeau J, Hamad WA, Desrosiers M. Biofilm formation by *Staphylococcus aureus* and *Pseudomonas aeruginosa* is associated with an unfavorable evolution after surgery for chronic sinusitis and nasal polyposis. *Otolaryngol Head Neck Surg*. 2006;134:991–996.
- Psaltis AJ, Weitzel EK, Ha KR, Wormald PJ. The effect of bacterial biofilms on post-sinus surgical outcomes. *Am J Rhinol*. 2008;22:1–6.
- Lin A, Busaba NY. *Staphylococcus aureus* and endoscopic sinus surgery. *Curr Opin Otolaryngol Head Neck Surg*. 2006;14:19–22.
- Bhattacharyya N, Gopal HV, Lee KH. Bacterial infection after endoscopic sinus surgery: a controlled prospective study. *Laryngoscope*. 2004;114:765–767.
- Jervis-Bardy J, Foreman A, Field J, Wormald PJ. Impaired mucosal healing and infection associated with *Staphylococcus aureus* after endoscopic sinus surgery. *Am J Rhinol Allergy*. 2009;23:549–552.
- Jervis-Bardy J, Foreman A, Bray S, et al. Methylglyoxal-infused honey mimics the anti-*Staphylococcus aureus* biofilm activity of manuka honey: potential implication in chronic rhinosinusitis. *Laryngoscope*. 2011;121:1104–1107.
- Singhal D, Foreman A, Jervis-Bardy J, Wormald PJ. *Staphylococcus aureus* biofilms: nemesis of endoscopic sinus surgery. *Laryngoscope*. 2011;121:1578–1583.
- Leid JG, Shirliff ME, Costerton JW, Stoodley P. Human leukocytes adhere to, penetrate, and respond to *Staphylococcus aureus* biofilms. *Infect Immun*. 2002;70:6339–6345.
- Gunther F, Wabnitz GH, Stroh P, et al. Host defence against *Staphylococcus aureus* biofilms infection: phagocytosis of biofilms by polymorphonuclear neutrophils (PMN). *Mol Immunol*. 2009;46:1805–1813.
- Guenther F, Stroh P, Wagner C, et al. Phagocytosis of staphylococci biofilms by polymorphonuclear neutrophils: *S. aureus* and *S. epidermidis* differ with regard to their susceptibility towards the host defense. *Int J Artif Organs*. 2009;32:565–573.
- Jia M, Chen Z, Du X, et al. A simple animal model of *Staphylococcus aureus* biofilm in sinusitis. *Am J Rhinol Allergy*. 2014;28:e115–e119.
- Flemming K, Klingenberg C, Cavanagh JP, et al. High in vitro antimicrobial activity of synthetic antimicrobial peptidomimetics against staphylococcal biofilms. *J Antimicrob Chemother*. 2009;63:136–145.
- Kim Y, Wang X, Ma Q, et al. Toxin-antitoxin systems in *Escherichia coli* influence biofilm formation through YjgK (TabA) and fimbriae. *J Bacteriol*. 2009;191:1258–1267.
- Meltzer EO, Hamilos DL, Hadley JA, et al. Rhinosinusitis: establishing definitions for clinical research and patient care. *J Allergy Clin Immunol*. 2004;114:155–212.
- Van Zele T, Claeys S, Gevaert P, et al. Differentiation of chronic sinus diseases by measurement of inflammatory mediators. *Allergy*. 2006;61:1280–1289.
- Hekiart AM, Kofonow JM, Doghramji L, et al. Biofilms correlate with TH1 inflammation in the sinonasal tissue of patients with chronic rhinosinusitis. *Otolaryngol Head Neck Surg*. 2009;141:448–453.
- Foreman A, Holtappels G, Psaltis AJ, et al. Adaptive immune responses in *Staphylococcus aureus* biofilm-associated chronic rhinosinusitis. *Allergy*. 2011;66:1449–1456.
- Cantero D, Cooksley C, Bassiouni A, et al. *Staphylococcus aureus* biofilms induce apoptosis and expression of interferon-gamma, interleukin-10, and interleukin-17A on human sinonasal explants. *Am J Rhinol Allergy*. 2015;29:23–28.
- Hultgren OH, Svensson L, Tarkowski A. Critical role of signaling through IL-1 receptor for development of arthritis and sepsis during *Staphylococcus aureus* infection. *J Immunol*. 2002;168:5207–5212.
- Miller LS, Pietras EM, Uricchio LH, et al. Inflammasome-mediated production of IL-1beta is required for neutrophil recruitment against *Staphylococcus aureus* in vivo. *J Immunol*. 2007;179:6933–6942.
- Dauwalder O, Thomas D, Ferry T, et al. Comparative inflammatory properties of staphylococcal superantigen enterotoxins SEA and SEG: implications for septic shock. *J Leukoc Biol*. 2006;80:753–758.
- Sinha P, Ghosh AK, Das T, et al. Protein A of *Staphylococcus aureus* evokes Th1 type response in mice. *Immunol Lett*. 1999;67:157–165.
- Rhyoo C, Sanders SP, Leopold DA, Proud D. Sinus mucosal IL-8 gene expression in chronic rhinosinusitis. *J Allergy Clin Immunol*. 1999;103:395–400.
- Kimura M, Matsukawa A, Ohkawara S, et al. Blocking of TNF-alpha and IL-1 inhibits leukocyte infiltration at early, but not at late stage of *S. aureus*-induced arthritis and the concomitant cartilage destruction in rabbits. *Clin Immunol Immunopathol*. 1997;82:18–25.
- Berenthal NM, Pribaz JR, Stavrakis AI, et al. Protective role of IL-1beta against post-arthroplasty *Staphylococcus aureus* infection. *J Orthop Res*. 2011;29:1621–1626.
- Moreillon C, Gras D, Hologne C, et al. Live *Staphylococcus aureus* and bacterial soluble factors induce different transcriptional responses in human airway cells. *Physiol Genomics*. 2005;20:244–255.
- Verdrengh M, Tarkowski A. Role of neutrophils in experimental septicemia and septic arthritis induced by *Staphylococcus aureus*. *Infect Immun*. 1997;65:2517–2521.
- Kielian T, Bearden ED, Baldwin AC, Esen N. IL-1 and TNF-alpha play a pivotal role in the host immune response in a mouse model of *Staphylococcus aureus*-induced experimental brain abscess. *J Neuropathol Exp Neurol*. 2004;63:381–396.
- Liang X, Ji Y. Involvement of alpha5beta1-integrin and TNF-alpha in *Staphylococcus aureus* alpha-toxin-induced death of epithelial cells. *Cell Microbiol*. 2007;9:1809–1821.
- Prabhakara R, Harro JM, Leid JG, et al. Suppression of the inflammatory immune response prevents the development of chronic biofilm infection due to methicillin-resistant *Staphylococcus aureus*. *Infect Immun*. 2011;79:5010–5018.
- Rao PS, Pallela VR, Vassileva-Belnikolovska D, et al. A receptor-specific peptide for imaging infection and inflammation. *Nucl Med Commun*. 2000;21:1063–1070.
- Prabhakara R, Harro JM, Leid JG, et al. Murine immune response to a chronic *Staphylococcus aureus* biofilm infection. *Infect Immun*. 2011;79:1789–1796.