

Multimodal temporary mechanically circulatory assistance for primary graft dysfunction after heart transplantation: a case report

Moritz B. Immohr , Artur Lichtenberg , Payam Akhyari *, and Udo Boeken 

Department of Cardiac Surgery, Medical Faculty and University Hospital Düsseldorf, Heinrich-Heine-University Düsseldorf, Moorenstraße 5, 40225 Düsseldorf, Germany

Received 8 July 2021; Revised 13 September 2021; first decision 6 August 2021; accepted 6 December 2021; online publish-ahead-of-print 31 January 2022

Background

Primary graft dysfunction (PGD) remains a serious complication after heart transplantation (HTx). Although there is no therapy available, veno-arterial extracorporeal membrane oxygenation (VA-ECMO) may be a bailout strategy in selected cases. Especially in patients with severe biventricular failure, chances of survival remain poor.

Case summary

Here, we report a case of a 56-year-old patient suffering from severe PGD after HTx with biventricular failure (ejection fraction < 20%) who was successfully bridged to recovery of the donor graft by temporary multimodal mechanically circulatory assistance by combining both, VA-ECMO and a microaxial pump (Impella[®], Abiomed, Inc., Danvers, MA, USA), a concept also referred as ECMELLA. During ECMELLA support, the patient experienced multiple severe thoracic bleeding complications with need for four re-thoracotomies and temporary open chest situation. Nevertheless, ventricular function recovered and the patient could be weaned from mechanical circulatory support after 12 days. During follow-up, the patient recovered and was successfully discharged. After the following rehabilitation, the patient now shows no persistent signs of heart failure with normal biventricular function of the cardiac graft.

Discussion

ECMELLA may offer a therapeutic option for patients with severe PGD after HTx. Special awareness and further studies addressing targeted anticoagulation strategies for patients on dual-mechanical support are needed to diminish the incidence of bleeding complications.

Keywords

Heart transplantation • Primary graft dysfunction • Extracorporeal life support • Microaxial pump • Impella • ECMELLA • Case report

ESC Curriculum

6.1 Symptoms and signs of heart failure • 7.3 Critically ill cardiac patient • 7.5 Cardiac surgery • 6.2 Heart failure with reduced ejection fraction

Learning points

- Primary graft dysfunction (PGD) remains a serious problem after heart transplantation (HTx) and often requires temporary mechanically circulatory assistance.
- Combining veno-arterial extracorporeal membrane oxygenation (VA-ECMO) and a microaxial pump (ECMELLA) offers an effective new approach for severe PGD with fulminant biventricular failure after HTx.
- ECMELLA can increase the advantages of both VA-ECMO and a microaxial pump alone but also the device-related complications.

* Corresponding author. Tel: +49 211 8118331, Fax: +49 211 8118333, Email: payam.akhyari@med.uni-duesseldorf.de

Handling Editor: Michel Pompeu Sá

Peer-reviewers: Eftychia Galiatsou; Henrik Fox; Marcelo Haertel Miglioranza

Compliance Editor: Brett Sydney Bernstein

Supplementary Material Editor: Mariame Chakir

© The Author(s) 2021. Published by Oxford University Press on behalf of the European Society of Cardiology.

This is an Open Access article distributed under the terms of the Creative Commons Attribution-NonCommercial License (<https://creativecommons.org/licenses/by-nc/4.0/>), which permits non-commercial re-use, distribution, and reproduction in any medium, provided the original work is properly cited. For commercial re-use, please contact journals.permissions@oup.com

Introduction

Primary graft dysfunction (PGD) remains a serious complication of patients undergoing orthotopic heart transplantation (HTx).^{1,2} By now, besides temporary extracorporeal mechanically circulatory support (MCS) by veno-arterial extracorporeal membrane oxygenation (VA-ECMO), therapy for severe PGD is quite limited.^{1,2} In addition, VA-ECMO support is associated with a variety of severe adverse events, especially bleeding, limb ischaemia, acute kidney injury, infections, as well as left ventricular volume overload and pulmonary oedema.³ In the recent years, percutaneous MCS by microaxial pumps (e.g. Impella[®], Abiomed, Inc., Danvers, MA, USA) has been used frequently.⁴ However, a high number of device-related complications have been reported with bleeding, deployment or retrieval issues, and vascular complications being the most common.⁴ A current study by Amin *et al.*⁵ even reported an association between the usage of microaxial pumps during percutaneous coronary intervention and increased adverse events and costs. In addition, implantation of microaxial pumps is limited in patients with biventricular failure, left ventricular thrombus, and mechanical aortic valve prosthesis.⁶ Nevertheless, combining of a percutaneous microaxial pump with VA-ECMO for left ventricular unloading has become more and more popular, a concept coined ECMELLA (*Figure 1*).⁷ However, by now, the ECMELLA concept is only a single case strategy and not an established therapy. Although ECMELLA offers the advantage of adequate left ventricular unloading without the need of a central left atrial venting catheter, it may increase some of the above mentioned complications of VA-ECMO support, especially bleeding complications and haemolysis.^{7,8} While

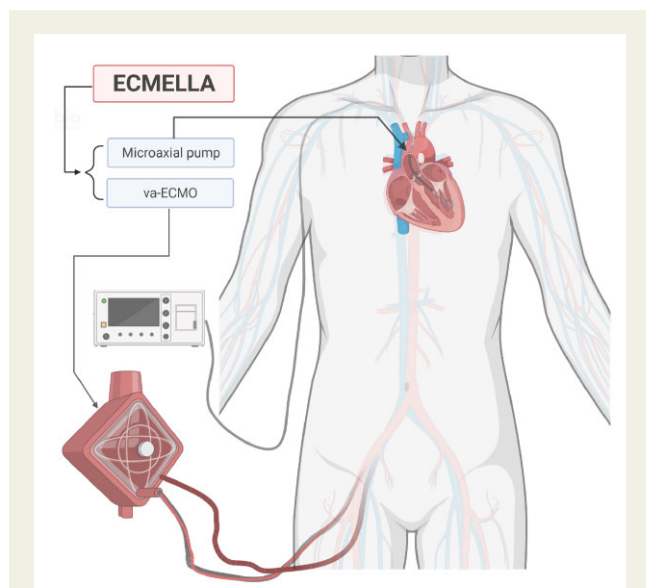


Figure 1 Schematic illustration of the temporary mechanical circulatory support of the patient. The combination of a microaxial pump and veno-arterial extracorporeal membrane oxygenation is also referred as ECMELLA. Impella 5.0[®] (Abiomed, Inc., Danvers, MA, USA) was implanted via the right subclavian artery and veno-arterial extracorporeal life support via the right femoral vessels.

ECMELLA has gained popularity for therapy-refractory cardiogenic shock as well as postcardiotomy syndrome, it is still new in the field of severe PGD after HTx.

Here, we report a patient suffering from severe PGD after HTx successfully bridged by temporary multimodal mechanically assistance by ECMELLA.

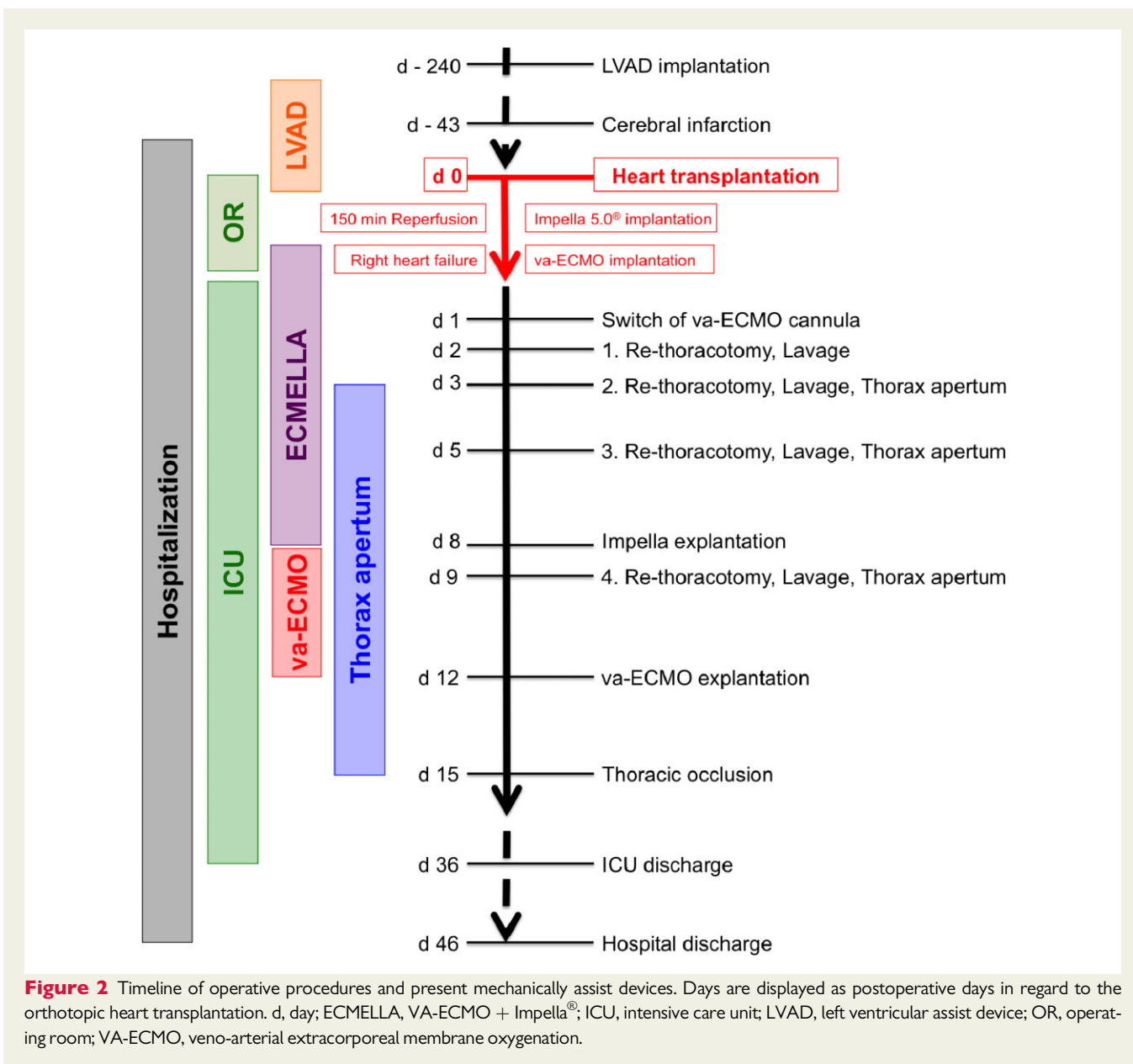
Case presentation

A 56-year-old male patient with end-stage ischaemic cardiomyopathy, chronic kidney disease, chronic obstructive pulmonary disease, type 2 diabetes mellitus, and dyslipidaemia developed cerebral infarction due to thrombosis of the right medial cerebral artery approximately one and a half year after minimally invasive left ventricular assist device (LVAD) implantation (HeartWare HVAD[®], Medtronic plc, Dublin, Ireland). The patient successfully underwent mechanical thrombectomy and was listed for HTx with high urgency waiting list status. Another 43 days later, the patient was finally allocated to a suitable donor organ of a 22-year-old donor and underwent HTx in orthotopic bicaval technique. Although reported donor ejection fraction was good (>60%) and transport time (157 min) and warm ischaemia (49 min) were not prolonged, the patient developed immediately PGD with biventricular failure and severe impairment of left ventricular function (ejection fraction <20%). After a total reperfusion time of more than 150 min, we decided to implant a microaxial pump (Impella 5.0[®], Abiomed, Inc., Danvers, MA, USA) via a vascular prosthesis connected to the right subclavian artery for temporary isolated left ventricular mechanically assistance. However, due to concomitant right heart failure, additional right ventricular assistance was inevitable. Thus, we upgraded the running Impella[®] system to ECMELLA configuration by additional VA-ECMO implantation via a second arm of the already implanted vascular prosthesis of the right subclavian artery and the right femoral vein as described before by Eulert-Grehn *et al.*⁹ Afterwards, the patient was stabilized and transferred to the intensive care unit.

In the following, the patient developed progressive hyperaemia of the right arm with consecutive therapy-refractory lactataemia. At the first postoperative day, we therefore switched the arterial cannula of the VA-ECMO to the right femoral artery. Unfortunately, the patient suffered from multiple bleeding complications during ECMELLA support with need for a total of four thoracic revisions and temporary thorax apertum due to repetitive haemothoraces. Finally, ventricular function recovered after levosimendan therapy and the Impella[®] device was explanted eight days after HTx. Due to on-going right ventricular dysfunction, we maintained VA-ECMO support for additional 4 days. We explanted VA-ECMO on the 15th postoperative day achieving thoracic occlusion. A detailed timeline of all operative procedures is displayed in *Figure 2*.

Approximately one month after the HTx, the patient was transferred to the intermediate care unit and at the 46th postoperative day, the patient was finally discharged to a rehabilitation clinic. At discharge, echocardiography confirmed full biventricular recovery with left ventricular ejection fraction at 53% and apparently good right ventricular function without any valve pathologies.

At follow-up, two months following HTx the patient presented fully recovered without any heart failure symptoms or chronic kidney



injury. He reported regular physical exercise without any dyspnoea and echocardiography revealed normal cardiac function.

Discussion

Here, we report a case of PGD after HTx with successful multimodal circulatory assistance by temporary ECMELLA support, a concept that to our best knowledge has not yet been reported in this particular context in the literature. Our case summarizes the possibilities of successful MCS therapy for PGD by combining both VA-ECMO as well as Impella® in order to combine the advantages of both therapy

strategies; however, we also indicated a severe amplification of the known adverse effects of both therapies.

Although survival after HTx has continuously improved in the recent years, PGD still remains a main cause for early graft failure and is associated with increased morbidity and mortality.¹ Incidence of PGD after HTx varies in the literature from less than five to more than 30%.^{1,2} Following the criteria of the International Society for Heart and Lung Transplantation (ISHLT), our reported patient suffered from both severe right as well as left ventricular PGD.² There are multiple known risk factors for the development of PGD in the literature with multiple trauma of the deceased donor (car accident) and concomitant non-cardiac organ donation, certain weight mismatch as well as previous thoracic surgery and LVAD support of the recipient being present here.²

Per definition by the ISHLT, treatment of severe PGD after HTx consists of temporary mechanically circulatory assistance, often by VA-ECMO support.² In general, ECMO support duration averages of about 5 days, which is much shorter than in our reported case.¹⁰ Prolonged ECMO support is associated with multiple complications such as bleeding, limb ischaemia, stroke, acute kidney injury, and infections.^{3,10} Without any doubt, bleeding complications are the most common ones observed, reported in more than one of every three patients, which was also the main device related-complication in our patient.^{3,10}

In ECMO patients with severe biventricular failure and loss of cardiac output, left ventricular overload with need for therapeutic venting in order to prevent ventricular distension and pulmonary oedema is commonly observed.^{7,8} In contrast to conventional surgical venting by central left atrial or pulmonary vein catheter, implantation of Impella[®] for ECMELLA support can be performed without thoracic cannulas.^{7,8} In addition, Impella[®] can assist the left ventricle as part of a staged weaning concept.^{7,8,11} As a consequence, Pappalardo *et al.*⁷ described significantly increased weaning rates as well as decreased in-hospital mortality for ECMELLA compared with VA-ECMO in patients with cardiogenic shock. However, simultaneously ECMO support duration as well as haemolysis and acute kidney injury requiring haemodialysis were also significantly increased in the ECMELLA cohort compared to stand-alone VA-ECMO.⁷ Furthermore, major bleeding complications were increased by about 30% in the ECMELLA group.⁷ These findings are also underlined by Castro *et al.*¹¹ who reported significantly increased blood transfusions in ECMELLA patients compared to stand-alone Impella[®] therapy. These data are congruent with our reported case, as we observed profound bleeding complications with multiple haematothoraces regardless of comprehensive haemostasiological therapy and an advanced patient blood management programme.

Conclusion

Multimodal temporary MCS by combining both VA-ECMO and Impella[®] to a so-called ECMELLA configuration can offer a new approach for patients suffering from severe PGD with fulminant biventricular failure after HTx. We were not only able to successfully wean the patient after 12 days of MCS therapy, but more important, the patient's ventricular as well as kidney function fully recovered. Although the reported patient did not experience any persistent impairments, during ECMELLA support we struggled with multiple severe bleeding complications.

Lead author biography



Moritz B. Immohr, MD, graduated from the Heinrich-Heine-University Düsseldorf in 2018 and is now a resident in the University's Department of Cardiac Surgery. He focuses on congestive heart failure, mechanically circulatory support, and heart transplantation.

Supplementary material

Supplementary material is available at *European Heart Journal - Case Reports* online.

Acknowledgements

The authors thank the whole medical staff of the Departments of Cardiac Surgery, Cardiology, Pulmonology and Vascular Medicine for their continuous effort devoted to the treatment of advanced heart failure. *Figure 1* was created with BioRender.com.

Slide sets: A fully edited slide set detailing this case and suitable for local presentation is available online as Supplementary data.

Consent: The authors confirm that written consent for submission and publication of this case report including images and associated text has been obtained from the patient in line with COPE guidance.

Conflict of interest: None declared.

Funding: None declared.

References

1. Singh SSA, Dalzell JR, Berry C, Al-Attar N. Primary graft dysfunction after heart transplantation: a thorn amongst the roses. *Heart Fail Rev* 2019;**24**: 805–820.
2. Kobashigawa J, Zuckermann A, Macdonald P, LePrince P, Esmailian F, Luu M *et al.*; Consensus Conference participants. Report from a consensus conference on primary graft dysfunction after cardiac transplantation. *J Heart Lung Transplant* 2014;**33**:327–340.
3. Thiagarajan RR, Barbaro RP, Rycus PT, McMullan DM, Conrad SA, Fortenberry JD *et al.*; ELSO member centers. Extracorporeal Life Support Organization Registry International Report 2016. *ASAIO J* 2017;**63**:60–67.
4. Philipson DJ, Cohen DJ, Fonarow GC, Ziaeian B. Analysis of adverse events related to Impella usage (from the Manufacturer and User Facility Device Experience and National Inpatient Sample Databases). *Am J Cardiol* 2021;**140**: 91–94.

5. Amin AP, Spertus JA, Curtis JP, Desai N, Masoudi FA, Bach RG et al. The evolving landscape of Impella use in the United States among patients undergoing percutaneous coronary intervention with mechanical circulatory support. *Circulation* 2020;**141**:273–284.
6. Schäfer A, Werner N, Westenfeld R, Möller JE, Schulze PC, Karatolios K et al. Clinical scenarios for use of transvalvular microaxial pumps in acute heart failure and cardiogenic shock—a European experienced users working group opinion. *Int J Cardiol* 2019;**291**:96–104.
7. Pappalardo F, Schulte C, Pieri M, Schrage B, Contri R, Soeffker G et al. Concomitant implantation of Impella® on top of veno-arterial extracorporeal membrane oxygenation may improve survival of patients with cardiogenic shock. *Eur J Heart Fail* 2017;**19**:404–412.
8. Tongers J, Sieweke JT, Kühn C, Napp LC, Flierl U, Röntgen P et al. Early escalation of mechanical circulatory support stabilizes and potentially rescues patients in refractory cardiogenic shock. *Circ Heart Fail* 2020;**13**:e005853.
9. Eulert-Grehn JJ, Starck C, Kempfert J, Falk V, Potapov E. ECMELLA 2.0: single arterial access technique for a staged approach in cardiogenic shock. *Ann Thorac Surg* 2021;**111**:e135–e137.
10. DeRoo SC, Takayama H, Nemeth S, Garan AR, Kurlansky P, Restaino S et al. Extracorporeal membrane oxygenation for primary graft dysfunction after heart transplant. *J Thorac Cardiovasc Surg* 2019;**158**:1576–1584.e3.
11. Castro L, Zipfel S, Braunsteiner J, Schaefer A, Sill B, Söffker G et al. Switching to Impella 5.0 decreases need for transfusion in patients undergoing temporary mechanical circulatory support. *J Crit Care* 2020;**57**:253–258.