

Elevation of serum surfactant protein-A with exacerbation in canine eosinophilic pneumonia

Katsuhito SONE^{1,2)}, Hideo AKIYOSHI^{1)*}, Akiyoshi HAYASHI¹⁾ and Fumihito OHASHI¹⁾

¹⁾Department of Veterinary Clinical Sciences, Graduate School of Life and Environmental Sciences, Osaka Prefecture University, 1-58 Rinku-ohrai-kita, Izumisano, Osaka 598-8531, Japan

²⁾Okayama Animal Medical Center Hospital, 456-1 Nishiichi, Minami-ku, Okayama, Okayama 700-0953, Japan

(Received 6 December 2014/Accepted 7 August 2015/Published online in J-STAGE 21 August 2015)

ABSTRACT. A 7-year-old female spayed Labrador Retriever was admitted to our hospital, because of cough with sputum. She was diagnosed as having canine eosinophilic pneumonia (CEP) based on blood eosinophilia, bronchial pattern and infiltrative shadow observed on thoracic radiography, bronchiolar obstruction and air-space consolidation predominantly affecting the right caudal lung lobe, as revealed by computed tomography (CT), predominant eosinophils in CT-guided fine needle aspiration and the clinical course. She exhibited a good response to steroid therapy, and the cough disappeared. The serum surfactant protein (SP)-A level increased with the aggravated symptom and decreased markedly with improvement compared with the C-reactive protein level and the number of eosinophils. We propose that serum SP-A level is a good biomarker in CEP.

KEY WORDS: canine, eosinophilic pneumonia, surfactant protein-A

doi: 10.1292/jvms.14-0643; *J. Vet. Med. Sci.* 78(1): 143–146, 2016

Canine eosinophilic pneumonia (CEP) is an interstitial lung disease that is characterized by eosinophilic infiltration of the terminal bronchioles, alveoli and blood vessels [6]. Peripheral blood eosinophilia is found in 50–70% of all cases, and time-dependent changes in the number of eosinophils may not correlate with disease activity [7, 16].

Pulmonary surfactant protein (SP)-A is a glycoprotein that plays an important role in natural immunity of the lungs [13]. It is a component of pulmonary surfactant, which is primarily synthesized and secreted by alveolar type II cells [23]. In human medicine, the blood SP-A primarily increases in interstitial lung disease and is indicated as a pulmonary-specific biomarker [21]. Time-dependent changes in serum SP-A levels have been studied as a potentially useful way to monitor the state of eosinophilic pneumonia, a type of interstitial pneumonia, in humans [9, 10].

In veterinary medicine, the blood SP-A level increases in pneumonopathies, such as canine aspiration pneumonia, primary lung tumor, blunt traumatic lung injury, diffuse panbronchitis and idiopathic pulmonary fibrosis, and measurement of SP-A has recently been useful in differentiating these from other diseases [20, 24]. However, there have been no reports in which the blood SP-A has been monitored over the course of the disease and the relationship between the SP-A level and disease activity. Herein, we present a case of canine eosinophilic pneumonia, in which serum SP-A levels

fluctuated with the disease condition. We propose that measuring serum SP-A is helpful for monitoring disease activity.

A 7-year-old female spayed Labrador Retriever, weighing 23.5 kg, was admitted to Okayama Animal Medical Center Hospital because of cough with clear sputum for the past week (Day 0), which continued for approximately 20 min once over 2 days. There was no medical history, and the dog had regularly received the prophylactic vaccine and heartworm prophylaxis. Physical examination on admission revealed a heart rate of 114 beats/min, respiratory rate of 36 breaths/min, temperature of 38.4°C and normal lung auscultation. Complete blood count showed hypereosinophilia of 2,524/ μ l (range, 100–750/ μ l). Blood microfilaria was negative. The plasma C-reactive protein (CRP) level (Laser CRP-2; ARROW MEDICAL Co., Ltd., Yokohama, Japan) was normal at 0 mg/dl (range, <1.0 mg/dl). Blood chemical examinations were within the reference range. Thoracic radiographs revealed a mild bronchial pattern throughout the lungs. The antigen test for heartworm disease and fecal examination were not conducted.

Based on these findings, we suspected chronic bronchial disease [11] and started treatment with aminophylline [4.3 mg/kg, per os (PO), bis in die (BID)] and tranexamic acid (10.6 mg/kg, PO, BID) without any steroid.

On Day 5, the dog revisited our hospital, because her cough had worsened and the sputum had turned from clear to yellow. Therefore, we added the antibiotic enrofloxacin [5.2 mg/kg, PO, semel in die (SID)] and switched from tranexamic acid to carprofen (2.1 mg/kg, PO, SID).

On Day 12, the dog was re-admitted, because her symptom worsened, and the sputum included blood. We hospitalized her in an oxygen cage, because she was mildly cyanotic. The blood oxygenation, i.e., blood gas analysis, was not measured. The number of eosinophils decreased to 1,932/ μ l, and the CRP level increased slightly to 2.0 mg/dl. On thoracic ra-

*CORRESPONDENCE TO: AKIYOSHI, H., Department of Veterinary Clinical Sciences, Graduate School of Life and Environmental Sciences, Osaka Prefecture University, 1-58 Rinku Ohrai Kita, Izumisano, Osaka 598-8531, Japan. e-mail: akiyoshi@vet.osakafu-u.ac.jp

©2016 The Japanese Society of Veterinary Science

This is an open-access article distributed under the terms of the Creative Commons Attribution Non-Commercial No Derivatives (by-nc-nd) License <<http://creativecommons.org/licenses/by-nc-nd/3.0/>>.

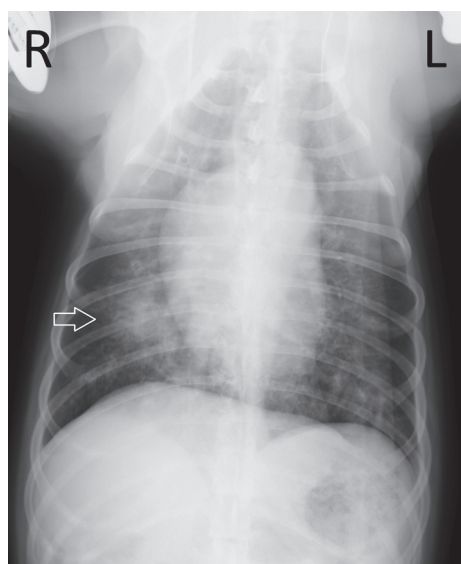


Fig. 1. A ventral-dorsal radiograph of the dog's thorax on Day 12. The radiograph shows a bronchial pattern throughout the lungs and an infiltrative shadow in the right caudal lung lobe (arrow).

diographs, the bronchial pattern was more severe than those obtained previously, and there was an infiltrative shadow in the right caudal lung lobe (Fig. 1).

Computed tomography (CT) (Pro Speed FII, GE Healthcare, Hino, Japan) performed on Day 13 identified thickened bronchial walls, and local and peripheral bronchiolar obstructions, which suggested bronchial disease with the accumulation of secretions in the peripheral bronchi. CT also identified infiltrative shadows with ground-glass opacity in the right caudal lung lobe just below the pleura (considered the main lesion) (Fig. 2), which suggested lung interstitial and parenchymal disease, including pneumonia, abscesses or bleeding. Therefore, we performed CT-guided fine needle aspiration (FNA) using a 24-gauge needle for the differential diagnosis on the main lesion and observed inflammatory cells, comprised mainly of eosinophils and alveolar cells (Fig. 3). Cytodiagnosis was made by the veterinary pathology specialists at Sumitomo Chemistry Techno Service Co., Ltd. Osaka, Japan. The possibility of overestimating eosinophils in FNA by aspirating the peripheral blood with hyper eosinophilia, compared with the ratio of red blood cell to eosinophil counts on the smear preparation of the lung specimen with the ratio of that in the peripheral blood was unlikely. Eosinophilic pneumonia was suspected on the basis of blood eosinophilia and the results of thoracic radiography, CT and CT-guided FNA.

Thus, we administered prednisolone (1 mg/kg, subcutaneously), and her symptoms improved considerably on Day 14. We then prescribed prednisolone (0.42 mg/kg, PO, SID) and discharged her. We continued enrofloxacin as an antimicrobial in case a bacterial infection had been missed.

The subsequent disease course was favorable, and the symptom was relieved on Day 19. Thereafter, we progres-

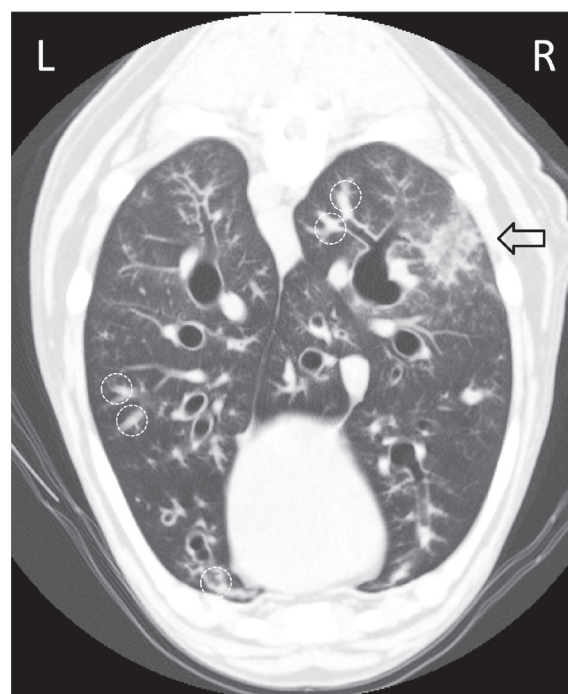


Fig. 2. Transverse CT thorax image at the level of the ninth thoracic vertebra on Day 13. The image shows thickened bronchial walls, local and peripheral bronchiolar obstructions (circle with the dotted line) and infiltrative shadows just below the pleura (arrow).

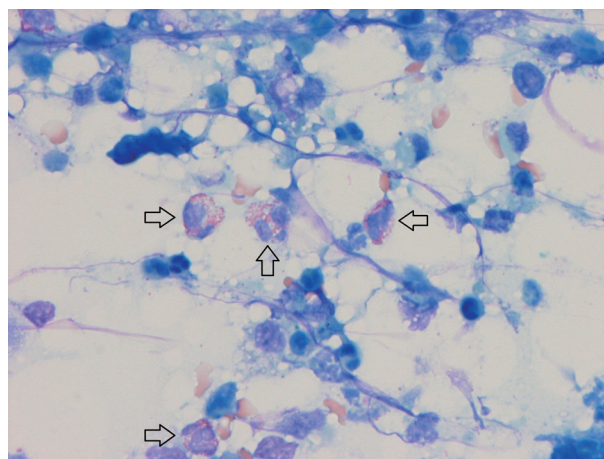


Fig. 3. Cytology from the CT-guided fine needle aspirate of the dog's main lung lesion on Day 13. Inflammatory cells, composed mainly of eosinophils (arrow), were observed. Giemsa stain, $\times 400$.

sively reduced the prednisolone dose. Enrofloxacin was discontinued on Day 26; prednisolone was discontinued on Day 54, because there was no symptom recurrence. However, cough recurred 1 week later (Day 61), and prednisolone therapy was re-initiated (0.21 mg/kg, PO, SID). Prednisolone was continued, and treatment was finally completed 16 months after the initial visit. The dog is currently healthy

with no recurrence 43 months later.

We measured serum SP-A levels during the treatment period with the consent of the pet owner (Fig. 4). Serum samples were retrieved from blood samples that were not used for medical examinations and were stored at -80°C . The frozen samples were transported to Osaka Prefecture University, wherein the individual measurements were performed. The serum SP-A levels were measured by sandwich enzyme-linked immunosorbent assay using rabbit anti-dog SP-A polyclonal antibody, as previously reported [19]. The serum SP-A level was 4.5 ng/ml (median concentration in healthy dogs, $<2.0\text{ ng/ml}$) [20] at the initial visit, but increased considerably to 35.5 ng/ml when the symptom became aggravated on Day 12. This level subsequently decreased as the symptom improved after starting steroid therapy, and was 1.4 ng/ml , the minimum value, on Day 26. However, its level increased slightly again to 6.9 ng/ml on Day 61, one week after withdrawal of the steroid, as we tapered the prednisolone dose.

The serum SP-A level was extremely high on the day when the symptom worsened considerably, and it changed with the degree of clinical manifestations and thoracic radiographs findings. The elevation of serum SP-A during the exacerbation could not be explained, because the pathological processes involved in canine eosinophilic pneumonia has only previously been investigated using bronchoalveolar lavage (BAL) cytology and histological examination of the bronchial mucosa; however, information regarding the lung parenchyma remains lacking [2, 14]. In human chronic eosinophilic pneumonia, resembling CEP [15], infiltration of eosinophils and lymphocytes occurs into the alveoli and at the alveolar epithelium with destruction of the basal membrane [12]. Eosinophils release granule proteins, oxygen radicals, lipid mediators and cytokines, which increase vascular permeability and/or cause leukocyte accumulation [18]. From the results showing that the BAL fluid and serum SP-A levels are both increased in human acute eosinophilic pneumonia, Daimon *et al.* reported the possibility that serum SP-A levels could be elevated due to hyperplasia of alveolar type II cells and by the increase in permeability of the alveoli into the circulation due to the destruction of the alveolar epithelium and endothelial cells [8].

Glucocorticoids are the mainstay drug for the management of CEP [5]. Steroids interfere with the transcription of several proinflammatory genes, i.e., interleukin (IL)-3, IL-4, IL-5, GM-CSF and various chemokines, which are necessary for eosinophil maturation, proliferation, chemoattraction, adhesion and migration, activation, and longevity [17]. Therefore, we speculated that lung injury by eosinophils improved with the steroids and the leakage of SP-A from the alveoli into the circulation decreased.

CRP is an acute phase protein that is primarily produced in the liver and is stimulated by inflammatory cytokines, primarily IL-6, which is mainly secreted by macrophages [1]. The CRP level is a useful marker of acute inflammation in both humans and dogs. In humans, it is routinely used as an index of inflammation in evaluating the effect of treatment, monitoring the progression of disease, and in determining

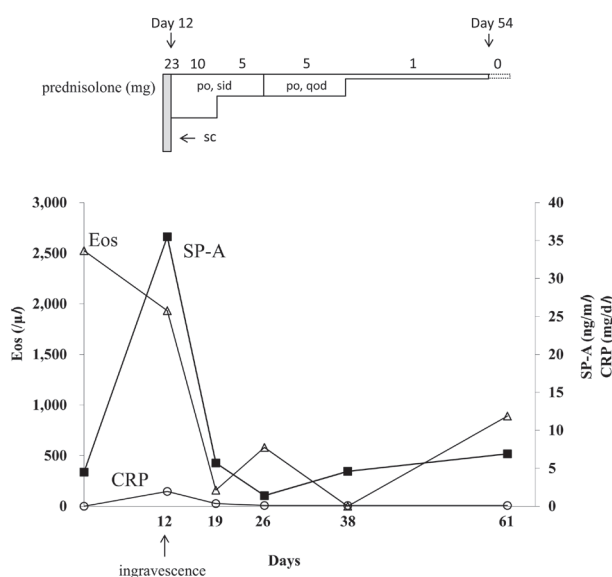


Fig. 4. Blood eosinophil counts (Eos: white triangle), serum SP-A levels (black square) and plasma C-reactive protein level (CRP: white circle) during the dog's clinical course. Po, per os; Sid, semel in die; Qod, quaque one die; Sc, subcutaneous.

the prognosis, but it is not pulmonary-specific [3]. In this case, the plasma CRP level increased slightly only on the day on which the acute symptom exacerbation occurred (Day 12); except for Day 12, the CRP level was within the reference range. Viitane *et al.* reported that dogs with eosinophilic pneumonia (EP) exhibited significantly lower CRP levels than dogs with bacterial pneumonia and that the CRP levels were similar between dogs with EP and healthy controls at the initial presentation, which is consistent with our findings [22]. Chihara *et al.* reported that serum CRP levels were lower in patients with eosinophilic pneumonia compared with patients with bacterial pneumonia because they may exhibit decreased IL-6 production or decreased liver reactivity for IL-6 [4]. No marked differences have been found in the expression of IL-6 mRNA in bronchial biopsies from control dogs and dogs with EP [15]. It was speculated that the expression of IL-6 did not increase; consequently, the CRP level did not increase in dogs with EP according to these results.

In this study, the number of eosinophils was the highest on the day of admission, but decreased on the day when the symptom worsened (Day 12). Thus, time-dependent changes in the number of eosinophils did not correlate with disease activity, which is consistent with a previous report [16]. The serum SP-A levels more precisely reflected the disease condition in this case. We propose that measuring the serum SP-A is useful for monitoring disease activity and clarifying the pathological condition of canine eosinophilic pneumonia.

REFERENCES

1. Agassandian, M., Shurin, G. V., Ma, Y. and Shurin, M. R. 2014. C-reactive protein and lung diseases. *Int. J. Biochem. Cell Biol.* **53**: 77–88. [[Medline](#)] [[CrossRef](#)]
2. Caswell, J. L. and Williams, K. J. 2007. Lungs. pp. 540–575. *In: Pathology of Domestic Animals*, 5th ed. (Maxie, M. G. ed.), Elsevier, Philadelphia.
3. Chalmers, J. D., Singanayagam, A. and Hill, A. T. 2008. C-reactive protein is an independent predictor of severity in community-acquired pneumonia. *Am. J. Med.* **121**: 219–225. [[Medline](#)] [[CrossRef](#)]
4. Chihara, J., Urayama, O., Yasuba, H., Fukuda, K., Yamamoto, T., Kurachi, D. and Nakajima, S. 1995. Possible low response of C-reactive protein production in eosinophilic pneumonia. *J. Clin. Lab. Immunol.* **47**: 33–39. [[Medline](#)]
5. Clercx, C., Peeters, D., Snaps, F., Hansen, P., McEntee, K., Dettleux, J., Henroteaux, M. and Day, M. J. 2000. Eosinophilic bronchopneumopathy in dogs. *J. Vet. Intern. Med.* **14**: 282–291. [[Medline](#)] [[CrossRef](#)]
6. Cohn, L. A. 2010. Pulmonary Parenchymal Disease. pp. 1096–1119. *In: Textbook of Veterinary Internal Medicine*, 7th ed. (Ettinger, S. J. and Feldman, E. C. eds.), Elsevier, St. Louis.
7. Corcoran, B., Thoday, K., HenFrey, J., Simpson, J., Burnie, A. and Mooney, C. 1991. Pulmonary infiltration with eosinophils in 14 dogs. *J. Small Anim. Pract.* **32**: 494–502. [[CrossRef](#)]
8. Daimon, T., Tajima, S., Oshikawa, K., Bando, M., Ohno, S. and Sugiyama, Y. 2005. KL-6 and surfactant proteins A and D in serum and bronchoalveolar lavage fluid in patients with acute eosinophilic pneumonia. *Intern. Med.* **44**: 811–817. [[Medline](#)] [[CrossRef](#)]
9. Fujii, M., Tanaka, H., Kameda, M., Tanaka, S., Ohashi, K., Chiba, H., Takahashi, H. and Abe, S. 2004. Elevated serum surfactant protein A and D in a case of acute eosinophilic pneumonia. *Intern. Med.* **43**: 423–426. [[Medline](#)] [[CrossRef](#)]
10. Ideura, G., Minamisawa, A., Urushihata, K., Hanaoka, M., Miyahara, T., Koizumi, T., Fujimoto, K., Kubo, K. and Tsukadaira, A. 2004. A case of acute eosinophilic pneumonia with a disassociation between the KL-6 level and SP-A and SP-D levels in the serum and BAL fluid. *Nihon Kokyuki Gakkai Zasshi* **42**: 640–644 (in Japanese). [[Medline](#)]
11. Johnson, L. R. 2014. Chronic Bronchial Disorders in Dogs. pp. 669–672. *In: Kirk's Current Veterinary Therapy*, 15th ed. (Bonagura, J. D. and Twedt, D. C. eds.), Elsevier, St. Louis.
12. Mochimaru, H., Kawamoto, M., Fukuda, Y. and Kudoh, S. 2005. Clinicopathological differences between acute and chronic eosinophilic pneumonia. *Respirology* **10**: 76–85. [[Medline](#)] [[CrossRef](#)]
13. Nayak, A., Dodagatta-Marri, E., Tsolaki, A. G. and Kishore, U. 2012. An Insight into the Diverse Roles of Surfactant Proteins, SP-A and SP-D in Innate and Adaptive Immunity. *Front. Immunol.* **3**: 131. [[Medline](#)] [[CrossRef](#)]
14. Norris, C. R. and Mellema, M. S. 2004. Eosinophilic Pneumonia. pp. 541–547. *In: Textbook of Respiratory Disease in Dogs and Cats* (King, L. G. ed.), Elsevier, St. Louis.
15. Peeters, D., Peters, I. R., Clercx, C. and Day, M. J. 2006. Real-time RT-PCR quantification of mRNA encoding cytokines, CC chemokines and CCR3 in bronchial biopsies from dogs with eosinophilic bronchopneumopathy. *Vet. Immunol. Immunopathol.* **110**: 65–77. [[Medline](#)] [[CrossRef](#)]
16. Rajamäki, M. M., Jarvinen, A. K., Sorsa, T. and Maisi, P. 2002. Clinical findings, bronchoalveolar lavage fluid cytology and matrix metalloproteinase-2 and -9 in canine pulmonary eosinophilia. *Vet. J.* **163**: 168–181. [[Medline](#)] [[CrossRef](#)]
17. Rothenberg, M. E. 1998. Eosinophilia. *N. Engl. J. Med.* **338**: 1592–1600. [[Medline](#)] [[CrossRef](#)]
18. Simon, D., Wardlaw, A. and Rothenberg, M. E. 2010. Organ-specific eosinophilic disorders of the skin, lung, and gastrointestinal tract. *J. Allergy Clin. Immunol.* **126**: 3–13. [[Medline](#)] [[CrossRef](#)]
19. Sone, K., Akiyoshi, H., Aoki, M., Sugii, S. and Ohashi, F. 2011. Development and validation of a sandwich ELISA for use in measuring concentrations of canine surfactant protein A in serum of dogs. *Am. J. Vet. Res.* **72**: 833–837. [[Medline](#)] [[CrossRef](#)]
20. Sone, K., Akiyoshi, H., Shimizu, J., Cao, Z., Li, Y., Tanaka, T., Hayashi, A., Sugii, S. and Ohashi, F. 2013. Surfactant protein-A concentration in sera from dogs with pulmonary parenchymal diseases. *J. Vet. Med. Sci.* **75**: 685–691. [[Medline](#)] [[CrossRef](#)]
21. Takahashi, H., Shiratori, M., Kanai, A., Chiba, H., Kuroki, Y. and Abe, S. 2006. Monitoring markers of disease activity for interstitial lung diseases with serum surfactant proteins A and D. *Respirology* **11** Suppl.: S51–S54. [[Medline](#)] [[CrossRef](#)]
22. Viitanen, S. J., Laurila, H. P., Lilja-Maula, L. I., Melamies, M. A., Rantala, M. and Rajamaki, M. M. 2014. Serum C-reactive protein as a diagnostic biomarker in dogs with bacterial respiratory diseases. *J. Vet. Intern. Med.* **28**: 84–91. [[Medline](#)] [[CrossRef](#)]
23. Walker, S. R., Williams, M. C. and Benson, B. 1986. Immunocytochemical localization of the major surfactant apoproteins in type II cells, Clara cells, and alveolar macrophages of rat lung. *J. Histochem. Cytochem.* **34**: 1137–1148. [[Medline](#)] [[CrossRef](#)]
24. Yamaya, Y., Suzuki, K., Watari, T. and Asano, R. 2014. Bronchoalveolar lavage fluid and serum canine surfactant protein A concentrations in dogs with chronic cough by bronchial and interstitial lung diseases. *J. Vet. Med. Sci.* **76**: 593–596. [[Medline](#)] [[CrossRef](#)]