

# Asystole Due to Oculocardiac Reflex during Surgical Repair of an Orbital Blowout Fracture

Yoshihiro Toyohara, MD  
Nanako Mito, MD  
Shiho Nakagawa, MD  
Kotaro Yoshimura, MD  
Ataru Sunaga, MD

**Summary:** Bradycardia and asystole due to oculocardiac reflex (OCR) are potential intraoperative complications of periocular surgery. We report a case of asystole due to OCR that occurred during surgical repair performed 40 hours after an orbital blowout fracture. The patient had vomiting, bradycardia, and ocular motility disorder before the operation. During the operation, asystole occurred when the entrapped tissue was grasped with forceps. After administration of anticholinergic drugs, the heart promptly resumed beating, and no sequelae due to asystole were observed after surgery. Before and during periocular surgery, it is important for the surgeon to maintain a protective surgical procedure and communicate appropriately with the anesthesiologist, including discussion of risks and emergency measures. In addition, prolonged entrapment of the extraocular muscles is likely to cause irreversible damage, so it is important to make a diagnosis and perform surgery as soon as possible. (*Plast Reconstr Surg Glob Open* 2022;10:e4544; doi: 10.1097/GOX.0000000000004544; Published online 28 September 2022.)

## INTRODUCTION

Oculocardiac reflex (OCR) is induced by pressure on the eyeball or extension of the extraocular muscles. The clinical symptoms of OCR include bradycardia, hypotension, and vomiting, because the periocular irritation is transmitted from the trigeminal nerve to the visceral motor nucleus of the vagus nerve in the medulla oblongata and affects the heart and stomach via the vagus nerve.<sup>1</sup> OCR occasionally occurs during periocular trauma, strabismus surgery, and surgery for periocular tumors or trauma.<sup>2</sup> We report a case of asystole due to OCR during surgery to repair an orbital blowout fracture.

## CASE REPORT

The patient was an 11-year-old girl. She was injured when she was struck in the face by the foot of another individual during volleyball practice. She began to vomit 15 minutes after the injury, and gradually began to show drowsiness, so she visited our emergency department later that night. She was easily arousable (Glasgow Coma Scale of 14) and had bradycardia, with a heart rate of about 50 beats/min. Computed tomography images taken at the emergency department indicated no organic brain damage and the

presence of a left orbital floor fracture, which suggested the diagnosis of brain concussion and blowout fracture (Fig. 1). The patient was referred to plastic surgery by the emergency department 2 days after the injury. Persistent vomiting, bradycardia, and left ocular motility disorder were present (Fig. 2), suspecting the oculocardiac reflex.

Emergency surgery began 40 hours after the injury. First, we confirmed a positive forced duction test result. The transconjunctival approach to the orbital floor revealed that the orbital contents including the inferior rectus muscle were entrapped at the orbital wall fracture line. During the operation, the heart rate was about 50 beats/min, but when the incarcerated tissue was grasped with forceps, asystole occurred. The anesthesiologist administered atropine (0.25 mg), and 12 seconds later the heart resumed beating. Immediately after the first atropine dose, bradycardia of about 40 beats/min was noted, so additional atropine (0.25 mg) was given. The heart rate improved to about 70 beats/min and the surgical procedure resumed (Fig. 3). The entrapped tissue was gently grasped and released. Because there was no bone defect, no implants were used. After confirmation of a negative forced duction test result, the operation was completed. After the operation, the heart rate was a stable 70–80 beats/min sinus rhythm. There were no findings that suggested the presence of sequelae due to asystole. The left ocular motility disorder remained for some time after surgery, but was improved at the 5-month follow-up (Fig. 4).

## DISCUSSION

OCR is caused by pressure on the eyeball or extension of the extraocular muscles. In this patient, the infraorbital

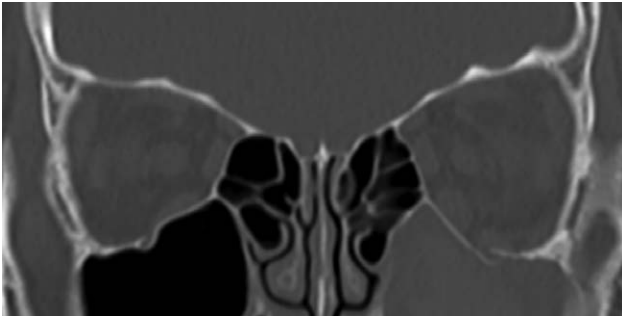
From the Department of Pediatric Plastic Surgery, Jichi Children's Medical Center Tochigi, Tochigi, Japan.

Received for publication May 12, 2022; accepted August 5, 2022.

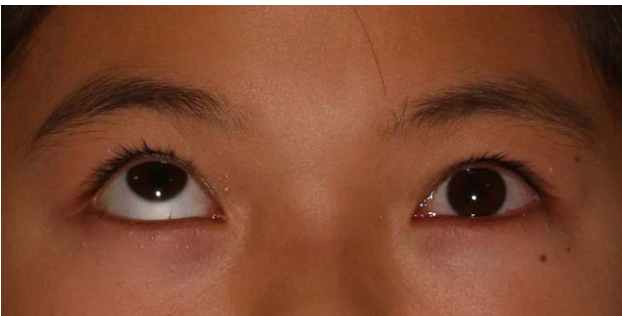Copyright © 2022 The Authors. Published by Wolters Kluwer Health, Inc. on behalf of The American Society of Plastic Surgeons. This is an open-access article distributed under the terms of the Creative Commons Attribution-Non Commercial-No Derivatives License 4.0 (CCBY-NC-ND), where it is permissible to download and share the work provided it is properly cited. The work cannot be changed in any way or used commercially without permission from the journal.

DOI: 10.1097/GOX.0000000000004544

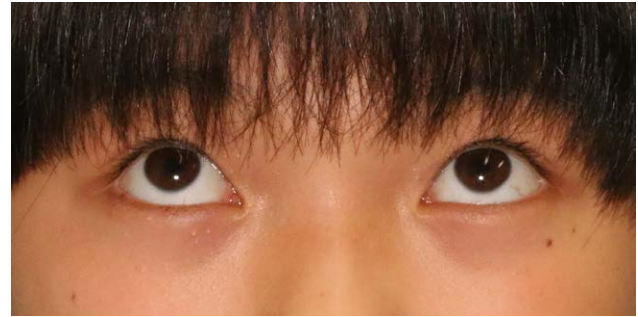**Disclosure:** The authors have no financial interest to declare in relation to the content of this article.



**Fig. 1.** Preoperative computed tomography image. A left orbital blowout fracture is present.



**Fig. 2.** Preoperative photograph of the patient. A left ocular motility disorder is present. No areas of subcutaneous or subconjunctival hemorrhage were found.



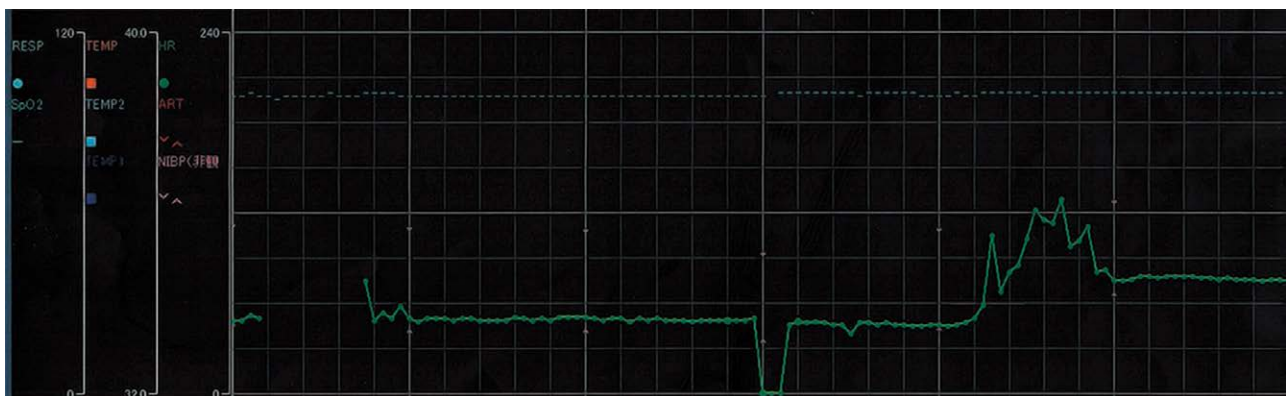
**Fig. 4.** Postoperative photograph of the patient. The left ocular motility disorder was improved at the 5-month postoperative follow-up examination.

nerve (a branch of the trigeminal nerve) was compressed due to an orbital floor fracture. Bradycardia and vomiting resulted from the subsequent OCR. OCR is often improved by removing the direct cause. Serious clinical signs include severe bradycardia and asystole, but few deaths have been reported. Anticholinergic drugs such as atropine are administered to treat severe bradycardia. Cardiopulmonary resuscitation is performed in response to asystole if there is no improvement when the direct cause is eliminated or anticholinergic drugs are administered. In this patient, forceps directly grasping the tissue containing the infraorbital nerve caused a severe OCR. Because the anesthesiologist immediately administered atropine to treat the asystole, cardiopulmonary resuscitation was not required.

During periocular surgery, it is not only important for the surgeon to be attentive and careful; appropriate communication with the anesthesiologist is equally important. Before surgery begins, the risk of OCR and the planned response if it occurs should be discussed. During surgery, pulse rates and ECG waveforms should be continuously monitored.<sup>3</sup> The surgeon and anesthesiologist should talk to each other during periocular manipulation. If OCR does occur, good communication will allow for prompt action and avoidance of negative outcomes.

Preoperative administration of anticholinergic drugs has been reported to prevent intraoperative bradycardia and arrhythmias<sup>4</sup> and may have been useful in preventing cardiac arrest in patients with preoperative OCR, as in this case. Although corticosteroids reduce swelling and may reduce the induction of OCR caused by intraoperative and postoperative compression, they have been reported to increase the incidence of OCR during surgery and should be used with caution.<sup>5</sup>

In this patient, the extraocular muscles were entrapped due to an orbital floor fracture, resulting in an ocular motility disorder. Surgical intervention within 24–48 hours is recommended because prolonged entrapment can cause irreversible muscle damage.<sup>6</sup> In our case, it took more than 40 hours for the extraocular muscles to be released from the injury due to the delayed referral. Therefore, it was likely that the muscles were severely damaged, and 5 months was thus required for the ocular motility disorder to improve. In the



**Fig. 3.** Assessment of intraoperative vital signs found bradycardia at 50 beats/min; asystole occurred at the moment the incarcerated tissue was grasped. After a total of 0.5 mg atropine was administered, the heart rate improved to 70 beat/min.

field of emergency medical care, intracranial hemorrhage is suspected preferentially when vomiting and impaired consciousness are present. At that time, attention is focused on brain computed tomography scans and not on facial bone computed tomography scans, which may delay the diagnosis.<sup>7</sup> Orbital blowout fractures are often so-called white-eyed blowout fractures that are associated with ocular motility disorder but lack subcutaneous or subconjunctival hemorrhage spots; periorbital fractures may be missed based on external physical findings alone.<sup>8</sup> Therefore, facial bone computed tomography examination results are indispensable. However, it is also important to perform a brain computed tomography examination, because 36%–88% of pediatric patients with orbital floor fractures have intracranial injuries.<sup>9</sup>

### CONCLUSIONS

We experienced a case of asystole due to OCR during reduction surgery for an orbital blowout fracture. It is important for the surgeon to be aware of the possibility that the patient may develop severe bradycardia or asystole due to OCR, and to respond quickly with appropriate communication with the anesthesiologist.

**Ataru Sunaga, MD**

Department of Pediatric Plastic Surgery  
Jichi Children's Medical Center Tochigi  
3311-1 Yakushiji, Shimotsuke  
Tochigi, Japan  
E-mail: atarusuna@me.com

### PATIENT CONSENT

*The patient provided written consent for the use of her image.*

### REFERENCES

1. Sires BS, Stanley RB Jr, Levine LM. Oculocardiac reflex caused by orbital floor trapdoor fracture: an indication for urgent repair. *Arch Ophthalmol.* 1998;116:955–956.
2. Yoo JJ, Gishen KE, Thaller SR. The oculocardiac reflex: its evolution and management. *J Craniofac Surg.* 2021;32:80–83.
3. Bosomworth PP, Ziegler CH, Jacoby J. The oculo-cardiac reflex in eye muscle surgery. *Anesthesiology.* 1958;19:7–10.
4. Gilani SM, Jamil M, Akbar F, et al. Anticholinergic premedication for prevention of oculocardiac reflex during squint surgery. *J Ayub Med Coll Abbottabad.* 2005;17:57–59.
5. Arnold RW, Jansen S, Seelig JC, et al. Anesthetic impacts on the oculocardiac reflex: evidence from a large, observational study. *Clin Ophthalmol.* 2021;15:973–981.
6. Gerbino G, Rocca F, Bianchi FA, et al. Surgical management of orbital trapdoor fracture in a pediatric population. *J Oral Maxillofac Surg.* 2010;68:1310–1316.
7. Reddy SS, Landry JP, Douglass K, et al. A case of ocular cardiac reflex in a child with blunt ocular trauma. *BMJ Case Rep.* 2014;2014:bcr2014206246.
8. Jurdy L, Malhotra R. White-eyed medial wall blowout fracture mimicking head injury due to persistent oculocardiac reflex. *J Craniofac Surg.* 2011;22:1977–1979.
9. Joshi, S, Kassira, W, Thaller, SR. Overview of pediatric orbital fractures. *J Craniofac Surg.* 2011;22:1330–1332.