



Case Report

Resolution of cauda equina syndrome after surgical extraction of lumbar intrathecal bullet

Zaid Aljuboori, Emily Sieg

Department of Neurosurgery, University of Louisville, Louisville, Kentucky, United States.

E-mail: *Zaid Aljuboori - zaid.aljuboori@yahoo.com; Emily Sieg - emily.sieg@ul.org



*Corresponding author:

Zaid Aljuboori,
Department of Neurosurgery,
University of Louisville,
Louisville, Kentucky,
United States.

zaid.aljuboori@yahoo.com

Received : 02 July 2020

Accepted : 09 July 2020

Published : 25 July 2020

DOI

10.25259/SNI_400_2020

Quick Response Code:



ABSTRACT

Background: Gunshot wound (GSW) injuries to the spinal column are correlated with potentially severe neurological damage. Here, we describe a GSW to the thoracolumbar junction (e.g., T12/L1 level) which resulted in a cauda equina syndrome that resolved once the bullet was removed.

Case Description: A 29-year-old male presented with a T12-L1 GSW; the bullet traversed the right chest and liver, entered the spinal canal at T12, and then settled at L1. He experienced excruciating burning pain in the right lower extremity/perineum and had urinary retention. On neurological examination, he exhibited severe weakness of the right iliopsoas/quadriceps (2/5) and extensor hallucis longus (1/5) which had decreased sensation in the right lower extremity in all dermatomes and urinary retention. The myelogram showed the bullet lodged intrathecally at L1; it compressed the cauda equina. Immediately after, the bullet was extracted and at 8 weeks follow-up, the patient's right-sided motor function normalized, the sensory findings improved, and the sphincteric dysfunction resolved; the only residual deficit was minimal residual numbness in the L2-L5 distributions.

Conclusion: Twenty percent of penetrating spinal column injuries are attributed to GSW s. The location of these injuries best determines the neurological damage and degree of recovery. Since patients with incomplete cauda equina syndromes have favorable prognoses, removal of bullets involving the T12-S1 levels may prove beneficial.

Keywords: Bullet, Cauda equine, Gunshot, Intrathecal

INTRODUCTION

There are no clear guidelines regarding the surgical management of penetrating injuries of the spinal column (PISC) attributed to ballistic or stab injuries.^[4] Patients with PISC can present with neurological deficits attributed to spinal cord injuries, cauda equina syndromes (CESs), or nerve root damage.^[2,4,5] Here, we present a patient who sustained a gunshot wound (GSW) to the thoracolumbar junction (T12/L1) that resulted in an incomplete cauda equina syndrome which resolved the following laminectomy and bullet removal.^[3,7]

CASE DESCRIPTION

A 29-year-old male sustained a GSW to the chest. The CT scan documented the bullet traversed the lung and liver, entered the spinal canal at T12 anterior to the psoas muscle

This is an open-access article distributed under the terms of the Creative Commons Attribution-Non Commercial-Share Alike 4.0 License, which allows others to remix, tweak, and build upon the work non-commercially, as long as the author is credited and the new creations are licensed under the identical terms.

©2020 Published by Scientific Scholar on behalf of Surgical Neurology International

(e.g., resulting in a nondisplaced fracture of the right facet joint), and settled intrathecally at L1 [Figure 1]. He exhibited 2/5 motor power of the iliopsoas/quadriceps, 1/5 motor function involving the right dorsi-/plantar flexors, decreased sensation throughout the right lower extremity, and urinary retention. He was immediately started on prophylactic vancomycin and zosyn. The CT-myelogram showed the bullet lodged intrathecally at the L1 level, where it compressed the cauda equina [Figure 2]. Within 24 h, he underwent an L1 laminectomy/durotomy for bullet removal [Figure 3]. Intraoperatively, the dura and nerve roots at L1 were intact, and there was also no obvious CSF leak. Immediately postoperatively and at 8 weeks follow-up, the patient regained normal motor function, the sensory examination improved (e.g., except for mild residual numbness in the L2-L5 dermatomes), and the sphincter dysfunction resolved. Furthermore, there were no postoperative complications.

DISCUSSION

Despite their frequency, the management of PISC remains controversial.^[2,4,6] The literature suggests the following indications for surgery; CES attributed to persistent neural compression, CSF leak, mechanical instability, bullet migration resulting in new neurological deficits, and the concern for lead poisoning.^[1,2,4,5] Having performed this study, we would add the following variables to the list; the type/severity of the neurological deficit, the duration between injury and presentation, involvement of the lumbosacral plexus, the injury type (e.g., weapon type [civilian vs. military]), bullet trajectory (e.g., transferred kinetic energy), and specific imaging findings.

Indications for surgery with incomplete CES

Incomplete CES has a favorable prognosis with early surgery/decompression, while complete injuries carry a poorer prognosis with or without surgery.^[3,5,7] With GSW, the neural injury can occur due to temporary distortion/cavitation attributed to the direct impact of the bullet. The severity of damage is determined by the kinetic energy of the bullet (e.g., impacted by fragmentation, tumbling, or deformation).^[6] The potential risks of PISC include CSF leaks requiring complex dural repair, meningitis, further neurological injury due to surgical manipulation of the nerve roots/cauda equina, and wound infection. Here, the patient presented with an incomplete CES attributed to a CT-myelogram-documented intrathecal bullet lodged at the L1 level, where it compressed the cauda equina. Surgery, consisting of an L1 laminectomy with bullet removal, resulted in both short- and long-term symptomatic improvement.

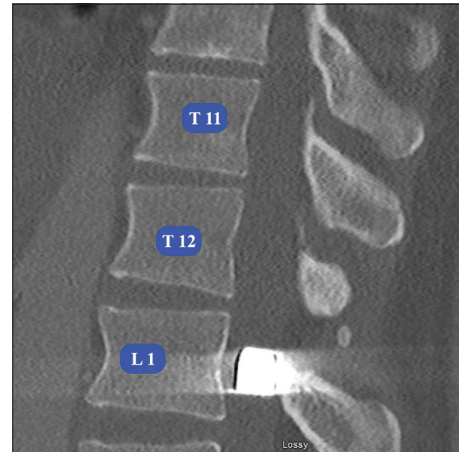


Figure 1: Computed tomography image of the lumbar spine (sagittal view) shows T11, T12, and L1 levels and the bullet inside the canal at the level of L1.

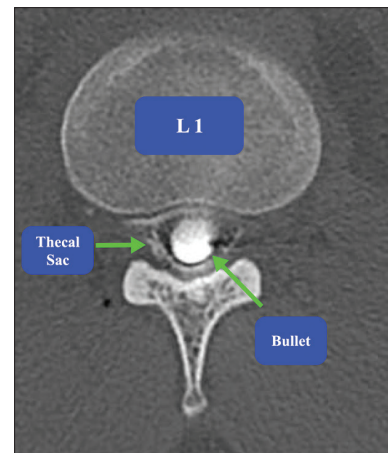


Figure 2: Computed tomography myelogram image of the lumbar spine (axial view) at the level of L1 that shows the bullet inside the thecal sac.

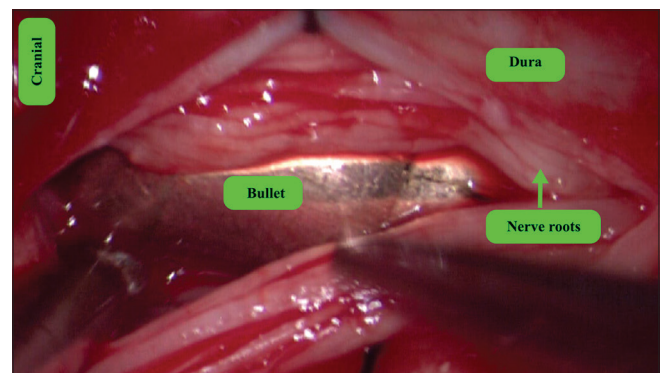


Figure 3: Intraoperative microscopic picture (50X) shows the dura, nerve roots and the bullet inside the thecal sac.

CONCLUSION

With GSW/PISC to the thoracolumbar junction, patients presenting with incomplete CES and radiographic documentation of bullet fragments lodged within the spinal canal should be considered for early surgical decompression and bullet removal.

Declaration of patient consent

Patient's consent not required as patients identity is not disclosed or compromised.

Financial support and sponsorship

Nil.

Conflicts of interest

There are no conflicts of interest.

REFERENCES

1. Crutcher CL, Wilson JM, DiGiorgio AM, Fannin ES, Shields JA, Morrow KD, *et al.* Minimally invasive management of civilian gunshot wounds to the lumbar spine: A case

- series and technical report. *Oper Neurosurg* (Hagerstown) 2020;opaa030. Doi: 10.1093/ons/opaa030.
2. Gutierrez A, Su YS, Vaughan KA, Miranda S, Chen HI, Petrov D, *et al.* Penetrating spinal column injuries (pSCI): An institutional experience with 100 consecutive cases in an urban trauma center. *World Neurosurg* 2020;138:e551-6.
3. Hoeritzauer I, Wood M, Copley PC, Demetriades AK, Woodfield J. What is the incidence of cauda equina syndrome? A systematic review. *J Neurosurg Spine* 2020;32:1-10.
4. Morrow KD, Podet AG, Spinelli CP, Lasseigne LM, Crutcher CL, Wilson JD, *et al.* A case series of penetrating spinal trauma: Comparisons to blunt trauma, surgical indications, and outcomes. *Neurosurg Focus* 2019;46:E4.
5. Patil R, Jaiswal G, Gupta TK. Gunshot wound causing complete spinal cord injury without mechanical violation of spinal axis: Case report with review of literature. *J Craniovertebr Junction Spine* 2015;6:149-57.
6. Penn-Barwell JG, Brown KV, Fries CA. High velocity gunshot injuries to the extremities: Management on and off the battlefield. *Curr Rev Musculoskelet Med* 2015;8:312-7.
7. Rider IS, Marra EM. Cauda Equina and Conus Medullaris Syndromes. Treasure Island, FL: StatPearls; 2020.

How to cite this article: Aljuboori Z, Sieg E. Resolution of cauda equina syndrome after surgical extraction of lumbar intrathecal bullet. *Surg Neurol Int* 2020;11:214.