

Intradiscal Injection with Condoliase (Chondroitin Sulfate ABC Endolyase) for Painful Radiculopathy Caused by Lumbar Disc Herniation

Takashi Hirai, Takuya Takahashi, Tomoyuki Tanaka, Takayuki Motoyoshi, Yu Matsukura, Masato Yuasa, Hiroyuki Inose, Toshitaka Yoshii and Atsushi Okawa

Department of Orthopaedic Surgery, Tokyo Medical and Dental University, Tokyo, Japan

Abstract:

Introduction: Chemonucleolysis with condoliase (chondroitin sulfate ABC endolyase) has been used to treat patients with lumbar disc herniation (LDH) in Japan since 2018. In this study, we retrospectively investigated clinical outcomes in patients who received an intradiscal condoliase injection for LDH and sought to identify significant predictors of good outcome.

Methods: Indications for treatment were as follows: (1) unilateral leg pain with or without back pain, (2) nerve root compression caused by LDH confirmed on magnetic resonance imaging (MRI), and (3) leg pain resistant to at least 1 month of conservative treatment, including medication, nerve root block, or physical therapy. Patients with motor weakness or a history of severe allergy were excluded, as were those with the foraminal or sequestered type of LDH. The injection was defined as effective if the numeric rating scale score for leg pain improved by $\geq 50\%$ at 6 months post-treatment.

Results: A total of 52 patients (mean age, 45.0 years) were enrolled and classified according to whether the injection was effective (E group, $n=40$, 76.9%) or less effective (L group, $n=9$, 17.3%). Three patients (5.8%) underwent herniotomy for residual pain within 6 months of the injection. There were no severe adverse events. Reduction of herniation was seen on MRI more often in the E group than in the L group. The effectiveness in patients with transligamentous LDH was similar to that in patients with subligamentous LDH. High-intensity signal change in the area of LDH on pretreatment T2-weighted MRI was a significant predictor of successful leg pain relief.

Conclusions: An intradiscal condoliase injection was a safe and effective treatment for painful radiculopathy caused by LDH. Leg pain was more likely to improve in patients with high-intensity signal change in the area of LDH before treatment.

Keywords:

Intradiscal injection, condoliase, chemonucleolysis, lumbar intervertebral disc herniation, radiculopathy, leg pain, low back pain, high-intensity signal change

Spine Surg Relat Res 2022; 6(3): 252-260
dx.doi.org/10.22603/ssrr.2021-0151

Introduction

Refractory radicular pain caused by lumbar intervertebral disc herniation (LDH) typically occurs in the younger working population and impairs mental status, social functioning, and work activities¹⁾. Radiculopathy due to LDH is conventionally treated using conservative strategies, including medication, physical therapy, nerve root block, and acupuncture. However, the symptoms of painful radiculopathy may become resistant to conservative treatment, and surgery may

be needed. Condoliase (chondroitin sulfate ABC endolyase)²⁾ has been developed as a novel agent with high substrate specificity for chondroitin sulfate and hyaluronic acid, both of which are constituents of the glycosaminoglycans contained in proteoglycans, which are abundant in the nucleus pulposus of the intervertebral disc. Unlike chymopapain, condoliase lacks protease activity and therefore was expected to be a safe enzyme for clinical use. The results of a Phase III clinical trial in Japan indicated that condoliase is a safe and effective treatment for radiculopathy caused by

Corresponding author: Takashi Hirai, hirai.orth@tmd.ac.jp

Received: July 21, 2021, Accepted: September 4, 2021, Advance Publication: October 11, 2021

Copyright © 2022 The Japanese Society for Spine Surgery and Related Research

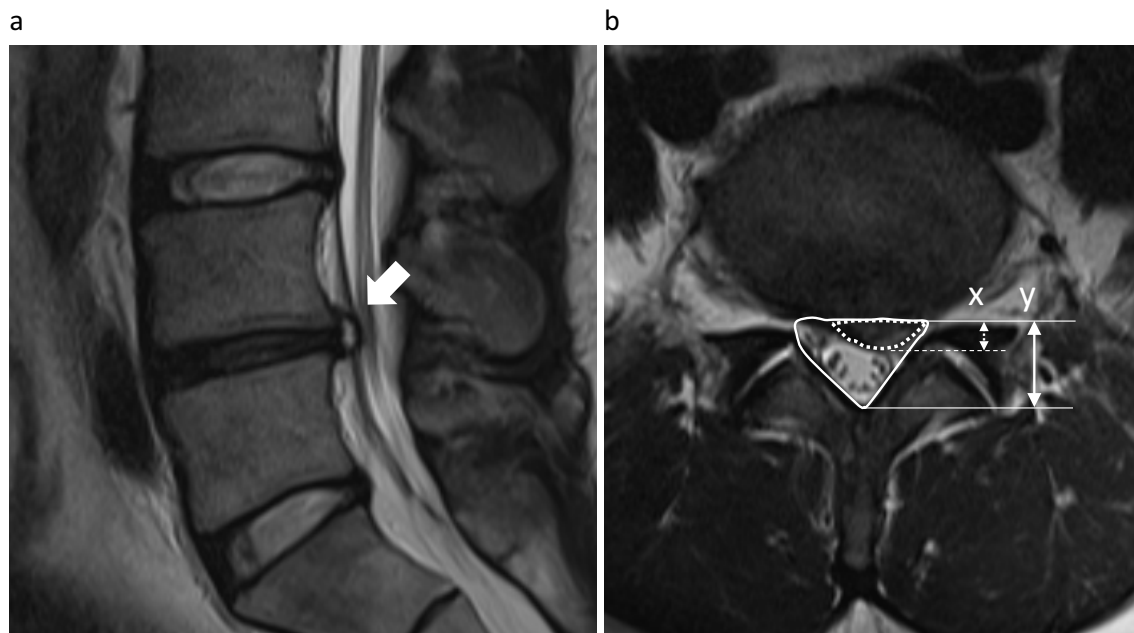


Figure 1. (a) High-intensity signal change on a T2-weighted magnetic resonance image of a patient with lumbar disc herniation. (b) Bulging ratio of herniation ($x/y \times 100\%$; x: anteroposterior diameter of herniation, y: anteroposterior diameter of canal space).

LDH^{3,4}), and it was approved as a novel agent for subligamentous herniation in Japan in 2018. However, very few studies have clarified whether condoliase is effective for extrusion types of herniation, especially the transligamentous type. In this study, we investigated clinical outcomes in patients with subligamentous or transligamentous LDH who underwent intradiscal condoliase injection for painful radiculopathy, and we sought to identify factors associated with good clinical outcome.

Materials and Methods

This retrospective, single-center study involved patients with unilateral leg pain caused by LDH who were treated by intradiscal condoliase injection in our department between October 2018 and September 2020 and followed up for at least 6 months. Indications for treatment were as follows: unilateral leg pain with or without back pain, nerve root compression caused by LDH confirmed on magnetic resonance imaging (MRI), and leg pain resistant to at least 1 month of conservative treatment, including medication, nerve root block, or physical therapy. Patients with motor weakness or a history of severe allergy were excluded, as were patients with the foraminal or sequestered type of LDH. The study was approved by our institutional ethics committee. Informed consent was obtained from all patients.

Intradiscal injection technique

All the intradiscal injections were administered by a qualified orthopedic spine surgeon. The patient was placed in a prone position and a conventional disc-puncture needle was inserted from the right side under fluoroscopic guid-

ance. Condoliase (Hernicore[®]; Seikagaku Corp., Tokyo, Japan/Kaken Pharmaceutical Co. Ltd., Tokyo, Japan) was dissolved in 1.2 mL of saline to prepare a 1.25 U/mL solution and injected into the intervertebral disc. All patients were carefully observed for at least 1.5 h after the injection and then allowed to return home.

Clinical outcomes

Data were retrospectively collected on age, sex, duration of symptoms before the injection, history of surgery at the same level as the injection, adverse events, and the numeric rating scale (NRS) scores for leg pain and low back pain. Patients in whom surgical treatment was required for residual pain were also recorded. The injection was deemed to be effective if the NRS score for leg pain improved by $\geq 50\%$ during the 6 months of follow-up.

Radiologic evaluation

Lumbar radiographs were obtained before and after the injection. The lumbar lordotic angle (L1-S1) on lateral images, the presence of spondylosis (defined as anterior or posterior translation ≥ 3 mm), and disc space height, defined as the distance between the centers of the lower and upper endplates of the affected intervertebral disc, in the upright and decubitus positions were evaluated over time. The MRI results before and at around 6 months post-injection were also examined. The level of herniation, Pfirrmann classification⁵, type of herniation, and presence of a change in signal intensity in the area of LDH on T2-weighted MRI were assessed by three experienced orthopedic spine surgeons (Fig. 1a). Any disagreement was resolved by majority consensus. The bulging ratio of herniation (defined as the proportion of

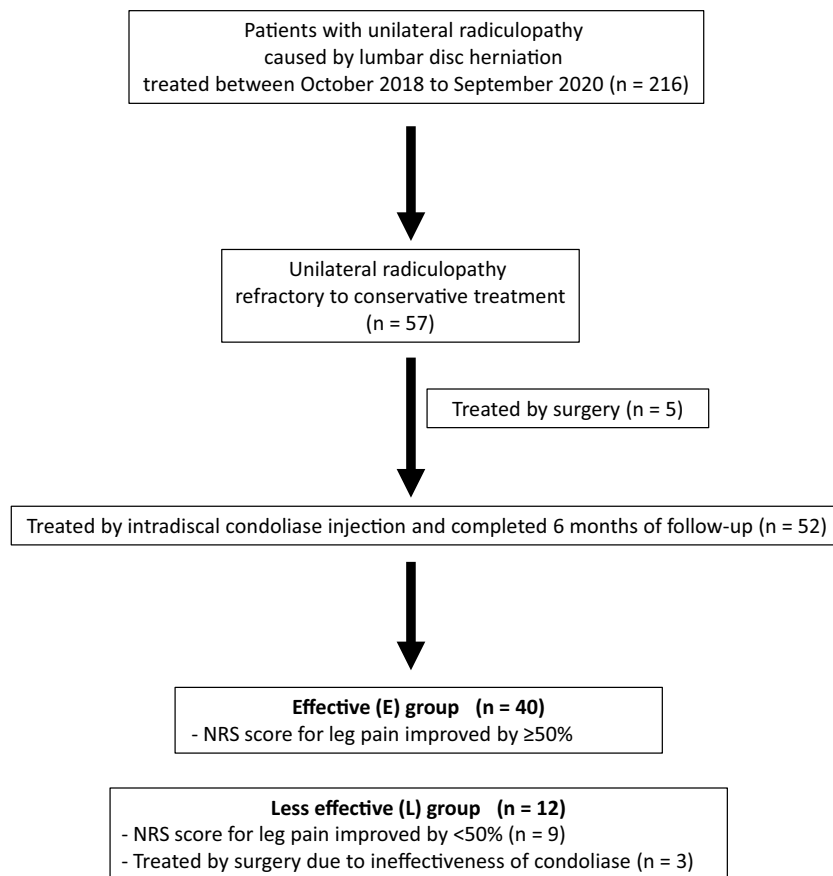


Figure 2. Flowchart of patients treated with intradiscal condoliase injection.

the anteroposterior diameter of herniation to the anteroposterior diameter of the canal space) and the reduction ratio (i.e., the postoperative bulging ratio to the preoperative bulging ratio) were calculated (Fig. 1b).

Statistical analysis

Differences in variables according to effectiveness were examined for statistical significance using the chi-squared test or Mann-Whitney *U* test as appropriate. Multivariate logistic regression with a forward stepwise procedure was performed to identify the strongest predictors of radiculopathic pain relief ($p < 0.1$ for entry). The dependent variable was effectiveness for leg pain (improved by $\geq 50\%$) and the independent variables were age, sex, symptom duration, and radiographic parameters. All statistical analyses were performed using SPSS for Windows (version 20.0; IBM Corp., Armonk, NY). A p -value < 0.05 was considered statistically significant.

Results

Patient demographics and clinical course

A total of 216 patients with unilateral radiculopathy caused by LDH were treated during the study period. Conservative treatment was ineffective in 57 of these patients. Five of the 57 patients opted for surgical treatment and 52

opted for intradiscal condoliase injection (Fig. 2). The demographics of these 52 patients (35 male, 17 female; mean age, 45.0 years) are summarized in Table 1. At baseline, mean NRS scores were 6.5 ± 2.1 and 4.5 ± 2.8 for leg pain and low back pain, respectively. All patients were followed up for at least 6 months. Median duration of symptoms before the injection was 15.3 (range, 1-192) months. Six of the 52 patients had a history of hemiotomy at the affected level. The affected level was L1/2 in 1 patient, L2/3 in 1, L3/4 in 4, L4/5 in 30, and L5/S1 in 16. The type of herniation was subligamentous extrusion in 27 patients (51.9%) and transligamentous extrusion in 25 patients (48.1%). A total of 24 patients (46.2%) had high-intensity signal change in the area of herniation on T2-weighted images. Mean bulging ratio was 32.1% before injection. Three of the 52 patients (5.8%) underwent surgical treatment for severe residual leg pain; their mean pre-injection and preoperative NRS scores for leg pain were 7.3 and 5.7, respectively. Other clinical parameters are shown in Table 1.

A total of 49 patients completed 6 months of follow-up. Their average NRS score for low back pain at 1 month post-injection was almost the same as that at baseline but gradually decreased by approximately 40% at 6 months post-injection (Fig. 3a). On the other hand, the mean NRS score for leg pain decreased by 56.3% at 1 month compared with baseline and decreased to around 30% compared with baseline within 3 months (Fig. 3b). The disc height decreased by

Table 1. Patient Demographic and Clinical Characteristics According to Need for Surgery.

	All cases (n=52)	Followed up for 6 months without surgery (n=49)	Surgery within 6 months (n=3)
Age (years)	45.0±17.7	44.4±17.3	63.0±13.9
Male/female	35:17	32:16	3:0
NRS score for leg pain	6.5±2.1	6.4±2.1	7.3±1.5
NRS score for low back pain	4.5±2.8	4.5±2.8	5.7±2.5
Duration of symptoms (months)	15.3 (1–192)	16.4 (1–192)	17.0 (7–36)
History of spine surgery at the herniated disc level, n	6 (11.5%)	6 (12.2%)	0 (0%)
Lumbar lordotic angle at baseline (degrees)	41.2±13.2	41.1±13.5	44.1±6.9
Disc height at baseline (mm)			
Upright position	7.9±2.2	8.0±2.1	6.4±2.2
Decubitus position	8.2±2.2	8.3±2.2	6.9±2.2
Spondylosis (>3 mm; anterior/posterior)	0/6 (0%/11.2%)	0/4 (0%/8.2%)	0/2 (0%/66.7%)
Disc level of herniation			
L1/2	1 (1.9%)	1 (2.0%)	
L2/3	1 (1.9%)	1 (2.0%)	
L3/4	4 (7.7%)	4 (8.2%)	
L4/5	30 (57.7%)	28 (57.1%)	2 (66.7%)
L5/S	16 (30.8%)	15 (30.6%)	1 (33.3%)
Pfirrmann grade			
II	6 (11.5%)	6 (12.2%)	
III	17 (32.7%)	15 (30.6%)	2 (66.7%)
IV	28 (53.8%)	27 (55.1%)	1 (33.3%)
V	1 (1.9%)	1 (2.0%)	
Type of herniation			
Subligamentous	27 (51.9%)	26 (53.1%)	1 (33.3%)
Transligamentous	25 (48.1%)	23 (46.9%)	2 (66.7%)
High-intensity signal change at herniation site on T2-weighted MRI	24 (46.2%)	23 (46.9%)	1 (33.3%)
Bulging ratio of herniation (%)	32.1±11.4	31.1±11.5	29.4±5.8

Data are presented as the mean±standard deviation, mean (range), or n (percentage). Abbreviations: MRI, magnetic resonance imaging; NRS, numeric rating scale

an average of 1.7 mm by 1 month after the injection, and the decrease was maintained over the 6 months of follow-up (Fig. 3c). There was also a significant decrease in the mean bulging ratio after injection compared with baseline (32.0% vs. 19.3%; Fig. 3d).

Patient demographics

In the 6 months following the injection, pain relief (indicated by a ≥50% reduction in the NRS score for leg pain) was achieved in 40 patients (E [effective] group, 76.9%); however, pain reduction was insufficient in 12 patients (the L [less effective] group, 23.1%) (Fig. 2). The L group included three patients (5.8%) who underwent surgery due to residual pain even after intradiscal injection and nine (17.3%) with insufficient pain relief (<50% reduction) who did not undergo surgery. The demographic characteristics of these two groups are shown in Table 2. The respective mean NRS scores for leg pain and low back pain were similar between the E group (6.6±2.1 and 4.5±2.8) and the L group (6.2±2.1 and 4.5±3.0) before the injection. Mean duration of symptoms was shorter in the E group (12.8 months) than in the L group (28.8 months); however, the difference was not

statistically significant. Four patients (10%) in the E group and two (16.7%) in the L group had a history of spine surgery at the herniated disc level. There were no significant differences in the clinical characteristics of these patients at baseline.

The radiologic findings are also shown in Table 2. Concomitant spondylosis was detected in four patients in the E group (10%) but not in any patient in the L group. In the E group, the LDH was Pfirrmann grade II in 6 patients, grade III in 11, grade IV in 22, and grade V in 1. The LDH in the L group was grade III in 4 patients, grade IV in 7, and grade V in 1. A total of 21 patients in the E group and 1 in the L group showed high-intensity signal change at the site of herniation on T2-weighted MRI; the difference was statistically significant ($p=0.007$). The type of herniation was subligamentous in 21 patients (52.5%) and transligamentous in 19 patients in the E group and subligamentous in 5 patients and transligamentous in 4 patients in the L group. The mean bulging ratio was 32.1% in the E group and 27.4% in the L group ($p=0.38$).

Two adverse events (skin rash and leg pain, one each) occurred immediately after the injection in the E group. There

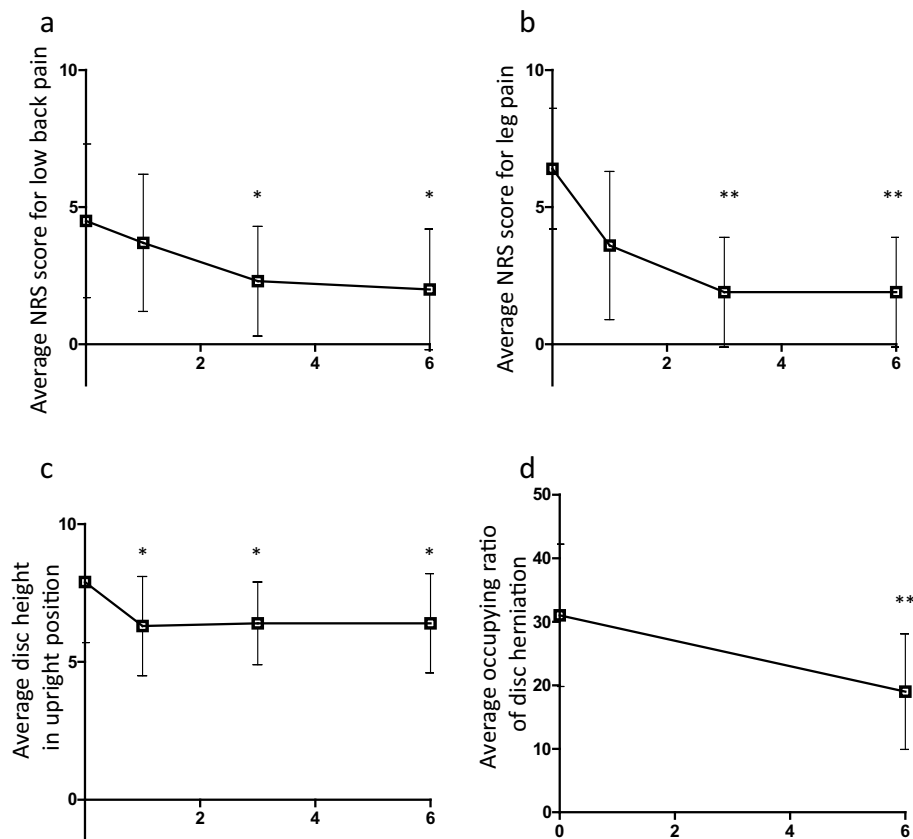


Figure 3. Clinical and radiologic findings in 49 patients who received an intradiscal injection of condoliase. (a) Average NRS score for low back pain. (b) Average NRS score for leg pain. (c) Average disc height in the upright position. (d) Average occupying ratio of disc herniation. NRS, numeric rating scale. * $p < 0.05$, ** $p < 0.01$ vs. baseline value

were no adverse events in the L group (Table 3).

Comparison of clinical and radiologic outcomes between the study groups

Changes in NRS scores for low back pain over time were similar between the E and L groups (Fig. 4a). However, the NRS scores for leg pain decreased to approximately 60% of the baseline value in both the E and L groups at 1 month after the injection and by 25.6% at 3 months and 16.7% at 6 months in the E group but remained unchanged at 6 months in the L group (Fig. 4b).

In both groups, there was a decrease in mean disc height in the upright position of approximately 1.6 mm at 1 month post-injection that was retained at 6 months (Fig. 4c). The mean bulging ratio significantly decreased from 32.1% to 17.5% in the E group and from 26.1% to 18.1% in the L group (Fig. 4d). The mean herniation reduction ratio was significantly greater in the E group than in the L group (39.1% vs. 18.6%; $p = 0.04$, Fig. 4e).

Logistic regression analysis demonstrated a significant association between the presence of high-intensity signal change before injection and effectiveness of intradiscal condoliase injection ($p = 0.024$; odds ratio 8.842; 95% confidence interval, 1.269-58.382). No other items were significant predictors of effectiveness.

Discussion

Chymopapain was developed as a chemonucleolysis agent and was in clinical use for patients with intervertebral disc herniation from the 1960s to the 1980s^{6,7}. Various research groups reported that chymopapain achieved satisfactory clinical outcomes^{6,7}. However, chymopapain has low substrate specificity, so it acts not only on the cartilage but also on the surrounding tissues and led to anaphylactic reactions, severe back pain, and neurological complications. Therefore, chymopapain was withdrawn from the market in 1999 and no alternative therapeutic option was available. A safer and more effective enzyme was needed for chemonucleolysis. Condoliase is composed of chondroitin sulfate ABS endolyase and basic studies have shown it to be selective for cartilage tissue^{8,9}. Matsuyama et al. investigated the efficacy and safety of condoliase in the treatment of LDH in a Phase II/III trial in Japan (NCT00634946). In that study, 194 patients were assigned to receive an injection of condoliase 1.25 U, 2.5 U, or 5 U or a placebo injection. The incidence of adverse events and the decrease in disc height were found to be dose-dependent although all three doses had similar efficacy; therefore, 1.25 U of condoliase was selected as an appropriate dose for intradiscal injection. No severe adverse events were noted in patients receiving this dose, which is

Table 2. Patient Demographic and Clinical Characteristics in the E and L Groups.

	E group (n=40)	L group (n=12) Including three cases undergoing operation	p-value
Age (years)	44.4±17.6	47.1±18.7	0.77
Male/female	26:14	9:3	0.52
Herniated disc level			0.22
L1/2	1 (2.5%)	—	
L2/3	1 (2.5%)	—	
L3/4	2 (5.0%)	2 (16.7%)	
L4/5	23 (57.5%)	7 (58.3%)	
L5/S	13 (32.5%)	3 (25.0%)	
NRS score for leg pain	6.6±2.1	6.2±2.1	0.76
NRS for low back pain	4.5±2.8	4.5±3.0	0.68
Duration of symptoms (months)	12.8 (1–84)	28.8 (3–192)	0.33
History of spine surgery at the herniated disc level, n	4 (10%)	2 (16.7%)	0.53
Lumbar lordotic angle (degrees)	41.8±14.4	39.2±8.4	0.22
Disc height (mm)			
Upright position	8.2±2.2	7.1±1.9	0.14
Decubitus position	8.4±2.2	7.8±2.4	0.59
Spondylosis (>3 mm; anterior/posterior)	0/4 (0%/10.0%)	0/0 (0%/0%)	0.25
Pfirrmann grade			0.23
II	6 (15%)	—	
III	11 (27.5%)	4 (33.3%)	
IV	22 (55.0%)	7 (58.3%)	
V	1 (2.5%)	1 (8.8%)	
High-intensity signal change at herniation site on T2-weighted MRI	21 (52.5%)	1 (8.3%)	0.007**
Type of herniation			0.81
Subligamentous	21 (52.5%)	6 (50%)	
Transligamentous	19 (47.5%)	6 (50%)	
Bulging ratio of herniation (%)	32.1±11.1	27.4±11.3	0.38

Data are presented as the mean±standard deviation, mean (range), or n (percentage). E, effective; L, less effective. Abbreviations: MRI, magnetic resonance imaging; NRS, numeric rating scale

Table 3. Adverse Events after Intradiscal Condoliase Injection.

	E group (n=40)	L group (n=12)	p-value
Adverse event			
Skin rash, n	1 (2.5%)	0 (0%)	0.63
Leg pain immediately after injection, n	1 (2.5%)	0 (0%)	0.63

consistent with our findings. Furthermore, a recent study in cynomolgus monkeys found that the histopathological changes associated with condoliase were less marked and more selective than those caused by chymopapain¹⁰. Moreover, in other studies, salvage treatment was required in only 2.0% of patients who received an injection of condoliase for LDH during 1-6 years postoperatively^{3,4}, whereas reoperation was needed in 5%-10% of patients with LDH who had undergone herniotomy^{11,12}. Therefore, chemonucleolysis with condoliase may not be inferior to herniotomy in terms of preventing recurrence of LDH. A Phase III trial of condoliase in Japanese patients with herniation of the protrusion or subligamentous extrusion type⁴ reported significant improve-

ments in leg pain and low back pain in patients who received condoliase injection compared with those allocated to placebo. Several post-marketing surveillance studies have also shown good clinical outcomes. Okada et al. reported that 70 (85.4%) of 82 patients diagnosed as having the subligamentous extrusion type of LDH achieved satisfactory outcome (defined as ≥50% improvement in the visual analog scale score for leg pain) after injection of condoliase¹³. Banno et al. reviewed patients with a diagnosis of any type of LDH who received an intradiscal condoliase injection and reported that 33 (70.2%) of 47 patients had significant improvement (defined as improvement in the visual analog scale score for leg pain of >20 mm)¹⁴. Ishibashi et al. inves-

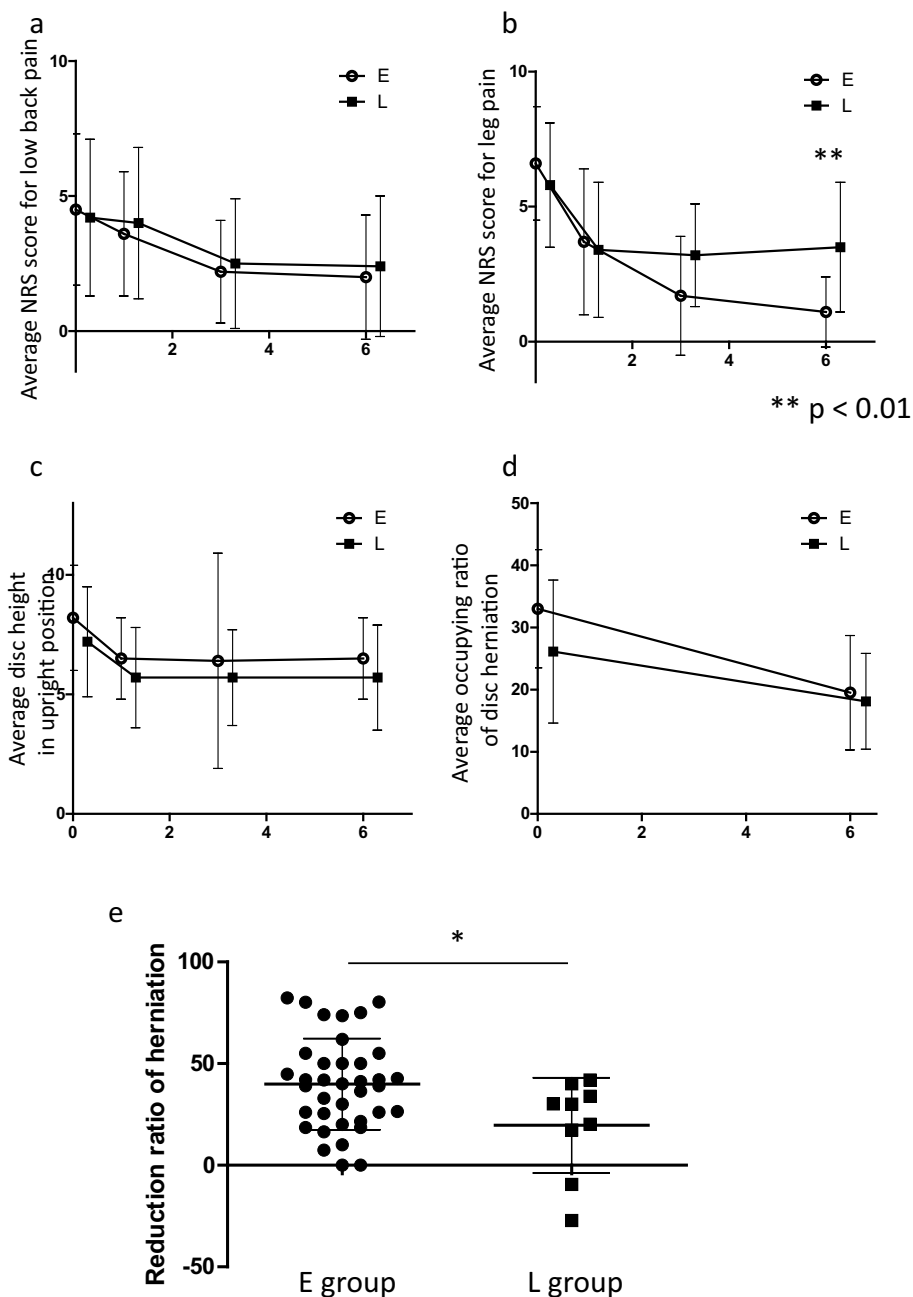


Figure 4. Clinical and radiologic findings in the E and L groups (excluding the three patients treated with surgery for residual pain after intradiscal injection). (a) Average NRS score for low back pain. (b) Average NRS score for leg pain. (c) Average disc height in the upright position. (d) Average occupying ratio for disc herniation. (e) Reduction ratio for disc herniation. NRS, numeric rating scale. * $p < 0.05$. E, effective; L, less effective

tigated the clinical outcomes in patients with a diagnosis of subligamentous or transligamentous LDH who received an intradiscal condoliase injection and demonstrated satisfactory relief of leg pain (defined as improvement of $\geq 50\%$ in the NRS score) in 21 of 34 cases (61.8%)¹⁵. In our present study, which includes the largest number of patients with the protrusion, subligamentous, and transligamentous types of LDH investigated to date, 40 of 52 patients (76.9%) achieved good pain relief in the 6 months after intradiscal condoliase injection. Furthermore, we found that 19 of 23

patients (82.6%) with transligamentous LDH had satisfactory outcomes, indicating that the outcomes were similar to those of patients with subligamentous LDH (80.8%). We speculate that even transligamentous LDH might shrink following degradation with hyaluronic acid and dehydration of the nucleus pulposus beneath the posterior longitudinal ligament. Therefore, condoliase appears to be an effective treatment for not only the protrusion and subligamentous extrusion types of LDH but also the transligamentous extrusion type.

In our regression model, there was no significant correlation between age and degree of pain relief following condoliase injection. Ishibashi et al¹⁵⁾ demonstrated that age was significantly associated with improvement of low back pain but not leg pain relief after condoliase injection. Interestingly, even relatively elderly patients over 70 years old had satisfactory pain relief in our study. This finding suggests that condoliase might be effective for LDH regardless of age and accordingly speculates that the nucleus pulposus may have relatively less degeneration even in elderly LDH patients, when herniation causes painful radiculopathy. This study identified high-intensity signal change on T2-weighted MRI as a significant predictor of good clinical outcome in patients with LDH treated with condoliase, which is consistent with the findings of Banno et al¹⁴⁾. High-intensity signal change in a disc indicates a pathological state in the posterior annulus fibrosus and is often found in symptomatic patients with high-grade disruption of an intervertebral disc¹⁶⁾. This distinctive lesion is often enhanced on gadolinium DTPA-MRI¹⁷⁾ and is considered to include granulation tissue and/or neovascularization induced by inflammation⁸⁾. Conversely, patients without high-intensity signal change were less likely to have pain relief (effective in 19 of 30 patients, 63.3%). Therefore, we speculate that an intradiscal condoliase injection acts on this high-intensity lesion, resulting in good clinical outcomes in patients with this type of LDH.

Risk factors for an unsatisfactory outcome after treatment with condoliase have also been documented. Banno et al. identified the presence of spondylolisthesis or a posterior intervertebral angle of >5 degrees to be risk factors for poor outcome after chemonucleolysis with condoliase¹⁴⁾, suggesting that condoliase may induce further instability in a degenerated segment. They also identified a history of herniotomy to be a risk factor for unsatisfactory outcome. In this study, pain relief was inadequate after the injection in two of six patients (33.3%) with a history of spine surgery at the same level.

Both the physician and patient should be involved in the choice between intradiscal injection and surgical treatment. Most surgeons would recommend surgery for patients with painful radiculopathy in the acute phase because it can eliminate pain and restriction of daily activities rapidly, whereas chemonucleolysis often takes longer to have a pain-relieving effect. Thus, surgical treatment, such as laminotomy with herniotomy or microendoscopic herniotomy, is indicated for patients with LDH and acute radiculopathy. However, there has been no published comparison of the clinical outcomes of chemonucleolysis and surgery in patients with LDH and chronic radiculopathy. A meta-analysis performed in the 1990s reported that surgery was superior to chemonucleolysis with chymopapain and that up to 30% of patients who received an intradiscal injection of chymopapain went on to have disc surgery within 2 years¹⁸⁾. In the recent Phase II/III clinical trial conducted in Japan, 13 of 130 patients (10.0%) who received the 1.25 U condoliase injection subsequently required surgery for residual

pain^{3,4)}. Although most of those patients underwent herniotomy within 6 months of the injection, no patient needed surgical treatment for recurrence of herniation at the affected level in the 2-6 years after the injection. In that study, the mean duration of symptoms before the intradiscal injection was 12.8 months in patients who had good clinical outcomes. Although some studies have reported satisfactory pain relief in patients with LDH in the chronic phase^{19,20)}, several groups have reported a reoperation rate of approximately 2% per year following herniotomy for LDH^{11,12,21)}. Overall, the reoperation rate was 10%-15% in the 5 years after the primary surgery. Furthermore, surgery is sometimes associated with peri- and postoperative complications, including surgical site infection, dural tear, and recurrence of radiculopathy due to hemorrhage. Overall, the results reported in the literature and our present findings suggest that an intradiscal condoliase injection may be suitable for patients with chronic radiculopathy due to LDH.

This study has several limitations. First, it did not have a prospective randomized controlled design. Second, patients were followed up for only 6 months, so the longer-term clinical outcomes of intradiscal condoliase injection in patients with LDH are unknown. Third, the study population was relatively small. However, despite these limitations, we believe that intradiscal injection of condoliase is a promising strategy for these patients.

Conclusion

This study reviewed 52 patients treated with an intradiscal condoliase injection for subligamentous or transligamentous LDH. Intradiscal condoliase injection was a safe and effective treatment for painful radiculopathy caused by LDH. Leg pain was more likely to improve in patients with high-intensity signal change in the area of LDH before treatment.

Conflicts of Interest: The authors declare that there are no relevant conflicts of interest.

Sources of Funding: None.

Acknowledgement: We greatly thank Mrs. Tomomi Kobayashi and Mrs. Nobuko Nakajima and Mrs. Namiko Katayama for data management.

Author Contributions: Takashi Hirai: study design, data acquisition, data analysis, drafting the manuscript

Takuya Takahashi: data analysis, measurement of radiologic data, data acquisition

Tomoyuki Tanaka: data analysis, measurement of radiologic data, data acquisition

Takayuki Motoyoshi: data acquisition, data analysis

Yu Matsukura: data acquisition, drafting the manuscript

Masato Yuasa: data acquisition, data analysis

Hiroyuki Inose: software, data analysis

Toshitaka Yoshii: data acquisition, interpretation of the

data, critical revision of the manuscript

Atsushi Okawa: study design, data acquisition, interpretation of the data, critical revision of the manuscript

Ethical Approval: This study was approved by Institutional Ethics Committee of Tokyo Medical and Dental University (M2021-045).

Informed Consent: Informed consent was obtained from each patient.

References

- Hansson E, Hansson T. The cost-utility of lumbar disc herniation surgery. *Eur Spine J.* 2007;16:329-37.
- Sato N, Shimada M, Nakajima H, et al. Cloning and expression in *Escherichia coli* of the gene encoding the *Proteus vulgaris* chondroitin ABC lyase. *Appl Microbiol Biotechnol.* 1994;41:39-46.
- Matsuyama Y, Chiba K, Iwata H, et al. A multicenter, randomized, double-blind, dose-finding study of condoliase in patients with lumbar disc herniation. *J Neurosurg Spine.* 2018;28:499-511.
- Chiba K, Matsuyama Y, Seo T, et al. Condoliase for the treatment of lumbar disc herniation: a randomized controlled trial. *Spine.* 2018;43:E869-76.
- Pfirschmann CW, Metzendorf A, Zanetti M, et al. Magnetic resonance classification of lumbar intervertebral disc degeneration. *Spine.* 2001;26:1873-8.
- McDermott DJ, Agre K, Brim M, et al. Chymodiactin in patients with herniated lumbar intervertebral disc(s). An open-label, multicenter study. *Spine.* 1985;10:242-9.
- Nordby EJ, Brown MD. Present status of chymopapain and chemonucleolysis. *Clin Orthop Relat Res.* 1977;(129):79-83.
- Hamai A, Hashimoto N, Mochizuki H, et al. Two distinct chondroitin sulfate ABC lyases. An endoeliminase yielding tetrasaccharides and an exoeliminase preferentially acting on oligosaccharides. *J Biol Chem.* 1997;272:9123-30.
- Yamagata T, Saito H, Habuchi O, et al. Purification and properties of bacterial chondroitinases and chondrosulfatases. *J Biol Chem.* 1968;243:1523-35.
- Muramatsu D, Yamaguchi H, Minamisawa Y, et al. Selective chemonucleolysis with condoliase in cynomolgus monkeys. *Toxicol Pathol.* 2020;48:656-68.
- Aizawa T, Ozawa H, Kusakabe T, et al. Reoperation for recurrent lumbar disc herniation: a study over a 20-year period in a Japanese population. *J Orthop Sci.* 2012;17:107-13.
- Sarubashi Y, Mori K, Katsuura A, et al. Evaluation of standard nucleotomy for lumbar disc herniation using the Love method: results of follow-up studies after more than 10 years. *Eur Spine J.* 2004;13:626-30.
- Okada E, Suzuki S, Nori S, et al. The effectiveness of chemonucleolysis with condoliase for treatment of painful lumbar disc herniation. *J Orthop Sci.* 2021;26:548-54.
- Banno T, Hasegawa T, Yamato Y, et al. Clinical outcome of condoliase injection treatment for lumbar disc herniation: Indications for condoliase therapy. *J Orthop Sci.* 2021;26:79-85.
- Ishibashi K, Fujita M, Takano Y, et al. Chemonucleolysis with chondroitin sulfate ABC endolyase for treating lumbar disc herniation: exploration of prognostic factors for good or poor clinical outcomes. *Medicina (Kaunas).* 2020;56(11):627.
- Wang ZX, Hu YG. Factors associated with lumbar disc high-intensity zone (HIZ) on T2-weighted magnetic resonance image: a retrospective study of 3185 discs in 637 patients. *J Orthop Surg Res.* 2018;13:307.
- Ross JS, Modic MT, Masaryk TJ. Tears of the annulus fibrosus: assessment with Gd-DTPA-enhanced MR imaging. *AJR Am J Roentgenol.* 1990;154:159-62.
- Gibson JN, Grant IC, Waddell G. The Cochrane review of surgery for lumbar disc prolapse and degenerative lumbar spondylosis. *Spine.* 1999;24:1820-32.
- Soliman J, Harvey A, Howes G, et al. Limited microdiscectomy for lumbar disk herniation: a retrospective long-term outcome analysis. *J Spinal Disord Tech.* 2014;27:E8-13.
- Benzakour A, Benzakour T. Lumbar disc herniation: long-term outcomes after mini-open discectomy. *Int Orthop.* 2019;43:869-74.
- Satoh I, Yonenobu K, Hosono N, et al. Indication of posterior lumbar interbody fusion for lumbar disc herniation. *J Spinal Disord Tech.* 2006;19:104-8.

Spine Surgery and Related Research is an Open Access journal distributed under the Creative Commons Attribution-NonCommercial-NoDerivatives 4.0 International License. To view the details of this license, please visit (<https://creativecommons.org/licenses/by-nc-nd/4.0/>).