



## Case report

## Recreational ‘mud fever’: *Leptospira interrogans* induced diffuse alveolar hemorrhage and severe acute respiratory distress syndrome in a U.S. Navy seaman following ‘mud-run’ in Hawaii

Sarah A Schmalzle<sup>a,b,c,\*</sup>, Ali Tabatabai<sup>c,1</sup>, Michael Mazzeff<sup>c</sup>, Ann Matta<sup>c</sup>, Allison Hollis<sup>c</sup>, Marc Zubrow<sup>c</sup>, Keshava Rajagopal<sup>d</sup>, Kerri Thom<sup>e</sup>, Thomas Scalea<sup>c</sup>

<sup>a</sup> Institute of Human Virology, University of Maryland School of Medicine, Baltimore, MD, United States

<sup>b</sup> Division of Infectious Diseases, University of Maryland School of Medicine, Baltimore, MD, United States

<sup>c</sup> University of Maryland School of Medicine, Baltimore, MD, United States

<sup>d</sup> University of Texas, Houston and Memorial Hermann, Texas Medical Center, Houston, TX, United States

<sup>e</sup> Department of Epidemiology and Public Health, University of Maryland School of Medicine, Baltimore, MD, United States

## ARTICLE INFO

## Article history:

Received 18 March 2019

Received in revised form 20 March 2019

Accepted 20 March 2019

## Keywords:

*Leptospira interrogans*

Leptospirosis

Leptospirosis pulmonary hemorrhage syndrome

Diffuse alveolar hemorrhage

Extra-corporeal membrane oxygenation

Mud-run

## ABSTRACT

A 23-year-old man with a viral-like prodrome developed sudden severe dyspnea and was found to have renal failure, anemia, shock, and diffuse alveolar hemorrhage with acute respiratory distress syndrome, requiring emergent endotracheal intubation and extracorporeal membrane oxygenation (ECMO). Travel and exposure history from peripheral sources revealed that the patient had participated in a ‘mud-run’ in Hawaii two weeks prior to symptom onset. The patient was subsequently diagnosed with leptospirosis and treated with ceftriaxone and doxycycline. He was discharged on hospital day 13 with full recovery. Leptospirosis is associated with exposure to water, soil, or other matter contaminated with urine of carrier animals. It has been associated with a multitude of activities over time; most recently recreational water-based activities including ‘mud-runs’ in endemic areas have been added to the list of routes of exposure. This case underscores the importance of obtaining a thorough epidemiological exposure and travel history and being aware of areas of endemicity for life-threatening infections. Additionally, to our knowledge this is the second case of a patient in the United States treated with ECMO for leptospirosis induced pulmonary hemorrhage.

© 2019 The Authors. Published by Elsevier Ltd. This is an open access article under the CC BY-NC-ND license (<http://creativecommons.org/licenses/by-nc-nd/4.0/>).

## Introduction

Here we report a case of a healthy young man presenting with life threatening diffuse alveolar hemorrhage (DAH) due to leptospirosis pulmonary hemorrhage syndrome (LPHS), acquired during a mud-run. The case is remarkable both in the epidemiologic investigation required to make the diagnosis, and in the use of extracorporeal membrane oxygenation (ECMO) in this infection, which has been reported only once in the United States.

Ernest Goodpasture first described DAH in 1919 in a patient with suspected influenza [1]. It is now classified into three major histologic patterns: capillaritis, bland hemorrhage, and alveolar bleeding due to other conditions (eg. infection, pulmonary

embolism). In DAH with capillaritis, there is profound neutrophil infiltration into the peri-capillary and pulmonary interstitial spaces. In bland pulmonary hemorrhage, there is leakage of blood into the alveoli without evidence of inflammation and in alveolar bleeding from other causes, there is minimal inflammation with evidence of another primary process. Typically patients with DAH present with cough, hemoptysis, alveolar infiltrates, and hypoxemia. Some patients do not have hemoptysis because alveolar surface area is large and blood can be resorbed. The diagnosis of DAH is classically made by bronchoscopic alveolar lavage with increasing bloody return on each subsequent lavage [2].

DAH is a rare, sometimes life-threatening manifestation of several unrelated diseases including capillaritis associated with systemic autoimmune diseases, coagulation disorders, inhalational injury, pulmonary veno-occlusive disease, and certain infections [3]. Immunocompetent hosts presenting with DAH and signs of infection should raise concern for dengue fever, malaria, influenza A, leptospirosis, hantavirus pulmonary syndrome, and *Staphylococcus aureus* (*S. aureus*) pneumonia, while DAH secondary to

\* Corresponding author at: Institute of Human Virology, 725 West Lombard St, N147, Baltimore, MD, 21201, United States.

E-mail address: [sschmalzle@ihv.umaryland.edu](mailto:sschmalzle@ihv.umaryland.edu) (S.A. Schmalzle).

<sup>1</sup> These authors are the co-first authors.

adenovirus, cytomegalovirus, invasive pulmonary aspergillosis, *Mycoplasma*, *Legionella*, and *Strongyloides* would more commonly be encountered in the immunocompromised [4].

### Case report

A 23-year-old man presented in March of 2014 to a community hospital in Maryland with four days of fever, chills, severe malaise, and myalgias, which he reportedly attributed to overexertion on a recent five-day ski trip to Vermont. Chest x-ray was unremarkable (Fig. 1a). He was given a diagnosis of viral upper respiratory infection and dehydration, and discharged from the Emergency Department in haste, as he needed to 'catch a flight to Hawaii' per hospital documentation. However, he returned later that day with severe dyspnea. Vital signs included maximum temperature to 102.7°Fahrenheit, heart rate 131 beats per minute, respiratory rate 48 breaths per minute, blood pressure 94/40, and arterial oxygen saturation was 55% on 100% oxygen via nasal cannula. He was emergently endotracheally intubated and copious bloody secretions from the endotracheal tube were noted. Other abnormalities included mild elevation of transaminases and total bilirubin, acute kidney injury (serum creatinine 2.3 mg/dL with protein and blood on urinalysis), rhabdomyolysis (creatinine kinase 2811 U/L), abnormal coagulation profile (prothrombin time 16.9s, partial thromboplastin time 29s, international normalized ratio 1.4), leukocytosis (18.3 K/l), anemia (hemoglobin 7.0 g/dL), and thrombocytopenia (96 K/μl). CXR showed development of interstitial opacities (Fig. 1b). Vancomycin, ceftriaxone, azithromycin, and oseltamivir were initiated empirically at the community hospital, to cover for usual bacterial pathogens associated with community-acquired pneumonia including methicillin-resistant *Staphylococcus aureus* (MRSA), and influenza.

Within 12 h of intubation, the patient had decompensated further and had evidence of acute respiratory distress syndrome (ARDS) with  $P_{a}O_2/F_{i}O_2$  of 62, bilateral infiltrates on chest x-ray, and no evidence of left atrial hypertension. The patient was transported by helicopter to a tertiary hospital critical care resuscitation unit, and immediately initiated on veno-venous ECMO and ventilated with a protective lung strategy. Bronchoscopy revealed severe erythema and inflammation of mucosa with increasing blood secretions returned with each bronchoalveolar lavage. Additionally he required vasopressors for severe acidosis and hypotension, and was initiated on continuous renal replacement therapy for oliguric renal failure. Twelve units of packed-red blood cells were

infused in the first 24 h to maintain hemoglobin levels above 7.0 g/dL.

Infectious Diseases service and several other consult services were immediately notified of his arrival. On physical examination, the patient was critically ill appearing, sedated and ventilated with ECMO cannulas, endotracheal tube, and other support structures in place, but appeared to be a previously healthy well-nourished and well-developed young man. Crackles were heard in all lung fields. Rash, jaundice, and conjunctival injection were absent.

A thorough investigation into the patient's medical, social, and travel history revealed that he was on a scheduled break from active military service for the United States Navy; he serves on a submarine stationed in Pearl Harbor, Hawaii (HI). Past medical history was notable only for Bells palsy as a child due to Lyme disease, and he had received recommended childhood vaccinations. He had flown to Maryland from HI, and then driven to Vermont with a friend to ski and they had skied 'hard' for five days. They stayed in a cabin, which according to the friend was clean and otherwise unremarkable. Contact with medical personnel and military officials from his unit provided an accurate travel history for the antecedent 6 months of military service, which cannot be detailed here. However, we were able to confirm that he had not traveled recently to the Middle East or any areas with endemic malaria. Based on areas traveled, mild liver involvement, and the short list of infectious causes of DAH in immunocompetent patients, leptospirosis and dengue fever were suspected. Influenza remained a possibility also as the presentation occurred during influenza season, though all military members on the ship had received annual influenza vaccination. Tick-borne illnesses, while unlikely causes of DAH, were also considered based on travel to Vermont (though seasonality was not consistent). *S. aureus* pneumonia also was a possibility, made less likely by the presence of viral prodrome unless it had occurred as a complication of influenza. Family history was unknown as the patient had been adopted from Romania at birth, and there were no known sick contacts or disease outbreaks on his submarine.

The patient was empirically started on high dose intravenous steroids for possible vasculitis; extensive evaluation for rheumatologic disease excluded granulomatosis with polyangiitis (Wegener's syndrome), anti-glomerular basement membrane disease (formerly 'Goodpastures' syndrome), systemic lupus erythematosus, antiphospholipid antibody syndrome, systemic sclerosis, and mixed connective tissue disease. Lung biopsy was not pursued due to high risk of bleeding while on ECMO.

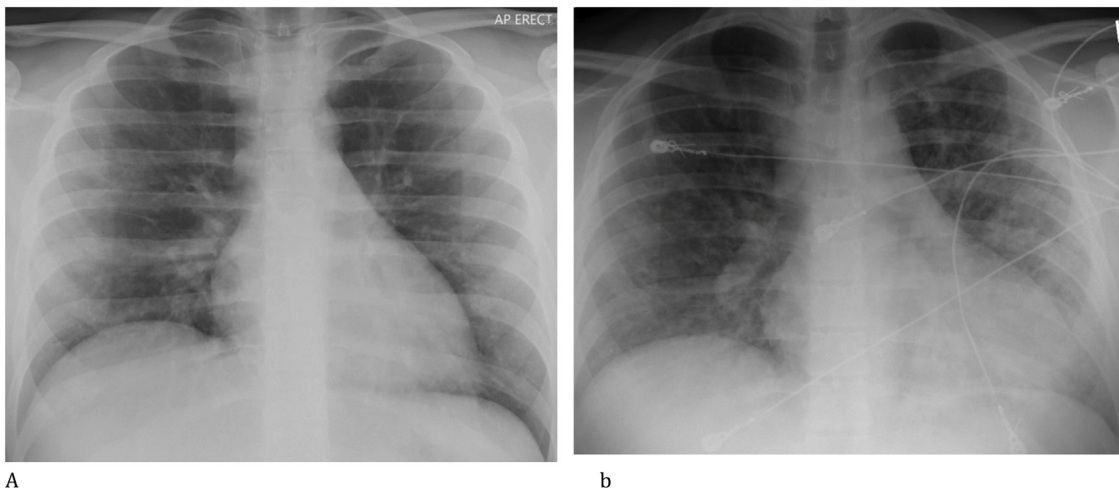


Fig. 1. (a) unremarkable CXR on initial presentation; (b) CXR upon re-presentation with developing interstitial opacities.

Based on epidemiologic risk factors, clinical presentation, and severity of illness, empiric antibiotic therapy with vancomycin, ceftriaxone, azithromycin, doxycycline, and oseltamivir was chosen to cover for community acquired pneumonia (including typical and atypical pathogens and MRSA), leptospirosis, tick-borne infections, and influenza. Prior to confirmation of full recent travel history, contact, droplet, and airborne isolation was instituted due to concern for MERS-CoV (Middle East respiratory syndrome coronavirus).

Testing for acute and chronic HIV, hepatitis B, and hepatitis C was negative. No respiratory viruses were identified by PCR from nasal swab or bronchoalveolar lavage (BAL). Cultures of blood and BAL specimens for bacterial and fungal pathogens were also negative. Other negative tests included: thick and thin blood smears for malaria, Legionella and *Streptococcus pneumoniae* urinary antigens, serum CMV PCR, Lyme IgM, and IgG, IgM, and PCR for *Ehrlichia chaffeensis* and *Anaplasma phagocytophilum*. *Mycoplasma* IgG was positive, but IgM and PCR were not. Hantavirus IgG was also positive with negative IgM.

Two days into the patient's admission to the tertiary hospital, his family recalled an important clue – they showed the medical team a digital photograph of the patient covered in mud that he had sent approximately two weeks prior to illness onset [Fig. 2]. He had participated in the “Warrior Dash” in Hawaii. The event consists of fourteen outdoor obstacles, several of which involved full body exposure to mud or fresh water. Consistent with clinical suspicion, IgM for *Leptospira* was positive. The Centers for Disease Control and Prevention and Hawaii Department of Health (HI DOH) Disease Investigation Branch were made aware, and they provided confirmatory testing. A four-fold increase in IgM titers from acute to convalescent phase, as well as PCR positive for *Leptospira interrogans* serovars Icterohaemorrhagiae and Mankarao, further bolstered the diagnosis. The dominant serovar in HI is icterohaemorrhagiae; therefore transmission likely did occur while the patient was in HI, during participation in the ‘Warrior Dash’ two weeks prior to symptom onset. The presence of serovar mankarao

is consistent either with co-infection or with cross reactivity on testing. Per HI DOH, there were no other known cases occurring in association with this event.

By the patient's sixth day on ECMO he had a significant radiographic and clinical improvement with no further evidence of DAH. He was decannulated from ECMO and endotracheally extubated the following morning. Total time on ECMO was 126 h. Two days later he was discharged from the intensive care unit and he left the hospital shortly after. At follow up one month later, patient reported being weak compared to his baseline (could ‘only’ perform 20 push-ups). Following a three to five month process of medical clearance, the patient was able to return to active duty for the US Navy (Fig. 3). He notes that on hikes in HI he routinely warns people he encounters of the risk of leptospirosis.

## Discussion

Leptospirosis occurs in humans following contact of mucous membranes or abraded skin with the spirochete *Leptospira interrogans*, excreted in the urine of infected animals. Cases of leptospirosis can occur worldwide but are classically associated with tropical and subtropical regions [5]. Of the states in the USA, Hawaii has the highest endemicity [6] and was the initial clue to the diagnosis in this case. Exposure to contaminated water, soil, and other matter places several populations at risk– rural animal or vegetable farmers, slaughterhouse workers, flood victims, soldiers, and urban sanitation workers or children exposed to rat urine in garbage or alleyways. Based on the various presentations and patterns of exposure, the human form of this disease has gone by many names: Weil's syndrome, hemorrhagic jaundice, swineherd's disease, Fort Bragg fever, swamp fever, mud fever, autumn fever, field fever, rice-field fever, cane-cutter's fever, and canicola fever [5]. Improved sanitation and mechanization of agriculture decreased rates of this disease, with epidemic leptospirosis disappearing in the 1960s. Global climate change has now been implicated in its reemergence beyond classic geographic



Fig. 2. Patient covered in mud following participation in mud-run in Hawaii.



Fig. 3. Patient returning to active duty in US Navy following recovery from leptospirosis pulmonary hemorrhage syndrome.



boundaries [7–9]. The epidemiology is changing in another way also– outbreaks associated with recreational water sports have been increasingly documented [10–12]. Chemoprophylaxis for participation in water sports has been suggested by some but remains controversial [2,12].

Presentation ranges from a mild and self-limited nonspecific viral-like syndrome to fulminant multisystem failure with jaundice, renal failure, and hemorrhage (Weil's syndrome), which can include leptospirosis pulmonary hemorrhage syndrome (LPHS). Severe disease complicates 5–15% of infections [1] and pulmonary involvement occurs in 20–70% [5]. There are an increasing number of case reports documenting LPHS or DAH as a feature in the last two decades [13].

The protean nature of most cases of leptospirosis, coupled with notoriously poor sensitivity and specificity of IgM for any infection make this diagnosis difficult to establish at initial time of presentation. Even in HI, the majority of cases are not suspected at presentation [5]. Convalescent sera and PCR can confirm diagnosis [14], but a high index of clinical suspicion is crucial to provide early and appropriate empiric antibiotics. In this case, the presence of DAH significantly narrowed the differential diagnosis, and exposure to mud and fresh water in HI were important epidemiologic clues that suggested Leptospirosis. Treatment should include penicillin, doxycycline, or a third generation cephalosporin [15,16]; this patient received ceftriaxone and doxycycline for 10 days and did recover.

Extracorporeal membrane oxygenation (ECMO) is used as a life-saving therapy for patients with lung injury who cannot be managed with conventional mechanical ventilation. There are reports of its use for non-infectious DAH syndromes, but to our knowledge there are very few cases where ECMO has been used for infectious DAH.

Use of ECMO in leptospirosis had been reported only thrice through the year 2010 but 15 times (including this case) since 2015 [17–19]. The case described here is the second report of use of ECMO for leptospirosis in the United States, both contracted outside of the contiguous United States. Only one of these 18 patients died. Comparatively, a recent description of LPHS patients in an endemic region revealed a mortality rate of 65.5% with standard care [20]. It therefore would be reasonable to extrapolate that the use of ECMO in severely ill patients with LPHS may reduce mortality. The timely coordination of care between the community hospital and the tertiary care center intensive care unit with ECMO capability played a major role in the successful outcome in this case.

## Conclusions

We have presented this case to raise awareness of the need for consideration of leptospirosis in the differential diagnosis for any patient who presents with pulmonary hemorrhage or frank DAH, in addition to other vascular and infectious etiologies more commonly seen in the United States. The importance of obtaining epidemiological data on travel and exposures cannot be understated. Anyone engaging in recreational water-based activities in areas endemic for *Leptospira* spp. should be made aware of the potential risks. Further research on the role of chemoprophylaxis is needed, especially as the cases of leptospirosis become more common in traditionally non-endemic areas due to climate change. Additionally, this case highlights the potential benefits of ECMO in LPHS and of streamlining transition of care from community hospitals to tertiary care centers for patients requiring advanced support strategies such as ECMO.

## Funding sources

None

## Conflicts of interest

The authors have no relevant conflicts of interest to report.

## CRediT authorship contribution statement

**Sarah A Schmalzle:** Writing - original draft, Writing - review & editing. **Ali Tabatabai:** Writing - original draft, Writing - review & editing. **Michael Mazzeffi:** Writing - review & editing. **Ann Matta:** Writing - review & editing. **Allison Hollis:** Writing - review & editing. **Marc Zubrow:** Writing - review & editing. **Keshava Rajagopal:** Writing - review & editing. **Kerri Thom:** Writing - review & editing. **Thomas Scalea:** Supervision.

## Acknowledgement

Written informed consent was obtained from the patient for publication of this case report and accompanying images. A copy of the written consent is available for review by the Editor-in-Chief of this journal on request.

This case was presented as a poster at the Society of Critical Care Medicine Annual Congress. Honolulu, HI. January 2017.

## References

- [1] Goodpasture EW. The significance of certain pulmonary lesions in relation to the etiology of influenza. *Am J Med Sci* 1919;158:863–70.
- [2] Ioachimescu OC, Stoller JK. Diffuse alveolar hemorrhage: diagnosing it and finding a cause. *Clev Clin J Med* 2008;75(4):258–80.
- [3] Specks U. Diffuse alveolar hemorrhage syndromes. *Curr Opin Rheumatol* 2001;13(1):12–7.
- [4] von Ranke FM, Zanetti G, Hochegger B, Marchiori E. Infectious diseases causing diffuse alveolar hemorrhage in immunocompetent patients: a state-of-the-art review. *Lung* 2013;191(1):9–18.
- [5] Farr RW. Leptospirosis. *Clin Infect Dis* 1995;21:1–8.
- [6] Katz AR, Ansdell VE, Effler PV, et al. Assessment of the clinical presentation and treatment of 353 cases of laboratory-confirmed Leptospirosis in Hawaii, 1974–1998. *Clin Infect Dis* 2001;33:1834–41.
- [7] Desai S, van Treeck U, Lierz M, et al. Resurgence of Field Fever in a Temperate Country: an epidemic of Leptospirosis among seasonal strawberry harvesters in Germany in 2007. *Clin Infect Dis* 2009;48(6):691–7.
- [8] Gubler DJ, Reiter P, Ebi KL, et al. Climate variability and change in the United States: potential impacts on vector- and rodent- borne diseases. *Environ Health Perspect* 2001;109:223–33.
- [9] Senior K. Climate change and infectious disease: a dangerous liaison. *Lancet Infect Dis* 2008;8:92–3.
- [10] Stern EJ, Galloway R, Shadomy SV, et al. Outbreak of Leptospirosis among adventure race participants in Florida. *Clin Infect Dis* 2005;2010(50):843–9.
- [11] Morgan J, Bornstein SL, Karpati AM, et al. Outbreak of Leptospirosis among triathlon participants and community residents in Springfield, Illinois. *Clin Infect Dis* 1998;2002(34):1593–9.
- [12] Haake DA, Dundoo M, Cader R, et al. Leptospirosis, water sports, and chemoprophylaxis. *Clin Infect Dis* 2002;34:e40–43.
- [13] Truong KN, Coburn J. The emergence of severe pulmonary hemorrhagic leptospirosis: questions to consider. *Front Cell Infect Mi* 2012;1(24):1–6.
- [14] Limmathurotsakul D, Turner EL, Wuthiekanun V, et al. Fool's gold: why imperfect reference tests are undermining the evaluation of novel diagnostics: a reevaluation of 5 diagnostic tests for Leptospirosis. *Clin Infect Dis* 2012;55(3):322–31.
- [15] Panaphut T, Domrongkitchaiporn S, Vibhagool A, et al. Ceftriaxone compared with sodium penicillin G for treatment of severe Leptospirosis. *Clin Infect Dis* 2003;36:1507–13.
- [16] Suputtamongkol Y, Niwattayakul K, Suttinont C, et al. An open, randomized, controlled trial of penicillin, doxycycline, and cefotaxime for patients with severe Leptospirosis. *Clin Infect Dis* 2004;39:1417–24.
- [17] Li HY, Mendes PV, Garcia Melro LM, Joelsons D, et al. Characterization of patients transported with extracorporeal respiratory and/or cardiovascular support in the State of São Paulo, Brazil. *Rev Bras Ter Intensiva* 2018;30(3):317–26.
- [18] Fonseka CL, Lekamwasam S. Role of plasmapheresis and extracorporeal membrane oxygenation in the treatment of leptospirosis complicated with pulmonary hemorrhages. *J Trop Med* 2018;2:1–8.
- [19] Vandroux D, Bouchet B, Bossard G, Leaute B, Alves T, Braunberger E. Adult respiratory distress syndrome occurring during leptospirosis. *Presse Med* 2010;39:1333–6.
- [20] Tsay AJ. Leptospirosis pulmonary hemorrhage syndrome in Salvador, Brazil from 2003 – 2012. *Public Health Theses* 2014;1296.