

# Effect of telmisartan on levels of IL-1, TNF- $\alpha$ , down-regulated COX-2, MMP-2, MMP-9 and RANKL/RANK in an experimental periodontitis model

Araújo AA, Souza TO, Moura LM, Brito GAC, Aragão KS, Araújo LS, Medeiros CAX, Alves MSCF, Araújo Jr RF. Effect of telmisartan on levels of IL-1, TNF- $\alpha$ , down-regulated COX-2, MMP-2, MMP-9, and RANKL/RANK in an experimental periodontitis model. *J Clin Periodontol* 2013; 40: 1104–1111. doi: 10.1111/jcpe.12160.

## Abstract

**Aim:** The aim of this study was to evaluate the effect of telmisartan (TELM) on inflammation, oxidation and the expression of matrix metalloproteinases (MMPs) and the expression RANKL/RANK/OPG in the periodontal tissue of a rat model for ligature-induced periodontitis.

**Materials and methods:** Male Wistar albino rats were randomly divided into five groups of 10 rats each: (i) non-ligated, given water; (ii) ligated, given water; (iii) ligated, given 1 mg/kg TELM; (iv) ligated, given 5 mg/kg TELM; and (v) ligated, given 10 mg/kg TELM. All groups were treated with saline or TELM for 10 days. Periodontal tissue was analysed by histopathology; by the immunohistochemical examination of COX-2, MMP-2, MMP-9 and the RANKL/RANK/OPG pathway; and by ELISA analysis of the levels of IL-1 $\beta$ , IL-10, TNF- $\alpha$ , myeloperoxidase (MPO), malonaldehyde (MDA) and glutathione (GSH).

**Results:** Treatment with 10 mg/kg TELM resulted in reduced concentrations of MPO, MDA ( $p < 0.05$ ) and the pro-inflammatory cytokine IL-1 $\beta$  ( $p < 0.05$ ); reduced expression of MMP-2, MMP-9, RANK, RANKL and COX-2; and an increase in OPG. The levels of TNF- $\alpha$  were significantly reduced in all TELM-treated groups.

**Conclusions:** These findings confirm the involvement of TELM in reducing the inflammatory response, oxidative stress and bone loss in ligature-induced periodontitis in rats.

Aurigena A. Araújo<sup>1</sup>, Tatiana O. Souza<sup>2</sup>, Lígia M. Moura<sup>3,4</sup>, Gerly A. C. Brito<sup>5</sup>, Karoline S. Aragão<sup>6</sup>, Lorena S. Araújo<sup>7</sup>, Caroline A. X. Medeiros<sup>8</sup>, Maria S. C. F. Alves<sup>9</sup> and Raimundo F. Araújo Jr<sup>10</sup>

<sup>1</sup>Post graduation Program Public Health/Post Graduation Program in Pharmaceutical Science, Department of Biophysics and Pharmacology, UFRN, Natal, Brazil; <sup>2</sup>Post Graduation Program Health Science, UFRN, Natal, Brazil; <sup>3</sup>Post Graduation Program Public Health, UFRN, Natal, Brazil; <sup>4</sup>Potiguar University, UNP, Natal, Brazil; <sup>5</sup>Post Graduation Program in Pharmacology, Department of Morphology, UFC, Fortaleza, Brazil; <sup>6</sup>Department of Physiology and Pharmacology, UFC, Fortaleza, Brazil; <sup>7</sup>Department of Dentistry, UFRN, Natal, Brazil; <sup>8</sup>Post Graduation Program in Health and Society, UERN, Mossoró, Brazil; <sup>9</sup>Post graduation Program Health Science/Post Graduation Program Public Health, UFRN, Natal, Brazil; <sup>10</sup>Post Graduation Program in Functional and Structural Biology/Post Graduation Program Health Science, Department of Morphology, UFRN, Natal, Brazil

Key words: anti-inflammatory; bone loss; periodontitis model; telmisartan

Accepted for publication 25 August 2013

Periodontal disease is a chronic infectious and inflammatory disease of the gums and supporting tissues. Gingival inflammation that accom-

panies this disease can lead to damage of the supporting connective tissues and loss of anchoring the teeth to the jawbone. Specific anaer-

obic bacteria within periodontal pockets are thought to be responsible for periodontal disease, and as the infection takes hold, a cascade of tissue-destructive pathways ensues, fuelled by inflammatory mediators (Williams et al. 2008).

Bacteria are essential for the occurrence of periodontitis, but they alone are insufficient to cause the dis-

## Conflict of interest and source of funding statement

The authors declare that they have no conflict of interests.

No external funding was received for this study. The reagents used were provided by the laboratory of pharmacology UFRN, and LAFICA/UFC.

ease. For periodontitis to develop, a susceptible host is required. Most periodontal breakdown (bone and attachment loss) is caused by destructive enzymes in the host, such as matrix metalloproteinases (MMPs) and inflammatory mediators (prostaglandins and interleukins) that are activated as part of the inflammatory response (Page 1999, Elavarasu et al. 2012).

Several modulating agents have been investigated as potential therapy for periodontal disease, including antiproteinases, anti-inflammatory drugs and bone-sparing drugs (Elavarasu et al. 2012). Anti-inflammatory drugs have been used as modulators of the host immune response. These agents reduce the activation of prostaglandins and cytokines involved in the inflammatory process; however, these drugs have side effects, such as gastrointestinal symptoms, bleeding, renal and hepatic impairment and accelerated bone loss when stopped abruptly (Howell & Williams 1993, Salvi & Lang 2005, Bhatavadekar & Williams 2009).

Improved knowledge and better elucidation of the host mechanisms that participate in the pathogenesis of periodontal disease have led to the proposal of novel agents aimed at modulating the host response by inhibiting inflammatory mediators. TELM, an angiotensin II receptor blocker (ARB), has been implicated as an anti-inflammatory agent that suppresses the tumour necrosis factor (TNF)- $\alpha$ -induced activation of nuclear factor (NF)- $\kappa$ B in vascular endothelial cells (Nakano et al. 2009). These authors investigated the effects of TELM on insulin resistance in rats treated with a high-fat diet and found that the drug significantly reduced the serum levels of TNF- $\alpha$  and interleukin (IL)-1 $\beta$ . In general, ARBs are well tolerated. None of the drugs reviewed has been found to cause a specific, dose-dependent adverse effect. The most common adverse reactions that have occurred in at least 2% of patients include dizziness, fatigue, diarrhoea, dyspepsia, abdominal pain, arthralgia, pain, coughing and sinusitis (Kario 2005). The aim of present study was to determine the efficacy of TELM in treating periodontal disease.

## Materials and Methods

### Animals

The experiments were performed on male Wistar rats (180–220 g) housed in standard conditions (12 h light/dark cycle and  $22 \pm 0.1^\circ\text{C}$ ), with ad libitum access to food and water. The protocol for experimental procedures and animal treatment was approved by the Animal Ethics Committee (No. 28/2012) of the Federal University of Rio Grande do Norte, Brazil.

### Model for experimental periodontitis (EPD)

Anaesthesia was induced in the rats by the IP injection of 10% ketamine (70 mg/kg Quetamina; Vetnil, São Paulo, Brazil) and 2% xylazine (10 mg/kg Calmium; São Paulo, Brazil). EPD was induced by the placement of a sterile nylon thread ligature (3-0; Polysuture, NP45330, São Paulo, Brazil) around the cervix of the maxillary left second molar. Eleven days after the initial treatment, the animals were killed with 20 mg/kg thiopental (0.5 g Thiopentax; Cristália, São Paulo, Brazil).

### Drug treatments

For the treatment, TELM (Micardis; Boehringer Ingelheim, São Paulo, Brazil) was dissolved in distilled water (the vehicle). All treatments (TELM or vehicle) were administered by oral gavage 1 h before ligation (induction of EPD) and thereafter once daily for 10 days. The animals were assigned randomly to the following five groups of 10 rats each: (i) a non-ligated group that received water (NL), (ii) a ligated group that received water (L), (iii) a ligated group treated with 1 mg/kg TELM, (iv) a ligated group treated with 5 mg/kg TELM and (v) a ligated group treated with 10 mg/kg TELM. The selection of animal drug doses was not based on human dosage because the two species have different genetic features that affect the pharmacokinetics of the drug. Dosage was based on *in vivo* studies that examined the action of the drug on blood pressure in rats (Wienen et al. 1993, 2001).

### Measurement of alveolar bone loss (ABL)

The excised maxillae were fixed in 10% neutral formalin for 24 h.

Both maxillary halves were then defleshed and stained with 1% aqueous methylene blue to differentiate bone from tooth. Measurements of bone loss were made along the length of each root surface of each molar. The ABL was measured in the five experimental groups, sample jaws of 10 per group (five ligated and five non-ligated animals). Three entries each were made for the first molars (three roots each) and two entries for the second and third molars (two roots each). The total alveolar bone loss was obtained by taking the sum of the measurements from the buccal tooth surfaces and subtracting the values of the right maxilla (no ligated control) from those of the left maxilla, in mm (Carvalho Rde et al. 2013). Morphometric analysis of the alveolar bone was performed with standardized digital photography (Olympus SC30, Olympus Corporation, Tokyo, Japan), and the distance (mm) was measured with Image Software (analysis getIT 5.1, Olympus Corporation).

### Histopathological analysis

The immunohistochemical analysis and the histological scores of the periodontal tissues were conducted by two calibrated oral pathologists (R.F.A. Jr and A.A.A.). The sectioning was performed in the Morphology and Oral Pathology laboratory and subsequently analysed by light microscopy in the Department of Morphology. Five jaws per group were used. The alveolar bone specimens were harvested, fixed in 10% neutral-buffered formalin and demineralized in 5% nitric acid. Following these treatments, the specimens were dehydrated, embedded in paraffin and sectioned along the molars in the mesiodistal plane for H&E staining. Sections of 4  $\mu\text{m}$  thickness, corresponding to the area between the first and second molars where the ligature had been placed, were evaluated by light microscopy ( $\times 40$  magnification). Parameters such as inflammatory cell influx and integrity of the alveolar bone and cementum were analysed by a histologist in a single-blind fashion and graded as follows: A score of 0 indicated that inflammatory cell infiltration was absent or sparse and was restricted to the region of the mar-

gingival gingiva, and that the alveolar process and cementum were preserved; a score of 1 indicated moderate cellular infiltration (inflammatory cellular infiltration present on the entire gingival insert), minor alveolar resorption and intact cementum; 2 indicated accentuated cellular infiltration (inflammatory cellular infiltration present in the gingiva and in the periodontal ligament), accentuated degradation of the alveolar process and partial destruction of the cementum; and 3 indicated accentuated cellular infiltration, complete resorption of the alveolar process and severe destruction of the cementum (Leitao et al. 2005).

#### Immunohistochemical analysis of COX-2, MMP-2, MMP-9, RANK-L, RANK and OPG

Thin sections of periodontal tissue (4  $\mu$ m) (three jaws per group) were obtained with a microtome and were transferred to gelatine-coated slides. Each tissue section was then deparaffinized and rehydrated. The gingival and periodontal tissue slices were washed with 0.3% Triton X-100 in phosphate buffer, quenched with endogenous peroxidase (3% hydrogen peroxide), and incubated with the following primary antibodies (Santa Cruz Biotechnology, INTERPRISE, São Paulo, Brazil) overnight at 4°C: cyclooxygenase-2 (COX-2), 1:400; matrix metalloproteinase (MMP)-2, 1:400; MMP-9, 1:400; receptor activator of the NF- $\kappa$ B ligand (RANK-L), 1:400; receptor activator of NF- $\kappa$ B (RANK), 1:400; and osteoprotegerin (OPG), 1:400. After the slices were washed with phosphate buffer, they were incubated with a streptavidin-HRP-conjugated secondary antibody (Biocare Medical, Concord, CA, USA) for 30 min., and immunoreactivity to COX-2, MMP-2, MMP-9, RANK, RANK-L and OPG was visualized using a colorimetric-based detection kit following the protocol provided by the manufacturer (TrekAvidin-HRP Label + Kit from Biocare Medical, Dako).

#### Myeloperoxidase (MPO) assay

The extent of neutrophil accumulation in the gingival samples was measured by assaying MPO activity. Gingival samples (five samples per group) were

harvested as described above and stored at  $-70^{\circ}\text{C}$  until required for assay. After homogenization and centrifugation (2000 *g* for 20 min.), MPO activity in these samples was determined by a colorimetric method described previously (Souza et al. 2003). The results were reported as units of MPO per milligram of tissue.

#### Malonaldehyde (MDA) levels

To assess lipid peroxidation, MDA production was measured with a thiobarbituric acid reaction in gingival tissue from the rats. The tissue (five samples per group) homogenate (0.25 ml of 10% tissue prepared in 0.15 M KCl) was added to a thiobarbituric acid solution (1.5 ml of 1%  $\text{H}_3\text{PO}_4$  and 500  $\mu$ l of a 0.6% thiobarbituric acid aqueous solution), and the mixture was placed in a water bath and heated for 45 min. at  $100^{\circ}\text{C}$ . Next, 2 ml of *n*-butanol P.A. was added, and the mixture was homogenized and then centrifuged at 40,816 *g* for 15 min. at  $4^{\circ}\text{C}$ . The absorbance of the butanol layer was measured at 520 nm (A1) and 535 nm (A2) (Genesys 10s UV-VIS; Thermo Fisher Scientific, Loughborough, UK). The concentration of MDA was calculated as (A2 – A1), expressed as nmol of MDA per gram of gingival tissue.

#### Glutathione (GSH) assay

Glutathione levels in the gingival tissues were measured as a marker for antioxidant activity. The gingival samples (five samples per group) were removed and stored at  $-70^{\circ}\text{C}$  until required for the assay. Gingival tissue homogenate (0.25 ml of a 5% tissue solution prepared in 0.02 M EDTA) was added to 320  $\mu$ l of distilled water and 80  $\mu$ l of 50% TCA. The samples were then centrifuged at 2551 *g* for 15 min. at  $4^{\circ}\text{C}$ . The supernatant (400  $\mu$ l) was added to 800  $\mu$ l of 0.4 M Tris-buffer at pH 8.9 and 20  $\mu$ l of 0.01 M DTNB. The absorbance of each sample was measured at 420 nm, and the results were reported as units of MPO per milligram of tissue.

#### IL-1 $\beta$ , IL-10 and TNF- $\alpha$ assay

The gingival sample tissues were stored at  $-70^{\circ}\text{C}$  until required for each assay. The tissue collected was

homogenized and processed as described by (Safieh-Garabedian et al. 1995). Levels of IL-1 $\beta$  (detection range: 62.5–4000 pg/ml; sensibility or lower limit of detection: 12.5 ng/ml of recombinant mouse IL-1 $\beta$ ), IL-10 (detection range: 62.5–4000 pg/ml; sensibility or lower limit of detection: 12.5 ng/ml of recombinant mouse IL-10) and TNF- $\alpha$  (detection range: 62.5–4000 pg/ml; sensibility or lower limit of detection: 50 ng/ml of recombinant mouse TNF- $\alpha$ ) in the gingival samples (samples per group) were determined with a commercial ELISA kit (R&D Systems, Minneapolis, MN, USA), as described previously (Kendall et al. 1983). All the samples were within the wavelength used in UV-VIS spectrophotometry (absorbance measured at 490 nm).

Briefly, microtitre plates were coated overnight at  $4^{\circ}\text{C}$  with antibodies against mouse TNF- $\alpha$ , IL-1 $\beta$  and IL-10. After the plates were blocked, the samples and standards were added at various dilutions in duplicate and incubated at  $4^{\circ}\text{C}$  for 24 h. The plates were washed three times with buffer. The following antibodies were then added to the wells: biotinylated sheep polyclonal anti-TNF- $\alpha$ , anti-IL-1 $\beta$  or anti-IL-10 (diluted 1:1000 with 1% BSA assay buffer). After further incubation at room temperature for 1 h, the plates were washed, and 50  $\mu$ l of avidin-HRP (diluted 1:5000) was added. The colour reagent *o*-phenylenediamine (50  $\mu$ l) was added 15 min. later, and the plates were incubated in the dark at  $37^{\circ}\text{C}$  for 15–20 min.

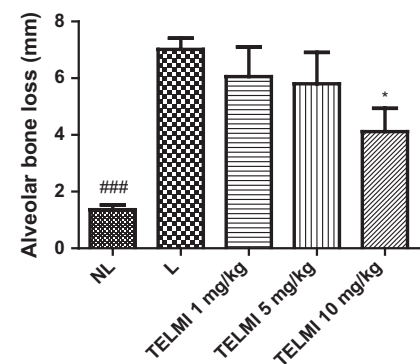


Fig. 1. Effect of Telmisartan treatment on alveolar bone loss associated with experimental periodontitis (EP) in rats. Values are expressed as means  $\pm$  SEM (### $p < 0.001$ , \* $p < 0.05$ ; determined with ANOVA and Tukey's test).

The enzyme reaction was stopped with H<sub>2</sub>SO<sub>4</sub>, and absorbance was measured at 490 nm. The resulting values were expressed in pg/ml.

**Statistical analysis**

The data are presented as means + standard error of the mean or as medians, when appropriate. Analysis of variance followed by Bonferroni's test was used to calculate the means, and the Kruskal–Wallis test followed by Dunn's test was used to compare medians (GraphPad Prism 5.0 Software, La Jolla, CA, USA). A *p*-value of <0.05 indicated a significant difference.

**Results**

**Effect of TELM treatment on alveolar bone loss in rats with EPD**

Rats with EPD (L) showed significant alveolar bone loss compared with NL (NL = 1.4 ± 0.07 mm; L = 7.02 ± 0.17 mm; *p* < 0.001). It was observed that treatment with TELM 10 mg/kg reversed the alveolar bone loss caused by EP (TELM 10 mg/kg 4.1 ± 0.8; *p* < 0.05) (Fig. 1). These data are shown in Fig. 2a, which also shows the macroscopic aspects of the NL group (SO) with no resorption of the alveolar bone compared with the L group (EPD), in which severe bone resorption with root exposure was observed (Fig. 2b). Figure 2c shows the macroscopic appearance of periodontium subjected to EPD and treated with TELM 10 mg/kg, wherein decreased bone loss was observed.

**Histological analysis**

Alveolar bone loss was reduced in the EPD-induced animals treated with 10 mg/kg TELM compared with the EPD-induced animals treated with 1 mg/kg TELM (*p* < 0.05). This result can be clearly observed histopathologically: discrete cellular infiltration restricted to the region of the marginal gingiva, preservation of alveolar bone, and intact cementum in the group treated with 10 mg/kg TELM (Fig. 3a).

Histological analysis of the region between the first and second molars of the NL group shows that the structure of the periodontium is normal and that the gingiva, periodontal ligament,

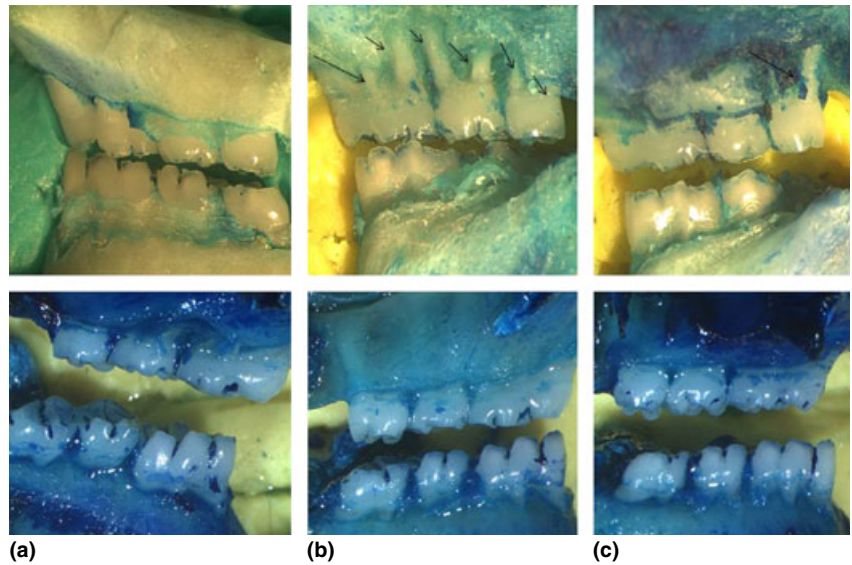


Fig. 2. (a) Superior: Left/Below: Right, Samples from the NL group, with no resorption of the alveolar bone. (b) Superior: Left/Below: Right, Samples from the L group, where severe bone resorption with root exposure is observed (arrows). (c): Superior: Left/Below: Right) Samples from the L group treated with Telmisartan 10 mg/Kg, where decreased bone resorption is observed (Arrows). Images were obtained at an original magnification of 1.7×.

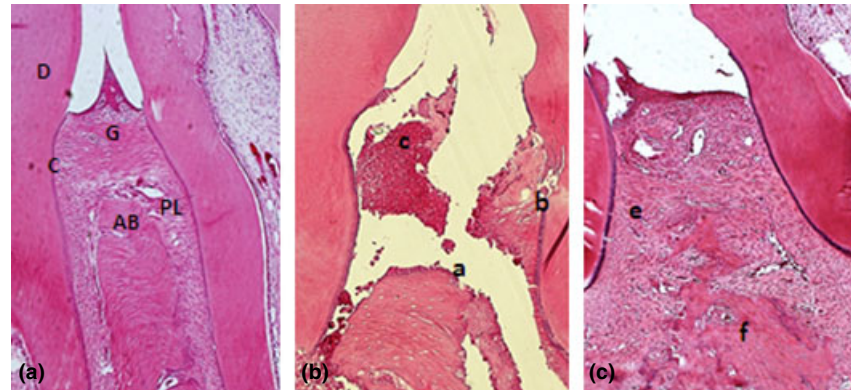


Fig. 3. Microscopic analysis. (a) Normal periodontium and (b) periodontium from a rat presenting with periodontitis (treated with saline) showing alveolar bone and cementum resorption (discontinuous cementum) and inflammatory cell infiltration. (c) Reduced inflammation and decreased alveolar bone loss in the periodontium of rats treated with telmisartan (10 mg/kg) for 10 days. Sections were stained with H&E. Microscopic original magnification at 40×. Scale bars = 100 μm. G = gingiva; PL = Periodontal ligament; D = dentin; AB = alveolar bone; C = cementum; a = bone loss; b = resorption of cementum; c = inflammatory process; e, f = decreased inflammation process and bone loss.

Table 1. Histological analysis of inflammatory response in periodontal disease model, Natal, RN, 2013

NL Median# (Q1–Q3)#	L Median# (Q1–Q3)##	TELM 1 mg/kg Median# (Q1–Q3)###	TELM 5 mg/kg Median# (Q1–Q3)###	TELM 10 mg/kg Median# (Q1–Q3)##
0 (0–0)	3 (3–3)**	3 (2–3)*	2 (2–3)	1 (1–2)

Effect of telmisartan (TELM) treatment on alveolar bone loss associated with experimental periodontitis (EP) in rats. Values are expressed as median (50th percentile) and first quartile (designated Q<sub>1</sub>), 25th percentile/third quartile (designated Q<sub>3</sub>), 75th percentile (\*\**p* < 0.001, \**p* < 0.05, ##*p* < 0.01, ###*p* < 0.01; determined by the Kruskal–Wallis test with the Dunn posttest).

alveolar bone and cementum can be observed (Fig. 3).

The periodontal histopathology of the animals subjected to EPD that received no treatment (L) revealed inflammatory cell infiltration coupled with severe destruction of the cementum and alveolar process, with animals of this group receiving a median score of 3 (Fig. 3b; Table 1). The 10 mg/kg TELM treatment prevented the inflammation induced by EPD (Fig. 3c), with animals of this group receiving a median score of 1 (Williams et al. 2008, Elavarasu et al. 2012) (Table 1).

#### Immunohistochemical analysis on markers of inflammation and bone loss

Compared with that of the NL, the periodontium of rats subjected to EPD (L) showed marked immunostaining for the following antibodies: COX-2, MMP-2, MMP-9, RANK-L and RANK (NL-saline, Fig. 4a, d, g, i and m; L-saline, Fig. 4b, e, h, k and n). However, TELM (10 mg/kg) reduced the immunostaining of COX-2, MMP-2, MMP-9, RANK-L and RANK in the periodontium of rats submitted to EPD (Fig. 4c, f, i, l and o). OPG immunostaining was observed to a mild extent in the periodontium of the L group and to a moderate extent in the NL group, while intense staining was observed for OPG in the group treated with 10 mg/kg TELM.

#### Effect of TELM treatment in inflammatory activity

MPO activity was increased in the L group compared with that of the NL group ( $p < 0.05$ ). The group treated with 10 mg/kg TELM showed a reduced concentration of MPO compared with that of the L group ( $p < 0.05$ ) (Fig. 5). The levels of the proinflammatory cytokine IL-1 $\beta$  were decreased in the group treated with 10 mg/kg TELM ( $p < 0.01$ ), and the levels of TNF- $\alpha$  were significantly reduced following treatment with any of the doses of TELM (Fig. 6). The levels of IL-10 in the group treated with TELM did not differ from those of the control groups ( $p > 0.05$ ).

#### Effect of TELM treatment on markers of oxidative stress

The treatment of EPD-induced rats with 10 mg/kg TELM reduced the

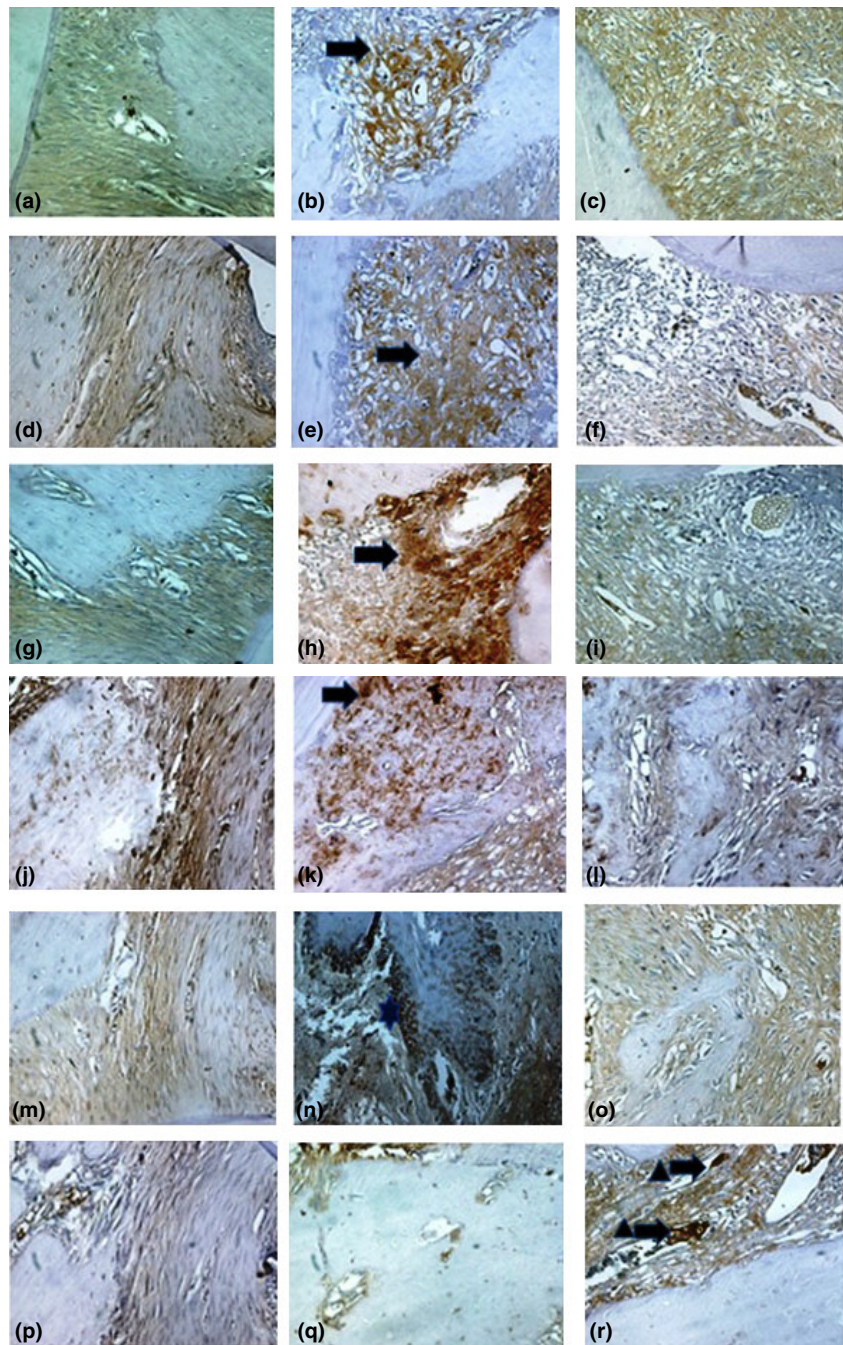


Fig. 4. Photomicrographs of periodontal tissue of rats subjected to PD and treated with telmisartan, showing the immunoreactivity to MMP-2, MMP-9, COX-2, RANK, RANK-L and OPG. Rats subjected to saline (a, d, g, j, m, p); rats subjected to PD (b, e, h, k, n, q); rats subjected to EPD and treated with telmisartan (10 mg/kg) (c, f, i, l, o, r). Images are shown at 40 $\times$  magnification. Bar scale = 100  $\mu$ m. The arrow indicates high or moderate labelling of the antibody in the periodontal ligament or in the alveolar bone. The asterisk indicates moderate labelling of the antibody in the osteoblasts. The triangle and arrow indicate moderate labelling of the OPG antibody in osteoclasts.

activity of MDA ( $p < 0.05$ ) but not the levels of GSH ( $p > 0.05$ ) compared with those of the L group (Fig. 5).

#### Discussion

In this study, we examined the preventive effects of TELM on the

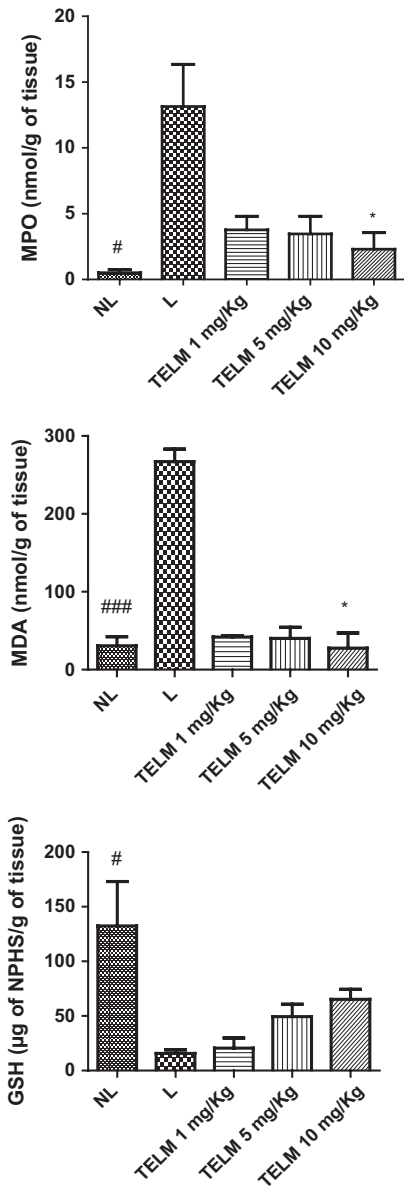


Fig. 5. Levels of MPO, MDA and GSH, in group NL, L and groups treated with 1, 5 and 10 mg/kg telmisartan (#; \* $p < 0.05$ ; ### $p < 0.001$ , determined with ANOVA and Tukey's test).

inflammatory events and bone loss associated with periodontal disease. We used ligature-induced periodontitis in rats as a model system for the study because it is a highly reproducible experimental model in which the ligation acts as mechanical trauma to the dentogingival area, thereby reducing tissue integrity and allowing for an intense host-bacterial interaction, and finally, the formation of bacterial plaque. de Lima et al. (2000) have shown that the placement of a nylon thread

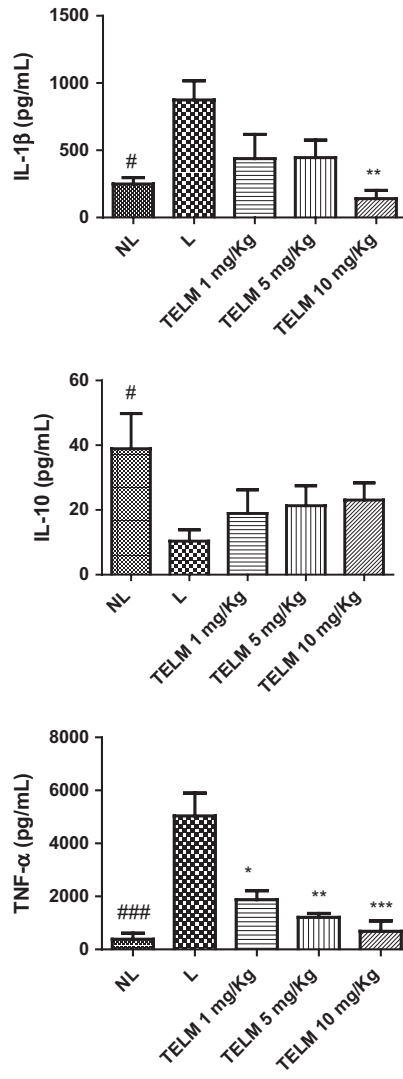


Fig. 6. Levels of IL-1 $\beta$ , IL-10 and TNF- $\alpha$ , in group NL, L and Telmisartan 1, 5 and 10 mg/kg (#; \* $p < 0.05$ ; \*\* $p < 0.01$ ; \*\*\* $p < 0.001$ ; ### $p < 0.001$ , determined with ANOVA and Tukey's test).

around the second upper molar induced significant alveolar bone loss commencing on day 3 of periodontal induction, reaching a maximum between days 7 and 11, and declining on day 14.

Under conditions of inflammation, the response of the host is leucocyte migration. Leucocytes release MPO (Malle et al. 2007). Cytokines such as TNF and interleukin 1 (IL-1) promote leucocyte extravasation by increasing the levels of leucocyte adhesion molecules on endothelial cells (Newton & Dixit 2012). IL-1 and TNF contribute substantially to the pathological bone loss that often

occurs with periodontal disease (Graves et al. 2011). In addition, IL-1 stimulates osteoclastogenesis and bone resorption, largely through up-regulation of the RANK and RANKL, whereas TNF stimulates osteoclastogenesis directly or indirectly through RANKL (Wei et al. 2005).

Furthermore, IL-1 and TNF can up-regulate the synthesis of MMPs in macrophages, fibroblasts, osteoblasts and osteoclasts (Ramamurthy et al. 2002). MMPs are a family of related zinc-containing proteinases that can degrade most of the extracellular matrix. It has been reported that the induction of MMPs (such as MMP-2) in osteoblasts is essential for bone resorption (Kusano et al. 1998). Excessive production of MMP-2, combined with the selective production of MMP-9, can lead to the acceleration of matrix degradation in pathological conditions such as periodontitis (Kusano et al. 1998).

Osteoblasts express RANKL as a membrane-associated factor in response to bone-resorbing factors such as IL-1. Osteoclast precursors possess RANK, a receptor for RANKL, and RANK-RANKL recognition induces differentiation of precursors into osteoclasts (Harada & Takahashi 2011).

Pro-inflammatory cytokines (such as IL-1 $\beta$ , IL-6, IL-11 and IL-17) and TNF- $\alpha$  stimulate the expression of RANKL and reduce the expression of OPG, leading to osteoclastogenesis and bone resorption (Nakashima et al. 2000). The effects induced by RANKL are counteracted by OPG, which acts as a soluble decoy receptor, thereby inhibiting the terminal stages of osteoclast differentiation, suppressing the activation of matrix osteoclasts, and inducing apoptosis. In this way, bone remodelling is controlled by a balance between RANK-RANKL binding and OPG production (Tobon-Arroyave et al. 2012).

The primary effect reported for TELM is the suppression of TNF- $\alpha$ -induced IL-6 gene promoter activity (Nakano et al. 2009, Tian et al. 2009); this suppression can directly interfere with various signalling pathways including both the activation of MMPs and the expression of the RANK gene, implying that it might affect the inflammation and bone loss associated with periodontal disease.

In this study, the 10 mg/kg dose of TELM reduced the levels of TNF- $\alpha$  and IL-1, and leucocyte migration was confirmed by the observed reduction in MPO levels. In addition, this dose of TELM reduced the expression of COX-2 in tissues. The macroscopic findings were corroborated by histological analysis, which revealed a partial preservation of the alveolar bone, cementum and periodontal ligament, as well as a reduction of the inflammatory infiltrate in animals receiving TELM. Higher doses of TELM significantly preserved the alveolar bone and reduced inflammatory infiltrate.

The initial step in inflammation involves the migration of leucocytes, such as polymorphonuclear neutrophils (PMNs), to the challenged site. As the first cells to migrate, PMNs release enzymes, such as MPO. The inflammatory infiltrate observed histologically in periodontal tissue may indicate the presence of PMNs. The use of TELM reduced MPO activity because of a reduction in the number of PMNs in the area. Studies have shown that the recruitment and activation of PMNs constitutes the front line of the acute host-inflammatory response, represents the main source of PGE<sub>2</sub>, and promotes the initiation of bone metabolism breakdown by stimulating osteoclasts. Therefore, the ability to reduce neutrophilia seems to be important for reducing inflammatory bone loss.

Another effect of TELM observed in this study was the reduction of MDA, which indicates that TELM regulates oxidative stress-signalling pathways. In a study by Suda et al. (2013) that investigated the effect of TELM on the progression of periodontitis in a mouse model of Marfan syndrome, the authors concluded that treatment with TELM significantly suppressed alveolar bone resorption and decreased the levels of TGF- $\beta$ , IL-17 and TNF- $\alpha$ .

Telmisartan is an antagonist of angiotensin II. Its use can be beneficial for treating periodontal disease by promoting greater blood flow to the tissues. Angiotensin can induce direct pro-oxidative effects on the vascular endothelium through the formation of reactive species within the endothelium via a new family of NADPH oxidative subunits (Cai et al. 2003). Angiotensin-converting

enzyme inhibition in vivo reduces the apparent formation of reactive oxidants (Hamed & Malek 2007). The potential importance of vascularization quality on periodontal healing was demonstrated by (Cetinkaya et al. 2007).

By this means, cytokines TNF- $\alpha$  and IL-1 are reduced to a lower production of MMPs, because this study confirmed that TELM reduced the expression of MMP-2, which is essential for the activation of osteoclastogenesis and for reducing the tissue expression of MMP-9 in osteoclasts. These data were further confirmed by analysing the expression of RANKL and OPG. The ratio of OPG to RANKL is critical for controlling osteoclast activity and bone resorption. In our study, we observed a decrease in the expression of RANK and RANKL in periodontal tissues following treatment with TELM, as well as an increase in OPG expression.

Although we found favourable results in reducing inflammation and bone loss, this study was conducted on healthy animals. The response to periodontal disease depends on the vasculature, as vasoconstriction can affect healing. For these reasons, our group will aim in the future to confirm these findings in hypertensive rats.

From this study, we conclude that in a periodontal disease animal model, the use of TELM reduced the levels of TNF and IL-1. Reduction of these cytokines might have led to the down-expression of RANKL and MMP-2 that we observed. In addition, TELM was confirmed to control the activation of osteoclasts by increasing the expression of OPG, thereby reducing bone loss. These findings suggest that the use of TELM as an antihypertensive in patients may slow the progression of inflammation and bone loss in periodontal disease.

#### Acknowledgements

Programme of Post-graduation Pharmaceutical Science/UFRN and LAFICA/UFC.

#### References

Bhatavadekar, N. B. & Williams, R. C. (2009) Modulation of the host inflammatory response

- in periodontal disease management: exciting new directions. *International Dental Journal* **59**, 305–308.
- Cai, H., Griendling, K. K. & Harrison, D. G. (2003) The vascular NAD(P)H oxidases as therapeutic targets cardiovascular diseases. *Trends in Pharmacological Sciences* **24**, 471–478.
- Carvalho Rde, S., de Souza, C. M., Neves, J. C., Holanda-Pinto, S. A., Pinto, L. M., Brito, G. A. & de Andrade, G. M. (2013) Vitamin E does not prevent bone loss and induced anxiety in rats with ligature-induced periodontitis. *Archives of Oral Biology* **58**, 50–8.
- Cetinkaya, B. O., Keles, G. C., Ayas, B., Sakalioğlu, E. E. & Acikgoz, G. (2007) The expression of vascular endothelial growth factor in a rat model at destruction and healing stages of periodontal disease. *Journal of Periodontology* **78**, 1129–1135.
- Elavarasu, S., Sekar, S. & Murugan, T. (2012) Host modulation by therapeutic agents. *Journal of Pharmacy & Bioallied Sciences* **4**(Suppl. 2), S256–S259.
- Graves, D. T., Li, J. & Cochran, D. L. (2011) Inflammation and uncoupling as mechanisms of periodontal bone loss. *Journal of Dental Research* **90**, 143–153.
- Hamed, A. A. & Malek, H. A. (2007) Effect of telmisartan in experimentally induced diabetes mellitus in rats. *International Journal of Health Sciences* **1**, 249–256.
- Harada, S. & Takahashi, N. (2011) Control of bone resorption by RANKL-RANK system. *Clinical Calcium* **21**, 1121–1130.
- Howell, T. H. & Williams, R. C. (1993) Nonsteroidal antiinflammatory drugs as inhibitors of periodontal disease progression. *Critical Reviews in Oral Biology and Medicine* **4**, 177–196.
- Kario, K. (2005) Morning surge and variability in blood pressure: a new therapeutic target? *Hypertension* **45**, 485–486.
- Kendall, C., Ionescu-Matiu, I. & Dreesman, G. R. (1983) Utilization of the biotin/avidin system to amplify the sensitivity of the enzyme-linked immunosorbent assay (ELISA). *Journal of Immunological Methods* **56**, 329–339.
- Kusano, K., Miyaura, C., Inada, M., Tamura, T., Ito, A., Nagase, H., Kamoi, K. & Suda, T. (1998) Regulation of matrix metalloproteinases (MMP-2, -3, -9, and -13) by interleukin-1 and interleukin-6 in mouse calvaria: association of MMP induction with bone resorption. *Endocrinology* **139**, 1338–1345.
- Leitao, R. F., Ribeiro, R. A., Chaves, H. V., Rocha, F. A., Lima, V. & Brito, G. A. (2005) Nitric oxide synthase inhibition prevents alveolar bone resorption in experimental periodontitis in rats. *Journal of Periodontology* **76**, 956–963.
- de Lima, V., Bezerra, M. M., de Menezes Alencar, V. B., Vidal, F. D., da Rocha, F. A., de Castro Brito, G. A. & de Albuquerque Ribeiro, R. (2000) Effects of chlorpromazine on alveolar bone loss in experimental periodontal disease in rats. *European Journal of Oral Sciences* **108**, 123–9.
- Malle, E., Furtmuller, P. G., Sattler, W. & Obinger, C. (2007) Myeloperoxidase: a target for new drug development? *British Journal of Pharmacology* **152**, 838–854.
- Nakano, A., Hattori, Y., Aoki, C., Jojima, T. & Kasai, K. (2009) Telmisartan inhibits cytokine-induced nuclear factor-kappaB activation independently of the peroxisome proliferator-

- activated receptor-gamma. *Hypertension Research* **32**, 765–769.
- Nakashima, T., Kobayashi, Y., Yamasaki, S., Kawakami, A., Eguchi, K., Sasaki, H. & Sakai, H. (2000) Protein expression and functional difference of membrane-bound and soluble receptor activator of NF-kappaB ligand: modulation of the expression by osteotropic factors and cytokines. *Biochemical and Biophysical Research Communications* **275**, 768–775.
- Newton, K. & Dixit, V. M. (2012) Signaling in innate immunity and inflammation. *Cold Spring Harbor Perspectives in Biology* **4**, pii: a006049.
- Page, R. C. (1999) Milestones in periodontal research and the remaining critical issues. *Journal of Periodontal Research* **34**, 331–339.
- Ramamurthy, N. S., Rifkin, B. R., Greenwald, R. A., Xu, J. W., Liu, Y., Turner, G., Golub, L. M. & Vernillo, A. T. (2002) Inhibition of matrix metalloproteinase-mediated periodontal bone loss in rats: a comparison of 6 chemically modified tetracyclines. *Journal of Periodontology* **73**, 726–734.
- Safieh-Garabedian, B., Poole, S., Allchorne, A., Winter, J. & Woolf, C. J. (1995) Contribution of interleukin-1 beta to the inflammation-induced increase in nerve growth factor levels and inflammatory hyperalgesia. *British Journal of Pharmacology* **115**, 1265–1275.
- Salvi, G. E. & Lang, N. P. (2005) Host response modulation in the management of periodontal diseases. *Journal of Clinical Periodontology* **32** (Suppl. 6), 108–129.
- Souza, M. H., Troncon, L. E., Cunha, F. Q. & Oliveira, R. B. (2003) Decreased gastric tone and delayed gastric emptying precede neutrophil infiltration and mucosal lesion formation in indomethacin-induced gastric damage in rats. *Brazilian Journal of Medical and Biological Research* **36**, 1383–1390.
- Suda, N., Moriyama, K. & Ganburged, G. (2013) Effect of angiotensin II receptor blocker on experimental periodontitis in a mouse model of Marfan syndrome. *Infection and Immunity* **81**, 182–188.
- Tian, Q., Miyazaki, R., Ichiki, T., Imayama, I., Inanaga, K., Ohtsubo, H., Yano, K., Takeda, K. & Sunagawa, K. (2009) Inhibition of tumor necrosis factor-alpha-induced interleukin-6 expression by telmisartan through cross-talk of peroxisome proliferator-activated receptor-gamma with nuclear factor kappaB and CCAAT/enhancer-binding protein-beta. *Hypertension* **53**, 798–804.
- Tobon-Arroyave, S. I., Isaza-Guzman, D. M., Restrepo-Cadavid, E. M., Zapata-Molina, S. M. & Martinez-Pabon, M. C. (2012) Association of salivary levels of the bone remodelling regulators sRANKL and OPG with periodontal clinical status. *Journal of Clinical Periodontology* **39**, 1132–1140.
- Wei, S., Kitaura, H., Zhou, P., Ross, F. P. & Teitelbaum, S. L. (2005) IL-1 mediates TNF-induced osteoclastogenesis. *Journal of Clinical Investigation* **115**, 282–290.
- Wienen, W., Huel, N., Van Meel, J. C., Narr, B., Ries, U. & Entzeroth, M. (1993) Pharmacological characterization of the novel nonpeptide angiotensin II receptor antagonist, BIBR 277. *British Journal of Pharmacology* **110**, 245–252.
- Wienen, W., Richard, S., Champeroux, P. & Audeval-Gerard, C. (2001) Comparative anti-hypertensive and renoprotective effects of telmisartan and lisinopril after long-term treatment in hypertensive diabetic rats. *JRAAS* **2**, 31–36.
- Williams, R. C., Barnett, A. H., Claffey, N., Davis, M., Gadsby, R., Kellett, M., Lip, G. Y. & Thackray, S. (2008) The potential impact of periodontal disease on general health: a consensus view. *Current Medical Research and Opinion* **24**, 1635–1643.

## Address:

Aurigena A. Araújo  
Departamento de Biofísica e Farmacologia,  
Centro de Biociências/UFRN. Av. Senador  
Salgado Filho, S/N, Campus Universitário,  
Lagoa Nova, 59072-970 Natal, RN  
Brazil

E-mail: aurigena@ufrnet.br

### Clinical Relevance

*Scientific rationale for the study:* Improved knowledge and better elucidation of the host mechanisms that participate in the pathogenesis of periodontal disease have led to the proposal of novel agents aimed at modulating the host response by inhibiting inflammatory mediators. Telmisartan (TELM), an angiotensin II receptor blocker (ARB), has been implicated as an anti-inflammatory agent that suppresses the tumour necrosis factor (TNF)- $\alpha$ -

induced activation of nuclear factor (NF)- $\kappa$ B in vascular endothelial cells.

*Principal findings:* We found that treatment with 10 mg/kg TELM resulted in reduced concentrations of MPO, MDA ( $p < 0.05$ ) and the proinflammatory cytokine IL-1 $\beta$  ( $p < 0.05$ ); reduced expression of MMP-2, MMP-9, RANK, RANKL and COX-2; an increase of OPG. TNF- $\alpha$  levels were significantly reduced in all TELM-treated groups. These findings confirm the involvement of telmisartan in reducing

the inflammatory response, oxidative stress and bone loss in experimental rat periodontitis.

*Practical implications:* Given the extensive use of anti-hypertensive drugs, combined with the fact that periodontal disease affects adults and the elderly, we decided to investigate the effect of TELM in reducing the risk for periodontal disease, confirmed by low levels of proinflammatory markers and by analysing markers of tissue destruction and bone remodelling.