



RESEARCH ARTICLE

The use of collagen matrix (Ologen) as a patch graft in glaucoma tube shunt surgery, a retrospective chart review [version 1; referees: 2 approved, 1 approved with reservations]

John D. Stephens, Steven R. Sarkisian, Jr.

Dean McGee Eye Institute, University of Oklahoma School of Medicine, Oklahoma City, OK, 73126-0901, USA

v1 First published: 01 Aug 2016, 5:1898 (doi: [10.12688/f1000research.9232.1](https://doi.org/10.12688/f1000research.9232.1))
 Latest published: 01 Aug 2016, 5:1898 (doi: [10.12688/f1000research.9232.1](https://doi.org/10.12688/f1000research.9232.1))

Abstract

Purpose: To determine the safety and efficacy of collagen matrix as a patch graft in glaucoma drainage surgery. Collagen matrix grafts may be advantageous because they do not need to be harvested from human donors.
Methods: An institutional, retrospective review of 43 patients with at least 12 months follow-up status post-glaucoma drainage implant surgery were evaluated for signs of tube erosion after initial placement of collagen matrix patch graft.
Results: Forty-one of 43 eyes (95.3%) required no intervention for patch graft melting with tube erosion. Average time of follow-up was 32 months (range: 12-45). Two cases had tube erosion at 4 months and 26 months post-op requiring tube revision, which was successfully revised with conjunctiva (4 month erosion) and donor sclera (26 month erosion).
Conclusion: Our results suggest that collagen matrix patch grafts may be used successfully as a patch graft in glaucoma tube shunt surgery, and may be advantageous because they do not have to be harvested from human donors. It is possible that exposure rates may be higher after longer follow-up and with larger numbers of patients. Further research is needed to compare Ologen to traditional graft materials to conclusively determine the safety and efficacy of collagen matrix as a novel patch graft material.

Open Peer Review

Referee Status:

	Invited Referees		
	1	2	3
version 1 published 01 Aug 2016	 report	 report	 report
1	Nils Loewen , University of Pittsburgh USA, Yalong Dang , University of Pittsburgh USA		
2	Arsham Sheybani , Washington University in St. Louis USA, Ankur Sudhir Gupta , Washington University in St. Louis USA, Bliss O'Bryhim , Washington University in St. Louis USA		
3	Nathan M. Radcliffe , New York University (NYU) USA		

Discuss this article

Comments (0)

Corresponding author: John D. Stephens (john.stephens@jefferson.edu)

How to cite this article: Stephens JD, Sarkisian and Jr. SR. **The use of collagen matrix (Ologen) as a patch graft in glaucoma tube shunt surgery, a retrospective chart review [version 1; referees: 2 approved, 1 approved with reservations]** *F1000Research* 2016, 5:1898 (doi: [10.12688/f1000research.9232.1](https://doi.org/10.12688/f1000research.9232.1))

Copyright: © 2016 Stephens JD and Sarkisian, Jr. SR. This is an open access article distributed under the terms of the [Creative Commons Attribution Licence](#), which permits unrestricted use, distribution, and reproduction in any medium, provided the original work is properly cited. Data associated with the article are available under the terms of the [Creative Commons Zero "No rights reserved" data waiver](#) (CC0 1.0 Public domain dedication).

Grant information: This paper was funded in part by Research to Prevent Blindness.

The funders had no role in study design, data collection and analysis, decision to publish, or preparation of the manuscript.

Competing interests: Dr. Sarkisian is a consultant for Alcon, Aeon Astron, Beaver Vistec, InnFocus, Sight Sciences, New World Medical, and Ellex He is currently receiving research grants from Alcon, Aeon Astron, Aerie, Transcend, Glaukos, and is a lecturer for Alcon.

First published: 01 Aug 2016, 5:1898 (doi: [10.12688/f1000research.9232.1](https://doi.org/10.12688/f1000research.9232.1))

Introduction

The use of glaucoma drainage implants to treat difficult glaucoma cases has increased in the past two decades¹. These devices drain aqueous through a silicone tube to a reservoir plate covered by Tenon's capsule and conjunctiva. The tube is then covered by one of several materials to prevent exposure to the overlying conjunctiva. Although most complications are transient and self-limited, glaucoma drainage procedures carry the risk of persistent corneal edema, tube erosion, endophthalmitis/blebitis, and tube migration, among other complications². Tube shunts in particular carry the risk of patch graft thinning and exposure of the subconjunctival portion of the shunt tube, which is a risk factor for infectious endophthalmitis^{3,4}. Prompt identification and revision of exposed patch grafts with collagenous human autograft or allograft material is therefore recommended⁵.

Several patch graft materials have been used. These include pericardium, fascia lata, cornea, sclera, and amniotic membrane^{6,7}. Ologen (Aeon Astron Europe BV, Leiden, the Netherlands) is a porcine-derived biodegradable collagen matrix implant which has been studied and used as an adjunct to trabeculectomy^{8,9}. A recent case report showed successful use of Ologen as a patch before closing the conjunctiva in a case of tube erosion¹⁰. To our knowledge, Ologen has not been used as a primary patch graft in glaucoma tube shunt procedures. Collagen matrix may be advantageous because it does not need to be harvested from human donors and is less expensive than other patch graft materials. This is particularly important considering that Medicare (the federal health insurance program for people who are 65 or older, medicare.gov) now no longer reimburses for any patch graft material when combined with a tube shunt procedure (former CPT code 67255). Additionally, Ologen appears clear under the conjunctiva and provides improved cosmesis compared to other patch grafts (Figure 1, printed with

permission courtesy of Steven R. Sarkisian, jr.). The purpose of this study was to determine the safety and efficacy of collagen matrix as a patch graft in glaucoma tube shunt surgery.

Materials and methods

This study was approved and monitored by the Institutional Review Board at the University of Oklahoma Health Science Center (IRB# 3425; reference #652312). Permission to publish clinical details and images was obtained for each subject. Potential subjects were identified by reviewing case logs of a single attending surgeon (S.R.S.). Charts of consecutive patients undergoing glaucoma tube shunt surgery with placement of collagen matrix patch graft between July 2009 and December 2010 were reviewed. Charts were excluded if the patient had less than 12 months of follow-up data. Forty-three eyes of 40 patients were identified. Demographic and clinical information of the patients is listed in Table 1. The primary outcome measure of this study was post-operative tube exposure requiring revision.

Table 1. Demographic and Clinical Information.

Age (+/- SD)	63 (+/- 20)
Gender	
Male	20
Female	23
Ethnicity	
Caucasian	23
African American	7
Native American	7
Hispanic	1
Not identified	5
Diagnosis	
Primary open angle glaucoma (POAG)	28
Non-POAG	15
Quadrant	
Superotemporal	40
Inferonasal	3
Type of tube shunt	
Ahmed	37
Barveldt	6
Tube location	
Anterior chamber	37
Sulcus	5
Pars plana	1
Average months of follow up	32 (range 12-45)

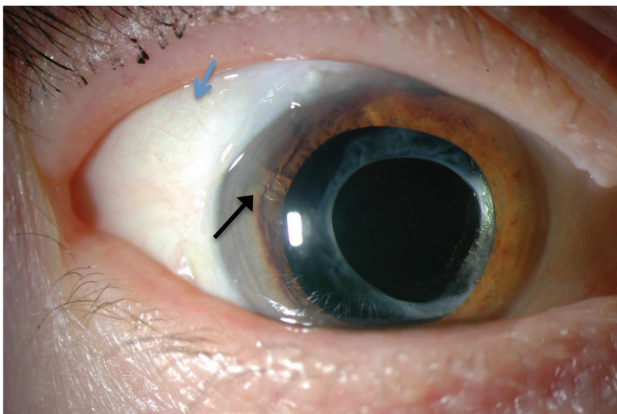


Figure 1. Slit lamp photo demonstrating cosmesis of Ologen patch graft. Black arrow: tube in anterior chamber. Blue arrow: Ologen patch graft.

Surgical technique

The glaucoma drainage implant of choice was placed in the usual fashion¹¹. Once the tube was secured to the sclera, the collagen patch graft was used to cover the tube (Figure 2). The Ologen to cover a tube comes as a 10×10×2 mm sheet. Presoaking the collagen is not necessary and is, in fact discouraged because once wet, the collagen becomes difficult to cut and can tear easily. While dry, the collagen sheet was cut to size to cover the tube per the surgeon's preference. Although some surgeons may desire to suture the collagen in place, we find this unnecessary as the collagen quickly picks up moisture from the scleral bed, does not slide out of place easily and never moves post-operatively once the conjunctiva is closed. However, great care is taken to ensure that the collagen is fully covered and the conjunctiva covering it is not under tension. Every effort must be made to be certain there is no chance that any part of the collagen is exposed and the conjunctiva is well secured. Once the conjunctiva was closed, a small amount of saline was placed in the anterior chamber and a fluorescein strip was used to verify the absence of leakage.

Results

A brief summary of results is displayed in Table 2. Forty-one of 43 (95.4%) eyes with Ologen patch graft required no intervention for patch graft melting with tube erosion. The average time of follow-up was 32 months (range 12–45 months). Two cases had tube erosion requiring revision. These occurred at 4 months and 26 months post-operatively. The first patient was an 86-year-old Caucasian woman with open angle glaucoma and a history of iritis. She had partial exposure of the patch graft after 1 week and full exposure at 4 months. She underwent successful tube revision with conjunctiva for a total

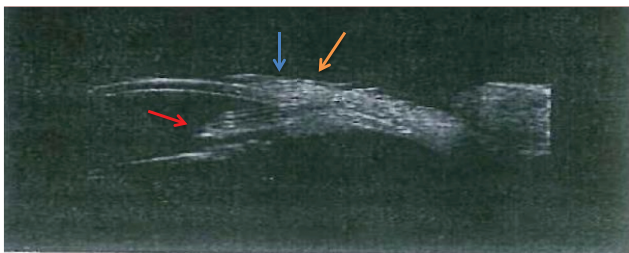


Figure 2. Ultrasound biomicroscopy taken three years post-operatively of tube shunt with Ologen patch graft. Red arrow: tube in anterior chamber. Blue arrow: conjunctiva over patch graft. Orange arrow: Ologen patch graft.

Table 2. Summary of results.

Number of eyes	43
Tube erosions (%)	2 (4.7%)
Average time to erosion	15 months (2 months, 36 months)
Successful revision	2/2 (100%)
Average time of follow up	32 months (range 12–45 months)

follow up of 32 months. The second erosion occurred in a 74-year-old Caucasian woman with open angle glaucoma and long-standing diabetes mellitus. The erosion occurred at 26 months and was successfully repaired with donor sclera for a total follow up of 32 months. Neither patient developed signs of endophthalmitis during their clinical course. Both of these patients had Ahmed valves placed in the superotemporal quadrant. One patient in this study, a 63-year-old man with open angle glaucoma, developed partial tube exposure on post-operative day 10 but did not require revision. He underwent placement of Baerveldt shunt in the inferonasal quadrant.

Dataset 1. The use of collagen matrix (Ologen) as a patch graft in glaucoma tube shunt surgery, a retrospective chart review data spreadsheet

<http://dx.doi.org/10.5256/f1000research.9232.d130894>

Collagen matrix patch graft data are provided in a spreadsheet. Description of the dataset is provided in the text file.

Discussion

To our knowledge, no study has investigated the use of collagen matrix material as a primary patch graft in glaucoma tube shunt surgery. Previous studies have reported rates of patch graft erosion. Gedde *et al.* reported tube erosion in five of 107 eyes (4.6%) in the tube versus trabeculectomy study at 5 years of follow-up¹¹. In a study of 702 patients, Levinson *et al.* reported an exposure rate of 5.8% at a mean follow up of 36 months¹². Additionally, Muir *et al.* reported an exposure rate of 6.2% in 1073 patients followed for an average of 41 months¹³. The erosion rate in our study, 4.7%, is comparable to these previous studies.

Several factors may predispose patients to patch graft erosion. In a cohort study of 121 eyes, Koval *et al.* identified Hispanic ethnicity, neovascular glaucoma, previous trabeculectomy, and combined surgery as potential risk factors for tube shunt exposure¹⁴. In the aforementioned study by Muir *et al.*, female gender and white race were associated with an increased risk of graft exposure. Uveitis, diabetes, and type of tube shunt were not associated with increased risk¹³. Mechanical and immunologic factors may also contribute to graft erosion¹⁵. Both of the patients with graft erosion in our study had histories suggestive of poor wound healing and/or ocular inflammation. One had long-standing diabetes mellitus without a diagnosis of neovascular glaucoma. The second patient with erosion in our study had a history of iritis.

Ologen encapsulates when not exposed to aqueous and does not biodegrade. It is possible that the patch graft erosions in our study occurred because the Ologen was exposed and not well-covered initially, leading to patch melting. Care must be taken to not use Ologen if the conjunctiva is under tension when it is closed.

There are several limitations to this study. First, given its relatively small sample size and limited duration, further studies are necessary to determine the safety and efficacy of Ologen collagen matrix patch grafts compared to other commonly used materials. There are inherent limitations in a retrospective chart review, including lack of randomization of patients, lack of comparative control group and incomplete follow-up by patients not reviewed

for this study. A prospective, large, controlled study is needed to compare erosion rates of Ologen to other graft materials. It is possible that collagen matrix patch grafts may be used successfully in glaucoma tube shunt surgery. They may be advantageous because they do not need to be harvested from human donors, are less expensive, and provide improved cosmesis compared to other commonly used materials. Further study is required to evaluate the long-term use of Ologen as a patch graft.

Data availability

F1000Research: Dataset 1. The use of collagen matrix (Ologen) as a patch graft in glaucoma tube shunt surgery, a retrospective chart review data spreadsheet. [10.5256/f1000research.9232.d130894](https://doi.org/10.5256/f1000research.9232.d130894)¹⁶

Ethical considerations

This study was approved and monitored by the Institutional Review Board at the University of Oklahoma Health Science Center (IRB# 3425; reference #652312). Permission to publish clinical details and images was obtained for each subject.

Author contributions

SRS conceived the study and performed the procedures reviewed in this study. JS carried out the research, analyzed the results, and prepared the first draft of the manuscript. JDS and SRS were involved in the revision of the draft and manuscript and have agreed to the final content.

Competing interests

Dr. Sarkisian is a consultant for Alcon, Aeon Astron, Beaver Vistec, InnFocus, Sight Sciences, New World Medical, and Ellex He is currently receiving research grants from Alcon, Aeon Astron, Aerie, Transcend, Glaukos, and is a lecturer for Alcon.

Grant information

This paper was funded in part by Research to Prevent Blindness.

The funders had no role in study design, data collection and analysis, decision to publish, or preparation of the manuscript.

References

- Gedde SJ, Schiffman JC, Feuer WJ, *et al.*: **Treatment outcomes in the tube versus trabeculectomy study after one year of follow-up.** *Am J Ophthalmol.* 2007; **143**(1): 9–22.
[PubMed Abstract](#) | [Publisher Full Text](#)
- Gedde SJ, Scott IU, Tabandeh H, *et al.*: **Late endophthalmitis associated with glaucoma drainage implants.** *Ophthalmology.* 2001; **108**(7): 1323–1327.
[PubMed Abstract](#) | [Publisher Full Text](#)
- Gedde SJ, Herndon LW, Brandt JD, *et al.*: **Surgical complications in the Tube Versus Trabeculectomy Study during the first year of follow-up.** *Am J Ophthalmol.* 2007; **143**(1): 23–31.
[PubMed Abstract](#) | [Publisher Full Text](#)
- Krebs DB, Liebman JM, Ritch R, *et al.*: **Late infectious endophthalmitis from exposed glaucoma setons.** *Arch Ophthalmol.* 1992; **110**(2): 174–175.
[PubMed Abstract](#) | [Publisher Full Text](#)
- Kalenak JW: **Revision for exposed anterior segment tubes.** *J Glaucoma.* 2010; **19**(1): 5–10.
[PubMed Abstract](#) | [Publisher Full Text](#)
- Smith MF, Doyle JW, Ticmey JW Jr: **A comparison of glaucoma drainage implant tube coverage.** *J Glaucoma.* 2002; **11**(2): 143–147.
[PubMed Abstract](#) | [Publisher Full Text](#)
- Anand A, Sheha H, Teng CC, *et al.*: **Use of amniotic membrane graft in glaucoma shunt surgery.** *Ophthalmic Surg Lasers Imaging.* 2011; **42**(3): 184–189.
[PubMed Abstract](#) | [Publisher Full Text](#)
- Johnson MS, Sarkisian SR Jr: **Using a collagen matrix implant (Ologen) versus mitomycin-C as a wound healing modulator in trabeculectomy with the EXPRESS mini glaucoma device: a 12-month retrospective review.** *J Glaucoma.* 2014; **23**(9): 649–52.
[PubMed Abstract](#) | [Publisher Full Text](#)
- Dada T, Kusumesh R, Bali SJ, *et al.*: **Trabeculectomy with combined use of subconjunctival collagen implant and low-dose mitomycin C.** *J Glaucoma.* 2013; **22**(8): 659–62.
[PubMed Abstract](#) | [Publisher Full Text](#)
- Rosentreter A, Schild AM, Dinslage S, *et al.*: **Biodegradable implant for tissue repair after glaucoma drainage device surgery.** *J Glaucoma.* 2012; **21**(2): 76–78.
[PubMed Abstract](#)
- Christakis PG, Tsai JC, Zurakowski D, *et al.*: **The Ahmed Versus Baerveldt study: design, baseline patient characteristics, and intraoperative complications.** *Ophthalmology.* 2011; **118**(11): 2172–9.
[PubMed Abstract](#) | [Publisher Full Text](#)
- Gedde SJ, Herndon LW, Brandt JD, *et al.*: **Postoperative complications in the Tube Versus Trabeculectomy (TVT) study during five years of follow-up.** *Am J Ophthalmol.* 2012; **153**(5): 804–814.e1.
[PubMed Abstract](#) | [Publisher Full Text](#) | [Free Full Text](#)
- Levinson JD, Giangiacomo AL, Beck AD, *et al.*: **Glaucoma drainage devices: risk of exposure and infection.** *Am J Ophthalmol.* 2015; **160**(3): 516–521.e2.
[PubMed Abstract](#) | [Publisher Full Text](#) | [Free Full Text](#)
- Muir KW, Lim A, Stinnett S, *et al.*: **Risk factors for exposure of glaucoma drainage devices: a retrospective observational study.** *BMJ Open.* 2014; **4**(5): e004560.
[PubMed Abstract](#) | [Publisher Full Text](#) | [Free Full Text](#)
- Koval MS, El Sayyad FF, Bell NP, *et al.*: **Risk factors for tube shunt exposure: a matched case-control study.** *J Ophthalmol.* 2013; **2013**:1–5, 196215.
[PubMed Abstract](#) | [Publisher Full Text](#) | [Free Full Text](#)
- Stephens J, Sarkisian SR Jr: **Dataset 1 in: The Use of Collagen Matrix (Ologen) as a Patch Graft in Glaucoma Tube Shunt Surgery, a Retrospective Chart Review.** *F1000Research.* 2016.
[Data Source](#)

Open Peer Review

Current Referee Status:



Version 1

Referee Report 01 February 2017

doi:10.5256/f1000research.9936.r19745



Nathan M. Radcliffe

Department of Ophthalmology, School of Medicine, New York University (NYU), New York, NY, USA

The authors provide a useful report on the practice of replacing a human allograft cornea, sclera, or pericardial graft with porcine collagen matrix (Ologen) to cover the tube entry site during glaucoma drainage device placement. The authors give a reasonable rationale for the use of collagen, namely cosmesis, cost and the ability to avoid transplanted human tissue. It should be noted that porcine material is not for everyone, and the use of this material should be discussed with patients prior to placement. The strengths of the study are a reasonable follow up duration and a sufficient number of patients, given that this is the first report of this surgical modification. I say that this number is reasonable, because after 40 cases of a new technique, it is appropriate for the surgeon to pause, carefully analyze the experience, and report the results to the scientific community.

The limitations of the study include its retrospective nature and the lack of a control arm. A greater number of patients would include the power of the study, and any future reports on this topic would do well to include more patients. The authors provide adequate support from the literature that a roughly 5% tube erosion rate, as was seen in this study, is the standard.

Another limitation of this study relates to the fact that there is a growing body of evidence that glaucoma tube shunt surgery may be safely performed without the use of any patch graft material. Using a long scleral tunnel needle technique, Oscar Albis and colleagues¹ reported a 0% erosion rate in 106 Mexican children followed after Ahmed valve placement with no patch graft. The mean follow up was just over two years, no patients were followed for less than six months and some were followed for up to eight years. While this data is encouraging, the reality of the situation is that in the United States, many surgeons are still using patch graft materials, and these materials do have problems, cosmesis and cost being among them. I applaud the authors for making a valuable contribution to the surgical literature and for answering a straightforward but important question: is it reasonable to substitute collagen matrix for other graft materials in glaucoma drainage device surgery? Yes.

References

1. Albis-Donado O, Gil-Carrasco F, Romero-Quijada R, Thomas R: Evaluation of Ahmed glaucoma valve implantation through a needle-generated scleral tunnel in Mexican children with glaucoma. *Indian J Ophthalmol.* **58** (5): 365-73 [PubMed Abstract](#) | [Publisher Full Text](#)

I have read this submission. I believe that I have an appropriate level of expertise to confirm that it is of an acceptable scientific standard.

Competing Interests: No competing interests were disclosed.

Referee Report 09 August 2016

doi:10.5256/f1000research.9936.r15561



Arsham Sheybani, Bliss O'Bryhim, Ankur Sudhir Gupta

Department of Ophthalmology and Visual Sciences, School of Medicine, Washington University in St. Louis, St. Louis, MO, USA

"The Use of Collagen Matrix As a Patch Graft in Glaucoma" is a well designed study on the use of Ologen as a primary graft in glaucoma shunt surgery. The title is appropriate, though it may benefit from the inclusion of the word "primary" (... "as a primary patch graft") to distinguish it from other publications on the use of Ologen as a patch graft. The method and analysis are well explained.

Although not the primary intent of the study, additional statistical analysis would be useful. This would include reporting the mean change in IOP and medication use post-operatively. While we do not expect that grafts would affect IOP or medication use, data showing IOP reductions could be useful in drawing this conclusion. Reporting the number of previous surgeries on the study eyes and eyelids may elucidate root causes for complications. At present, the supplemental data included only describes surgeries and procedures that occurred after the initial tube placement.

The conclusions are sensible and justified; however, they do not address whether use of Ologen in any way alters the mechanics of the glaucoma surgery and subsequent IOP management - which again we do not expect. Furthermore, this study describes the use and results of Ologen in one surgeon's hands. It is possible that results could be different in alternative surgical techniques that may differ in tunnel length and closure.

As identified by the authors in the discussion, the major limitations of this paper are its small study size and its lack of comparison to other grafts. However it does present a novel method for covering tubes - timely given the shift of glaucoma to a surgical disease. This article serves as a straightforward and succinct study that justifies further investigation and a more robust sub-group analysis.

Overall, this article is in line with the requirements of F1000Research and we support its approval.

We have read this submission. We believe that we have an appropriate level of expertise to confirm that it is of an acceptable scientific standard.

Competing Interests: No competing interests were disclosed.

Referee Report 08 August 2016

doi:10.5256/f1000research.9936.r15375



Nils Loewen , Yalong Dang

Department of Ophthalmology, School of Medicine, University of Pittsburgh, Pittsburgh, PA, USA

Ologen is an FDA approved biodegradable collagen matrix that can be used in trabeculectomy to maintain the bleb space and modulate wound healing^{1,2} and repair of scleral defects³. No lyophilized or prepared donor tissue is required which potentially has cost, safety, storage and standardization advantages. The authors are likely some of the most experienced surgeons worldwide with this material and need to be commended for sharing their experience and insight. In this retrospective study, Stephens *et al* evaluated the outcomes of this porcine derived biodegradable collagen matrix as a patch graft in tube shunt surgery. The authors found that 2 eyes out of 43 had tube erosion and required further surgical interventions. Both patients had a history of poor wound healing or ocular inflammation increasing the risk of erosion. It is intriguing that the rate of erosion is lower, 4.7%, compared to other materials or at least similar (indicating non-inferiority).

This first description of Ologen as a tube patch material is interesting and useful and might standardize tube shunt surgeries while avoiding human donor tissue.

I believe this already good manuscript can be made more useful by adding the following:

1. Can the authors please report the IOP data before and after surgery as well as number of medications?
2. Power calculation: approximately how many patients would be needed to show that ologen is better than the reported rates for other materials? While not critical it is possible that the patient number is large enough to make this statement and if not, at least non-inferiority is likely. In my opinion, is not a critical issue that should not prevent this article from being approved.
3. Ologen handling: the authors are extremely experienced with how ologen behaves and a description in the discussion would be helpful for less experienced surgeons. I recall the first generations looked like lifesaver rings but later became less rigid plates or circles?
4. Rosentreter *et al* published 2 papers using Ologen to repair the erosion of tube shunt⁴ or to modulate wound healing and bleb encapsidation after GDD surgery⁵. However, in the both studies, Ologen implantation was applied several months after the primary surgery. In the second study, the success rate of the Ologen group was significant lower than the controls (only MMC and capsule excision), indicating this collagen graft might affect the post-surgery intraocular pressure. Could authors please share their thoughts about this in the Discussion? This is mostly likely a result of patient cohort under study (i.e. scar formers).
5. Do the authors use the same postoperative medications with Ologen or can steroids be tapered sooner? Would combining Ologen with a scleral patch make sense in select patients?
6. Could Ologen improve the IOP if placed around the plate to modify encapsidation?
7. What is the authors' currently preferred practice pattern for tube shunts, scleral patch or Ologen? Or in other words, how do the authors decide when to use Ologen over a scleral patch graft.

References

1. El-Saied HM, Abdelhakim MA: Trabeculectomy with ologen in secondary glaucomas following failed trabeculectomy with MMC: comparative study. *Eye (Lond)*. 2016. [PubMed Abstract](#) | [Publisher Full Text](#)
2. Cillino S, Di Pace F, Cillino G, Casuccio A: Biodegradable collagen matrix implant vs mitomycin-C as an adjuvant in trabeculectomy: a 24-month, randomized clinical trial. *Eye (Lond)*. 2011; **25** (12): 1598-606 [PubMed Abstract](#) | [Publisher Full Text](#)

3. Cho CH, Lee SB: Biodegradable collagen matrix (Ologen™) implant and conjunctival autograft for scleral necrosis after pterygium excision: two case reports. *BMC Ophthalmol.* 2015; **15**: 140 [PubMed Abstract](#) | [Publisher Full Text](#)
4. Rosentreter A, Schild AM, Dinslage S, Dietlein TS: Biodegradable implant for tissue repair after glaucoma drainage device surgery. *J Glaucoma.* 2012; **21** (2): 76-8 [PubMed Abstract](#) | [Publisher Full Text](#)
5. Rosentreter A, Mellein AC, Konen WW, Dietlein TS: Capsule excision and Ologen implantation for revision after glaucoma drainage device surgery. *Graefes Arch Clin Exp Ophthalmol.* 2010; **248** (9): 1319-24 [PubMed Abstract](#) | [Publisher Full Text](#)

We have read this submission. We believe that we have an appropriate level of expertise to confirm that it is of an acceptable scientific standard, however we have significant reservations, as outlined above.

Competing Interests: No competing interests were disclosed.
