

Effects of Surgical Ventricular Restoration on Left Ventricular Shape, Size, and Function for Left Ventricular Anterior Aneurysm

Yao Wang, Chang-Qing Gao, Gang Wang, Yan-Song Shen

Department of Cardiovascular Surgery, Chinese People's Liberation Army General Hospital, Beijing 100853, China

Abstract

Background: Surgical ventricular restoration (SVR) has been performed to treat left ventricular (LV) aneurysm. However, there is limited analysis of changes in LV shape. This study aimed to evaluate the changes in LV shape induced by SVR and the effects of SVR on LV size and function for LV aneurysm.

Methods: Between April 2006 and March 2015, 18 patients with dyskinetic (dyskinetic group) and 12 patients with akinetic (akinetic group) postinfarction LV anterior aneurysm receiving SVR with the Dor procedure at Chinese People's Liberation Army General Hospital were enrolled in this study. A retrospective analysis was carried out using data from the echocardiography database. LV shape was analyzed by calculating the apical conicity index (ACI). LV end-diastolic volume index, end-systolic volume index, and ejection fraction (EF) were measured. One-way analysis of variance was used to compare means at different time points within each group.

Results: Within one week after SVR, LV shape became more conical in the two groups (ACI decreased from 0.84 ± 0.13 to 0.69 ± 0.11 [$t = 5.155$, $P = 0.000$] in dyskinetic group and from 0.73 ± 0.07 to 0.60 ± 0.11 [$t = 2.701$, $P = 0.026$] in akinetic group; LV volumes were decreased significantly and became closer to normal values and EF was improved significantly in the two groups). On follow-up at least one year, LV shape remained unchanged in dyskinetic group (ACI increased from 0.69 ± 0.11 to 0.74 ± 0.12 , $t = -1.109$, $P = 0.294$), but became more spherical in akinetic group (ACI significantly increased from 0.60 ± 0.11 to 0.75 ± 0.11 , $t = -1.880$, $P = 0.047$); LV volumes remained unchanged in dyskinetic group, but increased significantly in akinetic group and EF remained unchanged in the two groups.

Conclusions: SVR could reshape LV to a more conical shape and a more normal size and improve LV function significantly early after the procedure in patients with dyskinetic or akinetic postinfarction LV anterior aneurysm. However, LV tends to be more spherical and enlarged in the akinetic group on at least 1-year follow-up.

Key words: Cardiac Aneurysm; Echocardiography; Left Ventricle Remodeling; Left Ventricular Function; Surgery

INTRODUCTION

Left ventricular (LV) aneurysm is a common complication of myocardial infarction.^[1] The cardiac shape and size following postinfarction LV anterior aneurysm develop an enlarged spherical configuration due to postinfarction LV remodeling.^[2] The anterior-apical region is a particularly vulnerable segment of the LV for expansion because it is the thinnest and has the greatest curvature.^[3,4]

Surgical ventricular restoration (SVR) with different techniques has been performed to treat LV aneurysm.^[5-9] In 1985, Dor introduced an original surgical technique, endoventricular circular patch plasty repair (the Dor procedure), to improve geometric reconstruction with respect

to standard linear repair in LV aneurysm.^[6,10] A marked improvement in LV volume and pump function early after SVR with the Dor procedure has been reported in patients with postinfarction LV anterior aneurysm.^[11] However, there is limited detailed analysis of changes in LV shape at the apical level. Efforts to assess LV shape were made by

Address for correspondence: Prof. Chang-Qing Gao, Department of Cardiovascular Surgery, Chinese People's Liberation Army General Hospital, Beijing 100853, China
E-Mail: gcq.cvs301@hotmail.com

This is an open access article distributed under the terms of the Creative Commons Attribution-NonCommercial-ShareAlike 3.0 License, which allows others to remix, tweak, and build upon the work non-commercially, as long as the author is credited and the new creations are licensed under the identical terms.

For reprints contact: reprints@medknow.com

© 2017 Chinese Medical Journal | Produced by Wolters Kluwer - Medknow

Received: 19-12-2016 **Edited by:** Yuan-Yuan Ji

How to cite this article: Wang Y, Gao CQ, Wang G, Shen YS. Effects of Surgical Ventricular Restoration on Left Ventricular Shape, Size, and Function for Left Ventricular Anterior Aneurysm. Chin Med J 2017;130:1429-34.

Access this article online

Quick Response Code:



Website:
www.cmj.org

DOI:
10.4103/0366-6999.207467

global LV chamber analysis by the sphericity index (SI), which calculated LV short-to-long axis ratio.^[12] However, this analysis cannot detect LV shape changes at the apical level. To overcome this problem, a new apical conicity index (ACI) concept was introduced, which measured the apical-to-short axis ratio and can be useful to assess LV shape at the apical level induced by SVR.^[13,14] The present study was to assess the changes in regional LV shape induced by SVR and to evaluate the effects of SVR on LV size and function in patients with dyskinetic or akinetic postinfarction LV anterior aneurysm.

METHODS

Ethical approval

As a retrospective study and data analysis was performed anonymously, this study was exempt from the ethical approval and informed consent from patients according to the Ethical Guideline of Chinese People's Liberation Army (PLA) General Hospital.

Patients

A retrospective analysis was carried out on patients who underwent SVR with the Dor procedure, using data from the echocardiography database of the Department of Cardiovascular Surgery of Chinese PLA General Hospital. From April 2006 to March 2015, a total of 76 patients with postinfarction LV anterior aneurysm underwent SVR with the Dor procedure at Chinese PLA General Hospital. The indications for the operation were angina pectoris, congestive heart failure, or a combination of these symptoms. During SVR, the ventricular wall was closed using an endoventricular patch in thirty patients (40%) and direct ventriculotomy closure in the remaining 46 patients (60%). The thirty patients with the use of an endoventricular patch formed the study cohort of this analysis. Of the thirty patients, LV aneurysm was defined as dyskinetic in 18 patients (dyskinetic group) and akinetic in 12 patients (akinetic group) by ventriculography. We retrospectively analyzed all relevant medical record and echocardiographic data gathered prospectively for the analysis.

Coronary angiography and ventriculography

All patients underwent coronary angiography and ventriculography before operation using standard techniques. LV aneurysm was defined as a segment of the LV wall protruding from the expected outline of the ventricular chamber and displaying dyskinesia or akinesia.^[15]

Surgical procedure

All operations were performed by an experienced surgeon (Gao CQ). The procedures were conducted under cardiopulmonary bypass and aortic cross-clamping with crystalloid antegrade cardioplegia. Complete coronary artery bypass grafting (CABG) was first performed, almost always with the left internal mammary artery on the left anterior descending and sequential venous grafts on the right and circumflex arteries, when needed. After CABG was

completed, the LV was opened in the center of the depressed anterior area, produced by aspirating the vent catheter. The ventricular cavity was inspected and the thrombi, if present, were removed. The aortic cross-clamp was then released to allow the heart to start beat. In dyskinetic aneurysm, palpation of the LV muscle during its contraction allowed differentiation between scar and normal muscle. In akinetic aneurysm, the junction between scarred and normal muscle was not as clearly defined as in dyskinetic aneurysms. Through the open ventricle, the fibrous endocardial scar determined the border zone between the totally fibrous tissue and the beginning of muscular tissue. A continuous suture was placed at the junction of the scar and normal myocardium. The surgeon imaged what the LV would look like in the absence of an aneurysm and tightened the suture accordingly, to attain a more normal LV shape and size. A Dacron patch was then anchored inside the ventricle on this internal suture. Excluded areas were sutured above the patch.^[6,10]

Echocardiographic examinations and follow-up

Serial two-dimensional echocardiographic examinations were done by the same echocardiographer (Wang Y), using the same commercially available GE Vivid 7 Dimension Imaging System (GE Healthcare, Horten, Norway) equipped with M3S transducer or the Philips IE33 Ultrasound System (Philips Medical Systems, Andover, MA, USA) equipped with S5-1 transducer.

Preoperative echocardiography was performed within 1 week prior to the operation. LV shape was assessed by calculating the SI as the LV short-to-long axis ratio and the ACI as apical-to-short axis ratio in diastole.^[11] LV long axis (L) was measured in the apical four-chamber view (4CH) from the apex to the midpoint of the mitral valve and short axis (S) as the axis that perpendicularly intersects the midpoint of the long axis. From the same apical 4CH view, the diameter of the sphere that best fits the apex was measured as the apical axis (Ap).^[13] In healthy individuals, SI is 0.52 ± 0.06 and ACI is 0.60 ± 0.09 in diastole.^[14] By definition, a small value of SI or ACI implies a more conical LV, whereas values approaching 1 suggest a more spherical LV.

LV size and function were assessed by calculating LV volume and ejection fraction (EF). LV volume was measured using the biplane Simpson's method from the apical 4CH and 2CH views.^[16] LV end-diastolic and end-systolic volumes, indexed by body surface area (EDVI and ESVI, respectively), were calculated, and EF was calculated automatically by the following equation: $EF = (EDV - ESV)/EDV$. We consider $25\text{--}30 \text{ ml/m}^2$ for ESVI and $50\text{--}60 \text{ ml/m}^2$ for EDVI as normal values,^[17] and consider $62 \pm 5\%$ for EF as normal value.^[16]

Early postoperative echocardiography was performed within 1 week after the surgery. Echocardiographic follow-up was done at 6 and 12 months after the procedure through direct contact with patients at our outpatient clinic. Subsequent echocardiographic follow-up was done when clinically indicated. Late postoperative echocardiography was defined as follow-up for a minimum of 12 months after SVR. The

LV shape, size, and function were evaluated according to the same criteria as by preoperative echocardiography.

For precision, all measurements were done in triplicate and displayed as an average value. All the data were entered prospectively into database of our department.

Statistical analysis

Categorical variables were presented as number ratio or percentage (%). Continuous variables were expressed as mean \pm standard deviation, when the data were normally distributed. The normality of the distributions was tested with the Kolmogorov-Smirnov test. Comparisons of categorical variables between the groups were performed by Fisher's exact test or Chi-square test as appropriate. Comparisons of continuous variables between groups were performed by independent-samples *t*-test. One-way analysis of variance was used to compare the means at different time points within each group. *Post hoc* multiple comparisons with the least significant difference (equal variances assumed) or Tamhane's T2 (equal variances not assumed) method were used for two-by-two comparisons within each group. Homogeneity of variance was tested by Levene test. A $P < 0.05$ was considered statistically significant. All analyses were performed using SPSS for Windows version 18.0.1 (SPSS, Inc., Chicago, IL, USA).

RESULTS

Baseline characteristics

The baseline characteristics of the groups are summarized in Table 1.

Of the thirty patients, the left anterior descending artery was occluded or significantly narrowed in all but three patients in the dyskinetic group. Moreover, 13/18 patients in the dyskinetic group and 11/12 in the akinetic group had two- or three-vessel coronary disease. There were no significant differences between the two groups according to the analyzed parameters.

Preoperative left ventricular shape, size, and function

Before surgery, all the patients in both the dyskinetic and akinetic groups developed a spherical enlarged LV and

diminished LV function: ACI, EDVI, and ESVI were larger than normal values, and EF was smaller than normal value. There were no significant differences between the two groups for preoperative SI, EDVI, ESVI, and EF. However, ACI in the dyskinetic group was significantly larger than that in the akinetic groups, indicating that patients of the dyskinetic group produced a more spherical shape [Table 2 and Figures 1a, 2a].

Procedural outcomes

Myocardial revascularization was performed in 27 of 30 (90%) patients. The left internal mammary artery was used in 90% (27/30), and 18 of the 30 patients had saphenous vein grafts. The mean number of bypass grafts was 1.9 ± 1.1 per patient. The territory of the scar was revascularized in 15/18 patients of the dyskinetic group and in 12/12 of the akinetic group.

The in-hospital mortality was 3% (1/30). Of the thirty patients, one patient in the akinetic group died within the first 30 days. He suffered from cardiorespiratory arrest and died on the 10th day postoperatively.

Early postoperative left ventricular size, shape, and function

Early postoperative echocardiography data (within one week after SVR) were obtained in all the thirty patients [Table 3].

LV shape became more conical in the two groups [Figures 1b and 2b]. ACI significantly decreased from preoperative 0.84 ± 0.13 to 0.69 ± 0.11 ($t = 5.155$, $P = 0.000$) in the dyskinetic group and from 0.73 ± 0.07 to 0.60 ± 0.11 ($t = 2.701$, $P = 0.026$) in the akinetic group. However, SI had no significant change in the dyskinetic (0.58 ± 0.07 vs. 0.58 ± 0.13 , $t = -0.0004$, $P = 0.982$) and akinetic (0.63 ± 0.06 vs. 0.59 ± 0.07 , $t = 2.341$, $P = 0.482$) groups.

LV volumes in the two groups were decreased significantly and became closer to normal values. In the dyskinetic group, EDVI decreased from preoperative 115 ± 23 to 55 ± 10 ml/m² ($t = 11.325$, $P = 0.000$), and ESVI decreased from 80 ± 20 to 30 ± 6 ml/m² ($t = 11.759$, $P = 0.000$). In the akinetic group, EDVI decreased from 114 ± 22 to 56 ± 8 ml/m² ($t = 7.561$, $P = 0.000$), and ESVI decreased from 81 ± 24 to 29 ± 5 ml/m² ($t = 6.537$, $P = 0.000$).

Table 1: Baseline characteristics of patients with postinfarction left ventricular anterior aneurysm receiving SVR with the Dor procedure in the two study groups

Variable	Dyskinetic group (n = 18)	Akinetic group (n = 12)	Statistics	P
Age (years)	54.5 \pm 12.7	59.9 \pm 11.0	-1.206*	0.238
Male	15/18	12/12	2.222†	0.255
Months from first MI	32.6 \pm 44.6	41.9 \pm 59.8	-0.489*	0.629
NYHA class	3.1 \pm 0.5	3.3 \pm 0.3	-0.803*	0.429
VT	7/18	7/12	1.094†	0.296
Thrombus	5/18	2/12	0.497†	0.669
0- or 1-vessel disease	5/18	1/12	1.701†	0.358
2- or 3-vessel disease	13/18	11/12	1.701†	0.358
Left main	1/18	1/12	0.089†	1.000

Data are expressed as mean \pm SD for continuous variables and number ratio for categorical variables. **t* values, † χ^2 values. SVR: Surgical ventricular restoration; MI: Myocardial infarction; NYHA: New York Heart Association; VT: Ventricular tachycardia; SD: Standard deviation.

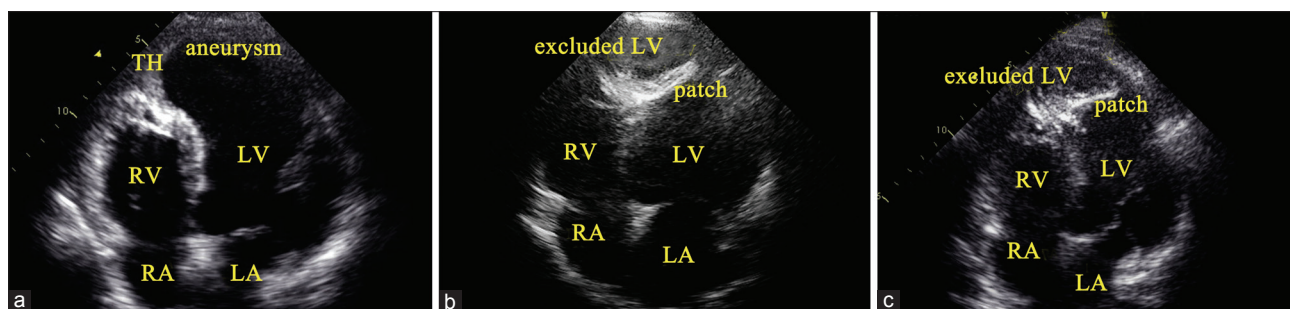


Figure 1: Patient with dyskinetic aneurysm: Pre- (a), early post- (b), and late post- operative (c) LV shape. Preoperative spherical LV became more conical 7 days after SVR and remained unchanged after 46-month follow-up. AN: Aneurysm; LA: Left atrium; LV: Left ventricular; RA: Right atrium; RV: Right ventricular; TH: Thrombus; SVR: Surgical ventricular restoration.

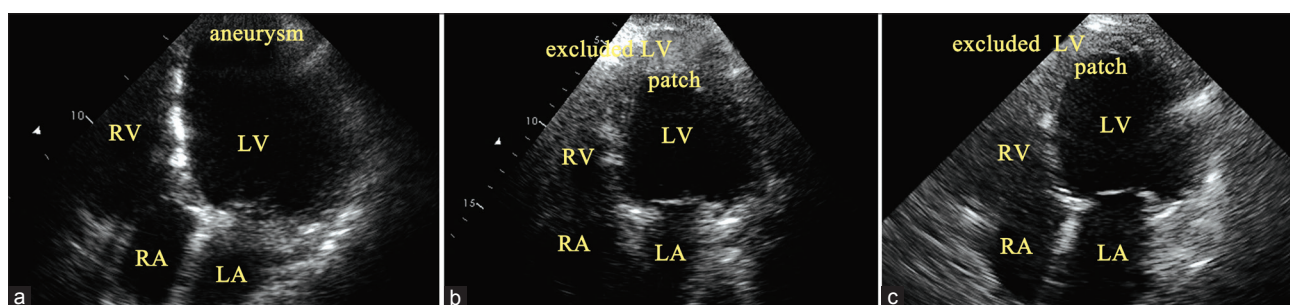


Figure 2: Patient with akinetic aneurysm: Pre- (a), early post- (b) and late post-operative (c) LV shape. Preoperative spherical LV became more conical 7 days after SVR and became more spherical after 60-month follow-up. AN: Aneurysm; LA: Left atrium; LV: Left ventricular; RA: Right atrium; RV: Right ventricular; SVR: Surgical ventricular restoration.

Table 2: Preoperative LV shape, size, and function of patients with postinfarction left ventricular anterior aneurysm receiving SVR with the Dor procedure in the two study groups

Variables	Dyskinetic group (n = 18)	Akinetic group (n = 12)	t	P
ACI	0.84 ± 0.13	0.73 ± 0.07	2.098	0.047
SI	0.58 ± 0.07	0.63 ± 0.06	-1.500	0.147
EDV (ml)	205 ± 46	209 ± 40	-0.262	0.795
ESV (ml)	142 ± 38	148 ± 42	-0.416	0.680
EDVI (ml/m ²)	115 ± 23	114 ± 22	0.093	0.927
ESVI (ml/m ²)	80 ± 20	81 ± 24	-0.142	0.889
EF (%)	31 ± 8	30 ± 7	0.428	0.672

Data are expressed as mean ± SD. ACI: Apical concavity index; EDV: End-diastolic volume; EDVI: End-diastolic volume index; EF: Ejection fraction; ESV: End-systolic volume; ESVI: End-systolic volume index; LV: Left ventricular; SI: Sphericity index; SD: Standard deviation; SVR: Surgical ventricular restoration.

LV function was improved significantly in the two groups. EF increased from preoperative 31 ± 8% to 46 ± 4% ($t = -8.676$, $P = 0.000$) in the dyskinetic group and from 30 ± 7% to 48 ± 5% ($t = -7.161$, $P = 0.000$) in the akinetic group.

Late postoperative left ventricular shape, size, and function

Late postoperative echocardiography data (at least 1 year after the procedure) were obtained in 14/18 patients in the dyskinetic group and 7/11 in the akinetic group [Table 3]. The follow-up extended from 12 to 113 months in the

dyskinetic group and from 13 to 82 months in the akinetic group. On follow-up at least 1 year, we observed that LV shape remained unchanged in the dyskinetic group, but became more spherical in akinetic group [Figures 1c and 2c]. ACI increased from early postoperative 0.69 ± 0.11 to 0.74 ± 0.12 ($t = -1.109$, $P = 0.294$) with no significance in the dyskinetic group and increased significantly in the akinetic group (0.60 ± 0.11 vs. 0.75 ± 0.11, $t = -1.880$, $P = 0.047$).

LV volumes remained unchanged in the dyskinetic group, but increased significantly in the akinetic group. In the dyskinetic group, EDVI increased from 55 ± 10 to 64 ± 15 ml/m² ($t = -1.938$, $P = 0.180$) and ESVI increased from 30 ± 6 to 34 ± 10 ml/m² ($t = -1.487$, $P = 0.391$). In the akinetic group, EDVI increased significantly from 56 ± 8 to 80 ± 25 ml/m² ($t = -2.918$, $P = 0.020$) and ESVI increased significantly from 29 ± 5 to 46 ± 18 ml/m² ($t = -3.091$, $P = 0.049$), respectively.

LV EF remained unchanged in the dyskinetic (46 ± 4% vs. 47 ± 6%, $t = -0.376$, $P = 0.975$) or the akinetic (48 ± 5%, vs. 43 ± 8%, $t = 1.723$, $P = 0.104$) group.

DISCUSSION

Preoperative left ventricular shape, size, and function

The present study showed that preoperative LV shape and size in patients with dyskinetic or akinetic postinfarction LV anterior aneurysm developed a spherical enlarged geometry, and LV function diminished. The results are similar to the previous study.^[14]

Table 3: Pre-, early post-, and late post-operative LV shape, size, and function of patients with postinfarction left ventricular anterior aneurysm receiving SVR with the Dor procedure in the two study groups

Variables	Dyskinetic group					Akinetic group				
	Preoperation (n = 18)	Early postoperative period (n = 18)	Late postoperative period (n = 14)	F	P	Preoperation (n = 12)	Early postoperative period (n = 12)	Late postoperative period (n = 7)	F	P
ACI	0.84 ± 0.13	0.69 ± 0.11*	0.74 ± 0.12	7.444	0.002	0.73 ± 0.07	0.60 ± 0.11*	0.75 ± 0.11 [†]	3.968	0.043
SI	0.58 ± 0.07	0.58 ± 0.13	0.63 ± 0.09	0.824	0.446	0.63 ± 0.06	0.59 ± 0.07	0.62 ± 0.17	0.274	0.764
EDV (ml)	205 ± 46	98 ± 19*	112 ± 27	53.349	0.000	209 ± 40	104 ± 14*	146 ± 46 [†]	26.190	0.000
ESV (ml)	142 ± 38	53 ± 12*	61 ± 19	61.800	0.000	148 ± 42	53 ± 9*	84 ± 33 [†]	27.072	0.000
EDVI (ml/m ²)	115 ± 23	55 ± 10*	64 ± 15	64.789	0.000	114 ± 22	56 ± 8*	80 ± 25 [†]	24.411	0.000
ESVI (ml/m ²)	80 ± 20	30 ± 6*	34 ± 10	72.859	0.000	81 ± 24	29 ± 5*	46 ± 18 [†]	25.061	0.000
EF (%)	31 ± 8	46 ± 4*	47 ± 6	33.691	0.000	30 ± 7	48 ± 5*	43 ± 8	22.840	0.000

Data are expressed as mean ± SD. **P*<0.05 versus preoperation; [†]*P*<0.05 versus early postoperative period. ACI: Apical conicity index; EDV: End-diastolic volume; EDVI: End-diastolic volume index; EF: Ejection fraction; ESV: End-systolic volume; ESVI: End-systolic volume index; LV: Left ventricular; SI: Sphericity index. SD: Standard deviation; SVR: Surgical ventricular restoration.

Myocardial infarcts, particularly large transmural infarcts, result in complex alterations in ventricular architecture involving both the infarcted and noninfarcted zones.^[3] The infarcted region would thin and elongate during the 1st h after myocyte necrosis, which may result in aneurysm formation. The anterior-apical region is a particularly vulnerable segment of the LV for expansion because it is the thinnest and has the greatest curvature. In the noninfarcted zone, the contractile segments of the LV elongated and the LV became more spherical in geometry. The further loss of cardiomyocytes contributes to progressive LV dilatation.^[3,18] The dilatation increases the stroke volume and temporarily improves the cardiac index (Starling law), but the increased wall tension has a detrimental effect on the myocardial contractility (Laplace law).^[17]

The LV remodeling can profoundly affect LV function. Normal LV shape and size exhibit a conical pattern. The spatial arrangements of this structural pattern are linked to a single helical ventricular myocardial band,^[18] which twisted on itself and curled in two helical loops: the basal loop contains predominantly horizontal fibers; the apical loop contains oblique fibers that make up of descending and ascending segments crossing each other around the apex.^[18] The LV shape and size following postinfarction LV anterior aneurysm develop a spherical enlarged configuration.^[19] The architecture of oblique apical loop fibers becomes more transverse and more closely resembles the horizontal fiber orientation of the basal loop.^[19] Within the intact heart, there is 15% fiber shortening of each myocyte. When heart muscle fibers adopt oblique fiber direction, the 15% fiber shortening causes a 60% EF. However, if fiber orientation is transverse, the same 15% fiber shortening produces only 30% EF.^[19] Hence, in a spherical enlarged LV, LV function diminishes.

Early postoperative left ventricular size, shape, and function

Our study demonstrates that early postoperative LV shape became more conical in the 2 groups: ACI significantly decreased, but SI had no significant change in the two groups; LV size was closer to normal and LV function was improved significantly in the two groups. The results are similar to that of the previous study.^[14]

The SVR permits reshaping LV to a more conical shape and normal size. For the Dor procedure, the rebuilding of the LV cavity is initiated using a continuous suture placed at the junction of the scar and normal myocardium, and the suture is tightened at the theoretical diastolic capacity of the patient LV (50–60 ml/m²) to attain a normal size of the LV.^[17] In addition, this endoventricular circular suture may restore the curvature of the myocardium to what it was before the infarct. A Dacron patch is then designed to the size of the opening of LV and sutured at the level of the circular suture, and thereby providing a more normal LV shape.^[17]

The LV apex is primarily involved in postinfarction LV anterior aneurysm so that the regional changes affect the anterior, septal, and inferior LV.^[13] The SI as the LV short-to-long axis ratio evaluates the entire LV chamber and fails to detect such regional apical abnormality. Conversely, the ACI as apical-to-short axis ratio may detect such abnormality.

There are specific factors that contribute to the increased EF associated with the SVR procedure in this group. In the patients with postinfarction LV aneurysm, by restoring LV into a more conical shape (ACI significantly decreased) and a more normal size (volume index closer to normal value), the normal helical configuration and a more normal fiber orientation were restored that could result in improved LV function.

Late postoperative left ventricular shape, size, and function

On follow-up at least 1 year, our study shows a significant increase in LV volume and a more spherical LV in the akinetic group. Our results are similar with the previous study.^[14]

The increase in LV volume and sphericity at follow-up in the akinetic group may be due to: (1) an excess of scarred ventricle salvaged. The Dor procedure for the repair of aneurysm depends on the identification of the junction between scar and normal myocardium,^[17] which is not always definitive and cannot be detected easily in patients with akinetic aneurysm,^[18] and therefore an excess of scarred LV may be salvaged; or (2) progressive LV remodeling. The scar is a critical trigger of the progressive LV remodeling,^[1] which ended with a dilatation of the noninfarcted area with a spherical shape;^[1] (3) scar rim patch attachment leaves a dilated remote muscle. The goal of the Dor procedure is directed toward excluding scar, which does not account for the progressive dilation of remote muscle resulted from postinfarction LV remodeling,^[1] and so more dilated remote muscle is retained.

Study limitations

Our study has some limitations. First, the present study was retrospective, which represents the major drawback of the study. Second, all measurements were obtained by 2DE. However, reference to preoperative patients evaluated with the same ultrasound views may allow a reliable data comparison. Finally, taking into account the relatively small sample size and the highly selected patients included in the study, our findings cannot be applied to the general LV aneurysm population.

Clinical implications and future research direction

It is commonly reported that the aim of SVR is to rebuild a more conical shape, but few studies have demonstrated that the LV is less spherical (i.e., more conical) postoperatively. This study evaluated the changes in LV shape induced by SVR and evaluated the effects of SVR on LV size and function in patients with postinfarction dyskinetic or akinetic LV anterior aneurysm. In our study, SVR with the Dor procedure demonstrated a beneficial effect on LV shape, size, and EF within 1 week after SVR, but LV tends to be more spherical and enlarged in the akinetic group on at least 1-year follow-up. In the future, we may increase sample size and extend the duration of follow-up.

Financial support and sponsorship

Nil.

Conflicts of interest

There are no conflicts of interest.

REFERENCES

1. Kutty RS, Jones N, Moorjani N. Mechanical complications of acute myocardial infarction. *Cardiol Clin* 2013;31:519-31, vii-viii. doi: 10.1016/j.ccl.2013.07.004.
2. Buckberg G, Athanasuleas C, Conte J. Surgical ventricular restoration

for the treatment of heart failure. *Nat Rev Cardiol* 2012;9:703-16. doi: 10.1038/nrcardio.2012.143.

3. Pfeffer MA, Braunwald E. Ventricular remodeling after myocardial infarction. Experimental observations and clinical implications. *Circulation* 1990;81:1161-72. doi: 10.1161/01.CIR.81.4.1161.
4. Pan LF, Ge DD, Wang XW, Zheng ZG, Zhou XC. Apical sphere ventricular aneurysm with severe endocardium calcification after old anterior myocardial infarction. *Chin Med J* 2015;128:849-50. doi: 10.4103/0366-6999.152693.
5. Cooley DA. Ventricular endoaneurysmorrhaphy: A simplified repair for extensive postinfarction aneurysm. *J Card Surg* 1989;4:200-5. doi: 10.1111/j.1540-8191.1989.tb00282.x.
6. Dor V, Saab M, Coste P, Kornaszewska M, Montiglio F. Left ventricular aneurysm: A new surgical approach. *Thorac Cardiovasc Surg* 1989;37:11-9. doi: 10.1055/s-2007-1013899.
7. Dor V. Surgery for left ventricular aneurysm. *Curr Opin Cardiol* 1990;5:773-80. doi: 10.1097/00001573-199012000-00009.
8. Dor V. Post myocardial infarction left ventricular dysfunction – Assessment and follow up of patients undergoing surgical ventricular restoration by the endoventricular patch plasty. *Indian Heart J* 2013;65:357-8. doi: 10.1016/j.ihj.2013.04.031.
9. Yang YJ, Huo Y, Xu YW, Wang JA, Han YL, Ge JB, *et al.* Percutaneous ventricular restoration therapy using the parachute device in Chinese patients with ischemic heart failure: Three-month primary end-point results of PARACHUTE China Study. *Chin Med J* 2016;129:2058-62. doi: 10.4103/0366-6999.189048.
10. Dor V, Sabatier M, Di Donato M, Montiglio F, Toso A, Maioli M. Efficacy of endoventricular patch plasty in large postinfarction akinetic scar and severe left ventricular dysfunction: Comparison with a series of large dyskinetic scars. *J Thorac Cardiovasc Surg* 1998;116:50-9. doi: 10.1016/S0022-5223(98)70242-9.
11. Di Donato M, Barletta G, Maioli M, Fantini F, Coste P, Sabatier M, *et al.* Early hemodynamic results of left ventricular reconstructive surgery for anterior wall left ventricular aneurysm. *Am J Cardiol* 1992;69:886-90. doi: 10.1016/0002-9149(92)90787-Y.
12. Ueno T, Sakata R, Iguro Y, Yamamoto H, Ueno M, Ueno T, *et al.* Mid-term changes of left ventricular geometry and function after Dor, SAVE, and overlapping procedures. *Eur J Cardiothorac Surg* 2007;32:52-7. doi: 10.1016/j.ejcts.2007.02.030.
13. Di Donato M, Dabic P, Castelveccchio S, Santambrogio C, Brankovic J, Collarini L, *et al.* Left ventricular geometry in normal and post-anterior myocardial infarction patients: Sphericity index and 'new' conicity index comparisons. *Eur J Cardiothorac Surg* 2006;29 Suppl 1:S225-30. doi: 10.1016/j.ejcts.2006.03.002.
14. Di Donato M, Castelveccchio S, Kukulski T, Bussadori C, Giacomazzi F, Frigiola A, *et al.* Surgical ventricular restoration: Left ventricular shape influence on cardiac function, clinical status, and survival. *Ann Thorac Surg* 2009;87:455-61. doi: 10.1016/j.athoracsur.2008.10.071.
15. Friedman BM, Dunn MI. Postinfarction ventricular aneurysms. *Clin Cardiol* 1995;18:505-11. doi: 10.1002/clc.4960180905.
16. Lang RM, Badano LP, Mor-Avi V, Afilalo J, Armstrong A, Ernande L, *et al.* Recommendations for cardiac chamber quantification by echocardiography in adults: An update from the American Society of Echocardiography and the European Association of Cardiovascular Imaging. *J Am Soc Echocardiogr* 2015;28:1-39.e14. doi: 10.1016/j.echo.2014.10.003.
17. Dor V, Sabatier M, Montiglio F, Civaia F, DiDonato M. Endoventricular patch reconstruction of ischemic failing ventricle. A single center with 20 years experience. advantages of magnetic resonance imaging assessment. *Heart Fail Rev* 2004;9:269-86. doi: 10.1007/s10741-005-6804-5.
18. Torrent-Guasp F, Buckberg GD, Clemente C, Cox JL, Coghlan HC, Gharib M. The structure and function of the helical heart and its buttress wrapping. I. The normal macroscopic structure of the heart. *Semin Thorac Cardiovasc Surg* 2001;13:301-19. doi: 10.1053/stcs.2001.29953.
19. Buckberg GD, Coghlan HC, Torrent-Guasp F. The structure and function of the helical heart and its buttress wrapping. V. Anatomic and physiologic considerations in the healthy and failing heart. *Semin Thorac Cardiovasc Surg* 2001;13:358-85. doi: 10.1053/stcs.2001.29957.