

Case Report

Multiple Cervical Spinous Process Fractures in a Novice Golf Player

Sei-Yoon Kim, M.D., Sang Ki Chung, M.D., Ph.D., Dong-Yun Kim, M.D.

Department of Neurosurgery, Seoul Chuk Spine Hospital, Seoul, Korea

Avulsion of spinous process, also called Clay-shoveler's fracture, is most prevalent among those engaged in hard physical labor. To the best of the author's knowledge, only one case of multiple spinous process fractures of the upper thoracic spine in a novice golfer has been reported. A 45-year-old female presented with intractable posterior neck pain. The patient experienced a sharp, sudden pain on the neck while swinging a golf club, immediately after the club head struck the ground. Dynamic cervical radiographic findings were C6 and C7 spinous process fractures. Magnetic resonance imaging revealed C6 and C7 spinous process fractures without spinal cord pathology. The patient was treated with pain medications and cervical bracing. The patient's pain gradually improved. The injury mechanism was speculated to be similar to Clay-shoveler's fracture. Lower cervical spinous process fractures can be associated with a golf swing. If the patient complains of long lasting neck pain and has a history of golf activity, further study should be conducted to rule out lower cervical spinous fracture.

Key Words : Golf injury · Cervical spinous process fracture · Trapezius muscle.

INTRODUCTION

Golf is a popular sport. Like other sporting activities, it can cause various types of injury to the musculoskeletal system. Golf does not involve physical contact between players. However, reports of golf swing-related fractures include stress fracture of the ribs, ulnar diaphysis, vertebral body, sternum, and hook of hamate^{2,6,9,15,17}. To our knowledge, only one case of multiple spinous process fractures of the upper thoracic spine in a beginning golfer has been reported¹⁴. We report a case of multiple cervical spinous process fractures in a novice golf player and discuss its pathomechanism.

CASE REPORT

A 45-year-old female presented with intractable posterior neck pain that had lasted for 11 days. The severity of the pain had prevented sleep and rotation of the neck for 7 days. The patient had experienced a sharp and sudden pain on the posterior neck during a golf swing. The pain began when the club contacted the ground instead of the golf ball. Under the impression

of acute sprain, the patient was treated conservatively at the local hospital. But, the symptom was aggravated despite receiving massage and physical therapy. There was no notable history of medical illness, such as diabetes, hypertension and osteoporosis. On physical examination, the patient complained of severe tenderness over the lower mid-cervical area and, in particular, limited range of motion during flexion and extension. However, swelling and ecchymosis were not evident at the tender point. The findings of neurological symptoms and signs were normal. Dynamic cervical radiographic findings were fractures in the spinous processes of C6 and C7 vertebrae without instability (Fig. 1). The patient underwent cervical magnetic resonance imaging (MRI) with a suspicion of other occult trauma around C6 and C7. Sagittal T1 and T2-weighted images (Fig. 2A, B) also showed spinous process fractures in C6 and C7. There was no abnormality in the spinal cord. Fat saturation image (Fig. 2C) revealed high signal areas in interspinous and supraspinous ligaments between the C6 and C7 vertebra suggestive of an acute injury to cervical spine. Under the diagnosis of stable C6 and C7 spinous process fractures, the patient was prescribed with pain medications and wearing a cervical collar was recom-

• Received : July 10, 2012 • Revised : September 29, 2012 • Accepted : December 14, 2012

• Address for reprints : Sei-Yoon Kim, M.D.

Department of Neurosurgery, Seoul Chuk Spine Hospital, 16-486 Jeongneung-dong, Seongbuk-gu, Seoul 136-100, Korea

Tel : +82-2-940-2145, Fax : +82-2-940-2193, E-mail : my-ksy3@hanmail.net

• This is an Open Access article distributed under the terms of the Creative Commons Attribution Non-Commercial License (<http://creativecommons.org/licenses/by-nc/3.0>) which permits unrestricted non-commercial use, distribution, and reproduction in any medium, provided the original work is properly cited.

mended for 6 weeks. After cervical bracing and medication, pain gradually improved.

DISCUSSION

Golf is a global sport. It requires a coordinated sequence of whole body muscle activity to efficiently transfer the power generated by the swing¹⁹⁾. During the each phase of a golf swing, there is a potential for injury. There have been a number of reports of golf related injuries (Table 1)^{2,6,7,9,14,15,17,18)}. But, only one report has described multiple spinous process fractures of the upper thoracic spine caused by golf swing itself⁴⁾. The case included acute and delayed stress fractures. Initial MRI revealed a spinous process fracture of first thoracic vertebra. But, the follow-up MRI revealed the additional fracture in the spinous process of the second thoracic vertebra. The pathomechanism of this type injury re-

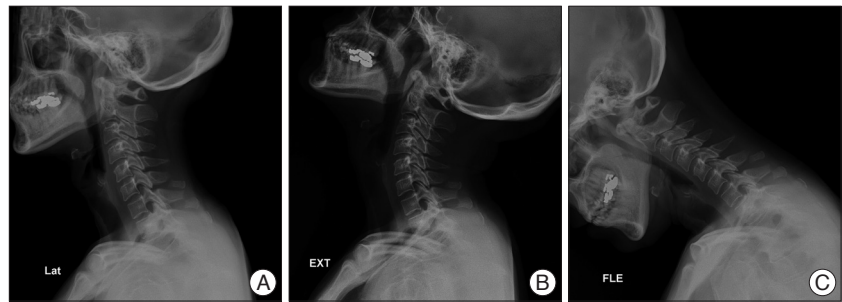


Fig. 1. Lateral radiographs showing C6 and C7 spinous process fractures (A) and no instability on lateral extension (B) and flexion (C) radiographs.

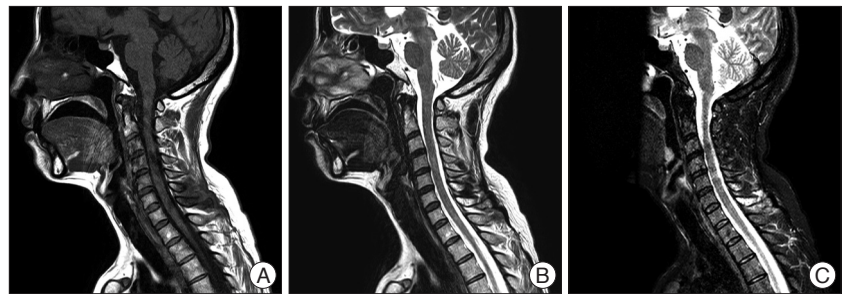


Fig. 2. Sagittal T1, T2-weighted magnetic resonance images (A and B) showing C6 and C7 spinous process fracture without spinal cord pathology. Fat saturation image (C) revealing high signal areas in interspinous and supraspinous between the C6 and C7 vertebra suggestive of an acute injury to cervical spine.

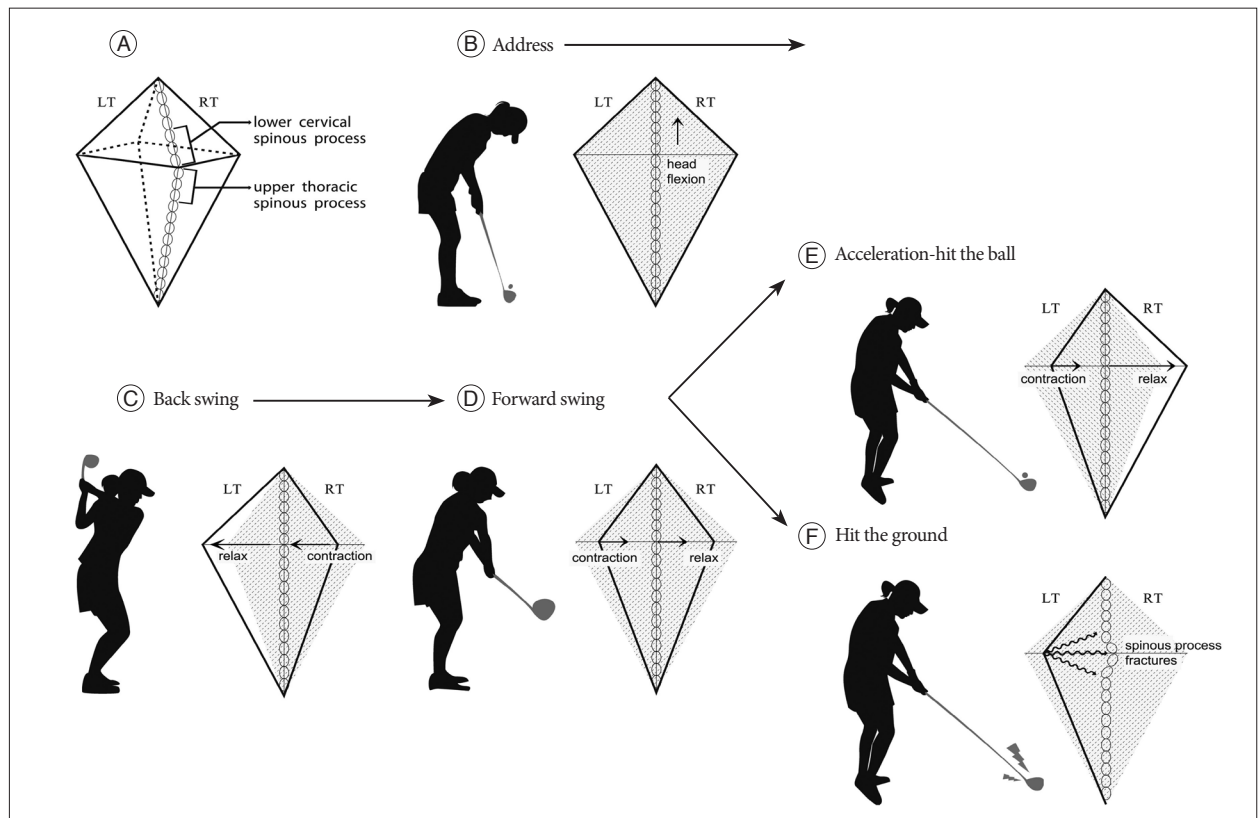


Fig. 3. Schematic draws of trapezius muscle during each swing phase. Trapezius muscle thickness is increased in the lower cervical and upper thoracic region (A). During back swing, right upper and middle trapezius muscle contract from address-neutral state (B and C). During forward swing, the left middle trapezius muscle contracts (D). The force may amplify during the acceleration phase (E). When a right-handed golfer swings such that the club contacts the ground before the ball back swing arc energy cannot be transmitted to the ball (F).

Table 1. Golf related injuries according to literatures

Author reference order	Injury site	Cause
Barbaix ²⁾	Sternum	Stress fracture
Ekin et al. ⁶⁾	Vertebrae	Compression fracture due to osteoporosis
Etgen et al. ⁷⁾	Brain	Intracranial hematoma without skull fracture by golf ball
Gill et al. ⁹⁾	Hook of hamate	Stress fracture
Kang et al. ¹³⁾	Thoracic spinous processes	Stress fracture
Koskinen et al. ¹⁴⁾	Ulnar diaphysis	Stress fracture
Lord et al. ¹⁶⁾	Ribs	Stress fracture
Maroon et al. ¹⁸⁾	Brain	Stroke from vertebral artery dissection

mained ill-defined and was presumed to be similar to Clay-shoveler's fracture¹⁰⁾. Avulsion of spinous process or Clay-shoveler's fracture was first described in Australia¹⁰⁾. It is most prevalent among those engaged in hard physical labor¹⁰⁾. More recently, it has also been described during Nintendo Wii activity⁴⁾, volleyball³⁾, car accident¹⁾, power lifting¹²⁾, and golf⁴⁾. It occurs when the head and upper cervical segments are forced into flexion against the opposing action of the interspinous and supraspinous ligaments¹¹⁾. The injury takes its name from the fact that, during the throwing phase of shoveling, clay may stick to the shovel and jerk the trapezius and other muscles attached to lower cervical or upper thoracic spinous processes¹⁰⁾. It can also occur with a whiplash injury, injuries that jerk the arms upwards, neck hyperflexion, or a direct blow to the spinous processes¹⁰⁾. In our case, the trapezius muscle also contributed to the injury. The trapezius muscle originates from the medial one-third of the superior nuchal line and the external occipital protuberance of the occipital bone, from the spines of the seventh cervical and all thoracic vertebrae, and from the intervening supraspinal ligament²⁰⁾. It assists in suspending the shoulder girdle with other muscles. It is relatively flat and thin, but its thickness increases in the lower cervical and upper thoracic region²⁰⁾. Where its increased thickness is matched by a distinct diamond-shaped accumulation of tendinous fibers of origin²⁰⁾(Fig. 3A). The spinous process is relatively longer in the lower cervical than the upper cervical area. Its fibers converge toward the bones of the shoulder²⁰⁾. During the back swing, the right upper and middle trapezius muscle contracts¹⁹⁾(Fig. 3B, C). During the forward swing, the left middle trapezius muscle contracts¹⁹⁾(Fig. 3D). So we can postulate that muscular contraction moves from right side to left side, like a bow. Because of the pectoralis muscle, the force may be amplified during the acceleration phase (Fig. 3E). When a right-handed golfer swings so the club contacts the ground prior to the ball, the energy accumulated during the back swing cannot be transmitted to the ball (Fig. 3F). There is a sudden change of muscle contraction from the right upper and middle trapezius to its attachment point (the spinous process). If enough force is transmitted through the trapezius tendon, spinous process fracture is possible. When the force is not strong

enough to make fracture, if applied repeatedly, overuse or stress-type fracture may occur. This fracture is stable, and by itself is of little significance. But, it is painful. The present patient was initially misdiagnosed as having an acute cervical sprain. Atypically, this fracture may extend to the lamina, thereby involving the spinal canal with the potential of spinal cord injury¹¹⁾.

If a patient complains of long lasting neck pain, the attending clinician should have further study (cervical spine radiographs, computed tomography scan or cervical MRI) to rule out other occult fractures or injuries¹⁶⁾. Midline tenderness may be the clue for the presence of fracture. If the lower cervical spine and/or cervico-thoracic junction are not well visualized on cervical spine lateral radiographs, a swimmer's view⁵⁾ or CT scan¹⁵⁾ should be obtained. An understanding of correct swing technique will help the golf beginner³⁾. Golf related injuries increase without warm-up exercise⁸⁾. So, warming up and stretching exercise before golf will reduce the risk of golf related injury⁸⁾.

CONCLUSION

Lower cervical spinous process fractures, even minor stable fractures, can be associated with the golf swing. If a patient complains of long lasting neck pain and has a history of golf play, lower cervical spinous fracture should be suspected and ruled out.

• Acknowledgements

This study was supported by a grant from Seoul Chuk Spine Foundation. The authors thank to Ms Yun Jeong Choe in the preparation of the figures of this manuscript.

References

- Akhaddar A, El-asri A, Boucetta M : Multiple isolated thoracic spinous process fractures (Clay-Shoveler's fracture). *Spine J* 11 : 458-459, 2011
- Barbaix EJ : Stress fracture of the sternum in a golf player. *Int J Sports Med* 17 : 303-304, 1996
- Brandon B, Pearce PZ : Training to prevent golf injury. *Curr Sports Med Rep* 8 : 142-146, 2009
- Brown CN, McKenna P : A Wii-related clay-shoveler's fracture. *ScientificWorldJournal* 9 : 1190-1191, 2009
- Davidorf J, Hoyt D, Rosen P : Distal cervical spine evaluation using swimmer's flexion-extension radiographs. *J Emerg Med* 11 : 55-59, 1993
- Ekin JA, Sinaki M : Vertebral compression fractures sustained during golfing : report of three cases. *Mayo Clin Proc* 68 : 566-570, 1993
- Etgen T, Sander K : Intracerebral haematoma without skull fracture by golf ball. *BMJ Case Rep* 2008 : bcr0620080024, 2008
- Fradkin AJ, Finch CE, Sherman CA : Warm-up attitudes and behaviours of amateur golfers. *J Sci Med Sport* 6 : 210-215, 2003
- Gill NW, Rendeiro DG : Hook of the hamate fracture. *J Orthop Sports Phys Ther* 40 : 325, 2010
- Greenberg MS : *Handbook of neurosurgery*, ed 4. Florida : Greenberg

- Graphics Inc., 1997
11. Harris JH, Mirvis SE : *The radiology of acute cervical spine trauma*, ed 3. Baltimore : Williams & Wilkins, 1996
 12. Herrick RT : Clay-shoveler's fracture in power-lifting. A case report. *Am J Sports Med* 9 : 29-30, 1981
 13. Hestroni I, Mann G, Dolev E, Morgenstern D, Nyska M : Clay shoveler's fracture in a volleyball player. *Phys Sportsmed* 33 : 38-42, 2005
 14. Kang DH, Lee SH : Multiple spinous process fractures of the thoracic vertebrae (Clay-Shoveler's Fracture) in a beginning Golfer : a case report. *Spine (Phila Pa 1976)* 34 : E534-E537, 2009
 15. Koskinen SK, Mattila KT, Alanen AM, Aro HT : Stress fracture of the ulnar diaphysis in a recreational golfer. *Clin J Sport Med* 7 : 63-65, 1997
 16. Lin JT, Lee JL, Lee ST : Evaluation of occult cervical spine fractures on radiographs and CT. *Emerg Radiol* 10 : 128-134, 2003
 17. Lord MJ, Ha KI, Song KS : Stress fractures of the ribs in golfers. *Am J Sports Med* 24 : 118-122, 1996
 18. Maroon JC, Gardner P, Abla AA, El-Kadi H, Bost J : "Golfer's stroke" : golf-induced stroke from vertebral artery dissection. *Surg Neurol* 67 : 163-168; discussion 168, 2007
 19. McHardy A, Pollard H : Muscle activity during the golf swing. *Br J Sports Med* 39 : 799-804; discussion 799-804, 2005
 20. Woodburne RT, Burkel WE : *Essentials of human anatomy*, ed 8. New York : Oxford university press, 1988