

Teaching Case

Radiation-Induced Colitis in a Pancreatic Cancer Patient With a Germline BRCA2 Mutation: A Case Report



Adam R. Wolfe MD, PhD ^a, Rishi Jain MD ^b,
Timothy M. Pawlik MD, PhD, MPH ^c, Jon Walker MD ^d,
Terence M. Williams MD, PhD ^{a,*}

Departments of ^aRadiation Oncology, ^bMedical Oncology, and ^cSurgical Oncology, Ohio State University James Comprehensive Cancer Center, Columbus, Ohio; and ^dDepartment of Gastroenterology at the Ohio State University Wexner Medical Center, Columbus, Ohio

Received 6 July 2018; revised 31 August 2018; accepted 31 August 2018

Introduction

Borderline resectable pancreatic cancer (BRPC) represents only about 10% of all patients with pancreatic cancer.¹ Upfront surgery for BRPC leads to high rates of R1 or R2 resection, local recurrence, and distant metastasis.² Therefore neoadjuvant chemotherapy with chemoradiation (CRT) is becoming the preferred treatment approach for BRPC. Modern multiagent chemotherapy in this setting often includes FOLFIRINOX (fluorouracil, irinotecan, oxaliplatin, and folinic acid) or gemcitabine and nab-paclitaxel, whereas single-agent gemcitabine, fluorouracil, or capecitabine are commonly used as radiosensitizers during chemoradiation. Although prospective data sample sizes are small, the reported rates of R0 resection after neoadjuvant chemotherapy and CRT are high at 75% to 97%, and the median overall survival is 25 to 40 months versus 14 to 18 months in patients with resected versus unresected BRPC, respectively.²⁻⁶

Germline mutation of either the BRCA1 or BRCA2 genes is associated with an increased relative risk of pancreatic ductal adenocarcinoma equal to approximately

3.5 (95% confidence interval, 1.87-6.58).⁷ BRCA1 and BRCA2 transcription is modulated throughout the cell cycle, and BRCA proteins are involved in all phases of the cell cycle and even coordinate cell cycle progression, programmed cell death, and maintenance of genomic stability.⁸ Furthermore, the canonical function of these 2 proteins is repair of DNA double-strand breaks via homologous recombination (HR).⁹ BRCA1/2 loss leads to increased DNA damage and cell death after irradiation.¹⁰⁻¹³ Although decreased DNA damage repair is optimal in cancer cells targeted with radiation, there is concern with normal tissue toxicities that also exhibit BRCA1/2 loss resulting in defects in HR. Several clinical studies have reported tissue toxicities within the acceptable range or have found no evidence of increased toxicities for patients with breast cancer with BRCA1/2 germline mutations treated with radiation.¹⁴⁻¹⁶ Herein we present a case of a man with a diagnosis of BRPC with a germline BRCA2 mutation who developed severe acute colitis after administration of CRT.

Case Report

A 45-year-old white man with an Eastern Cooperative Oncology Group performance score of 0 presented with obstructive jaundice, weight loss of 35 pounds over 6 months, dark-colored urine, and clay-colored stools. A

Sources of support: This work had no specific funding.

Conflicts of interest: The authors have no conflicts of interest to disclose.

* Corresponding author. 460 West 10th Ave., Columbus, OH 43210.
E-mail address: Terence.Williams@osumc.edu (T.M. Williams).

<https://doi.org/10.1016/j.adro.2018.08.025>

2452-1094/© 2018 The Authors. Published by Elsevier Inc. on behalf of American Society for Radiation Oncology. This is an open access article under the CC BY-NC-ND license (<http://creativecommons.org/licenses/by-nc-nd/4.0/>).

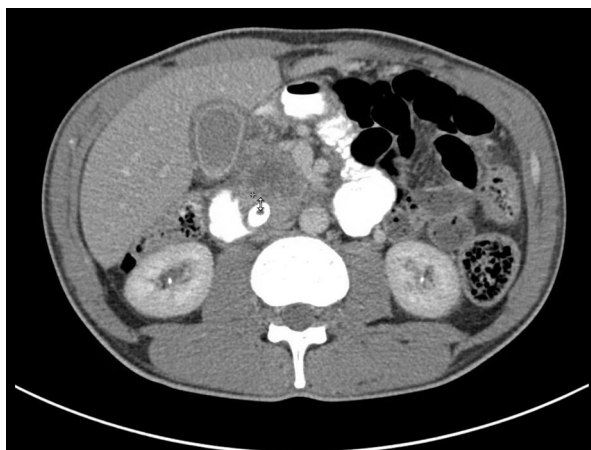


Figure 1 Axial view of computed tomography scan of the abdomen before chemoradiation therapy. Pancreatic tumor abutted but did not encase the hepatic artery, portal splenic confluence, or superior mesenteric artery.

computed tomography (CT) scan of the abdomen and pelvis revealed a mass measuring 3.8×2.6 cm in the head of the pancreas. His initial bilirubin was 27 mg/dL (normal, 0.1-1.2 mg/dL) and carbohydrate antigen (CA) 19-9 was more than 4000 U/mL (normal, 0-37 U/mL). Fine needle aspiration of the pancreatic mass via endoscopic ultrasound revealed adenocarcinoma. The mass abutted but did not encase the hepatic artery, portal splenic confluence, or superior mesenteric artery (Fig 1). The oncology team recommended neoadjuvant chemotherapy followed by CRT for BRPC. Staging scans confirmed he did not have metastatic disease.

A workup for underlying liver disease with laboratory tests and liver biopsy was nonrevealing, and it was concluded that the patient had prolonged cholestasis as a result of long-standing obstruction. Therefore the clinical team recommended pursuing CRT with 5-fluorouracil (5-FU)—based chemotherapy to start treatment. CA 19-9 was 10,790 U/mL 3 weeks before starting CRT. With such an elevated CA 19-9 there was concern for metastatic disease, but full workup and staging studies did not reveal evidence of metastasis (eg, liver, lungs, peritoneum), so the decision was made to move forward with definitive therapy.

The patient started 5-FU—based CRT with the plan for a total dose of 55 Gy in 25 fractions using a 6 MV volumetric modulated arc therapy plan (Fig 2). He received standard 5-FU 225 mg/m² per day for a planned 5 d/wk on days of radiation. His total bilirubin started trending down. However, about 1 week after starting therapy, he reported increasing diarrhea. Before starting therapy, he was having 6 to 8 bowel movements a day, which was attributed to pancreatic enzyme and bile salt insufficiency. After fraction 8 of radiation he reported a slight increase in bowel movements, with 8 to 10 bowel movements per day with a more watery consistency and

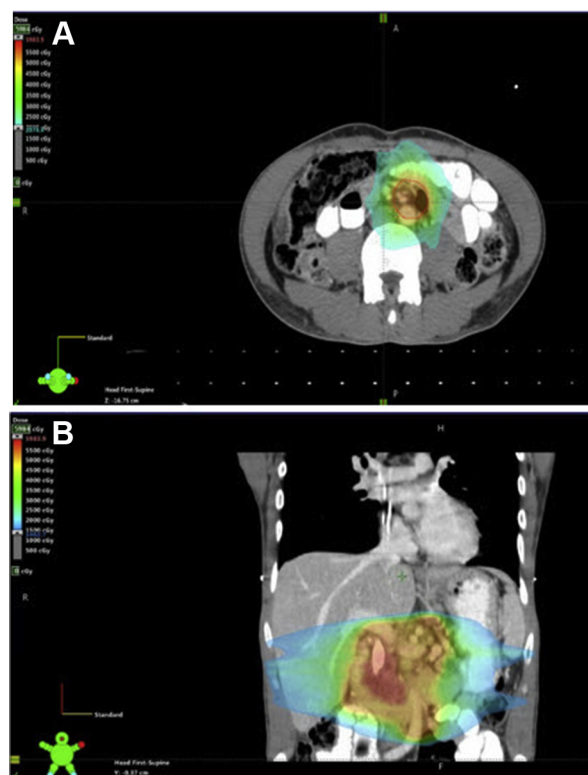

Figure 2 Radiation treatment plan (planned for a total dose of 55 Gy in 25 fractions with concurrent 5-fluorouracil). (A) Axial slice showing radiation dose overlapping the transverse colon. (B) Coronal image of radiation plan. Large areas of overlap between treatment planning target volume and large bowel.

increased gas. He was taking diphenoxylate/atropine (Lomotil by Pfizer, Inc.) twice a day along with other conservative measures without relief. After a discussion with the patient about discontinuing therapy, holding therapy, or reducing 5-FU or radiation dose, he indicated he wished to continue aggressively with therapy without delay because he was otherwise asymptomatic.

Infectious testing was negative, including *Clostridium difficile* and stool studies. At fraction 16 he appeared to be improved with only 4 bowel movements per day. However, at fraction 19 and a total of 41.8 Gy delivered, he had a sudden increase in bowel movements to 13 to 15 bowel movements per day and was subsequently hospitalized as a result of severe diarrhea, reduced performance status, dehydration, and new-onset hematochezia. During his hospitalization a CT of the abdomen and pelvis showed pancolonic wall thickening with adjacent inflammatory changes (Fig 3). By this time, his total bilirubin had decreased to 1.5 mg/dL. A colonoscopy was performed, with findings of diffuse areas of erythematous mucosa spanning the entire colon and having the highest degree within the transverse colon, which lay in close proximity to the radiation field. The mucosa had punctate hemorrhages and ulceration and was friable with contact (Fig 4). Biopsy specimens of the colon revealed

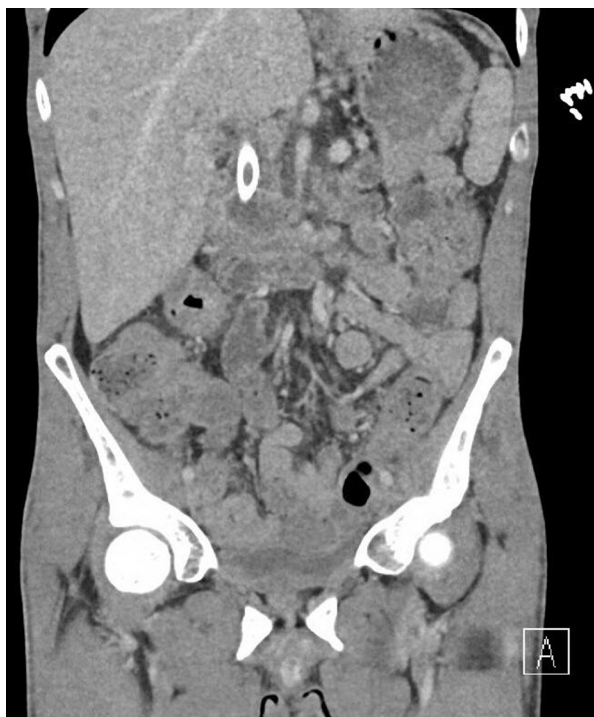

Figure 3 Coronal view from computed tomography scan of the abdomen after radiation therapy. Note pancolonic wall thickening with adjacent inflammatory changes compatible with an acute inflammatory colitis.

pathologic findings of marked acute colitis with epithelial denudation, prominent apoptotic bodies, crypt rupture granuloma, decreased goblet and Paneth cells, and patchy increased chronic inflammation. Workup for an infectious cause was negative (including *Shigella*, *Escherichia coli*, *Campylobacter*, *Enterobacter histolytica*, *Salmonella*, cytomegalovirus, and Epstein-Barr virus). However, CRT was discontinued with only 19 of the planned 25 fractions completed because of concern that CRT was the cause of the pancolitis.

After the discontinuation of CRT, the patient's colitis resolved. During this time, Foundation One testing of the tumor tissue revealed a BRCA2 R2520 mutation and additional alterations, including KRAS G12D, p14ARF exon 1 loss (encoded by CDKN2A), CDKN2B loss, SMAD4 exons 9 to 10 loss, and TP53 R196. A family history had uncovered a history of breast, ovarian, pancreatic, colon, and bladder cancer, and germline genetic testing was positive for the same germline BRCA2 mutation (BRCA2 c.7558C>T, R2520*) after CRT had been discontinued. This mutation is a heterozygous mutation in exon 15; it is classified as pathogenic and is expected to result in loss of function as a result of absent/disrupted protein product.

Interval staging scans obtained approximately 4 weeks after CRT was discontinued unfortunately revealed diffuse metastatic disease in the liver, with innumerable

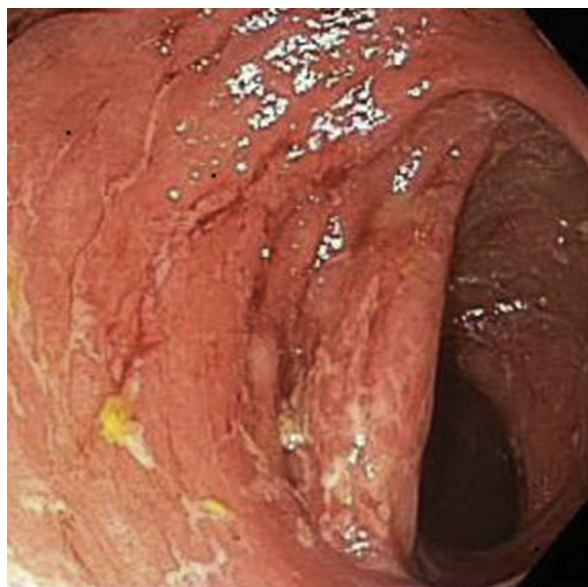


Figure 4 Colonoscopy showing mucosa with punctate hemorrhages, ulceration, and increased friability with contact.

small hypodense lesions, and a CA 19-9 of 84,750 U/mL. He was subsequently initiated on FOLFIRINOX, and 4 months after therapy, his CA 19-9 dropped to 77. His CT scans indicated essentially complete resolution of liver metastases and a significant decrease in size of the pancreatic head mass to 2.0 × 0.9 cm (Response Evaluation Criteria in Solid Tumors partial response).

Discussion

We present herein a case of a patient who developed severe gastrointestinal toxicity after treatment of BRPC with radiation and 5-FU. The patient was subsequently found to have a BRCA2 germline mutation. It is important to note that this pathogenic mutation is expected to result in loss of BRCA2 function. This is an important distinction because some BRCA mutations can be functionally silent, and our findings should certainly not be applied to all patients with a BRCA mutation. Cancer cells deficient in BRCA1 or 2 have been found in vitro to be more sensitive to radiation than their wild type counterparts.¹⁷ Furthermore, in vivo studies have found that BRCA1 silencing in breast cancer models leads to enhanced radiosensitization.¹⁸ Although BRCA1/2 mutations result in enhanced radiosensitization, there has been a dearth of clinical data to suggest that patients (with malignancies other than breast cancer) with BRCA1/2 mutations have differences in outcomes or toxicities after radiation therapy compared with wild type patients.^{14,19,20} As of now it is not clear whether loss of one wild type BRCA (ie, haploinsufficiency) is sufficient to reproducibly lead to an increased susceptibility to radiation-induced cell death in patients or if loss of heterozygosity (LOH) is

required.²¹ Although LOH is common in tumor development and evolution, normal cells are usually haploinsufficient and LOH is rare. Certainly there is preclinical evidence that BRCA haploinsufficiency can lead to impaired DNA damage repair in vitro.^{10,22,23} In addition, Buchholz et al²³ reported that heterozygous mutations in BRCA1 or BRCA2 in dermal fibroblasts had decreased survival fraction at 2 Gy of radiation and increased chromatid breaks compared with wild type control cell lines in vitro.

One hypothesis is that normal cells deficient in BRCA1/2 are more susceptible to radiation-induced DNA damage, and therefore patients with germline BRCA1/2 mutations will exhibit more normal tissue toxicities after radiation. Kelsey et al²⁴ compared lung damage with single-photon emission computed tomography lung perfusion scans before and after radiation treatments and found that polymorphisms within genes involved in DNA repair (XRCC1 and BRCA1) were associated with radiation sensitivity. However, the majority of studies, mostly in breast cancer, have not found any correlation with increased radiation-induced normal tissue toxicities in the setting of BRCA1/2 germline mutations. Pierce et al²⁰ reported results from 71 breast cancer patients with either germline BRCA 1 or 2 mutations treated with breast-conserving surgery and radiation compared with matched controls. There was no difference in acute or late toxicities in terms of skin or lung toxicities, and clinical outcomes were similar. From the UK, Shanley et al¹⁵ examined a retrospective cohort of 55 BRCA1/2 carriers who were treated for breast cancer with radiation and were compared with age-matched sporadic controls. There was no increase in rates of late events (rib fractures, lung fibrosis, necrosis of soft tissue or bone, and pericarditis) or clinical photography scores of breast size, shape, and skin telangiectasia. Gaffney et al¹⁶ also reported no differences in toxicities in patients with breast cancer harboring BRCA1 or BRCA2 mutations compared with sporadic controls.

Although it appears that patients with breast cancer carrying BRCA1/2 mutations do not have increased risks of acute or late-term toxicities, there is a scarcity of data reviewing the risk of acute gastrointestinal toxicities in germline BRCA1/2 mutated patients who receive abdominal radiation. This is in part a result of BRCA gene status not being routinely tested in patients with abdominal malignancies. As mentioned, there are data to support germline BRCA mutations as not associated with increased radiosensitivity or radiation-induced toxicity in various tumor types, including breast and prostate cancer (reviewed by Bernier and Poortmans²⁵). In multiple reports consisting of germline BRCA mutated patients with breast cancer treated with radiation, no increased rates of acute or late toxicities were noted compared with sporadic breast cancer.^{14,16} In addition, one case report by Vesprini et al²⁶ of 3 men with prostate cancer and germline BRCA2 mutations found no adverse short- or long-term

gastrointestinal or genitourinary side effects after treatments with radiation and chemotherapy. Furthermore, cell lines generated from one of these BRCA2 mutated patients indicated no difference in clonogenic survival after radiation compared with normal fibroblast strains.

In our case report the patient experienced colitis that appeared to be related to the radiation because the most severe portion of the colitis was in the transverse colon, the part of the colon closest to the high-dose region of the radiation plan. We speculate that the radiation damage resulting from BRCA2 mediated radiosensitivity, resulting in breakdown of the intestinal epithelial barrier, which subsequently led to a transmural infection or colitis of most of the colon. Interestingly, the colitis improved rapidly after radiation was discontinued and did not occur again, even when he was on FOLFIRINOX chemotherapy (platinum containing and 5-FU containing). We would have expected the colitis to return during FOLFIRINOX chemotherapy if it was related to 5-FU chemotherapy.

In summary, we provide evidence of a brisk noninfectious colitis arising during 5-FU-based chemoradiation in a healthy man with BRCA2 germline-mutated pancreatic cancer. This case report suggests that caution and close monitoring must be undertaken in patients with known germline HR-deficient pancreatic cancer undergoing radiation or chemoradiation therapy. This report further supports genetic testing of patients with pancreatic cancer with a family history in the context of appropriate genetic counseling. In addition, more comprehensive testing of DNA repair pathways, including homologous recombination pathways, in patients who have received abdominal radiation for upper abdominal malignancies is warranted to determine whether any increased risk of radiation toxicity may be associated with alterations in these pathways.

References

1. Katz MHG, Marsh R, Herman JM, et al. Borderline resectable pancreatic cancer: Need for standardization and methods for optimal clinical trial design. *Ann Surg Oncol*. 2013;20:2787-2795.
2. Katz MHG, Pisters PW, Evans DB, et al. Borderline resectable pancreatic cancer: The importance of this emerging stage of disease. *J Am Coll Surg*. 2008;206:833-848.
3. Stokes JB, Nolan NJ, Stelow EB, et al. Preoperative capecitabine and concurrent radiation for borderline resectable pancreatic cancer. *Ann Surg Oncol*. 2011;18:619-627.
4. Lee J-L, Kim SC, Kim SE, et al. Prospective efficacy and safety study of neoadjuvant gemcitabine with capecitabine combination chemotherapy for borderline-resectable or unresectable locally advanced pancreatic adenocarcinoma. *Surgery*. 2012;152:851-862.
5. Takahashi H, Ohigashi H, Gotoh K, et al. Preoperative gemcitabine-based chemoradiation therapy for resectable and borderline resectable pancreatic cancer. *Ann Surg*. 2013;258:1040-1050.
6. Murphy JE, Wo JY, Ryan DP, et al. Total neoadjuvant therapy with FOLFIRINOX followed by individualized chemoradiotherapy for borderline resectable pancreatic adenocarcinoma: A phase 2 clinical trial. *JAMA Oncol*. 2018;4:963-969.

7. The Breast Cancer Linkage Consortium. Cancer risks in BRCA2 mutation carriers. *J Natl Cancer Inst.* 1999;91:1310-1316.
8. Deng C-X. BRCA1: Cell cycle checkpoint, genetic instability, DNA damage response and cancer evolution. *Nucleic Acids Res.* 2006;34:1416-1426.
9. Roy R, Chun J, Powell SN. BRCA1 and BRCA2: Different roles in a common pathway of genome protection. *Nat Rev Cancer.* 2012;12:68-78.
10. Foray N, Randrianarison V, Marot D, Perricaudet M, Lenoir G, Feunteun J. Gamma-rays-induced death of human cells carrying mutations of BRCA1 or BRCA2. *Oncogene.* 1999;18:7334-7342.
11. Venkitaraman AR. Functions of BRCA1 and BRCA2 in the biological response to DNA damage. *J Cell Sci.* 2001;114:3591-3598.
12. Gudmundsdottir K, Ashworth A. The roles of BRCA1 and BRCA2 and associated proteins in the maintenance of genomic stability. *Oncogene.* 2006;25:5864-5874.
13. Wu J, Lu LY, Yu X. The role of BRCA1 in DNA damage response. *Protein Cell.* 2010;1:117-123.
14. Pierce LJ, Strawderman M, Narod SA, et al. Effect of radiotherapy after breast-conserving treatment in women with breast cancer and germline BRCA1/2 mutations. *J Clin Oncol.* 2000;18:3360-3369.
15. Shanley S, McReynolds K, Arden-Jones A, et al. Late toxicity is not increased in BRCA1/BRCA2 mutation carriers undergoing breast radiotherapy in the United Kingdom. *Clin Cancer Res.* 2006;12:7025-7032.
16. Gaffney DK, Brohet RM, Lewis CM, et al. Response to radiation therapy and prognosis in breast cancer patients with BRCA1 and BRCA2 mutations. *Radiother Oncol.* 1998;47:129-136.
17. Shen S-X, Weaver Z, Xu X, et al. A targeted disruption of the murine Brca1 gene causes γ -irradiation hypersensitivity and genetic instability. *Oncogene.* 1998;17:3115.
18. Cortez D, Wang Y, Qin J, Elledge SJ. Requirement of ATM-dependent phosphorylation of Brca1 in the DNA damage response to double-strand breaks. *Science.* 1999;286:1162-1166.
19. Kirova YM, Savignoni A, Sigal-Zafrani B, et al. Is the breast-conserving treatment with radiotherapy appropriate in BRCA1/2 mutation carriers? Long-term results and review of the literature. *Breast Cancer Res Treat.* 2010;120:119-126.
20. Pierce LJ, Levin AM, Rebbeck TR, et al. Ten-year multi-institutional results of breast-conserving surgery and radiotherapy in BRCA1/2-associated stage I/II breast cancer. *J Clin Oncol.* 2006;24:2437-2443.
21. Santarosa M, Ashworth A. Haploinsufficiency for tumour suppressor genes: When you don't need to go all the way. *Biochim Biophys Acta.* 2004;1654:105-122.
22. Baldeyron C, Jacquemin E, Smith J, et al. A single mutated BRCA1 allele leads to impaired fidelity of double strand break end-joining. *Oncogene.* 2002;21:1401-1410.
23. Buchholz TA, Wu X, Hussain A, et al. Evidence of haplotype insufficiency in human cells containing a germline mutation in BRCA1 or BRCA2. *Int J Cancer.* 2001;97:557-561.
24. Kelsey CR, Jackson IL, Langdon S, et al. Analysis of single nucleotide polymorphisms and radiation sensitivity of the lung assessed with an objective radiologic endpoint. *Clin Lung Cancer.* 2013;14:267-274.
25. Bernier J, Poortmans P. Clinical relevance of normal and tumour cell radiosensitivity in BRCA1/BRCA2 mutation carriers: A review. *Breast.* 2015;24:100-106.
26. Vesprini D, Narod S, Trachtenburg J, et al. The therapeutic ratio is preserved for radiotherapy or cisplatin treatment in BRCA2-mutated prostate cancers. *Can Urol Assoc J.* 2011;5:E31-E35.