



Role of intravitreal brolocizumab with intravitreal rtPA and pneumatic displacement for submacular hemorrhage: A case series

Debdulal Chakraborty^{a,*}, Jay U. Sheth^b, Soumen Mondal^a, Subhendu Boral^a

^a Department of Vitreoretinal Services, Disha Eye Hospitals Kolkata, India

^b Department of Vitreoretinal Services, Surya Eye Institute and Research Center, Mumbai, India

ARTICLE INFO

Keywords:

Brolocizumab

Submacular hemorrhage

Anti-vascular endothelial growth factor

ABSTRACT

Purpose: To evaluate the role of intravitreal injection (IVI) of brolocizumab along with intravitreal recombinant tissue plasminogen activator (rtPA) and C3F8 gas injection for large submacular hemorrhage (SMH) secondary to neovascular age-related macular degeneration (nAMD).

Observations: This was a prospective uncontrolled non-randomized case series conducted at a single site. Three patients with fresh SMH (≤ 4 days) secondary to nAMD underwent triple therapy with IVI brolocizumab + intravitreal rtPA (50 μg in 0.1 mL) + 0.3 mL of 100% C3F8 gas injection. Post-injection, a face-down position was advised for 5 days with periodic follow-up visits. All three patients had complete resolution of SMH at the end of 4 weeks with a notable improvement in the best-corrected visual acuity (BCVA). No optical coherence tomographic (OCT) biomarkers of disease activity were noted at the end of 12 weeks in the first and the third case and 4 weeks in the second case respectively. There were no ocular or systemic side effects reported in any of the cases.

Conclusions and importance: Intravitreal brolocizumab administered along with intravitreal rtPA and C3F8 gas injection was found to be efficacious and safe for the management of large SMH secondary to nAMD. Complete displacement of SMH with excellent structural and functional outcomes can be seen with triple therapy.

1. Introduction

Submacular hemorrhage (SMH) is a grave visual threatening complication of neovascular age-related macular degeneration (nAMD) and polypoidal choroidal vasculopathy (PCV).¹ If untreated, the accumulated blood can cause irreversible damage to the retinal pigment epithelial (RPE) and neurosensory retina (NSR), particularly the photoreceptor layer.^{2,3} Although intravitreal anti-vascular endothelial growth factor (anti-VEGF) injections remain the gold standard for the management of this choroidal neovascularization (CNV), the therapeutic results of anti-VEGF monotherapy are suboptimal in the presence of large SMH.⁴

The primary goal of treating SMH is to displace the blood away from the fovea and treat the underlying etiology.⁵ Although there are no established protocols for the management of SMH secondary to nAMD, a variety of therapeutic strategies have been employed. These include a combination of modalities such as intravitreal gas injection, intravitreal or subretinal recombinant tissue plasminogen activator (rtPA),

anti-VEGF injection, and pars plana vitrectomy (PPV).⁶ Amongst the various anti-VEGF agents currently available, bevacizumab (AVASTIN, Genentech, Inc.), ranibizumab (Lucentis®; Genentech, S. San Francisco, CA/Roche, Basel, Switzerland), and aflibercept (Eylea®, Regeneron, Tarrytown, NY) have been successfully employed for the management of SMH.^{7,8} Brolocizumab (Beovu®; Novartis, Basel, Switzerland), the most recent anti-VEGF agent, received the US Food and Drug Administration (FDA) approval for nAMD in 2019.⁹ In India, the drug is marketed as Pagenax® (Novartis India Ltd, Mumbai, India).⁹ Although the HAWK and HARRIER trials have demonstrated the efficacy of intravitreal injection (IVI) of brolocizumab in nAMD,¹⁰ a thorough PUBMED/MEDLINE search revealed that its role in the management of SMH remains unreported.

Here, we describe the efficacy of IVI brolocizumab in combination with intravitreal rtPA and gas injection in three eyes with fresh (≤ 4 days) large SMH secondary to nAMD. Patients having the longest diameter of the SMH > 4 -disc diopters (DD) and a thickness of $> 100 \mu\text{m}$ on the spectral-domain optical coherence tomography (SD-OCT) were

* Corresponding author. Disha Eye Hospitals, 88 Ghosh para Road, Barrackpore, Kolkata, 700120, India.

E-mail addresses: devdc@rediffmail.com (D. Chakraborty), drjay009@gmail.com (J.U. Sheth), hisoumenm@yahoo.co.in (S. Mondal), drsubhendu@yahoo.co.uk (S. Boral).

<https://doi.org/10.1016/j.ajoc.2022.101390>

Received 11 October 2021; Received in revised form 15 January 2022; Accepted 31 January 2022

Available online 5 February 2022

2451-9936/© 2022 The Authors.

Published by Elsevier Inc.

This is an open access article under the CC BY-NC-ND license

(<http://creativecommons.org/licenses/by-nc-nd/4.0/>).

advised the triple therapy. This retrospective chart analysis was conducted in accordance with the tenets of the Declaration of Helsinki and was approved by the Institutional Review Board and the Ethical Committee of Disha Eye Hospitals in Kolkata, India. Written informed consent was obtained from each patient. All available anti-VEGF medicines were offered to the eligible patients, who freely opted for IVI brolucizumab (6 mg in 0.05 mL). All procedures were performed in a sterile operating room. Povidone-iodine 5% was applied to the periocular region. Initially, the patients received an intravitreal injection of rtPA (50 µg in 0.1 mL) and were given a supine position for 45 minutes for better penetration of the drug. Subsequently, IVI brolucizumab was administered along with 0.3 mL of 100% C3F8 gas, followed by an anterior chamber (AC) paracentesis. Post-operatively, a face-down position was advised for 5 days along with topical moxifloxacin 0.5% for one week. Oral acetazolamide (250 mg) was given in cases with raised intraocular pressure (IOP). The patients were followed up on the second and the fifth day after injection, and subsequently at weeks 2, and 4, and every 4 weekly thereafter, respectively. Best-corrected visual acuity (BCVA) assessment using the Snellen's visual acuity chart, intraocular pressure (IOP) measurement by Goldmann applanation tonometer, anterior segment evaluation using slit-lamp biomicroscopy and fundus examination with both slit-lamp biomicroscopy (+90D lens) and indirect ophthalmoscopy (+20D lens), SD-OCT and color fundus photograph (CFP) were taken at baseline and all subsequent visits. The occurrence of any ocular or systemic adverse event due to IVI brolucizumab or procedure-related were noted too. All patients were planned to receive three monthly loading doses of IVI Brolucizumab followed by pro-re-nata [PRN] regimen.

2. Findings

2.1. Case 1

A 67-year-old female with a history of nAMD in the left eye (OS) developed sudden onset of decreased vision in OS for 3 days. She had undergone 3 intravitreal anti-VEGF injections (2 IVI Ranibizumab, 1 IVI Aflibercept) one year ago following which she was lost to follow-up due to the COVID-19 pandemic. Her OS BCVA was 20/400. Fundus examination of the left eye showed the presence of a massive SMH extending beyond the arcades (Fig. 1 a, b) which were confirmed on SD-OCT (Fig. 2 a). She underwent IVI brolucizumab + rtPA + C3F8 gas injection in OS and was advised prone position for 5 days. The SMH gradually disappeared over the course of one month (Fig. 1 c-f) with the BCVA improving upto 20/80. The SD-OCT at two weeks showed significant improvement of retinal the architecture, with some subretinal fluid (SRF) and fibrovascular pigment epithelial detachments (FVPED) (Fig. 2 b). The SD-OCT at one month showed flattening of the FVPED and no SRF or intra retinal fluid (IRF) (Fig. 2 c). The patient was advised to undergo further IVI brolucizumab injections, but she declined to do so due to financial constraints. Over the next 12 weeks, the BCVA was maintained at 20/80 with an absence of any disease activity (Figs. 1 g, h and 2d). At all visits, the intraocular pressure (IOP) was normal, with no serious side effects.

2.2. Case 2

A 62-year-old male with treatment-naïve nAMD in OS and dry AMD in the right eye (OD) presented with sudden onset of visual loss in OS for 2 days. His BCVA was 20/20 in OD and 20/800 in OS. Fundus evaluation and SD-OCT showed the presence of large SMH (Figs. 3 a and 4 a) in the OS. We performed IVI brolucizumab + rtPA + C3F8 gas injection and advised prone position for 5 days. Over one month, the SMH gradually decreased (Fig. 3 b) with the BCVA improving to 20/250. The SD-OCT illustrated multiple FVPEDs along with an absence of any fluid (Fig. 4 b). Further IVI brolucizumab injections were recommended to the patient, but he declined due to economic constraints. Subsequently, his

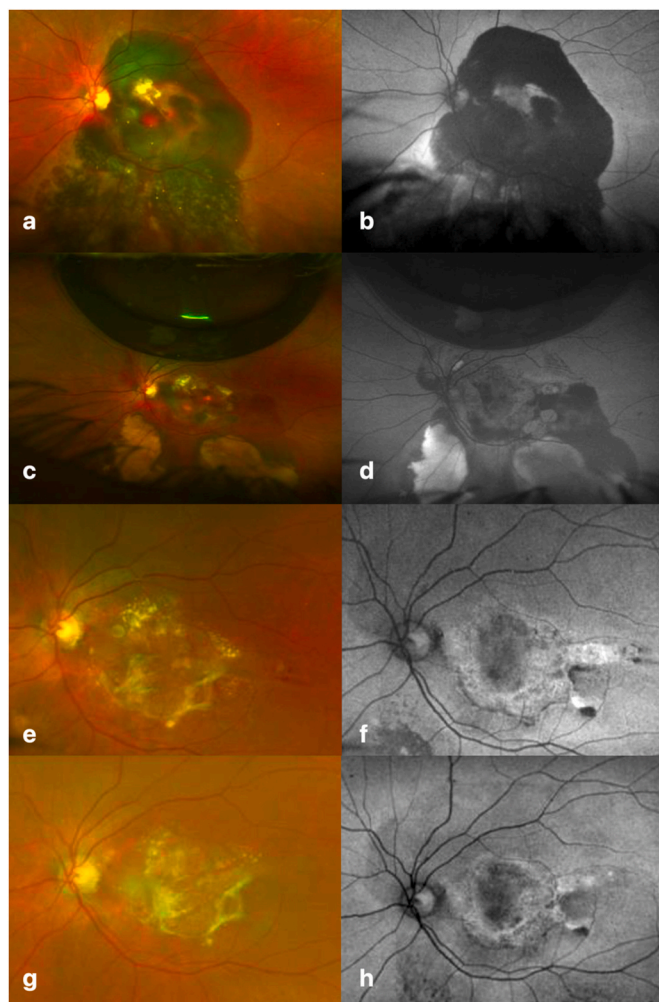


Fig. 1. Case 1 - Optos fundus and autofluorescence image showing the presence of a massive sub-macular hemorrhage (SMH) extending beyond the arcades at baseline (a, b). Two weeks after treatment with intravitreal injection (IVI) brolucizumab + intravitreal recombinant tissue plasminogen activator (rtPA) + 0.3 cc C3F8 gas injection, there was considerable reduction in SMH with presence of residual C3F8 gas bubble (c, d). At one month, trace residual SMH was present (e, f) which completely resolved by the end of three months (g, h).

BCVA gradually improved to 20/200 at two months and 20/120 at three months respectively. The patient continues to be under close observation with an absence of any SMH (Fig. 3 c) and OCT biomarker of disease activity at 8 and 12 weeks (Fig. 4 c, d). No serious adverse events were noted at any of the visits.

2.3. Case 3

An 86-year-old male presented with decreased vision OS for 4 days. He had an active treatment-naïve nAMD with SMH in OS (Fig. 5 a, b) and a scarred nAMD in OD. His BCVA was 20/800 in OD and 20/120 in OS. The SD-OCT revealed the presence of a large FVPED along with sub retinal hyperreflective membrane (SHRM) (Fig. 6 a) in the OS. For the OS SMH, the patient underwent IVI brolucizumab + rtPA + C3F8 gas injection. The patient responded considerably well and showed considerable reduction of SMH at 4 weeks (Fig. 5 c, d), with improvement in BCVA to 20/60. The presence of SHRM and residual SRF was noted on SD-OCT (Fig. 6 b) for which the patient underwent a second dose of IVI brolucizumab at 1 month. One month later, there was a complete resolution of SMH (Fig. 5 e, f), SD OCT revealed a shallow PED (Fig. 6 c), with improvement in BCVA to 20/40. Third dose of IVI

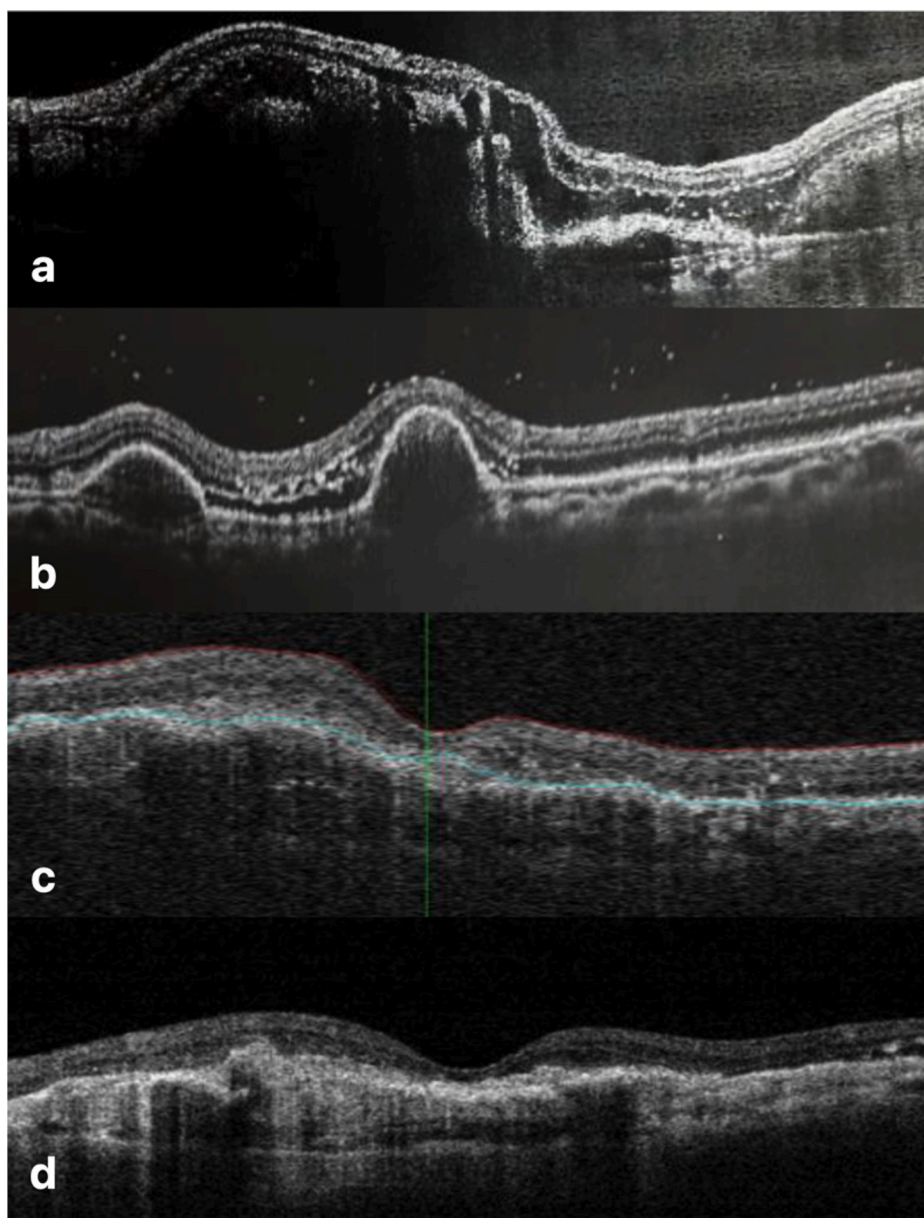


Fig. 2. Case 1 – Spectral domain optical coherence tomography (SD-OCT) image demonstrating the massive sub-macular hemorrhage (SMH) with pigment epithelial detachment (PED) and intra retinal fluid (IRF) at baseline (a). Two weeks post triple therapy, there was significant improvement in the retinal architecture with the presence of trace subretinal fluid (SRF) and fibrovascular pigment epithelial detachments (FVPEDs; b). The macula was completely dry at months 1 (c) and 3 (d), along with flattening of the FVPEDs.

Brolucizumab was administered and the patient is yet to follow-up. At all visits, there were no safety concerns with the brolucizumab injection. The patient is scheduled for follow-up.

3. Discussion

The purpose of our case series was to evaluate the role of IVI brolucizumab in conjunction with rtPA and C3F8 gas in the management of SMH secondary to nAMD. Our results corroborate the efficacy of this newer anti-VEGF agent in the resolution of SMH with tomographic inactivation of the disease. Additionally, in our study, we observed no ocular or systemic adverse effects.

SMH is an infrequent, but visually devastating complication associated with nAMD.^{1,2} If left untreated, it can cause significant visual disability. In the Submacular Surgery Trial (SST), 60% and 70% of the patients in the observational arm had a visual acuity of 3/60 or worse at the end of 3 months and 24 months respectively.¹¹ Since the introduction of anti-VEGF agents, the management of nAMD has transformed dramatically. Anti-VEGF monotherapy not only makes the disease quiescent, but also helps address smaller macular bleeds. However, for

large SMH, additional pneumatic displacement of the blood from the subfoveal location is warranted for optimal visual outcomes.⁵ This can be achieved by a combination of intravitreal rtPA along with gas injection and post-procedure positioning to iron out the bleed. Stanescu-Segall D et al.⁵ performed a literature review on various treatment modalities for SMH. In their combined analysis of 5 studies, the rate of effective displacement of SMH was 76% (62/81 eyes) with an overall improvement in vision across the board.⁵ Furthermore, triple therapy with an anti-VEGF agent, rtPA, and gas resulted in a significant improvement in visual acuity ($\geq 20/100$) in 58 patients with baseline visual acuity of $\leq 20/200$.⁵

The timing of this combination treatment plays a major role in final visual outcomes. Hattenbach LO et al.¹² have demonstrated that the best visual outcomes are obtained when patients are treated during the early phase of the hemorrhage (≤ 14 days). Earlier treatment by pneumatic displacement, within the first four days of the bleed, was also shown to achieve the best visual outcomes by Sobolewska B et al.¹³ In our series too, all the three patients were treated within the first 4 days of bleed, which enabled us to achieve good anatomical and visual outcomes.

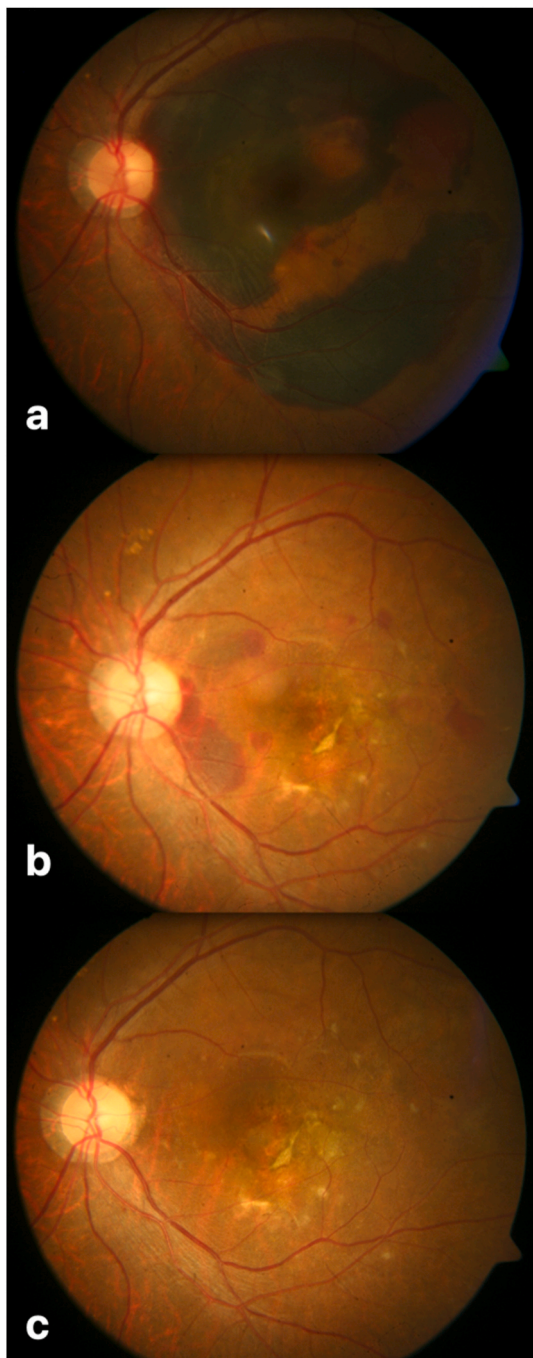


Fig. 3. Case 2 - Fundus image showing presence of a large sub-macular hemorrhage (SMH) at baseline (a) which gradually reduced over a month (b) and completely disappeared by three months (c) after the triple therapy (Intravitreal injection brolocizumab + intravitreal recombinant tissue plasminogen activator [rtPA] + 0.3 cc C3F8 gas injection).

Amongst the various anti-VEGF agents available, bevacizumab and ranibizumab have been commonly used as a component of triple therapy for SMH.^{5,7,8} Klettner A¹⁴ have shown that when combined with plasmin, aflibercept is cleaved by rtPA, and its ability to bind VEGF is diminished. Due to this reason, it is not a preferred agent in the form of triple therapy for large SMH. The newer agent brolocizumab is a single-chain humanized antibody fragment that is only 26 kDa in weight.⁹ Brolocizumab's effective molar dose is 22-fold more than ranibizumab and 12-fold greater than aflibercept due to its low molecular weight, which is 1/4th that of aflibercept and 1/1.8th that of

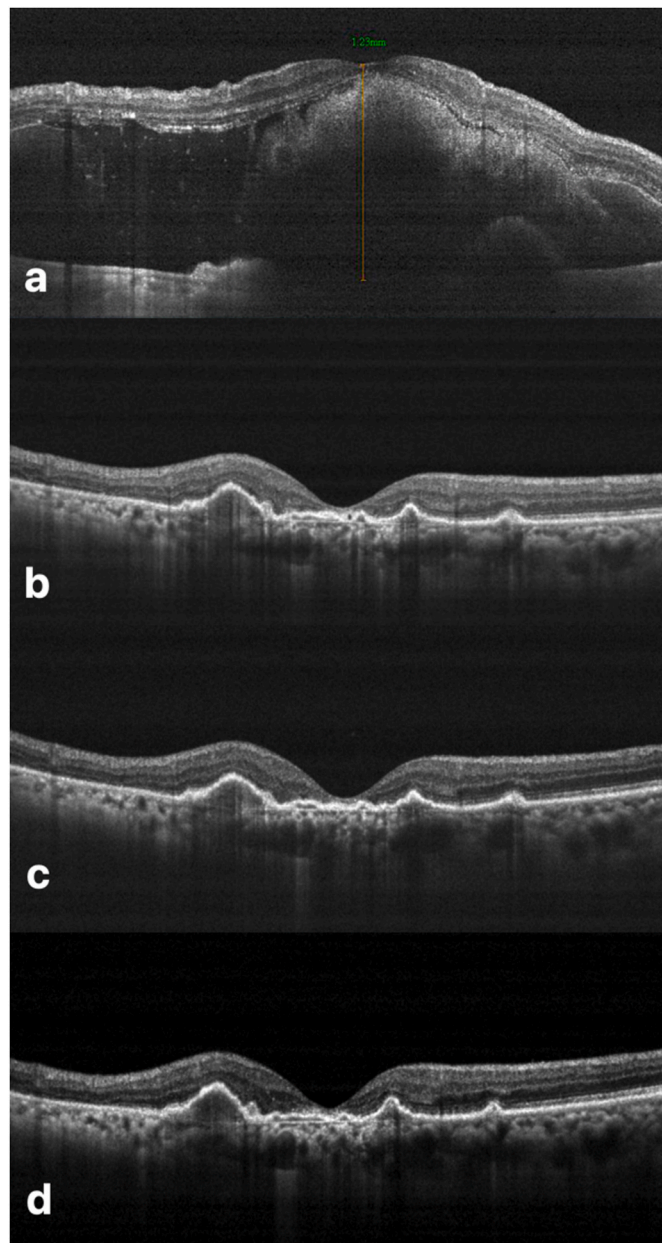


Fig. 4. Case 2 - Spectral domain optical coherence tomography (SD-OCT) image illustrating the large sub-macular hemorrhage (SMH) at baseline (a). After the triple therapy, there was complete resolution of SMH with a dry macula and presence of fibrovascular pigment epithelial detachments at months 1 (b), 2 (c) and 3 (d) respectively.

ranibizumab.⁹ With lower molecular weight and a higher molar dose, the brolocizumab molecule should theoretically penetrate the retina tissue more effectively. Consecutively, there is putatively a greater therapeutic role of this agent when compared to the other anti-VEGF molecule. With this backdrop, all three patients in our series were offered therapy with the brolocizumab molecule in combination with rtPA and C3F8 injection. Although we achieved good therapeutic outcomes in our cases, we propose further electrophoretic studies to evaluate the compatibility of the brolocizumab molecule with rtPA in the presence of plasmin.

Episodes of intraocular inflammation (IOI) have been reported with IVI brolocizumab, with a reported incidence of around 4% in the HAWK and HARRIER studies.¹⁰ In the post-marketing surveillance, the incidence of Retinal vasculitis +/-retinal vascular occlusion was 15.1 per 10,

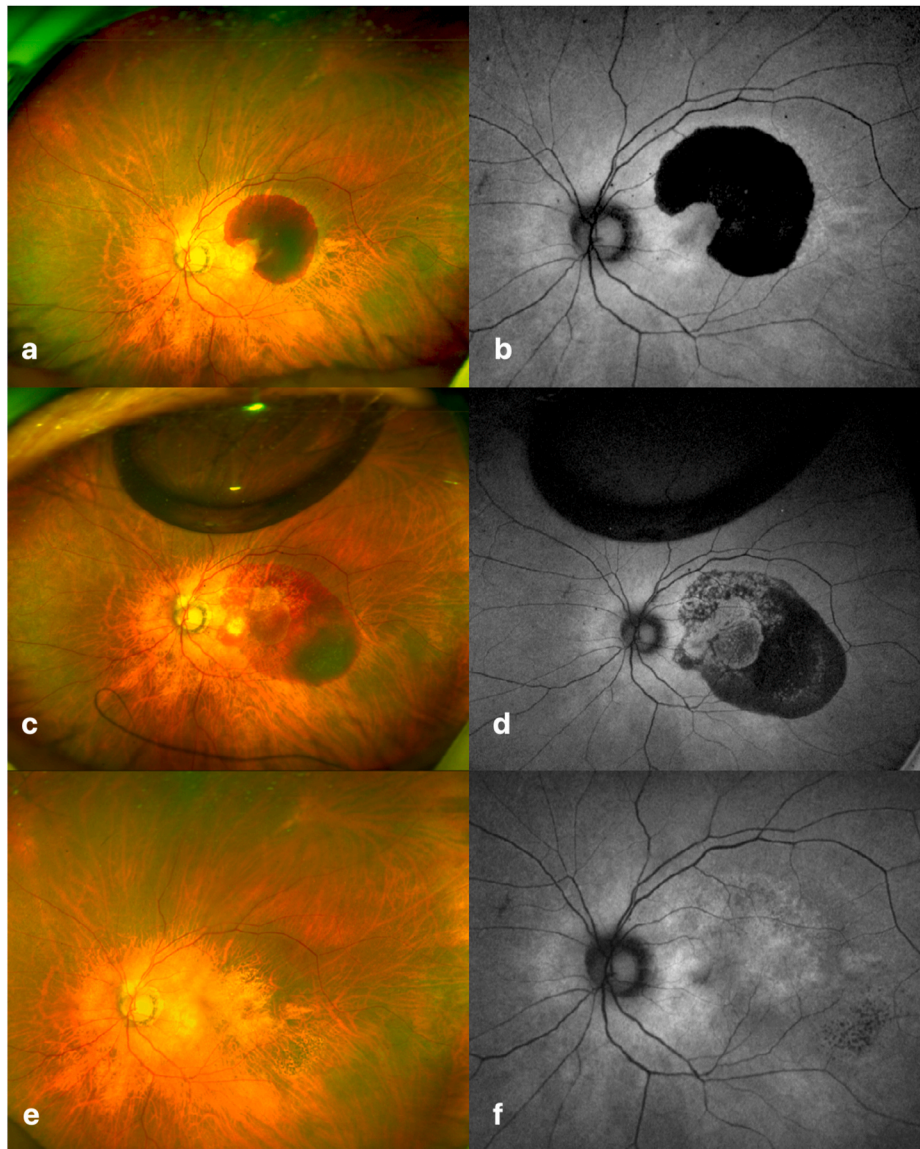


Fig. 5. Case 3 - Optos fundus and autofluorescence image demonstrating the large sub-macular hemorrhage (SMH) at baseline (a). One month post-triple therapy (intravitreal injection (IVI) brolocizumab + intravitreal recombinant tissue plasminogen activator [rtPA] + 0.3 cc C3F8 gas injection), the SMH had considerably reduced (b) which subsequently completely resolved by two months (c) after IVI brolocizumab was repeated.

000 injections (till October 9, 2021).¹⁵ Correspondingly, our group recently reported the first Indian real-world data (BRAILLE Study) regarding the safety and efficacy of IVI brolocizumab in nAMD eyes.¹⁶ We noted a significant improvement in BCVA and central subfield thickness (CST) over a mean follow-up of 7.3 ± 2.2 (range 5–30) weeks.¹⁶ Interestingly, no episodes of IOIs were observed after 126 injections in our BRAILLE study.¹⁶ Since the data primarily consisted of Indian eyes, the authors emphasized the importance of further research into the impact of race and genetics in predisposing to/protecting against brolocizumab-related IOIs.¹⁶ In the current series too, we did not observe any ocular or systemic adverse events. Nonetheless, our series was too small with a short follow-up period, and hence insufficiently powered for safety analysis.

The relatively small number of cases and the short follow-up period are two of the study's major limitations. Additionally, we do not have the electrophoretic data to evaluate the molecular interaction of brolocizumab with rtPA and plasmin. Further long-term studies with a larger sample size along with a focus on evaluating the biological activity of the brolocizumab molecule in the presence of other

pharmacological agents such as rtPA are warranted.

4. Conclusion

This is the first reported series of IVI brolocizumab therapy along with rtPA and gas injection in the successful management of large SMH secondary to nAMD. Triple therapy with brolocizumab helps in the displacement of the SMH along with good visual outcomes. Further studies are warranted to validate our results and assess the long-term anatomical and visual outcomes of this combination treatment.

Patient consent

Written informed consent was obtained from patients for publication of these case reports and any accompanying images.

Funding

No funding or grant support.

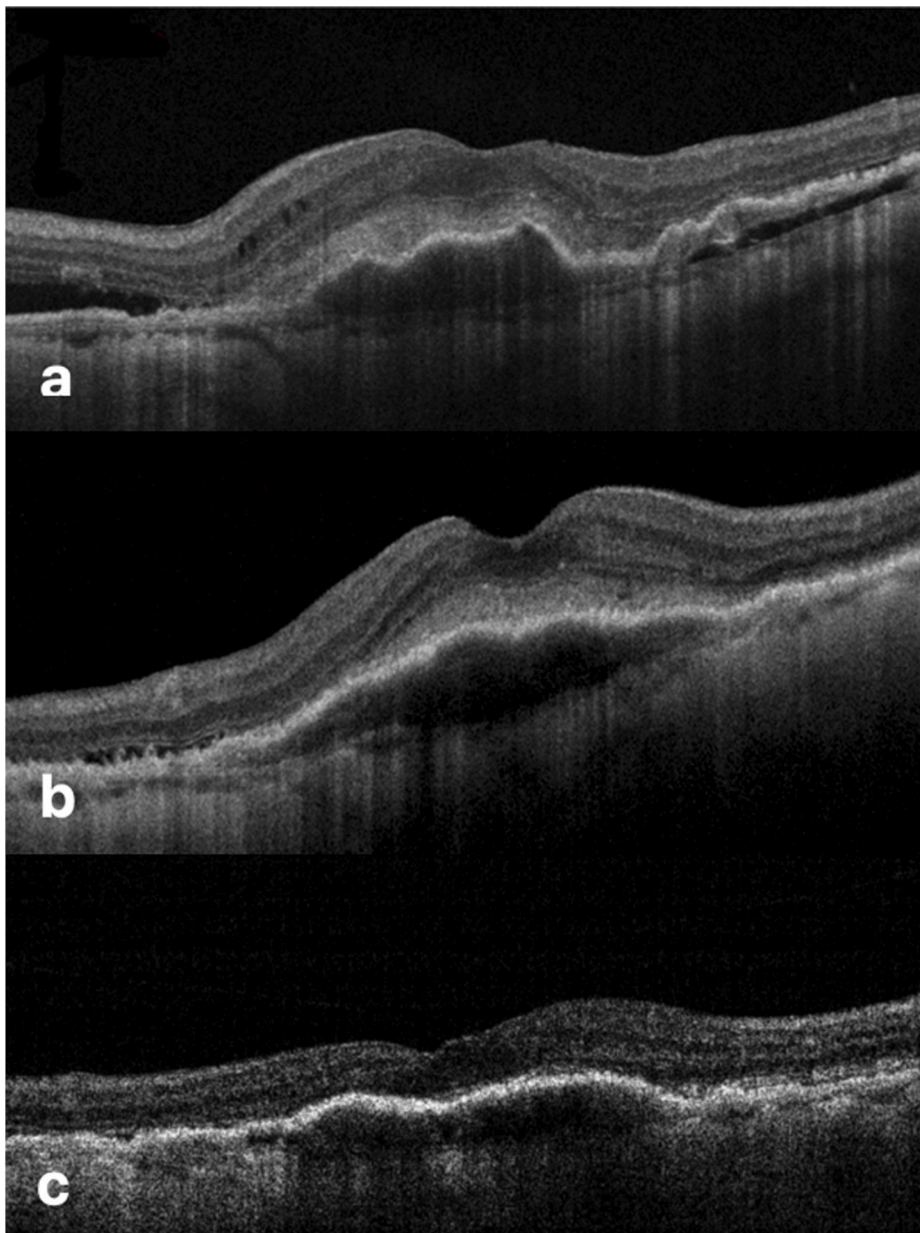


Fig. 6. Case 3 - Spectral domain optical coherence tomography (SD-OCT) image showing the presence of a large fibrovascular pigment epithelial detachment (FVPED), with sub-retinal hyperreflective membrane (SHRM), intraretinal fluid (IRF) and subretinal fluid (SRF) at baseline (a). One month after undergoing triple therapy, the IRF completely resolved along with an improvement in SHRM and SRF as seen on SD-OCT (b). After the second dose of IVI brolucizumab was administered, the SRF and the SHRM completely resolved with a significant reduction in the height of FVPED at two months (c).

Authorship

All authors attest that they meet the current ICMJE criteria for Authorship.

Declaration of competing interest

The following authors have no financial disclosures: DC, JS, SM, SB.

Acknowledgements

None.

References

- Hochman MA, Seery CM, Zarbin MA. Pathophysiology and management of subretinal hemorrhage. *Surv Ophthalmol.* 1997 Nov-Dec;42(3):195–213.
- Kim JH, Chang YS, Lee DW, Kim CG, Kim JW. Quantification of retinal changes after resolution of submacular hemorrhage secondary to polypoidal choroidal vasculopathy. *Jpn J Ophthalmol.* 2018;62(1):54–62.
- Toth CA, Morse LS, Hjelmeland LM, Landers 3rd MB. Fibrin directs early retinal damage after experimental subretinal hemorrhage. *Arch Ophthalmol.* 1991;109(5):723–729.
- Karamitsos A, Papastavrou V, Ivanova T, et al. Management of acute submacular hemorrhage using intravitreal injection of tissue plasminogen activator and gas: a case series. *SAGE Open Med Case Rep.* 2020;8, 2050313X20970337.
- Stanescu-Segall D, Balta F, Jackson TL. Submacular hemorrhage in neovascular age-related macular degeneration: a synthesis of the literature. *Surv Ophthalmol.* 2016;61(1):18–32.
- Grohmann C, Dimopoulos S, Bartz-Schmidt KU, et al. Surgical management of submacular hemorrhage due to n-AMD: a comparison of three surgical methods. *Int J Retina Vitreous.* 2020;6:27.
- Shienbaum G, Garcia Filho CA, Flynn Jr HW, et al. Management of submacular hemorrhage secondary to neovascular age-related macular degeneration with anti-vascular endothelial growth factor monotherapy. *Am J Ophthalmol.* 2013;155(6):1009–1013.
- Kim JH, Kim CG, Lee DW, et al. Intravitreal aflibercept for submacular hemorrhage secondary to neovascular age-related macular degeneration and polypoidal choroidal vasculopathy. *Graefes Arch Clin Exp Ophthalmol.* 2020;258(1):107–116.
- Chakraborty D, Sheth JU, Boral S, Sinha TK. Off-label intravitreal brolucizumab for recalcitrant diabetic macular edema: a real-world case series. *Am J Ophthalmol Case Rep.* 2021;24, 101197. Published 2021 Sep. 1.
- Dugel PU, Singh RP, Koh A, et al. HAWK and HARRIER: ninety-six-week outcomes from the phase 3 trials of brolucizumab for neovascular age-related macular degeneration. *Ophthalmology.* 2021;128(1):89–99.

11. Bressler NM, Bressler SB, Childs AL, et al. Surgery for hemorrhagic choroidal neovascular lesions of age-related macular degeneration: ophthalmic findings: SST report no. 13. *Ophthalmology*. 2004;111(11):1993–2006.
12. Hattenbach LO, Klais C, Koch FH, Gümber HO. Intravitreal injection of tissue plasminogen activator and gas in the treatment of submacular hemorrhage under various conditions. *Ophthalmology*. 2001;108(8):1485–1492.
13. Sobolewska B, Utebey E, Bartz-Schmidt KU, Tatar O. Long-term visual outcome and its predictive factors following treatment of acute submacular hemorrhage with intravitreal injection of tissue plasminogen factor and gas. *J Ocul Pharmacol Therapeut*. 2014;30(7):567–572.
14. Klettner A, Grotelüschen S, Treumer F, Roeder J, Hillenkamp J. Compatibility of recombinant tissue plasminogen activator (rtPA) and aflibercept or ranibizumab coapplied for neovascular age-related macular degeneration with submacular haemorrhage. *Br J Ophthalmol*. 2015;99(6):864–869.
15. Post-marketing data. Available at <https://www.brolucizumab.info/post-marketing-data>. Accessed September 10, 2021.
16. Chakraborty D, Maiti A, Sheth JU, et al. Brolucizumab in neovascular age-related macular degeneration - Indian real-world experience: the BRAILLE study. *Clin Ophthalmol*. 2021;15:3787–3795.