

ORIGINAL ARTICLE

COVID-19 and kidney transplant recipients

Sara Abolghasemi | Masoud Mardani | Shahnaz Sali | Negin Honarvar |
Mana Baziboroun 

Infectious Diseases and Tropical Medicine
Research Center, Shahid Beheshti University
of Medical Sciences, Tehran, Iran

Correspondence

Mana Baziboroun, Infectious Diseases and
Tropical Medicine Research Center, Shahid
Beheshti University of Medical Sciences,
Tehran, Iran.
Email: manabaziboroun@gmail.com

Abstract

Background: The novel coronavirus has become a global threat and healthcare concern. The manifestations of COVID-19 pneumonia in transplant patients are not well understood and may have more severe symptoms, longer duration, and a worse prognosis than in immunocompetent populations.

Aims: This study proposed to evaluate the clinical characteristics of COVID-19 pneumonia in kidney transplant recipients.

Patients/Methods: Clinical records, laboratory results, radiological characteristics, and clinical outcome of 24 kidney transplant patients with COVID-19 pneumonia were evaluated from March 20, 2020, to May 20, 2020.

Results: The most common symptom was shortness of breath (70.8%), followed by fever (62.5%) and cough (45.8%). Five patients had leukopenia, and only one patient had leukocytosis, while 75% of the patients had a white blood cell (WBC) count in the normal range, and 79% of recipients developed lymphopenia. All of the patients had an elevated concentration of C-reactive protein and an increase in blood urea levels. Chest CT images of 23 patients (95.8%) showed typical findings of patchy ground-glass shadows in the lungs. Of the 24 patients, 12 were admitted to ICU (invasive care unit), and ten of 24 patients (41.6%) died, and 14 patients were discharged after complete recovery.

Conclusion: It seems that COVID-19 is more severe in transplant patients and has poorer outcomes. Multiple underlying diseases, low O₂ saturation, and multilobar view in chest CT scan may be of prognostic value. However, many SARS-CoV-2 demonstrations are similar to those of the general population.

KEYWORDS

COVID-19, immunosuppression, kidney transplant, SARS-CoV-2

1 | INTRODUCTION

The novel coronavirus, also known as SARS-CoV-2 or COVID-19, emerged in China and rapidly spread all over the world and became a global threat and healthcare concern. The infected patients' symptoms ranged from asymptomatic to severe. Fever (98%), cough (76%), dyspnea (55%), myalgia, and fatigue (44%) are the most

common complaints of patients. However, despite the respiratory system, involvement of other organs, including cardiac, gastrointestinal, kidney, and nervous system involvement, has been reported too.¹⁻⁴ In kidney transplant patients, because of their status of immunosuppression, the clinical manifestation, course of the disease, and prognosis of COVID-19 pneumonia may differ from the general population. Also, unlike the general population that has lymphopenia

up to 63%, many kidney transplant recipients have drug-induced lymphopenia, so we cannot get help from this finding to diagnosis.⁵

To date, several studies have reported the demographic, clinical, laboratory, and radiological data of patients with COVID-19 pneumonia. But these reports are mostly in the general population with healthy immunity before the disease occurred. Given that both innate and adaptive immunity play essential roles in the clearance of virus, the manifestation of COVID-19 pneumonia in immune-compromised patients is not well understood and may have more severe symptoms, longer duration, and a worse prognosis than in immunocompetent populations.⁶ In this study, we present 24 kidney transplant recipients with confirmed COVID-19 pneumonia who had been hospitalized in two tertiary hospitals, Tehran, Iran.

2 | MATERIALS AND METHODS

2.1 | Study design and patients

This descriptive cross-sectional study was done in two tertiary hospitals of Tehran, Iran, for two months, from March 20, 2020, to May 20, 2020. During this period, a total of 24 kidney transplant recipients with COVID-19 pneumonia admitted to these hospitals were enrolled in this study. Diagnosis of SARS-CoV-2 pneumonia was based on positive quantitative RT-PCR from a nasopharyngeal sample (tested in Iranian reference for Influenza and COVID-19 WHO celebratory center) or typical finding of COVID-19 on chest CT scan. The Medical Ethical Committee approved this study of Shahid Beheshti University. Written informed consent was obtained from each enrolled patient.

2.2 | Data collection

We developed a questionnaire about the epidemiological, clinical, laboratory, and radiological characteristics of the patients, as well as treatment and clinical outcome data. After obtaining consent, we filled the questionnaire for each patient. The data were reviewed by two study investigators independently to verify data accuracy.

2.3 | Statistical analysis

Statistical analysis was done with SPSS, version 20.0. Continuous variables were expressed as a range, and categorical variables were as the number.

3 | RESULTS

Among the 24 patients with COVID-19 pneumonia, 62.5% were male, and the mean age was 49 years (range, 29 to 64). The time range after transplantation was 1-20 years, with the meantime of

10.3 years. Eighteen recipients (83.3%) had received a deceased-donor kidney. Only one patient had a history of smoking tobacco, and all 24 patients had a BMI (body mass index) less than 40. Table 1 shows the detailed clinical characteristics of 24 patients. 62.5% of patients had hypertension, and 20% had diabetes mellitus. Among immunosuppressive regimens, all patients were receiving prednisolone, 83.3% were receiving mycophenolate mofetil (MMF), 41.6% tacrolimus, and 50% cyclosporine.

The most common symptom was shortness of breath (in 17 patients [70.8%]), followed by fever (62.5%), cough (45.8%), and chills (33.3%). The highest body temperature was 38.9 °C. Data from laboratory tests showed that 5 patients with COVID-19 pneumonia (20.8%) had leukopenia (<4000 per mm³) and only one patient had leukocytosis (>11 000 per mm³) while 75% of the patients had a white cell count in the normal range. A total of 19 patients (79%) developed lymphopenia (<1100 per mm³), and the lowest lymphocyte count was 165 per mm³, with the mean of 893.5 lymphocytes per mm³. All of the patients had an elevated concentration of C-reactive protein (CRP) (>10 mg/L) with a range of (11-88 mg/L). Additionally, an increase in blood urea levels was also observed in all recipients (32-227 mg/dL), and 18 patients (75%) had elevated serum creatinine (cr) level with a mean of 3.026 mg/dL.

On admission, 16 patients (66.6%) had an O₂ saturation of less than 93%. All patients had a non-contrast chest CT scan. Chest CT images of 23 patients (95.8%) had typical findings of patchy ground-glass shadows in the lungs in addition to other views, and 41.6% of patients showed multilobar pattern on chest CT scans. In 20 patients (83.3%), bilateral pulmonary involvement was seen, predominantly on the right side (Figure 1).

On admission, the dose of immunosuppressive agents was reduced under consultation with a nephrologist and an infectious disease specialist. All of the patients received hydroxychloroquine (HCQ), and Kaletra (lopinavir/ritonavir) was administered to 18 patients (75%). Intravenous immunoglobulin (IVIG) was administered to 8 patients (33%) with severe pneumonia and hypoxemia. And finally, 3 patients received hemoperfusion in acute respiratory distress syndrome (ARDS) phase. Of the 24 patients, 12 were admitted to ICU, and despite all the measures taken, ten of 24 patients (41.6%) died, and 14 patients were discharged after complete recovery. The median hospital stay between the discharged patients was 6.6 days (range 5-9 days), and the median time to stay in the hospital for those who died was 18 days, with the most prolonged hospital stay of 22 days. In patients with more than one underlying disease, the rate of mortality was higher than patients with one or without the underlying disease (50% versus 14%, OR: 6.48, 95% CI: 1.30 to 32.29, *P*: .02). Also, patients with multilobar involvement on chest CT scans had significantly higher mortality than patients with other pulmonary involvement patterns (90% versus 7%, OR: 24, 95% CI: 2.78 to 206.96, *P*: .003) (Figure 2). The mortality rate among patients who had O₂ saturation less than 93% on admission also was higher than those with O₂ saturation more than 93% (80% versus 35.7%, OR: 7.2, 95% CI: 1.08 to 47.96, *P*: .04) (Figure 3).

TABLE 1 Clinical and radiological characteristics in kidney transplant recipients

Variable	Value
Demographic features	
Male—no./total no. (%)	15/24 (62.5)
Female—no./total no. (%)	9/24 (37.5)
Age—mean (range)—years	49 (29-64)
Living-donor kidney—no./total no. (%)	6/24 (25)
Deceased-donor kidney—no./total no. (%)	18/24 (75)
Time after transplantation—mean (range)—years	10.3 (1-20)
Clinical manifestation—no./total no. (%)	
Fever	15/24 (62.5)
Chilling	8/24 (33.3)
Cough	11/24 (45.8)
Shortness of breath	17/24 (70.8)
Myalgia	7/24 (29)
Diarrhea	6/26 (25)
Malaise	5/24 (20.8)
Loss of appetite	4/24 (16.6)
Vomiting	3/24 (12.5)
Underlying Disease—no./total no. (%)	
DM	5/24 (20)
HTN	15/24 (62.5)
IHD	4/24 (16.6)
COPD	1/24 (4.1)
NON	4/24 (16.6)
History of immunosuppressive therapy—no./total no. (%)	
Prednisolone	24/24 (100)
MMF	20/24 (83.3)
Cyclosporine	12/24 (50)
Tacrolimus	10/24 (41.6)
Sirolimus	1/24 (4.1)
Azathioprine	2/24 (8.3)
Laboratory finding—no./total no. (%)	
WBC < 4000/mm ³	5/24 (20.8)
4000 < WBC <11 000/mm ³	18/24 (75)
WBC > 11 000/mm ³	1/24 (4.1)
Lymphocyte count < 1100/mm ³	19/24 (79)
Hemoglobin < 14 (gr/dL)	21/24 (87.5)
CRP > 10 (mg/L)	24/24 (100)
Cr > 1.4 (mg/dL)	18/24 (75)
LDH > 480 (IL/mL)	8/17 (47)
CPK > 195 (IL/L)	4/19 (21)
Alb < 3.5 (gr/L)	13/18 (72)
35 ALT> (U/L)	5/23 (21/7)
PCR +	16/24 (66.6)

(Continues)

TABLE 1 (Continued)

Variable	Value
Chest CT scan patterns—no./total no. (%)	
Ground-glass	23/24 (95.8)
Multilobar	10/24 (41.6)
Bilateral	20/24 (83.3)
Treatment for COVID-19—no./total no. (%)	
HCCQ	24/24 (100)
Kaletra	18/24 (75)
Oseltamivir	12/24/(50)
Ribavirin	6/24 (25)
Favipiravir	1/24 (4/1)
Hemoperfusion	3/24 (12.5)
IVIG	8/24 (33)
Outcomes—no./total no. (%)	
ICU admission	12/24 (50)
Discharged from hospital	14/24 (58.3)
Death	10/24 (41.6)

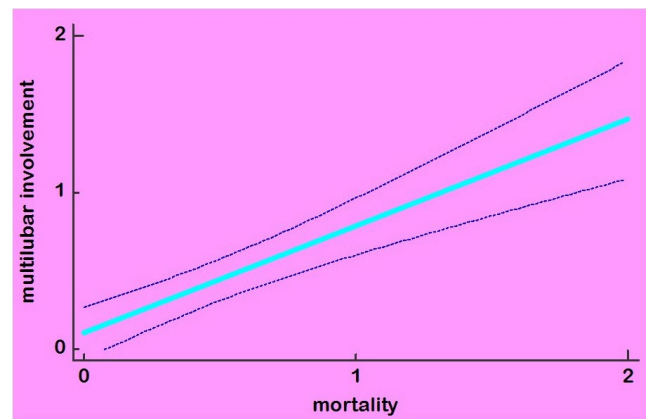


FIGURE 1 The relationship between the multilobar pattern on CT scan and mortality

4 | DISCUSSION

COVID-19 can cause fatal respiratory tract infections and extrapulmonary manifestation. T cells play an essential antiviral role, the reduction of CD8+ T cells does not delay viral replication in SARS-CoV infection, and depletion of CD4 +T cells results in an immune-mediated interstitial pneumonitis and delayed clearance of COVID-19 from lungs.⁷ Transplant patients suffer from immunosuppression due to their drugs, so they are at high risk for complications if they become infected with COVID-19. We report clinical data from 24 kidney transplant recipients with COVID-19 pneumonia.

Kidney transplant recipients may have atypical clinical manifestation as a result of immunosuppression,⁸ but according to our study, this group of patients showed a similar pattern of clinical characteristics to the general population. Typical symptoms on admission included shortness of breath, fever, and cough, but the percentage

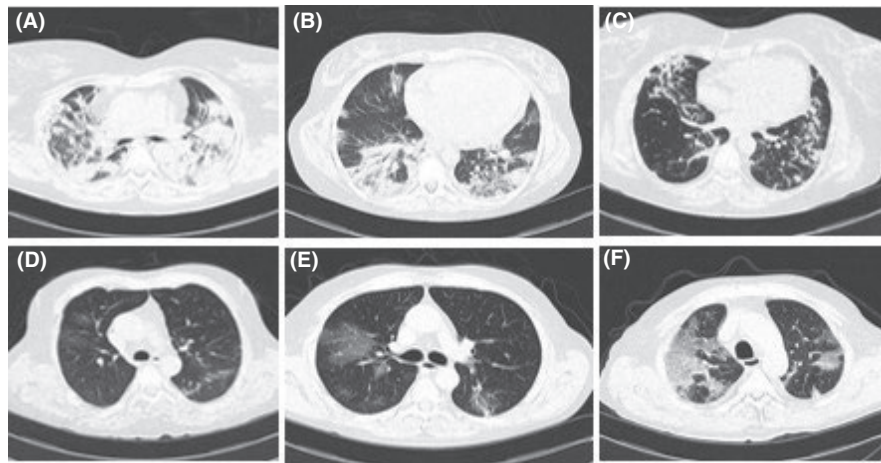


FIGURE 2 A, 50-year-old woman presented with a dry cough, dyspnea and myalgia, and a history of kidney transplantation 17 y ago that had multiple bilateral ground-glass opacity and consolidation with air bronchogram in chest CT scan. She was discharged after a lengthy hospital stay. B, Her latest CT scan showed some resolution of the pulmonary infiltrates. C, Chest CT scan of a 53-year-old man with fever and cough and history of kidney transplantation that shows typical ground-glass opacities. He had made a full recovery and was discharged after 1 wk of hospitalization. D, A 43-year-old woman with a history of kidney transplantation from 15 y ago presented with chilling and dyspnea. Her chest CT scan showed bilateral consolidation and patchy ground-glass opacities. She deteriorated rapidly and died. E, Chest CT scan from a 62-year-old man with a history of kidney transplantation that shows bilateral ground-glass opacities. F, His chest CT scan that obtained 5 d after the first CT scan shows a crazy-paving pattern. He died after 10 d hospitalization in ICU

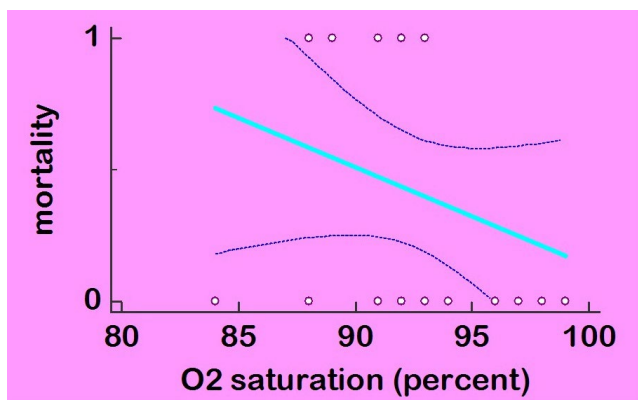


FIGURE 3 The relationship between O_2 saturation and mortality

of shortness of breath higher than in other studies (70.8%).⁶ In Envar Akalin's report,⁹ diarrhea was the most common presenting symptom. Laboratory tests indicated leukopenia in 20.8% and

lymphopenia in 79% of patients, and normal white blood cell count was more frequent in our study, as Alireza Abrishami¹⁰ reported in their case series, while in Fishman and Grossi's study,¹¹ leukopenia was the characteristic finding. Besides, the most common pattern in chest CT scan was bilateral peripheral ground-glass opacity was similar to the general population, but the multilobar pattern was more frequent among patients who needed ICU and had a poor prognosis. Two patients developed pneumothorax, and both of them were expired (Figure 4).

Management of the patient's immunosuppressive medication regimens remains a challenge due to the lack of data about COVID-19. Decisions in this regard must be taken on a case-by-case considering factors such as time since transplantation, baseline graft function, and age.¹¹ Despite the apparent concern about the risk of rejection with the reduction in immunosuppression, due to the high mortality rate in hospitalized patients with COVID-19 pneumonia, we stopped or reduced the dose of immunosuppressive agents as previously reported, as other clinicians in other studies did.^{6,12}

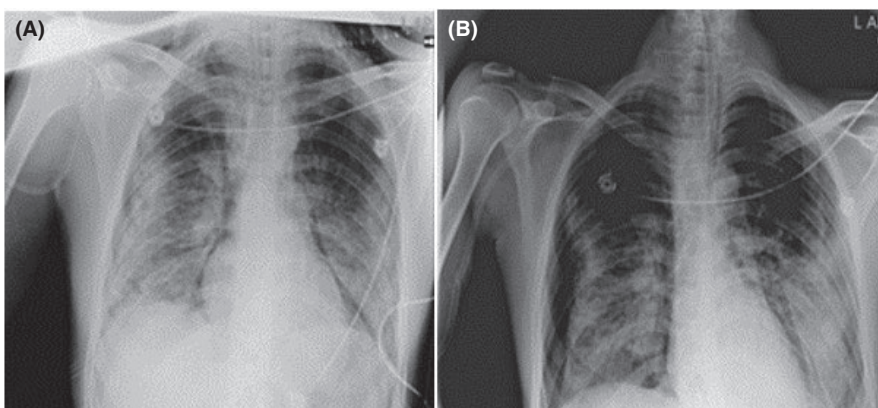


FIGURE 4 A, Chest x-ray from a 58-year-old man with a history of DM, HTN, and kidney transplantation that shows patchy bilateral consolidation. He died after 2 wk. B, His latest image shows the right pneumothorax

Currently, it is unclear whether transplant recipients are more likely to develop severe forms of the disease.⁵ In our study, in patients with more than one underlying disease and patients who had O₂ saturation less than 93% on admission, the mortality rate was higher. Also, patients with multilobar involvement on chest CT scan had significantly higher mortality, and (due to the OR: 24), multilobar pattern in chest CT scan was the most effective factor in mortality in our study, and it was even more critical than O₂ saturation (OR: 24 vs OR: 7.2). But there was no significant association between mortality with lymphopenia (OR: 0.9, 95% CI: 0.11 to 7.4, P: 0.95). Due to the small size of our study, these findings may not be generalizable to all transplant patients. Enver Akalin reported a very high early mortality among kidney transplant recipients with COVID-19 (28% at 3 weeks) as compared with the general population,^{5,13} and our study also showed similar results (41.6% mortality).

5 | CONCLUSION

We conclude that COVID-19 is more severe in transplant patients and has poorer outcomes. Multiple underlying diseases, low O₂ saturation, and multilobar view in chest CT scan may be of prognostic value. However, many SARS-CoV-2 demonstrations are similar to those of the general population. Although the small sample size limits our study, we believe that the findings we reported are going to help to understand the clinical characteristics of COVID-19 in transplant patients.

ACKNOWLEDGEMENTS

All authors met four criteria for authorship contribution based on recommendations of the International Committee of Medical Journal Editors. The authors would like to represent their thankfulness to the Department of Infectious Disease, Shahid Beheshti University of medical sciences. No financial support.

CONFLICT OF INTEREST

No conflict of interest was reported regarding this study.

AUTHOR CONTRIBUTIONS

Mana Baziboroun had full access to data in the study and responsibility of the integrity of the data and drafting of the manuscript. Masoud Mardani involved in study concept and design. Negin Honarvar involved in acquisition of data. Shahnaz Sali involved in analysis and interpretation of data. Sara Abolghasemi involved in critical revision of the manuscript.

ORCID

Mana Baziboroun  <https://orcid.org/0000-0001-6251-9682>

REFERENCES

1. Liang W, Guan W, Chen R, et al. Cancer patients in SARS-CoV-2 infection: a nationwide analysis in China. *Lancet Oncol.* 2020;21(3):335-337.
2. James M, Marguerite L, Tomasz Z, James B. Pharmacologic treatments for coronavirus disease 2019 (COVID-19). *JAMA.* 2020;323(18):1824-1836.
3. Diseases AAftSoL. Clinical insights for hepatology and liver transplant providers during the COVID-19 pandemic. In:2020.
4. , Sharifi razaviA., Karimi N., Zarvani A.. Ischemic stroke associated with novel coronavirus 2019: a report of three cases. *International Journal of Neuroscienc.* 2020. <https://doi.org/10.1080/00207454.2020.1782902>
5. Sharifi-Razavi A, Karimi N, Rouhani N. COVID-19 and intracerebral haemorrhage: causative or coincidental? *New Microbes New Infect.* 2020;35:100669.
6. Liu H, He X, Wang Y, et al. Management of COVID-19 in patients after liver transplantation: Beijing working party for liver transplantation. *Hepatal Int.* 2020;1-5.
7. Zhu L, Gong N, Liu B, et al. Coronavirus disease 2019 pneumonia in immunosuppressed renal transplant recipients: a summary of 10 confirmed cases in Wuhan, China. *Eur Urol.* 2020;77(6):748-754.
8. Caselli D, Aricò M. 2019-nCoV: polite with children!. *Pediatr Rep.* 2020;12(1):8495.
9. Yang X, Yu Y, Xu J, et al. Clinical course and outcomes of critically ill patients with SARS-CoV-2 pneumonia in Wuhan, China: a single-centered, retrospective, observational study. *Lancet Respir Med.* 2020;8(5):475-481.
10. Akalin E, Azzi Y, Bartash R, et al. Covid-19 and kidney transplantation. *N Engl J Med.* 2020;382(25):2475-2477.
11. Abrishami A, Samavat S, Behnam B, Arab-Ahmadi M, Nafar M, Taheri MS. Clinical course, imaging features, and outcomes of COVID-19 in kidney transplant recipients. *Eur Urol.* 2020. <https://doi.org/10.1016/j.eururo.2020.04.064>
12. Fishman JA, Grossi PA. Novel coronavirus-19 (COVID-19) in the immunocompromised transplant recipient: #Flatteningthecurve. *Am J Transplant.* 2020;20(7):1765-1767.
13. Banerjee D, Popoola J, Shah S, Ster IC, Quan V, Phanish M. COVID-19 infection in kidney transplant recipients. *Kidney Int.* 2020;97(6):1076-1082.
14. Huang C, Wang Y, Li X, et al. Clinical features of patients infected with 2019 novel coronavirus in Wuhan, China. *Lancet.* 2020;395(10223):497-506.

How to cite this article: Abolghasemi S, Mardani M, Sali S, Honarvar N, Baziboroun M. COVID-19 and kidney transplant recipients. *Transpl Infect Dis.* 2020;22:e13413. <https://doi.org/10.1111/tid.13413>