



Research Article

The Treatment Method and Results of Percutaneous Pinning and Dynamic External Fixator Application for Unstable Distal Radius Fractures

Adnan Kara,¹ Erden Ertürer,² Faik Seçkin,³ Şenol Akman,³ İrfan Öztürk⁴

¹Department of Orthopedics and Traumatology, Medipol University Faculty of Medicine, Istanbul, Turkey

²Department of Orthopedics and Traumatology, Istinye University Faculty of Medicine, Istanbul, Turkey

³Department of Orthopedics and Traumatology, Bilim University Faculty of Medicine, Istanbul, Turkey

⁴Department of Orthopedics and Traumatology, Istanbul University Faculty of Medicine, Istanbul, Turkey

Abstract

Objective: The aim of the present study was to present the results of patients with unstable distal radius fracture treated with closed reduction and percutaneous fixation followed by application of the Pennig dynamic wrist fixator to allow early wrist motion.

Methods: Twenty-five patients diagnosed with distal radius fracture and treated with closed reduction and percutaneous fixation followed by application of a dynamic wrist fixator were included in the study. There were 15 (60%) male and 10 (40%) female patients. The mean age of the patients was 47.32 (20–76) years. The mean period between initial trauma and operation was 8.52 (1–23) days. All patients were allowed active shoulder, elbow, and finger exercises immediately after surgery.

Results: Radiological evaluation was performed according to the criteria described by Sarmiento and modified by Lidström. Results were excellent in 12 (46.15%), good in 11 (42.30%), and fair in 3 (11.55%) patients. No patient had poor result. Functional scores were assessed according to the Gartland–Werley classification and modified by Sarmiento. Results were excellent in 14 (56%), good in 8 (32%), and moderate in 3 (12%) patients.

Conclusion: Use of the Pennig dynamic wrist fixator in the treatment of unstable distal radius fractures has advantages, such as ease of use, minimal surgical trauma, allowing early rehabilitation, and early return to daily activities as well as increased anatomical and functional results.

Keywords: Distal radius fracture; dynamic fixator; unstable fracture.

Please cite this article as "Kara A, Ertürer E, Seçkin F, Akman Ş, Öztürk İ. The Treatment Method and Results of Percutaneous Pinning and Dynamic External Fixator Application for Unstable Distal Radius Fractures. Med Bull Sisli Etfal Hosp 2018;52(3):173–178".

Distal radius fracture is the most common type of fracture among all bone fractures in the whole body.^[1] A standard treatment method has not been established although various surgical intervention methods and detection materials in the treatment of unstable fractures have been described. Surgical alternatives include grafting, arthroscopy-assisted reduction and stabilization in addition to percutaneous pinning or external fixator applica-

tion after closed reduction, pinning after limited open or open reduction, internal fixation, and combinations of all these interventions.^[2, 3]

Radius distal tip fracture is the most common type of fracture in whole body bone fractures.^[1] Though various surgical intervention methods and fixation materials in the treatment of unstable fractures have been described, a standard treatment method has not been established yet.

Address for correspondence: Dr. Adnan Kara. Department of Orthopedics and Traumatology, Medipol University Faculty of Medicine, Istanbul, Turkey

Phone: +90 505 395 14 75 **E-mail:** dradnankara@gmail.com

Submitted Date: April 11, 2018 **Accepted Date:** April 20, 2018 **Available Online Date:** September 27, 2018

©Copyright 2018 by The Medical Bulletin of Sisli Etfal Hospital - Available online at www.sislietfaltip.org

This is an open access article under the CC BY-NC-ND license (<http://creativecommons.org/licenses/by-nc/4.0/>).



Surgical treatment alternatives include percutaneous pinning or external fixator application after closed reduction, pinning after limited open or open reduction, and internal fixation. In addition to these interventions, combinations of all these interventions and arthroscopy-assisted reduction and stabilization may be enumerated.^[2, 3]

Whatever method is chosen, the basic prerequisite is to bring the radial length, radial inclination, and palmar inclination to the most appropriate level so as to allow anatomical repair of the distal radial articular surface.^[4]

In the present study, patients with distal radius fractures treated with the Pennig-type dynamic external fixator (Orthofix Srl, Italy) were followed up, and the results of treatment were evaluated radiologically, clinically, and functionally.

Methods

In the present study, 26 unstable distal radius fractures were evaluated in 25 patients surgically treated with a dynamic wrist external fixator. Fractures were evaluated according to the AO,^[5] Frykman,^[6] and Gustilo–Anderson open fracture classification.^[7] The radiological and anatomical results of the cases were evaluated according to the radiological criteria developed by Lidström and modified by Sarmiento. Statistical analysis was performed between pre- and post-reduction radial angulation, loss in radial height and palmar angulation measurements, and these measurements after removal of a fixator following achievement of dynamization. The measurements were compared with those of the robust side.

The functional results were evaluated by the scoring system developed by Gartland–Werley^[9] and modified by Sarmiento. Complications were recorded. Trauma etiologies of the patients were evaluated. Pediatric patients and open wrist fractures with vascular lesions were excluded from the study.

Ethics approval was obtained (decision no. 10840098/159). Radial angulation, radial height, and palmar angulation were evaluated using the Student's t-test. Based on the two-way p-value, etiologies for trauma and their distribution according to age groups were expressed as percentages (%).

Surgical Technique

Patients were brought to the operating room and placed in the supine position. The fracture was reduced after application of general or axillary block anesthesia. After the desired reduction was achieved, two K-wires crossing each other were sent proximally from the radial styloid and dorsomedial aspect of the radius under fluoroscopic control. In

addition, to prevent radial shortening, a parallel K-wire was sent to the radioulnar joint.

During application of a fixator, the distal Schanz pins were placed first. A 2 cm long dorsoradial incision site near the second metacarpal base was determined for the placement of the distal Schanz pins. Then, a 2 cm incision site at the dorsolateral aspect of the 10 cm proximal part of the radial styloid was determined for the placement of the proximal Schanz pins.

After placement of the Schanz pins, the mobile joint of the external fixators was adapted statically at 10°–20° flexion and 15° ulnar deviation so as to place them on the proximal pole of the head of the capitulunate joint, which is the center of the rotational movement of the wrist. Distraction was then performed with the aid of the traction unit distal to the fixator. When appropriate reduction and distraction were achieved, the incision sites were sutured and closed with a dressing (Fig. 1).

Results

The median follow-up period of the patients was 20.3 (8–60) months. The median age of the patients was 47.32 (20–76) years. The median ages of the female (n=10, 40%) and male (n=15, 60%) patients were 41.26 (20–75) and 56.4 (44–76) years, respectively. Of the patients, 11 (44%) had right, 13 (52%) had left, and 1 (4%) had fractures on both wrists.

In the etiological evaluation, fractures occurred due to falling on the floor at home (n=5, 20%), on flat ground outside the home (n=9, 36%), and from height (n=6, 24%); traffic accidents (n=4, 16%); and direct trauma (n=1, 4%) (Table 1). Five (19.23%) patients had open fractures. According to the Gustilo–Anderson classification, fractures were classi-

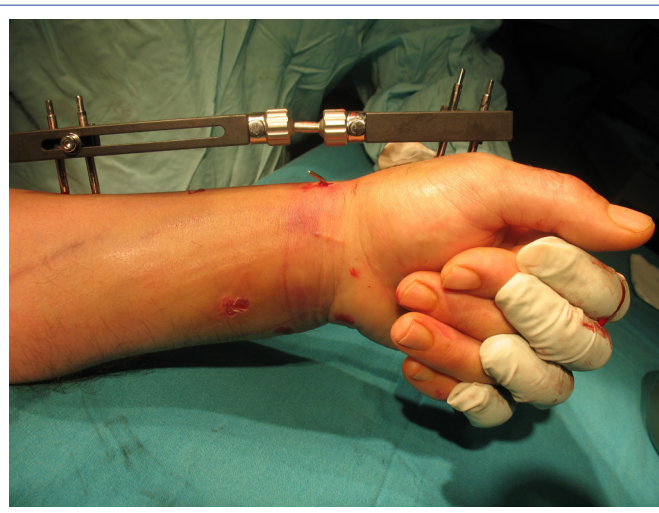

Figure 1. Postoperative evaluation of optimal reduction and distraction.

Table 1. Distribution of etiologies of trauma according to age groups

Age groups (years)	Fall incident at home	Fall on a flat surface outside the home	Fall from height	Traffic accident	Direct trauma	Total
20-29	2					2
30-39	3	2	1			6
40-49	2	1	1	2	1	7
50-59	2	2	1	1		6
60-69	1					1
70≥	3					3
Total (%)	5	9	6	4	1	25
	20	36	24	16	4	100

fied as type I (n=1, 3.85%), II (n=3, 11.53%), and IIIb (n=1, 3.85%) open fractures. According to the Frykman classification, type I–II (n=3.11, 53%), III–IV (n=4, 15.38), V–VI (n=9, 34.61%), and VII–VIII (n=10, 38.46%) fractures were seen in respective number of patients. According to the AO/ASIF classification, type C (n=15, 57.69%), A2–3 (n=9, 34.61%), B1 (n=1, 3.84%), and B3 (n=1, 3.84) displaced fractures were detected. Nine (34.61%) patients had A2–3, 1 (3.84%) patient had type B1, and 1 (3.84%) patient had type B3 displaced fractures.

Patients were operated within an average of 8.52 (1–23) days after hospitalization. Prior to the application of an external fixator, fractures were fixed using closed reduction and percutaneous fixation with K-wires (n=24, 92.3%) and limited open reduction and fixation with K-wires (n=2, 7.7%) in an indicated number of patients. None of the fractures underwent grephonage.

A double articulated dynamic wrist fixator (Pennig external fixator; Orthofix Srl, Italy) was used for 24 out of 25 patients,

and a single articulated dynamic wrist fixator (Stableloc external fixator; Acumed, USA) was used for the remaining patient. Patients were discharged on an average of 3.48 (1–12) days postoperatively. An external fixator was dynamized by loosening its articulated part at the center of the capitulum joint.

After a median period of 6.8 (5–8) weeks, a radiologically adequate union was observed, and the fixators were removed with their fixation wires (Fig. 2). Statistically significant improvements in radial length ($p<0.0001$), radial angulation ($p<0.001$), and palmar inclination ($p<0.001$) of our patients were detected during post-treatment and post-fixation examinations when compared with pretreatment measurements (Table 2).

According to Lidström's radiological–anatomical scoring system, 12 out of 26 (46.15%) distal radius fractures of 25 patients were excellent, 11 (42.30%) were good, and 3 (11.55%) were moderately satisfactory results. Poor outcomes were not obtained in any patient. One patient died

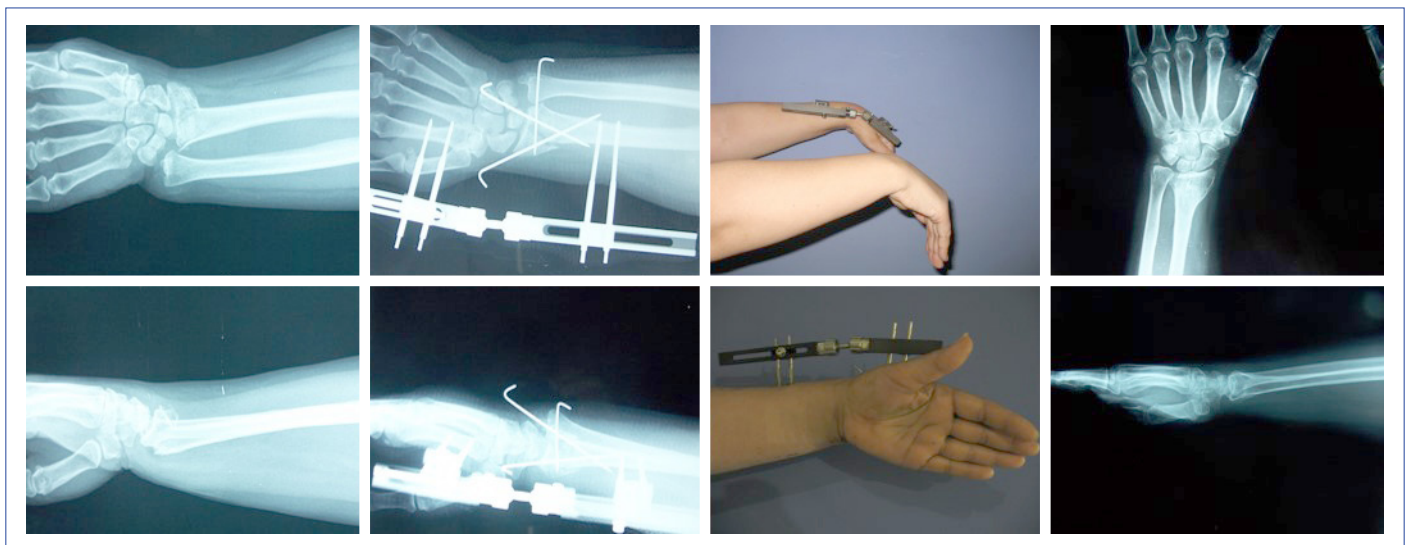
**Figure 2.** AO: C2, Frykman: F8. Radiological and functional results of a 53-year-old female patient with distal radius fracture

Table 2. Comparison of radiological values of the fractured side measured before reduction and after both reduction and removal of the fixator with parameters of the intact side

Period	Radial length (mm) Median	Radial angulation (°) Median	Palmar inclination (°) Median
Robust	11.65	21.92	11.23
Preoperative	0.84	11.15	-17.84
Postoperative	9.88	20.76	2.04
After removal of the fixator	9.11	20.07	1.15

Dorsal angulation was demonstrated as (-) value; $p < 0.001$ (statistically and extremely significant).

of cardiopulmonary arrest on postoperative day 14 and was excluded from the functional follow-up group. According to the clinical scoring system of Gartland–Werley and modified by Sarmiento in cases with 25 distal radius fractures, excellent ($n=24$, 56%), good ($n=8$, 32%), and moderate ($n=3$, 12%) results were achieved in an indicated number of patients. The grip strength of the patients was found to be 87.5%.

Complications

During the early postoperative period, 3 (11.53%) patients developed superficial pin root infection responding to dressings and antibiotics. Reflex sympathetic dystrophy was seen in 2 (7.69%) patients. One (3.84%) patient had hypoesthesia on the area innervated by the sensory branch of the radial nerve. Two (7.69%) patients developed finger stiffness. K-wires applied with a fixator after dynamization were seen to be loosened that required their removal in 2 (7.69%) patients with advanced osteoporosis. The fixator joint completely loosened, and distraction disappeared in week 3 of the control visit in 1 (3.84%) patient with poor cooperation.

Discussion

The basic prerequisite that must be met in the treatment of unstable radius fractures is to bring the radial length, radial inclination, and palmar inclination to the optimal level to provide anatomical repair of the distal radial joint surface.^[10,11]

Altissimi et al.^[12] reported long-term results of their 217 patients who had undergone conservative treatment and observed abnormal radial angulation, dorsal angulation, and radial height; loss of grip strength; pain; and neuropathies. In conclusion, they indicated that in the management of distal radius fractures, conservative treatment should not be the only option.

In his 10-year follow-up study, Warwick^[13] reported that cast application cannot provide adequate radial length,

and that an external fixator should be preferred. We have first tried closed reduction and casting in all our patients. However, we did not insist on conservative treatment in patients without the appropriate reduction criteria. Bradway^[14] reported that he had achieved 80% satisfactory results with internal fixation in the long term in cases with comminuted intraarticular fractures, suggesting open reduction and, if necessary, grafting if articular surface repair cannot be achieved by closed methods.

In their study of 90 patients, Kapoor et al.^[15] stated that the best treatment alternative for unstable intraarticular distal radius fractures is fixation with an external fixator. In our study, we could not achieve joint reduction with closed methods in 2 (7.70%) patients. K-wires and Pennig external fixators were used together with limited open reduction of joints. No grafting was needed in any of our patients.

Klein et al.^[16] treated 103 patients with distal radius fractures using the Pennig-type external fixator, and in 61% of them, they used additional methods, such as K-wires, bone grafting, and radioulnar stabilization. They indicated that with additional treatments, the anatomical integrity of the joints is achieved and maintained more favorably, which exerted a positive effect on the functional outcomes. In our study, all of our patients were managed with an external fixator and K-wires as an additional fixation method.

It has been observed that combining the external fixator with percutaneous K-wire aids in accomplishing both anatomical reduction and also increased stability, allowing for earlier intervention, even in comminuted fractures, by reducing the need for traction, thereby achieving successful results.

When the radiological results of our study were examined, in 23 (88.47%) of our patients, loss of radial length was found to be < 5 mm. Palmar inclination and neutral or volar angulation could be obtained in 17 (65.38%) patients. In our study, the average value of radial angulation was 11.15° before reduction and increased to 20.76° after reduction, whereas it increased to 20.07° after dynamization and removal of the fixator.

In the present study, the easiest and best corrected parameter in accordance with the literature was radial angulation, and the least corrected parameter was dorsal angulation. In cases with excessive dorsal angulation, it has been reported that there were loss of flexion and wrist deformity with a cosmetic appearance of dinner fork deformity due to loss of function.^[17]

Various angulations and shortenings that occur in the wrist can also lead to negative results in hand grip

strength. In their study, Jenkis et al.^[18] reported lost in grip strength when fractures healed with radial shift >2 mm, radial angulation <10°, and dorsal angulation >20°. Cooney^[19] reported that 50% restoration of grip strength is achieved. In our study, this rate was 87.5%. In accordance with the literature findings, we have thought that our high rate of grip strength can be attributed to the ability to restore fractures to the appropriate angle and length with a fixator, initiation of active shoulder elbow and finger movements immediately after surgery, and patients' use of their hands in daily activities and after dynamization process.

Loss of reduction seen after removal of the external fixator is a major problem. Cooney et al.^[14] and Szabo and Weber^[15] reported reduction loss of 4% and 7.6%, respectively. There was no significant loss of reduction in any of the patients in our series. In our study, this is thought to be due to the use of an external fixator in combination with percutaneous K-wires in all of our patients.

Distal radius fractures have higher complication rates. Factors including patients' personal characteristics, presence of osteoporosis, and compliance with treatment influence complication rates. Szabo and Weber,^[20] Solgaard,^[21] and Vaughan^[22] reported the complication rates as 61%, 45%, and 14%, respectively. In our series, complications were seen in 11 (42.3%) patients. None of our complications required termination of therapy and resulted in poor functional outcome. We have not encountered complications, such as tendon rupture, compartment syndrome, and nonunion reported at different rates in the literature as a result of our external fixator application in distal radius fractures.

In conclusion, we consider the use of the Pennig-type dynamic wrist external fixator as a preferable treatment modality for the management of unstable distal radius fractures in that it can be applied easily with minimal surgical trauma; provides earlier rehabilitation, allowing patients to return to their normal daily activities in a short period; and has successful anatomical and functional outcomes.

Disclosures

Ethics Committee Approval: Ethics approval was obtained (decision no. 10840098/159).

Peer-review: Externally peer-reviewed.

Conflict of Interest: None declared.

Authorship contributions: Concept – İ.Ö., E.E.; Design – A.K.; Supervision – E.E.; Materials – A.K.; Data collection &/or processing – A.K., F.S.; Analysis and/or interpretation – A.K., Ş.A.; Literature search – F.S.; Writing – A.K.; Critical review – İ.Ö., Ş.A.

References

1. Ekin A, Yaldiz K, Boya H, Turkyilmaz M: Distal radius kırıklarında açık redüksiyon, plak ve / veya eksternal fiksator uygulamaları. XV Milli Türk Ortopedi ve Travmatoloji Kongre Kitabı. Ankara: Türk Hava Kurumu Basımevi; 1997. p.117-21.
2. Seitz WH, Froimson AI, Brooks DB, Postak P, Polando G, Greenwald AS. External fixator pin insertion techniques: biomechanical analysis and clinical relevance. *J Hand Surg Am* 1991; 16: 560-3.
3. Werber KD, Raeder F, Brauer RB, Weiss S. External fixation of distal radial fractures: four compared with five pins: a randomized prospective study. *J Bone Joint Surg Am* 2003; 85: 660-6.
4. Markiewitz AD, Gellman H. Five-pin external fixation and early range of motion for distal radius fractures. *Orthop Clin North Am* 2001; 32: 329-35.
5. Kreder HJ, Hanel DP, McKee M, Jupiter J, McGillivray G, Swiontkowski MF. Consistency of AO fracture classification for the distal radius. *J Bone Joint Surg Br* 1996; 78: 726-31.
6. Illarramendi A, González Della Valle A, Segal E, De Carli P, Maignon G, Gallucci G. Evaluation of simplified Frykman and AO classifications of fractures of the distal radius. Assessment of interobserver and intraobserver agreement. *Int Orthop* 1998; 22: 111-5.
7. Horn BD, Rettig ME. Interobserver reliability in the Gustilo and Anderson classification of open fractures. *J Orthop Trauma* 1993; 7: 357-60.
8. Sarmiento GW, Zagorski JB, Sinclair WF: Functional bracing of Colles fractures: A prospective study of immobilization in supination, pronation. *Clin Orthop* 1980; 146: 175-183.
9. Gartland Jr JJ, Werjey CW. Evaluation of healed Colles' fractures. *J Bone Joint Surg* 1951; 33: 895-907.
10. Ring D. Intra articular fractures of the distal radius. *J Hand Surg Am* 2002; 2: 60-77.
11. Rogachefsky RA, Lipson SR, Applegate B, Ouellette EA, Savenor AM, McAuliffe JA. Treatment of severely comminuted intra-articular fractures of the distal end of the radius by open reduction and combined internal and external fixation. *J Bone Joint Surg Am* 2001; 83: 509-19.
12. Altissimi M, Antenucci R, Fiacca C, Mancini GB. Long-term results of conservative treatment of fractures of the distal radius. *Clin Orthop Relat Res* 1986; 206: 202-10.
13. Warwick D, Prothero D, Field J, Bannister G. Radiological measurement of radial shortening in Colles' fracture. *J Hand Surg Br* 1993; 18: 50-2.
14. Bradway JK, Amadio PC, Cooney WP. Open reduction and internal fixation of displaced, comminuted intra-articular fractures of the distal end of the radius. *J Bone Joint Surg Am* 1989; 71: 839-47.
15. Kapoor H, Agarwal A, Dhaon BK. Displaced intra-articular fractures of distal radius: a comparative evaluation of results following closed reduction, external fixation and open reduction with internal fixation. *Injury* 2000; 31: 75-9.
16. Klein W, Dee W, Rieger H, Neumann H, Joosten U. Results of

- transarticular fixator application in distal radius fractures. *Injury* 2000; 31: 71-7.
17. Older TM, Stabler EV, Cassebaum WH. Colles Fracture: Evaluation and Selection of Therapy. *J Trauma* 1965; 5: 469-76.
 18. Jenkins NH, Jones DG, Johnson SR, Mintowt-Czyz WJ. External fixation of Colles' fractures. An anatomical study. *J Bone Joint Surg Br* 1987; 69: 207-11.
 19. Cooney WP. Distal radius fractures: external fixation proves best. *J Hand Surg Am* 1998; 23: 1119-21.
 20. Szabo RM, Weber SC. Comminuted intraarticular fractures of the distal radius. *Clin Orthop* 1988; 230: 39-47.
 21. Solgaard S. External fixation or a cast for Colles' fracture. *Acta Orthop Scand* 1989; 60: 387-91.
 22. Vaughan PA, Lui SM, Harrington IJ, Maistrelli GL. Treatment of unstable fractures of the distal radius by external fixation. *J Bone Joint Surg Br* 1985; 67: 385-9.