

RESEARCH ARTICLE

Optical coherence tomography findings as a predictor of clinical course in patients with branch retinal vein occlusion treated with ranibizumab

Akira Shiono, Jiro Kogo*, Hiroki Sasaki, Ryo Yomoda, Tatsuya Jujo, Naoto Tokuda, Yasushi Kitaoka, Hitoshi Takagi

Department of Ophthalmology, St. Marianna University School of Medicine, Kawasaki, Kanagawa, Japan

* kogo@marianna-u.ac.jp



OPEN ACCESS

Citation: Shiono A, Kogo J, Sasaki H, Yomoda R, Jujo T, Tokuda N, et al. (2018) Optical coherence tomography findings as a predictor of clinical course in patients with branch retinal vein occlusion treated with ranibizumab. PLoS ONE 13 (6): e0199552. <https://doi.org/10.1371/journal.pone.0199552>

Editor: Der-Chong Tsai, National Yang-Ming University Hospital, TAIWAN

Received: December 29, 2017

Accepted: June 8, 2018

Published: June 20, 2018

Copyright: © 2018 Shiono et al. This is an open access article distributed under the terms of the [Creative Commons Attribution License](https://creativecommons.org/licenses/by/4.0/), which permits unrestricted use, distribution, and reproduction in any medium, provided the original author and source are credited.

Data Availability Statement: All relevant data are within the paper and its Supporting Information files.

Funding: This work received research funding support from Novartis Pharma K.K. The providers of that funding had no role in study design, data collection and analysis, decision to publish, or preparation of the manuscript.

Competing interests: This work received research funding support from Novartis Pharma K.K. The

Abstract

Purpose

To examine the relationship between optical coherence tomography (OCT) images and clinical course in eyes with branch retinal vein occlusion (BRVO) treated with intravitreal ranibizumab injection (IVR).

Design

Prospective cohort study.

Participants

Thirty eyes of 30 patients with BRVO treated with IVR.

Methods

All patients received 1 initial IVR followed by repeated injections in the pro re nata (PRN) regimen. Correlations between logarithm of minimum angle of resolution best-corrected visual acuity (logMAR BCVA) or number of IVRs after 12 months and OCT parameters including the external limiting membrane (ELM), ellipsoid zone (EZ), interdigitation zone (IZ), and photoreceptor outer segment (PROS) length at first resolution of macular edema (ME) were assessed. Resolution of ME was defined as central foveal thickness <300 μm and the absence of subretinal fluid. OCT parameters influencing BCVA and number of IVRs were evaluated using multivariate analysis. Correlations between nonperfusion areas (NPAs) and thinning areas and changes in retinal thickness of BRVO-affected areas were assessed.

Results

Of the 30 patients, 27 completed this study and were included in the statistical analyses. The mean logMAR BCVA at 3, 6, and 12 months was 0.16 ± 0.19 , 0.09 ± 0.20 , and $0.07 \pm$

funding support received does not alter our adherence to PLOS ONE policies on sharing data and materials. The authors declare no other potential competing interests related to the publication of this paper or the study on which it was based.

Abbreviations: OCT, optical coherence tomography; IVR, intravitreal ranibizumab; BRVO, branch retinal vein occlusion; BCVA, best-corrected visual acuity; SD-OCT, spectral domain optical coherence tomography; ELM, external limiting membrane; EZ, ellipsoid zone; IZ, interdigitation zone; PROS, photoreceptor outer segment; ME, macular edema; NPAs, nonperfusion areas.

0.20, respectively, which improved significantly from baseline at each visit ($p < 0.0001$, respectively), while the mean number of IVRs at 12 months was 3.9 ± 2.2 . The mean number of IVRs for the first resolution of ME was 1.6 ± 0.8 . Eyes with ELM and EZ defects at the points of first resolution of ME were correlated with a significantly lower BCVA at 12 months compared with eyes with preserved ELMs and EZs ($p = 0.035$, $p = 0.002$, respectively). However, eyes with IZ defects at the points of first resolution of ME were not correlated with a significantly lower BCVA at 12 months compared with eyes with preserved IZs ($p = 0.160$). Defects in the EZ at the points of first resolution of ME significantly affected the number of IVRs at 12 months ($p = 0.042$), although the ELM and IZ did not. PROS length at the points of first resolution of ME was significantly correlated with BCVA and number of IVRs at 12 months ($p = 0.006$, $p = 0.0008$, respectively). In multivariate analysis, PROS length at the points of first resolution of ME had the most significant effect on BCVA and number of IVRs ($p = 0.013$, $p = 0.012$, respectively). NPA size on fluorescein angiography and thinning area on OCT within the macular area showed a significant correlation ($p = 0.003$, $r = 0.971$). The retinal thickness of ischemic BRVO-affected areas was significantly less than that of control areas at 10, 11, and 12 months ($p = 0.001$, $p = 0.005$, $p = 0.003$, respectively).

Conclusion

We showed that the 1+PRN regimen may be a useful therapy for ME due to BRVO. In addition, PROS length at points of first resolution of ME appears to be a good indicator of BCVA and number of IVRs in BRVO patients.

Introduction

Branch retinal vein occlusion (BRVO) is a retinal vascular disease and cause of visual loss due to macular edema (ME) and retinal ischemia. The Branch Vein Occlusion Study (BVOS) reported that grid laser photocoagulation increased visual acuity in patients with ME due to BRVO[1]. However, that effect was limited. In 2009, the Standard Care vs Corticosteroid for Retinal Vein Occlusion (SCORE) study showed that intravitreal triamcinolone administration resulted in similar visual improvement but with high rates of intraocular pressure elevation[2]. Recently, anti-vascular endothelial growth factor (VEGF) has been used for the treatment of ME due to RVO, with greater increases in visual acuity compared with laser photocoagulation [3–8].

Several large clinical trials were conducted in which anti-VEGF injections were administered monthly for at least 6 months. After the initial treatment period, anti-VEGF injections were administered on an as-needed basis. Anti-VEGF treatment resulted in marked improvement in visual acuity in patients with BRVO. However, some patients with BRVO-reduced visual acuity continued to require intravitreal anti-VEGF injections, and anti-VEGF therapy is associated with several problems such as the risk of endophthalmitis, retinal detachment, and cardiovascular events as well as cost. Recently, Miwa et al. have reported that one initial intravitreal ranibizumab injection (IVR) and 3 monthly IVR regimens achieved similar functional outcomes at 12 months[9]. Consequently, loading-dose ranibizumab injections in the treatment of ME due to BRVO may be unnecessary.

Previously, several groups including ours[10–17] reported that spectral domain optical-coherence tomography (SD-OCT) findings were indicators of visual function and prognostic

factors in patients with macular disease. OCT is a well-established diagnostic and monitoring tool for vitreomacular disorders. Thus, the clinical course of patients with BRVO treated with IVR may be predicted by OCT findings.

The aim of this study was to examine the relationship between OCT images and clinical findings in eyes with BRVO treated with 1 initial IVR followed by a monthly pro re nata (PRN) regimen (1+PRN).

Methods

This prospective study was approved by the Institutional Review Board of St. Marianna University of Medicine (Kanagawa, Japan), and adhered to the tenets of the Declaration of Helsinki. Study participants provided written informed consent. We registered this study in Clinical Trial Government (<https://clinicaltrials.gov>) (ClinicalTrials.gov Identifier: NCT02144662, registered on March 22, 2014). Thirty patients with ME due to BRVO were enrolled in this study. One death occurred in the 1-year study period, and 2 patients dropped out. Statistical analyses were performed on the results of the 27 patients who completed this study. The BRVO diagnosis was based on fundus examination and fluorescein angiography (FA) findings. Key inclusion criteria were: treatment-naïve patients; age >18 years; ME due to BRVO involving the fovea; and macular thickness >300 μm at the initial visit. Key exclusion criteria were: central retinal vein occlusion; hemi-central retinal vein occlusion; and other chorioretinal disease such as diabetic retinopathy, hypertensive retinopathy, and choroidal neovascularization.

Treatment

All patients received 1 initial IVR followed by a monthly PRN regimen without a loading phase. At monthly visits, repeat injections were administered if there was evidence of ME (mean central foveal thickness [CFT] >300 μm) or subretinal fluid (SRF) at the fovea on OCT images. Eyes with nonperfusion areas (NPAs) >10 optic disc areas (DAs) in size on FA were determined to represent ischemic BRVO, and scatter laser photocoagulation was performed on those eyes at 12 months.

Examination

According to the study protocol, patients were scheduled for monthly monitoring visits during which they underwent a complete visual examination including measurement of the mean logarithm of minimum angle of visual acuity (logMAR) BCVA with a Landolt chart, determination of intraocular pressure, and OCT (Cirrus HD-OCT, Carl Zeiss Meditec, Dublin, CA). Macular morphologic evaluation was determined based on OCT images at each visit. CFT was defined as the mean distance between the inner limiting membrane (ILM) and retinal pigment epithelium (RPE) within a central subfield. CFT measurements were derived from the software (Cirrus 3.0; Carl Zeiss Meditec, Inc.) provided by the manufacturer. Examination of the outer retina including external limiting membrane (ELM), ellipsoid zone (EZ), interdigitation zone (IZ), and photoreceptor outer segment (PROS) length were examined with the Cirrus HD-OCT using 5-line raster scans. PROS length measurement was described in our previous report[15] (Fig 1). To assess retinal perfusion status, all patients underwent FA (Spectralis HRA+OCT, Heidelberg Engineering, Heidelberg, Germany) at 12 months.

The study aimed to identify prognostic factors for the improvement of BCVA and number of IVRs at 12 months, such as OCT parameters of the outer retina at the points of the first resolution of ME. These were examined using multivariate analysis. Resolution of ME was defined as CFT <300 μm and the absence of SRF.

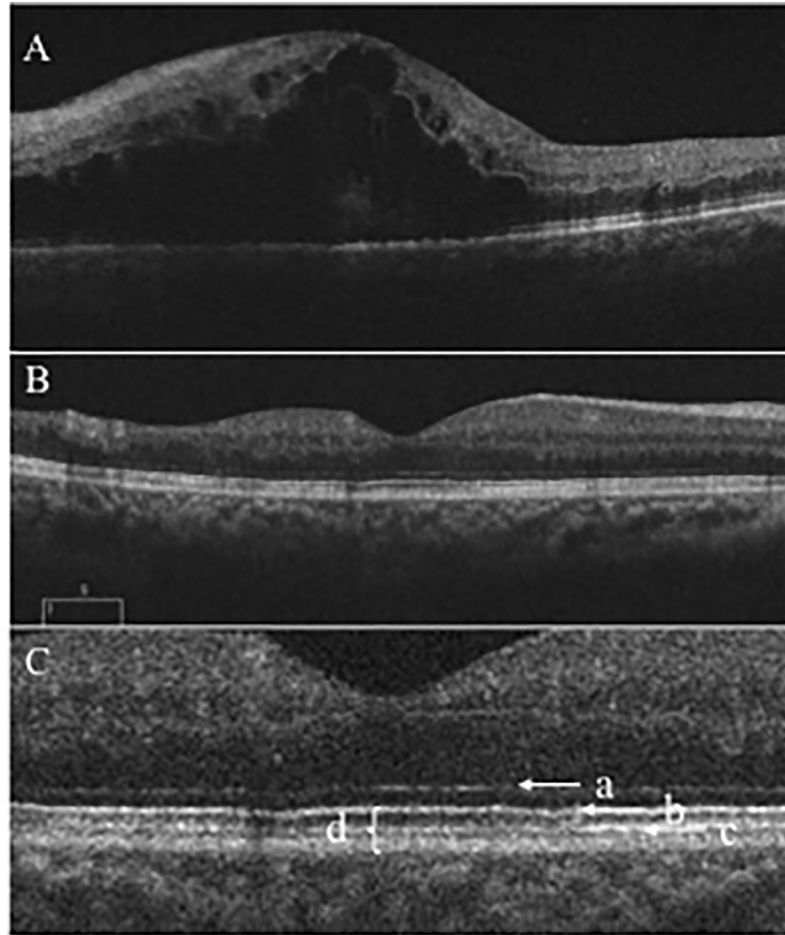


Fig 1. Optical coherence tomography (OCT) image before and after intravitreal ranibizumab injection (IVR). (A) OCT image before IVR. The outer retina was not detected. (B) OCT image at the point of resolution of ME. (C) Enlargement of the OCT image showing the ELM (a), EZ (b), IZ (c), and PROS length (d). ELM = external limiting membrane; EZ = ellipsoid zone; IZ = interdigitation zone; PROS = photoreceptor outer segment.

<https://doi.org/10.1371/journal.pone.0199552.g001>

To examine changes in retinal thickness in the area affected by BRVO, OCT images with no ME (central macular thickness $<300\ \mu\text{m}$) were analyzed by two authors (A.S, H.S). Based on FA findings at 12 months, the patients were divided into two groups: ischemic BRVO (NPAs >10 DAs); and nonischemic BRVO (NPAs ≤ 10 DAs). Based on the report of Lim et al. [18] we defined the BRVO-affected area in the superotemporal BRVO as the outer superior areas of the Early Treatment Diabetic Retinopathy Study (ETDRS) subfield in the Macular Cube 200×200 Combo protocol. We also defined the BRVO-affected area in the inferotemporal BRVO as the outer inferior areas of the ETDRS subfield in the Macular Cube 200×200 Combo protocol. Retinal thickness of the BRVO-affected area was defined as the mean distance between the ILM and RPE at the outer superior or inferior section as defined by the ETDRS grid, which was obtained using the Macular Cube 200×200 Combo protocol at each point of resolution of ME, and the retinal thickness of a symmetric area within the BRVO-affected area was defined as the retinal thickness of the control area (Fig 2). The retinal thicknesses of the ischemic or nonischemic BRVO-affected areas and control areas were used for analysis. The size of manually delineated ischemic areas in FA and thinning areas in OCT images within the macular area ($6\ \text{mm} \times 6\ \text{mm}$) were measured using ImageJ software

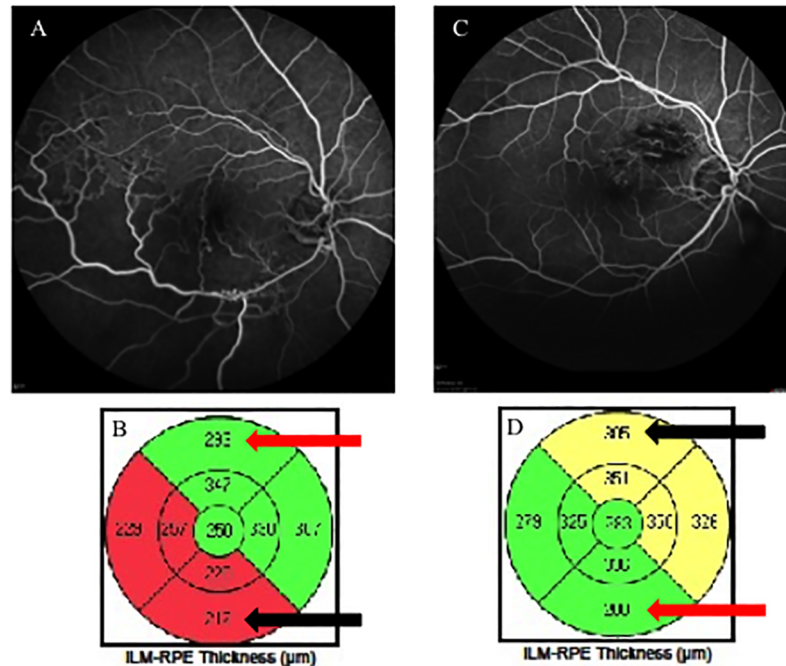


Fig 2. Fluorescein angiography (FA) images and macular cube analysis of branch retinal vein occlusion (BRVO). (A, B) FA images and macular cube analysis of ischemic inferotemporal BRVO. These parameters show the retinal thickness of each sector within the macular area as calculated automatically. The retinal thickness of the BRVO-affected area is shown in the lower section (black arrow), and a symmetrical area was examined to determine the retinal thickness of the control area (red arrow). (C, D) FA images and macular cube analysis of nonischemic superotemporal BRVO. In this case, the retinal thickness of the BRVO-affected area is shown in the upper section (black arrow), and a symmetrical area was examined to determine the retinal thickness of the control area (red arrow).

<https://doi.org/10.1371/journal.pone.0199552.g002>

(National Institutes of Health, Bethesda, Maryland, USA; available at <http://rsbweb.nih.gov>) (Fig 3). Changes in thinning retina within the macular area (6 mm × 6 mm) were evaluated.

Statistical analysis

All statistical analyses were performed using IBM SPSS Statistics ver. 21.0 (IBM Co., Armonk, NY, USA). Data correlations between the status of OCT parameters (ELM, EZ, IZ, and PROS

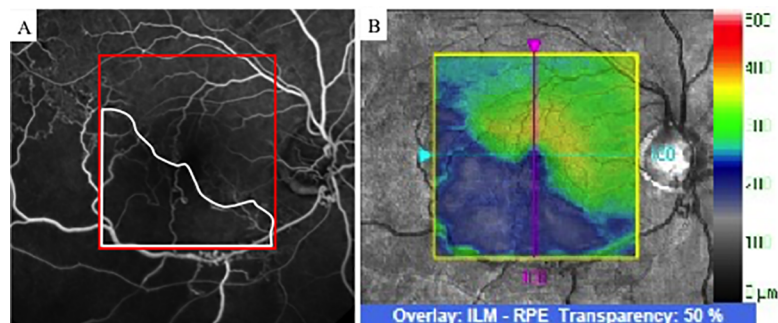


Fig 3. Fluorescein angiography (FA) of ischemic branch retinal vein occlusion (BRVO). (A) FA image of ischemic BRVO. The nonperfusion area is outlined in white. The area indicated by the red square was identical to the OCT image obtained by macular cube scan (200 × 200) (right, indicated by the yellow square). (B) OCT image showing a layer map of retinal thickness. The thinning area is indicated in blue. OCT = optical coherence tomography.

<https://doi.org/10.1371/journal.pone.0199552.g003>

length) and BCVA at 12 months or number of IVRs at 12 months were investigated using the Mann-Whitney U-test and Spearman rank-correlation test. The time-course changes in the retinal thinning area, CFT, and BCVA were analyzed in the Wilcoxon signed-rank test. The retinal thicknesses of the ischemic or nonischemic BRVO-affected areas and control areas were analyzed using the Mann-Whitney U-test. Furthermore, OCT parameters influencing VA and number of IVRs at 12 months were examined using multivariate analysis of variance. A p value of less than 0.05 was considered to represent a statistically significant difference.

Results

Clinical course

The baseline characteristics of patients are shown in Table 1. The mean logarithm of minimum angle of resolution best-corrected visual acuity (logMAR BCVA) at 3, 6, and 12 months was 0.16 ± 0.19 , 0.09 ± 0.20 , and 0.07 ± 0.20 , respectively, which improved significantly from baseline at each visit ($p < 0.0001$, respectively) (Fig 4). The mean CFT at 3, 6, and 12 months was $286 \pm 50 \mu\text{m}$, $289 \pm 76 \mu\text{m}$, and $278 \pm 83 \mu\text{m}$, respectively, and significantly improved from baseline at each visit ($p < 0.0001$, respectively), while the mean number of IVRs at 6 and 12 months was 3.0 ± 1.3 and 3.9 ± 2.2 , respectively. The mean number of IVRs for the first resolution of ME was 1.6 ± 0.8 .

At 12 months, 27 eyes underwent FA examination to determine the presence of NPAs. Fifteen eyes had NPAs, of which 12 had NPAs greater than >10 DAs and therefore scatter laser photocoagulation was performed. Three eyes with NPAs <10 DAs and 12 eyes without NPAs did not undergo scatter laser photocoagulation.

During the follow-up period, none of the patients showed adverse ocular events associated with IVR such as retinal detachment, endophthalmitis, and cataract. None showed neovascular glaucoma and vitreous hemorrhage concomitant with ischemia. One patient exhibited systemic adverse events, and 1 death occurred during the study.

Relationship between outer retinal structure at the points of first resolution of ME and BCVA or number of IVRs at 12 months

At the points of first resolution of ME, defects in the ELM, EZ, and IZ were detected in 22.2% (6/27), 37.0% (10/27), and 81.4% (22/27) of patients, respectively. EZ defects did not completely resolve in any of the eyes, although PROS length could be measured in all. The mean PROS length at the points of first resolution of ME was $43.0 \pm 10.3 \mu\text{m}$. Fig 5 shows the relationship between outer retinal parameters at the points of first resolution of ME and

Table 1. Baseline patient characteristics.

No. of patients	27
Male, n (%)	13 (48)
Age (y), mean \pm SD	62.8 \pm 11.9
Duration of symptoms (weeks), mean \pm SD	4.8 \pm 3.2
Observation period (months), mean \pm SD	21.8 \pm 4.4
Baseline logMAR BCVA, mean \pm SD	0.38 \pm 0.33
Baseline CFT (μm), mean \pm SD	502 \pm 124
History of hypertension, n (%)	19 (70)

SD = standard deviation; logMAR = logarithm of minimum angle of resolution; BCVA = best-corrected visual acuity; CFT = central foveal thickness

<https://doi.org/10.1371/journal.pone.0199552.t001>

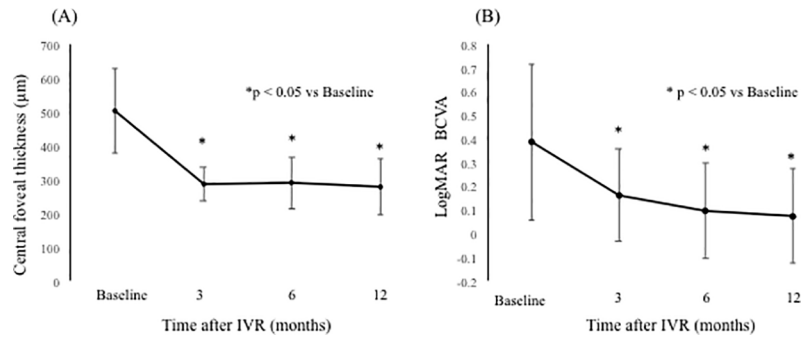


Fig 4. Changes in the mean central foveal thickness (CFT) and mean logarithm of minimum angle of resolution (logMAR) best-corrected visual acuity (BCVA) from baseline to 12 months after intravitreal ranibizumab injection (IVR). (A) CFT and (B) logMAR BCVA from baseline to 12 months after IVR. The CFT and visual acuity at 12 months were significantly improved compared with baseline ($p < 0.05$, respectively). logMAR = logarithm of minimum angle of resolution. IVR = intravitreal ranibizumab injection.

<https://doi.org/10.1371/journal.pone.0199552.g004>

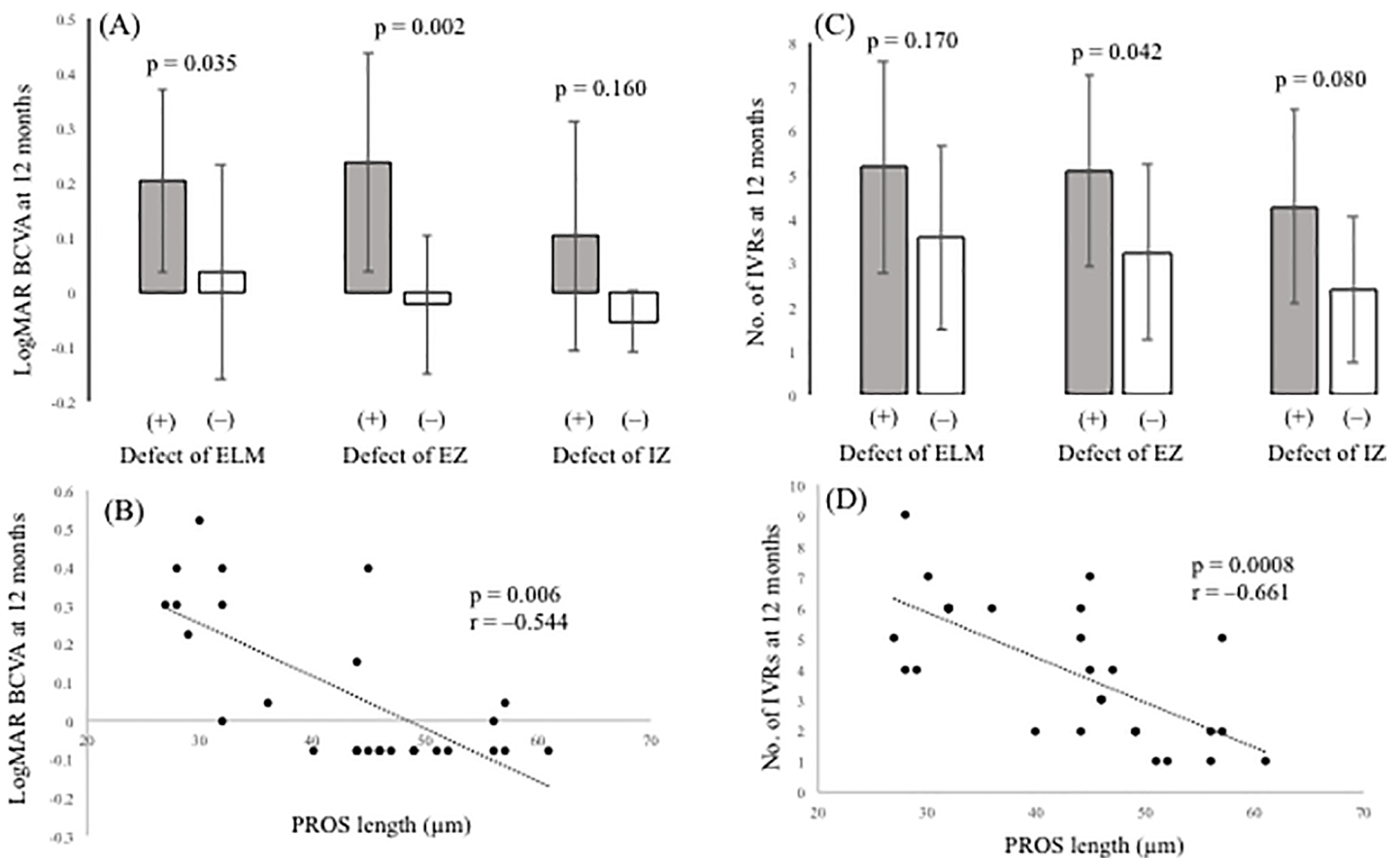


Fig 5. Relationship between optical coherence tomography (OCT) parameters and visual outcome or number of intravitreal ranibizumab injections (IVRs). (A) Correlation between logMAR BCVA at 12 months and the status of the ELM, EZ, and IZ. (B) Correlation between logMAR BCVA at 12 months and PROS length. (C) Correlation between the number of IVRs and the status of the ELM, EZ, and IZ. (D) Correlation between the number of IVRs and PROS length. OCT = optical coherence tomography; logMAR = logarithm of minimum angle of resolution; BCVA = best-corrected visual acuity; IVR = intravitreal ranibizumab injection; ELM = external limiting membrane; EZ = ellipsoid zone; IZ = interdigitation zone; PROS = photoreceptor outer segment.

<https://doi.org/10.1371/journal.pone.0199552.g005>

BCVA or the number of IVRs at 12 months. Eyes with ELM and EZ defects at the points of first resolution of ME were correlated with a significantly lower BCVA at 12 months compared with eyes with preserved ELMs and EZs ($p = 0.035$, $p = 0.002$, respectively). However, eyes with IZ defects at the points of first resolution of ME were not correlated with a lower BCVA at 12 months compared with eyes with preserved IZs ($p = 0.160$). Defects in the EZ at the points of first resolution of ME significantly affected the number of IVRs at 12 months ($p = 0.042$), although defects in the ELM and IZ did not ($p = 0.170$, $p = 0.080$, respectively). PROS length at the points of first resolution of ME was significantly correlated with BCVA and number of IVRs at 12 months ($p = 0.006$, $r = -0.544$ and $p = 0.0008$, $r = -0.661$, respectively).

Factors affecting BCVA and number of IVRs at 12 months in multivariate analysis

In univariate analysis, the EZ and PROS length at the points of first resolution of ME were significantly associated with BCVA and number of IVRs at 12 months. Multivariate analysis of variance was used to compare the EZ and PROS length. The results showed that PROS length at the points of first resolution of ME had the most significant effect on BCVA and number of IVRs at 12 months ($p = 0.013$, $p = 0.012$, respectively) (Table 2).

OCT-based analysis of BRVO-affected areas

NPAs were detected by FA in 15 eyes at 12 months. The NPAs in the macular area with no ME corresponded to the thinning areas detected by the OCT macular cube at 12 months. The thinning area was defined as that indicated in blue on the macular cube scan. On the other hand, in 12 eyes without NPAs, no thinning areas were detected using OCT (Fig 6). NPA size (9.02 ± 5.34 mm) on FA and thinning area (7.22 ± 5.72 mm) on OCT within the macular area ($6 \text{ mm} \times 6 \text{ mm}$) showed a significant correlation (Fig 7, $p = 0.003$, $r = 0.971$). Changes in retinal thickness in BRVO-affected and control areas are shown in Fig 8. The retinal thickness of ischemic BRVO-affected areas after 10 months was significantly less than that of control areas (10 months, $p = 0.001$; 11 months, $p = 0.005$; 12 months, $p = 0.003$). The retinal thickness of nonischemic BRVO-affected areas at each time point was significantly greater than that of control areas (2 months, $p = 0.007$; 3 months, $p = 0.007$, 4 months, $p = 0.043$; 6 months, $p = 0.046$; 7 months, $p = 0.035$; 8 months, $p = 0.042$; 12 months, $p = 0.028$). The retinal thickness of ischemic BRVO-affected areas gradually thinned in most eyes, and a significant reduction was noted from 10 months and sustained until 12 months compared with baseline. Changes in the area of thinning retina within the macular area are shown in Fig 9. The thinning retina area gradually expanded in most eyes.

Table 2. Factors affecting BCVA and number of IVRs at 12 months in multivariate analysis.

Dependent variable	Independent variable	p value
BCVA	EZ	0.102
	PROS length	0.013
Number of IVRs	EZ	0.832
	PROS length	0.001

BCVA = best-corrected visual acuity; EZ = ellipsoid zone; PROS = photoreceptor outer segment; IVR = intravitreal ranibizumab

<https://doi.org/10.1371/journal.pone.0199552.t002>

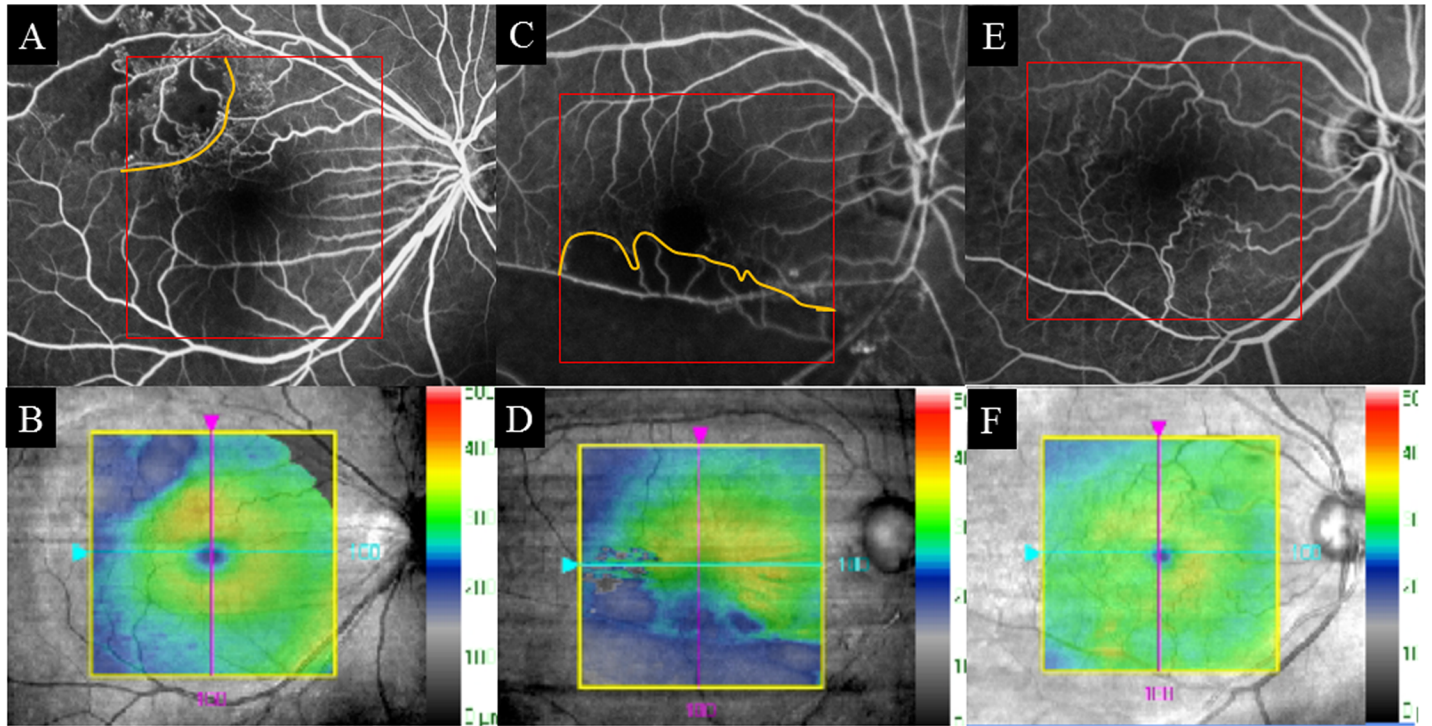


Fig 6. Fluorescein angiography (FA) images and color maps of retinal thickness using optical coherence tomography (OCT) images. (A, C) FA images of eyes with nonperfusion areas (NPAs) (shown in orange). (B, D) Color maps of eyes with NPAs which corresponded to the thinning areas (in blue) detected by OCT. (E) FA of eyes without NPAs. (F) The thinning areas were not detected in OCT.

<https://doi.org/10.1371/journal.pone.0199552.g006>

Discussion

In this study, patients received IVRs on the 1+PRN regimen. VA and CFT significantly improved from baseline to 12 months. An improvement of 0.31 units on the logMAR scale

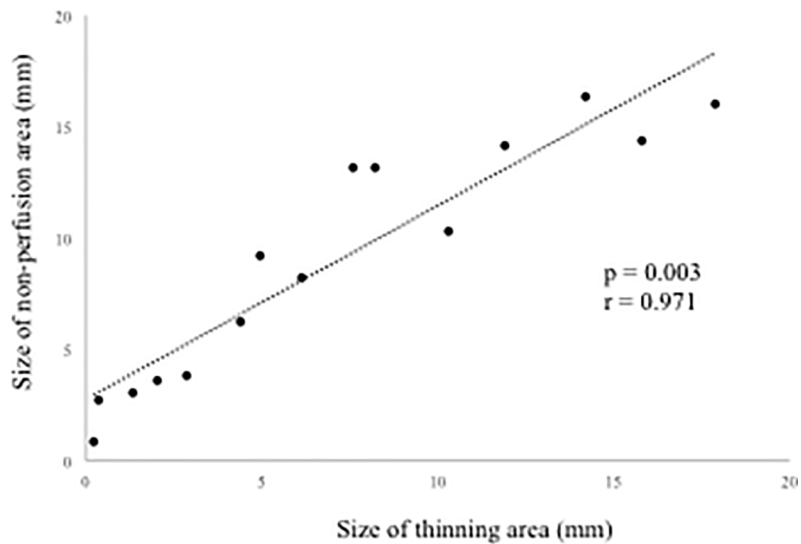


Fig 7. Correlation between nonperfusion areas (NPAs) in fluorescein angiography (FA) and thinning areas in optical coherence tomography (OCT).

<https://doi.org/10.1371/journal.pone.0199552.g007>

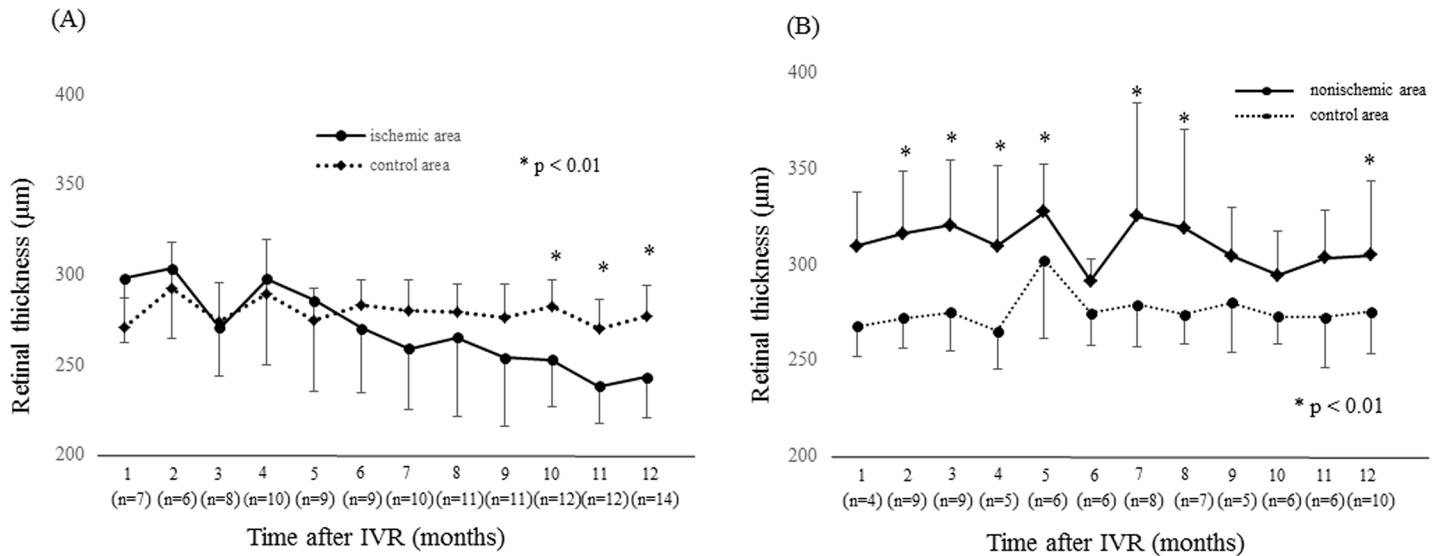


Fig 8. Changes in the retinal thickness of ischemic and nonischemic branch retinal vein occlusion (BRVO). (A) Changes in the retinal thickness of ischemic BRVO-affected areas and control areas at points of resolution of macular edema (ME) from 1 month to 12 months. Retinal thicknesses at point of recurrence of ME were excluded. Retinal thicknesses of ischemic areas after 10 months were significantly less than those of control areas ($p < 0.01$). (B) Changes in the retinal thickness of nonischemic BRVO-affected areas and control areas at points of resolution of ME from 1 month to 12 months. The retinal thickness of nonischemic areas tended to be greater than that of control areas. IVR = intravitreal ranibizumab.

<https://doi.org/10.1371/journal.pone.0199552.g008>

with 3.9 injections during the 12-month period was seen. Ito et al. reported that a single intravitreal injection of bevacizumab (IVB; off-label use) achieved noninferior visual outcomes compared with those achieved by 3 monthly injections in eyes with ME secondary to BRVO [19]. Recently, Miwa et al. [9] have reported a comparison of 1 initial IVR (1+PRN) and 3 monthly IVRs (3+PRN) in patients with ME due to BRVO. In their report, the 1+PRN and 3

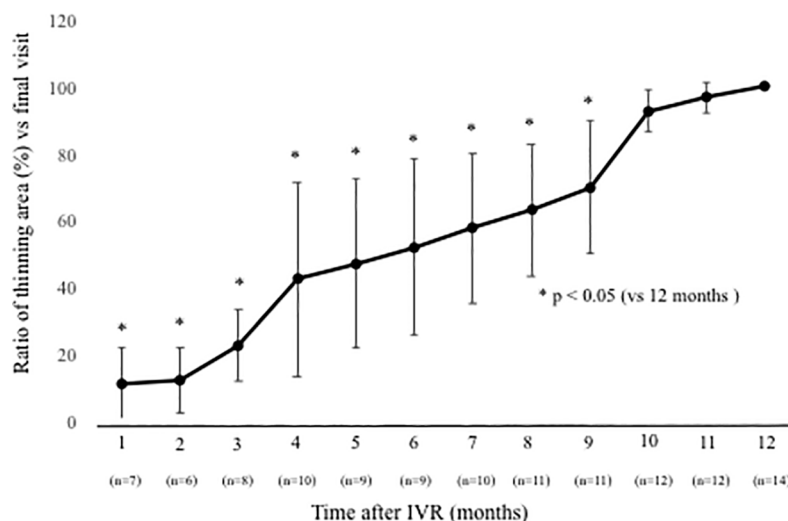


Fig 9. Changes in the ratio of thinning areas within the macular area at points of resolution of macular edema (ME) compared with the final visit. The ratio of the thinning area, which is indicated in blue on the macular cube scan (200 × 200), was defined as the measurement of the thinning area at each visit/measurement of the thinning area at the final visit. Only eyes that met the definition of resolution of ME are included. The ratio of thinning areas gradually increased until 9 months ($p < 0.05$, respectively). IVR = intravitreal ranibizumab.

<https://doi.org/10.1371/journal.pone.0199552.g009>

+PRN regimens achieved similar clinical results, and the mean number of IVRs was 3.8 in the 1+PRN group and 4.6 in the 3+PRN group over 12 months. Our study also yielded comparable results (3.9 in this study), including VA and CFT. Narayanan et al. reported the comparative study of IVR vs IVB with a 6-month 3+PRN regimen (MARVEL study) [20]. In their report, there was no significant difference between the two groups in terms of VA, CFT, and the number of injections, and the mean IVR was 3.2 and mean IVB 3.0 over 6 months. More recently, Pichi et al. have conducted a comparative study of IVR vs aflibercept with the 1+PRN regimen [21]. They reported no significant difference between the two groups in terms of VA, CFT, and number of injections. They administered a mean of 2.8 IVRs and 2.6 intravitreal aflibercept injections over 12 months, comparable with the results of our study. The combined results suggest that the 1+PRN regimen may be a useful therapy for ME due to BRVO and require fewer injections. Minimizing the number of injections may contribute to reducing the risk of systemic complications associated with IVR. However, the current study had one treatment arm without a control group, and direct comparisons with the results of previous clinical trials of ranibizumab [3,4] cannot be made because of differences in the retreatment criteria and follow-up schedule.

For investigation of OCT-based prognostic factors, we examined elements of the outer retina such as the ELM, EZ, IZ, and PROS length, because several authors including us reported that the outer retina morphology is strongly correlated with visual function in patients with vitreoretinal disease [22–29]. Chang et al. [22] found that the postoperative VA was correlated with a restored ELM in patients with macular holes, while Ooka et al. [23] found that the preoperative lengths of ELM defects were significantly correlated with foveal sensitivity after macular hole surgery. Wakabayashi and associates [24] reported that restoration of the foveal ELM in the early postoperative period helped predict better visual outcome in patients with macular holes. Regarding the EZ and IZ, Cheng et al. [25] found that worsening VA was correlated with greater disruption of the EZ and IZ in patients with Behçet's disease. According to Shimozono et al. [26], the status of the EZ and IZ is a useful prognostic factor of the results of epiretinal membrane surgery. Previously, it was reported that intact EZ and ELM and the presence of a foveal bulge at final follow-up are prognostic factors of resolution of ME and better visual improvement. [27,28] In terms of PROS length, Hasegawa et al. [29] noted that PROS length is a good parameter indicating the integrity of foveal photoreceptors in eyes with central serous chorioretinopathy. We also previously reported that PROS length is a strong indicator of visual function and prognostic factor in patients with epiretinal membrane [15]. However, it is occasionally difficult to analyze the outer retina precisely in cases of ME, because OCT signals deteriorate due to the presence of fluid and hemorrhage. Accordingly, we examined OCT images of the outer retina at points of first resolution of ME. In univariate analysis, EZ status and PROS length at first points of ME resolution were significantly correlated with BCVA and number of IVRs at 12 months. In the comparison of EZ and PROS length using multivariate analysis of variance, our results showed that PROS length has a higher correlation with BCVA and number of IVRs than the EZ. This suggests that PROS length is a better indicator of final visual outcome and number of IVRs. Previously, several authors noted that baseline BCVA had prognostic relevance for visual outcome in patients with BRVO treated with anti-VEGF therapy [16,30]. Recently, it has been reported that the number of IVBs in BRVO patients treated with the 1+PRN regimen was significantly less in the better VA group during 12 months. [31] We previously found that PROS length strongly correlated with BCVA, which reflected retinal function¹⁵. Those reports might support the suggested reason for the significant correlation between the status of the outer retina such as the EZ and PROS length and the number of IVRs.

With regard to analysis of retinal thickness in BRVO-affected areas, we found that ischemia-related thinning areas shown on OCT images reflected the NPAs obtained by FA. Several studies indicated that retinal ischemia associated with diabetic retinopathy and RVO induces thinning of the inner retina[32–34]. Ebnetter et al. [35] reported that the thickness of the layers of the outer retina in the ischemic retinal area is well preserved, whereas that of the layers of the inner retina is reduced, in animal models of RVO. The inner retina receives its blood supply from the retinal blood vessels, whereas the outer retina receives its supply mainly from the choroidal circulation. In this study, although there was a trend for reduced retinal thickness between the ischemic BRVO-affected areas and control areas, a significant reduction in the ischemic BRVO-affected area was observed after 10 months. In patients with retinal artery occlusion, Chen et al. [36] confirmed diffuse thickening in the macular area in the acute stage. In contrast, retinal thinning was confirmed in the chronic central retinal artery occlusion phase. In BRVO, the timing of onset and thinning may differ from that in retinal artery occlusion. In nonischemic BRVO, retinal thinning was not confirmed at each time point. Thus, retinal thinning was caused by retinal ischemia, not by perfused BRVO alone.

To the best of our knowledge, this study is the first to demonstrate the clinical course of retinal thinning of NPAs. During observation, the retinal thickness of the ischemic BRVO-affected areas gradually thinned and expanded, and a few months were required for a significant change to be noted. This likely reflects the time required for the ischemia to damage the inner retina, and that damage subsequently became obvious in OCT analysis. More recently, several authors have reported that OCT angiography (OCTA) can detect NPAs[37–39]. Although OCTA is effective in detecting NPAs, OCT alone might be sufficient to detect NPAs. The present results suggest that OCT-based examination of BRVO-affected areas is a useful, safe examination of ischemia in patients with BRVO.

This study had some limitations. A relatively small number of eyes was examined, and the follow-up period was relatively short. Nevertheless, it was the first to demonstrate that the determination of PROS length is useful clinically, since it is an important structural feature that reflects visual function and predicts visual outcome and number of IVRs in patients with BRVO. Examination of thinning retinas during the clinical course can reflect the presence and progression of NPAs in patients with BRVO.

Supporting information

S1 File. Original protocol in Japanese.
(PDF)

S2 File. Original protocol in English.
(PDF)

S3 File. Representative case.
(PDF)

Author Contributions

Conceptualization: Akira Shiono, Jiro Kogo.

Data curation: Akira Shiono, Jiro Kogo, Hiroki Sasaki, Ryo Yomoda, Tatsuya Jujo.

Formal analysis: Akira Shiono.

Funding acquisition: Hitoshi Takagi.

Investigation: Jiro Kogo.

Methodology: Akira Shiono, Jiro Kogo.

Resources: Akira Shiono.

Software: Akira Shiono.

Supervision: Naoto Tokuda, Yasushi Kitaoka, Hitoshi Takagi.

Writing – original draft: Akira Shiono, Jiro Kogo.

Writing – review & editing: Jiro Kogo, Yasushi Kitaoka, Hitoshi Takagi.

References

1. The Branch Vein Occlusion Study Group. Argon laser photocoagulation for macular edema in branch vein occlusion. *Am J Ophthalmol.* 98, 271–282 (1984). PMID: [6383055](#)
2. Scott I. U., Ip M. S., VanVeldhuisen P. C., Oden N. L., Blodi B. A., Fisher M. et al. A randomized trial comparing the efficacy and safety of intravitreal triamcinolone with standard care to treat vision loss associated with macular edema secondary to branch retinal vein occlusion: the Standard Care vs Corticosteroid for Retinal Vein Occlusion (SCORE) study report 6. *Arch Ophthalmol.* 127, 1115–1128 (2009). <https://doi.org/10.1001/archophthalmol.2009.233> PMID: [19752420](#)
3. Campochiaro P. A., Heier J. S., Feiner L., Gray S., Saroj N., Rundle A. C. et al. Ranibizumab for macular edema following branch retinal vein occlusion: six-month primary end point results of a phase III study. *Ophthalmology* 117, 1102–1112 (2010). <https://doi.org/10.1016/j.ophtha.2010.02.021> PMID: [20398941](#)
4. Brown D. M., Campochiaro P. A., Bhisitkul R. B., Ho A. C., Gray S. et al. Sustained benefits from ranibizumab for macular edema following branch retinal vein occlusion: 12-month outcomes of a phase III study. *Ophthalmology* 118, 1594–1602 (2011). <https://doi.org/10.1016/j.ophtha.2011.02.022> PMID: [21684606](#)
5. Trach A. B., Yau L., Hoang C., Tuomi L. Time to clinically significant visual acuity gains after ranibizumab treatment for retinal vein occlusion: BRAVO and CRUISE trials. *Ophthalmology* 121, 1059–1602 (2014). <https://doi.org/10.1016/j.ophtha.2013.11.022> PMID: [24424249](#)
6. Heier J. S., Campochiaro P. A., Yau L., Li Z., Saroj N., Rubio R. G., Lai P. Ranibizumab for macular edema due to retinal vein occlusions: long-term follow-up in the HORIZON trial. *Ophthalmology* 119, 802–809 (2012). <https://doi.org/10.1016/j.ophtha.2011.12.005> PMID: [22301066](#)
7. Campochiaro P. A., Sophie R., Pearlman J., Brown D. M., Boyer D. S., Heier J. S. et al. Long-term outcomes in patients with retinal vein occlusion treated with ranibizumab: the RETAIN study. *Ophthalmology* 121, 209–219 (2014). <https://doi.org/10.1016/j.ophtha.2013.08.038> PMID: [24112944](#)
8. Campochiaro P. A., Clark W. L., Boyer D. S., Heier J. S., Brown D. M., Vitti R. et al. Intravitreal aflibercept for macular edema following branch retinal vein occlusion: the 24-week results of the VIBRANT study. *Ophthalmology* 122, 538–544 (2015). <https://doi.org/10.1016/j.ophtha.2014.08.031> PMID: [25315663](#)
9. Miwa Y., Muraoka Y., Osaka R., Ooto S., Murakami T., Suzuma K. et al. Ranibizumab for macular edema after branch retinal vein occlusion: One initial injection versus three monthly injections. *Retina* 37, 702–709 (2017). <https://doi.org/10.1097/IAE.0000000000001224> PMID: [27471827](#)
10. Puliafito C. A., Hee M. R., Kin C. P., Reichel E., Schuman J. S., Duker J. S. et al. Imaging of macular diseases with optical coherence tomography. *Ophthalmology* 102, 217–229 (1995). PMID: [7862410](#)
11. Ashraf M., Souka A., Adelman R. Predicting outcomes to anti-vascular endothelial growth factor (VEGF) therapy in diabetic macular oedema: a review of the literature. *Br J Ophthalmol.* 100, 1596–1604 (2016). <https://doi.org/10.1136/bjophthalmol-2016-308388> PMID: [27231313](#)
12. Okamoto F., Sugiura Y., Okamoto Y., Hiraoka T., Oshika T. Inner nuclear layer thickness as a prognostic factor for metamorphopsia after epiretinal membrane surgery. *Retina* 35, 2107–2114 (2015). <https://doi.org/10.1097/IAE.0000000000000602> PMID: [25978729](#)
13. Simader C., Ritter M., Bolz M., Deak G. G., Mayer-Sponer U., Golbaz I. et al. Morphologic parameters relevant for visual outcome during anti-angiogenic therapy of neovascular age-related macular degeneration. *Ophthalmology* 121, 1237–1245 (2014). <https://doi.org/10.1016/j.ophtha.2013.12.029> PMID: [24684838](#)
14. Alkabes M., Padilla L., Salinas C., Nucci P., Vitale L., Pichi F. et al. Assessment of OCT measurements as prognostic factors in myopic macular hole surgery without foveoschisis. *Graefes Arch Clin Exp Ophthalmol.* 251, 2521–2527 (2013). <https://doi.org/10.1007/s00417-013-2347-y> PMID: [23695656](#)

15. Shiono A., Kogo J., Klose G., Takeda H., Ueno H., Tokuda N. et al. Photoreceptor outer segment length: a prognostic factor for idiopathic epiretinal membrane surgery. *Ophthalmology* 120, 788–794 (2013). <https://doi.org/10.1016/j.ophtha.2012.09.044> PMID: 23290984
16. Jaissle G. B., Szurman P., Feltgen N., Spitzer B., Pielen A., Rehak M. et al. Predictive factors for functional improvement after intravitreal bevacizumab therapy for macular edema due to branch retinal vein occlusion. *Graefes Arch Clin Exp Ophthalmol.* 249, 183–192 (2011).
17. Kogo J., Shiono A., Sasaki H., Yomoda R., Jujo T., Kitaoka Y. et al. Foveal microstructure analysis in eyes with diabetic macular edema treated with vitrectomy. *Adv Ther.* 34, 2139–2149 (2017). <https://doi.org/10.1007/s12325-017-0598-4> PMID: 28808926
18. Lim H. B., Kim M. S., Jo Y. J., Kim J. Y. Prediction of retinal ischemia in branch retinal vein occlusion: spectral-domain optical coherence tomography study. *Invest Ophthalmol Vis Sci.* 56, 6622–6629 (2015). <https://doi.org/10.1167/iovs.15-17678> PMID: 26465891
19. Ito Y., Saishin Y., Sawada O., Kakinoki M., Miyake T., Sawada T. et al. Comparison of single injection and three monthly injections of intravitreal bevacizumab for macular edema associated with branch retinal vein occlusion. *Clin Ophthalmol.* 9, 175–180 (2015). <https://doi.org/10.2147/OPTH.S76261> PMID: 25657578
20. Narayanan R., Panchal B., Das T., Chhablani J., Jalali S., Ali M. H. A randomised, double-masked, controlled study of the efficacy and safety of intravitreal bevacizumab versus ranibizumab in the treatment of macular oedema due to branch retinal vein occlusion: MARVEL report no. 1. *Br J Ophthalmol.* 99, 954–959 (2015). <https://doi.org/10.1136/bjophthalmol-2014-306543> PMID: 25631483
21. Pichi F, Elbarky A. M., Elhamaky T. R. Outcome of “treat and monitor” regimen of aflibercept and ranibizumab in macular edema secondary to non-ischemic branch retinal vein occlusion. *Int Ophthalmol.* <https://doi.org/10.1007/s10792-017-0798-6> (2017).
22. Chang Y. C., Lin W. N., Chen K. J., Wu H. J., Lee C. L., Chen C. H. et al. Correlation between the dynamic postoperative visual outcome and the restoration of foveal microstructures after macular hole surgery. *Am J Ophthalmol.* 160, 100–106 (2015). <https://doi.org/10.1016/j.ajo.2015.03.019> PMID: 25817009
23. Ooka E., Mitamura Y., Baba T., Kitahashi M., Oshitari T., Yamamoto, S. Foveal microstructure on spectral-domain optical coherence tomographic images and visual function after macular hole surgery. *Am J Ophthalmol.* 152, 283–290 (2011). <https://doi.org/10.1016/j.ajo.2011.02.001> PMID: 21669402
24. Wakabayashi T., Fujiwara M., Sakaguchi H., Kusaka S., Oahima Y. Foveal microstructure and visual acuity in surgical closed macular holes: spectral-domain optical coherence tomographic analysis. *Ophthalmology* 117, 1815–1824 (2010). <https://doi.org/10.1016/j.ophtha.2010.01.017> PMID: 20472291
25. Cheng D., Wan Y., Huang S., Wu Q., Chen Q., Shen M. et al. Macular inner retinal layer thickening and outer retinal layer damage correlate with visual acuity during remission in Behcet’s disease. *Invest Ophthalmol Vis Sci.* 57, 5470–5478 (2016). <https://doi.org/10.1167/iovs.16-19568> PMID: 27760261
26. Shimozono M., Oishi A., Hata M., Matsuki T., Ito S., Ishida K. et al. The significance of cone outer segment tips as a prognostic factor in epiretinal membrane surgery. *Am J Ophthalmol.* 153, 698–704 (2012). <https://doi.org/10.1016/j.ajo.2011.09.011> PMID: 22245463
27. Kang H.M., Chung E.J., Kim Y.M., Koh H.J. Spectral-domain optical coherence tomography (SD-OCT) patterns and response to intravitreal bevacizumab therapy in macular edema associated with branch retinal vein occlusion. *Graefes Arch Clin Exp Ophthalmol.* 251, 501–508 (2013). <https://doi.org/10.1007/s00417-012-2067-8> PMID: 22653439
28. Hasegawa T., Ueda T., Okamoto M., Ogata N. Presence of foveal bulge in optical coherence tomographic images in eyes with macular edema associated with branch retinal vein occlusion. *Am J Ophthalmol.* 157, 300–306 (2014).
29. Hasegawa T., Okamoto M., Masuda N., Ueda T., Ogata N. Relationship between foveal microstructures and visual outcomes in eyes with resolved central serous chorioretinopathy. *Graefes Arch Clin Exp Ophthalmol.* 253, 343–350 (2015).
30. Chung E. J., Hong Y. T., Lee S. C., Kwon O. W., Koh H. J. Prognostic factors for visual outcome after intravitreal bevacizumab for macular edema due to branch retinal vein occlusion. *Graefes Arch Clin Exp Ophthalmol.* 246, 1241–1247 (2008). <https://doi.org/10.1007/s00417-008-0866-8> PMID: 18546006
31. Kim M., Jeong S., Sagong M. Efficacy of intravitreal bevacizumab for macular edema following branch retina vein occlusion stratified by baseline visual acuity. *Graefes Arch Clin Exp Ophthalmol.* 255, 691–697 (2017). <https://doi.org/10.1007/s00417-016-3535-3> PMID: 27796671
32. Unoki N., Nishijima K., Sakamoto A., Kita M., Watanabe D., Hangai M. et al. Retinal sensitivity loss and structural disturbance in areas of capillary nonperfusion of eyes with diabetic retinopathy. *Am J Ophthalmol.* 144, 755–760 (2007). <https://doi.org/10.1016/j.ajo.2007.07.011> PMID: 17868632

33. Sakimoto S., Gomi F., Sakaguchi H., Akiba M., Kamei M., Nishida K. Analysis of retinal nonperfusion using depth-integrated optical coherence tomography images in eyes with branch retinal vein occlusion. *Invest Ophthalmol Vis Sci.* 256, 640–646 (2015).
34. Imai A., Toriyama Y., Iesato Y., Hirano T., Murata T. En face swept-source optical coherence tomography detecting thinning of inner retinal layers as an indicator of capillary nonperfusion. *Eur J Ophthalmol.* 25, 153–158 (2015). <https://doi.org/10.5301/ejo.5000514> PMID: 25264117
35. Ebnetter A., Agca C., Dysli C., Zinkermagel M. S. Investigation of retinal morphology alterations using spectral domain optical coherence tomography in a mouse model of retinal branch and central retinal vein occlusion. *PLOS One* 10, e0119046 (2015). <https://doi.org/10.1371/journal.pone.0119046> PMID: 25775456
36. Chen S. N., Hwang J. F., Chen Y. T. Macular thickness measurements in central retinal occlusion by optical coherence tomography. *Retina* 31, 730–737 (2011). <https://doi.org/10.1097/IAE.0b013e3181f2a15c> PMID: 21242861
37. Hwang T. S., Gao S. S., Liu L., Lauer A. K., Bailey S. T., Flaxel C. J. et al. Automated quantification of capillary nonperfusion using optical coherence tomography angiography in diabetic retinopathy. *JAMA Ophthalmol.* 134, 367–373 (2016). <https://doi.org/10.1001/jamaophthalmol.2015.5658> PMID: 26795548
38. Zhang M., Hwang T. S., Dongye C., Wilson D. J., Huang D., Jia Y. Automated quantification of nonperfusion in three retinal plexuses using projection-resolved optical coherence tomography angiography in diabetic retinopathy. *Invest Ophthalmol Vis Sci.* 57, 5101–5106 (2016). <https://doi.org/10.1167/iovs.16-19776> PMID: 27699408
39. Kimura M., Nozaki M., Yoshida M., Ogura Y. Wide-field optical coherence tomography angiography using extended field imaging technique to evaluate the nonperfusion area in retinal vein occlusion. *Clin Ophthalmol.* 10, 1291–1295 (2016). <https://doi.org/10.2147/OPHTH.S108630> PMID: 27471374