

# Flecainide toxicity in renal tubular acidosis type IV treated with extracorporeal membrane oxygenation



Salima Ahmed Bhimani, MD, MBBS,\* Sruti Rao, MD, MBBS,† Holly Nadorlik, DO,\* Elizabeth V. Saarel, MD, FHRS,\* Peter F. Aziz, MD, FHRS\*

From the \*Department of Pediatric Cardiology, Cleveland Clinic Children's, Cleveland, Ohio, and †Department of Cardiology, Nemours Children's Health System, Wilmington, Delaware.

## Introduction

Flecainide is a class Ic antiarrhythmic medication used for medical management of atrial tachycardia.<sup>1</sup> At therapeutic doses it slows depolarization and conduction through cardiac myocytes, leading to delayed myocardial electrical propagation manifesting as PR prolongation, QRS widening, and QTc prolongation.<sup>2</sup> It is known to have a narrow therapeutic index with potential for proarrhythmic effects, particularly in the setting of impaired clearance, as with renal insufficiency, congestive heart failure, and drug interactions.<sup>3</sup> Fatalities owing to overdose have been reported across all ages.<sup>4</sup> We describe the case of an infant with type IV renal tubular acidosis (RTA) with flecainide overdose owing to administration error leading to hemodynamically unstable ventricular tachycardia (VT) treated with extracorporeal membrane oxygenation and alkalization.

## Case report

A 4-month-old female infant with 16p11.2del, type IV RTA; prenatal diagnosis of a large, perimembranous ventricular septal defect; and right aortic arch with aberrant subclavian artery underwent an uncomplicated repair in the neonatal period. Her electrocardiogram (ECG) at baseline was significant for a right bundle branch block, as shown in [Figure 1A](#). The patient had a history of hemodynamically significant ectopic atrial tachycardia refractory to beta-blockade therapy but responsive to flecainide.

Approximately 3 weeks following initiation of flecainide and 4 days after discharge from a rehabilitation facility she was noted to have decreased activity with occasional staring spells, 1 of which resulted in a brief loss of consciousness, concerning for a seizure, on the day of presentation. Emergency Medical Services was summoned and at arrival, a rhythm strip was remarkable for monomorphic, regular wide complex

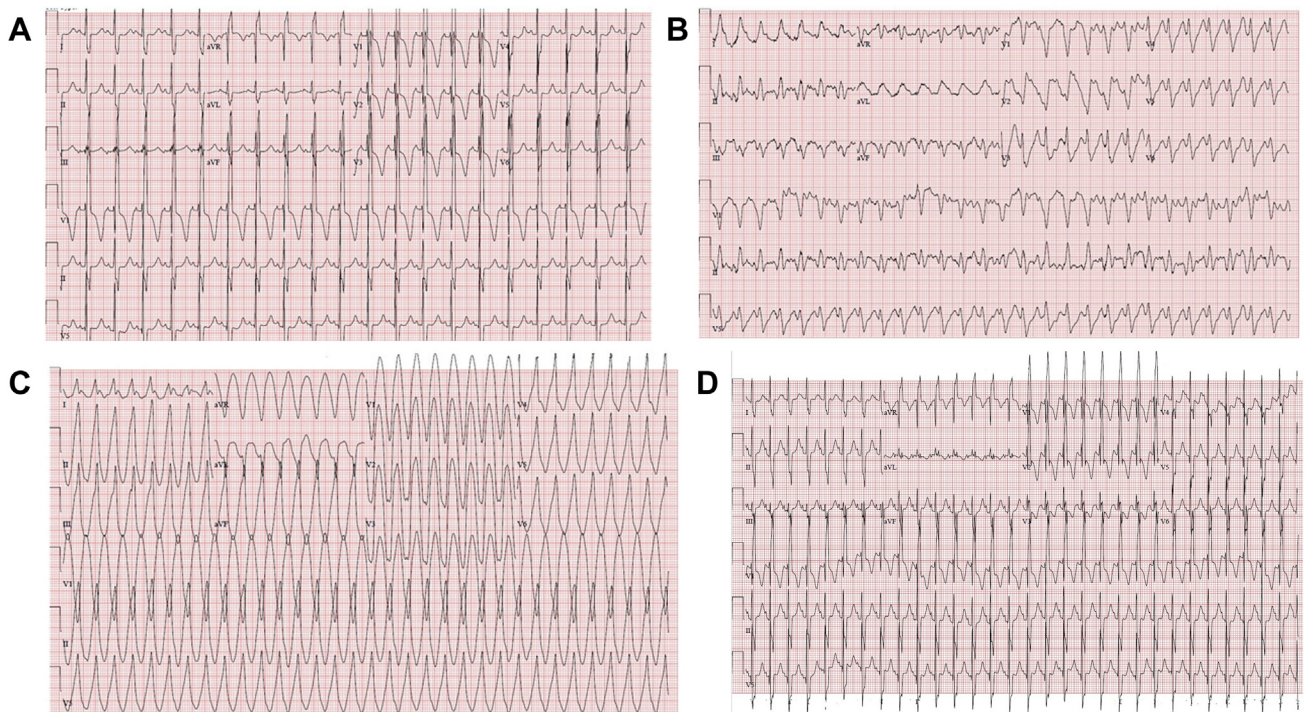
## KEY TEACHING POINTS

- Flecainide has a narrow therapeutic index with potential to become proarrhythmic at toxic levels, leading to fatal ventricular arrhythmias.
- It is metabolized by the liver and undergoes renal clearance. Factors like impaired renal clearance, acidosis, dehydration, and drug interactions act as potential mediators of toxicity.
- Timely recognition of toxicity and use of venoarterial extracorporeal membrane oxygenation may be beneficial in clearance of the drug while providing myocardial rest in clinical scenarios where hemodynamic compromise ensues.
- Primary prevention of flecainide toxicity should be encouraged by educating caregivers with a multidisciplinary team approach prior to discharge.

tachycardia at a rate of 170–180 beats/min while the patient was hemodynamically stable. At arrival to the emergency department a 12-lead ECG was performed, as shown in [Figure 1B](#). The rhythm was consistent with a wide QRS tachycardia. Emergent laboratory investigation was significant for metabolic acidosis and elevated creatinine of 0.65 mg/dL (baseline at 0.4 mg/dL) in the setting of type IV RTA (potassium: 4.2; eGFR: 37.2 mL/min/1.73 m<sup>2</sup>; ALT: 457; AST: 465). Bicarbonate bolus was administered and flecainide levels were drawn. The patient acutely decompensated with hypotension but intact pulses as rhythm degenerated into sustained wide complex tachycardia at rates of 225–240 beats/min, as shown in [Figure 1C](#). Bedside emergent echocardiogram demonstrated severely diminished biventricular function. Owing to continued hemodynamic deterioration, worsening lactic acidosis, low mixed venous saturation, and concern for end-organ dysfunction, she was cannulated successfully to venoarterial extracorporeal membrane oxygenation (VA-ECMO), with almost immediate reversion to sinus tachycardia

**KEYWORDS** Extracorporeal membrane oxygenation; Flecainide toxicity; QTc prolongation; Renal tubular acidosis type IV; Wide complex tachycardia (*Heart Rhythm Case Reports* 2020;6:287–289)

**Address reprint requests and correspondence:** Dr Peter F. Aziz, Pediatric Cardiology Department, Cleveland Clinic Children's, Desk M41, 9500 Euclid Ave, Cleveland, OH 44195. E-mail address: [azizp@ccf.org](mailto:azizp@ccf.org).



**Figure 1** Electrocardiograms (ECG). **A:** Baseline ECG; normal sinus rhythm with complete right bundle branch block (RBBB), QRS 104 ms. **B:** Wide QRS tachycardia (QRS: 162 ms) at initial presentation. **C:** Monomorphic, wide complex ventricular tachycardia at a rate of 200 beats per minute. **D:** ECG at discharge; normal sinus rhythm with complete RBBB, QRS 94 ms.

with wide QRS in the setting of right bundle branch block. Owing to the timely intervention, she did not lose pulse and cardiopulmonary resuscitation did not have to be performed. After a period with myocardial rest on VA-ECMO for 36 hours and serial echocardiograms demonstrating improving function, decannulation was achieved without breakthrough arrhythmia. A detailed history revealed an error in medication administration by caregivers over a course of multiple days with change in syringe volume dispensed at discharge from rehabilitation, resulting in 6 times the prescribed dose. This was likely unrecognized until the clinical manifestation of seizures. Although the flecainide had been administered for a total of 3 weeks, owing to strong suspicion for toxicity flecainide levels were obtained on admission and were mildly supratherapeutic at 1.11  $\mu\text{g}/\text{mL}$  (0.20–1.00  $\mu\text{g}/\text{mL}$ ), consistent with overdose.

After successful decannulation and while antiarrhythmics were withheld, the patient was observed as an inpatient without any breakthrough arrhythmia and was discharged home on an ambulatory monitor for surveillance of asymptomatic atrial tachycardia. The ECG prior to discharge is shown in [Figure 1D](#). Flecainide was not resumed, and no other antiarrhythmic was initiated. To date, the patient remains hemodynamically stable, without any sustained atrial tachycardia, off medical therapy.

## Discussion

Flecainide is a class Ic antiarrhythmic agent with a high affinity for open-state sodium channels (Na channels). Thus,

by delaying phase 0 depolarization, it slows down the conduction in the atria, ventricle, and His-Purkinje fibers, prolonging the refractoriness of ventricular tissue by decreasing intracellular levels of calcium. Na channel-blocking properties increase with increasing heart rate.<sup>5</sup> Bradyarrhythmia and QRS widening are seen in a dose-dependent manner. Flecainide overdose can also manifest as tachyarrhythmia, particularly VT. Experimental studies have postulated nonuniform conduction and prolonging the ventricular myocyte refractory period potentiates development of reentrant circuits that can trigger ventricular arrhythmias.<sup>6</sup>

Flecainide toxicity is a rare and potentially fatal condition. Noncardiac manifestations of toxicity are nonspecific and include nausea, vomiting, and seizures. ECG findings of flecainide toxicity are similar to commonly used Na channel-blocking agents like tricyclic antidepressants and include PR prolongation, QRS widening, and QTc prolongation, with eventual progression to monomorphic VT, as demonstrated in our patient.<sup>7</sup> In the adult population where polypharmacy is common, drug interactions with tricyclic antidepressants and amphetamines can enhance toxicity by additive sodium channel blockade.<sup>6,8</sup> As flecainide levels become supratherapeutic, cardiogenic shock ensues rapidly and can be refractory to chronotropic and inotropic therapies. The electromechanical dissociation from VT, as seen in our patient, can further worsen end-organ perfusion, especially to the kidneys and liver, which are involved in its elimination pharmacokinetics. Our case was unique in that the degree of flecainide toxicity as manifested clinically seemed out of

proportion to the mildly elevated flecainide level, emphasizing the impact that coexisting factors like metabolic acidosis, impaired renal function, and dehydration have in augmenting flecainide toxicity.

Despite correction of electrolytes and supportive therapies, the rapidity of clinical deterioration warrants early activation of VA-ECMO. ECMO offers multiple advantages by supporting cardiopulmonary function and end-organs involved in clearance of the drug. There have been a few case studies in the adult literature citing successful recovery of ventricular function following flecainide toxicity post VA-ECMO<sup>6,9</sup>

Flecainide overdose is challenging to treat owing to its large volume of distribution.<sup>10</sup> This makes it a poorly dialyzable compound. While it is primarily metabolized by the cytochrome system in the liver, at least 30% of the drug is eliminated from the kidney unchanged. Alkalinization with sodium bicarbonate to achieve a pH goal of 7.5–7.55 is thought to decrease the ionized form of flecainide that usually binds to sodium channels, as indicated by narrowing of QRS duration (preferably  $\leq 160$  ms).<sup>11</sup> Recent studies have also supported the use of fat emulsion to decrease the volume of distribution of fat-soluble medications like flecainide.<sup>4</sup>

It is equally important for clinicians to actively address avenues for primary prevention of flecainide toxicity. This can be done by simply educating caregivers in conjunction with pharmacists through practical demonstration and assessing caregiver comfort and ability to administer it safely. The side-effect profile and identifiers of adverse reactions should also be fully explained, with close monitoring on an outpatient basis.

## Conclusion

Flecainide should be used with caution in pediatric patients with impaired renal function. This case highlights the use of VA-ECMO as a bridge to recovery following cardiogenic shock from flecainide overdose in an infant. Clinicians should have a high index of suspicion for flecainide toxicity in patients with impaired renal clearance, acidosis, and dehydration, with early consideration of VA-ECMO as a treatment modality in critically ill patients.

## References

1. Williams J, Panakos A, Pavri BB, Ragupathi L, Valentino MA. Flecainide toxicity: a case report and systematic review of its electrocardiographic patterns and management. *Cardiovasc Toxicol* 2016;17:260–266.
2. Smith A, Gerasimon G. An electrocardiographic series of flecainide toxicity. *Indian Pacing Electrophysiol J* 2019;19:75–78.
3. Tamargo J, Le Heuzey JY, Mabo P. Narrow therapeutic index drugs: a clinical pharmacological consideration to flecainide. *Eur J Clin Pharmacol* 2015;71:549–567.
4. Ellsworth H, Stellpflug SJ, Cole JB, Dolan JA, Harris CR. A life-threatening flecainide overdose treated with intravenous fat emulsion. *Pacing Clin Electrophysiol* 2013;36:e87–e89.
5. Roden DM, Woosley RL. Flecainide. *N Engl J Med* 1986;315:36–41.
6. Vu NM, Hill TE, Summers MR, Vranian MN, Faulx MD. Management of life-threatening flecainide overdose: a case report and review of the literature. *HeartRhythm Case Rep* 2016;2:228–231.
7. Subedi R, Dean RK, Chaudhary A, Szombathy T. Flecainide toxicity in renal failure. *Baylor Univ Med Cent Proc* 2018;31:328–330.
8. Mandawat A, McCullough SA, Gilstrap LG, Yeh RW. Successful treatment of flecainide overdose with sustained mechanical circulatory support. *HeartRhythm Case Rep* 2015;1:137–140.
9. Auzinger GM, Scheinkestel CD. Successful extracorporeal life support in a case of severe flecainide intoxication. *Crit Care Med* 2001;29:887–890.
10. Price JF, Kertesz NJ, Snyder CS, Friedman RA, Fenrich AL. Flecainide and sotalol: a new combination therapy for refractory supraventricular tachycardia in children <1 year of age. *J Am Coll Cardiol* 2002;39:517–520.
11. Barber MJ, Wendt DJ, Starmer CF, Grant AO. Blockade of cardiac sodium channels. Competition between the permeant ion and antiarrhythmic drugs. *J Clin Invest* 1992;90:368–381.