



CASE REPORT

Herpes Zoster Duplex Unilateralis: Two Cases and Brief Literature Review

Jee Hee Son, Bo Young Chung, Hye One Kim, Hee Jin Cho¹, Chun Wook Park

Department of Dermatology, Kangnam Sacred Heart Hospital, Hallym University College of Medicine, Seoul, ¹Department of Dermatology, Chuncheon Sacred Heart Hospital, Hallym University College of Medicine, Chuncheon, Korea

Cases involving dermatomal herpes zoster in two or more locations are rare, especially in immunocompetent patients. When two noncontiguous dermatomes are involved, if affected unilaterally, it is called herpes zoster duplex unilateralis; if bilaterally, bilateralis. Here, we report two cases of herpes zoster duplex unilateralis. A 66-year-old man presented with painful erythematous grouped vesicles on his left scalp, forehead, trunk, and back (left [Lt.] V1, Lt. T8). Histologic findings were consistent with herpetic infection. A 33-year-old woman presented with painful erythematous grouped vesicles and crust on her left forehead and neck (Lt. V1, Lt. C5). Both patients were treated with oral administration of famcyclovir 750 mg/day for seven days. (**Ann Dermatol 28(6) 757~761, 2016**)

-Keyword-

Herpes zoster

INTRODUCTION

A vesicular rash of unilateral distribution limited to a single dermatome is characteristic of herpes zoster (HZ)¹. HZ

affecting two dermatomes or more occurs rarely (<0.5%)². In Korea, 19 cases of multidermatomal HZ, which affected two and more dermatomes, have been reported³⁻¹⁰. When two noncontiguous dermatomes are involved, if affected unilaterally, it is called HZ duplex unilateralis and if bilaterally, HZ duplex bilateralis¹¹. Herein, we present two cases of zoster duplex unilateralis and a review of the previous literature.

CASE REPORT

Case 1

A 66-year-old man presented with 3-day history of pain and erythematous grouped vesicles on his left scalp, forehead, trunk, and back (dermatome left [Lt.] V1, Lt. T8) (Fig. 1). The patient appeared acutely ill; he has a 17-year history of hypertension and diabetes. He was also a chronic alcoholic, consuming 1~2 bottles of alcohol per day. All results of laboratory studies, including a complete blood cell count and liver function tests, were negative or within normal limits, except for a high level of gamma glutamyl transferase. Polymerase chain reaction (PCR) from the blood and serologic tests for anti-varicella-zoster virus (VZV), immunoglobulin G (IgG) showed positive, but anti-VZV IgM was negative. We performed a punch biopsy from the vesicles on the Lt. scalp and Lt. trunk. Skin biopsy from the lesional skin showed intraepidermal blisters with characteristic eosinophilic intranuclear inclusion bodies and acantholytic multinucleated giant cells. Basal vacuolization, necrotic epidermal cells, and lymphocytic infiltration in the upper dermis were noted (Fig. 2). He was diagnosed with HZ involving two noncontiguous unilateral dermatomes (Lt. V1, Lt. T8) and treated with oral administration of famcyclovir 750 mg/day for seven days; wet dressings were done four times weekly, until all the vesi-

Received April 11, 2016, Revised May 18, 2016, Accepted for publication June 16, 2016

Corresponding author: Chun Wook Park, Department of Dermatology, Kangnam Sacred Heart Hospital, 1 Singil-ro, Yeongdeungpo-gu, Seoul 07441, Korea. Tel: 82-2-829-5221, Fax: 82-2-832-3237, E-mail: dermap@hanmail.net

This is an Open Access article distributed under the terms of the Creative Commons Attribution Non-Commercial License (<http://creativecommons.org/licenses/by-nc/4.0>) which permits unrestricted non-commercial use, distribution, and reproduction in any medium, provided the original work is properly cited.

Copyright © The Korean Dermatological Association and The Korean Society for Investigative Dermatology

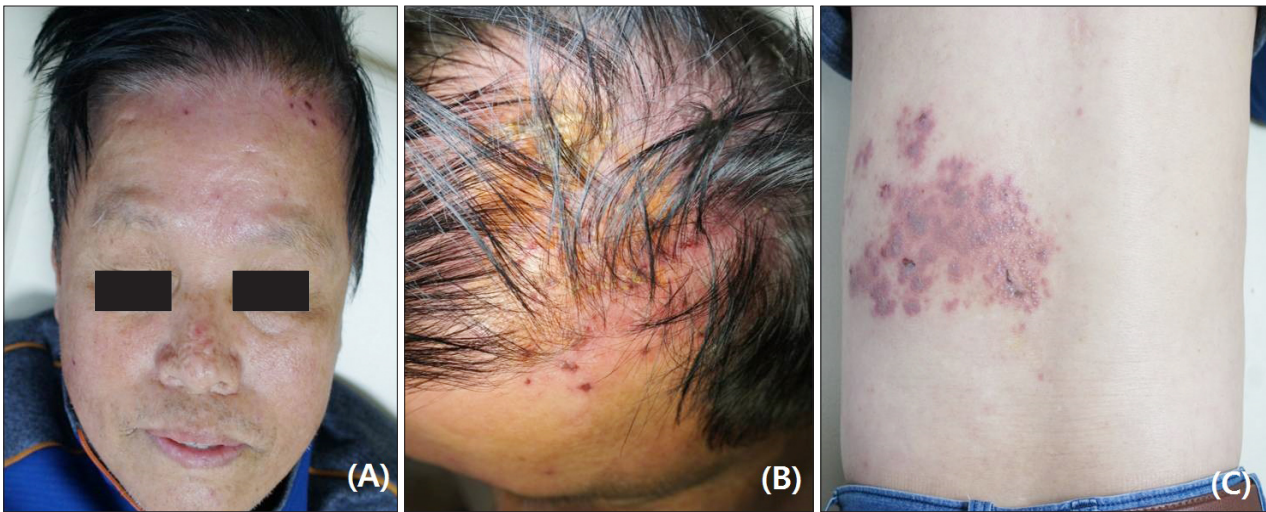


Fig. 1. A 66-year-old man presented with erythematous grouped vesicles on his (A) left scalp, forehead (left [Lt.] V1), (B) trunk, and (C) back (Lt. T8).

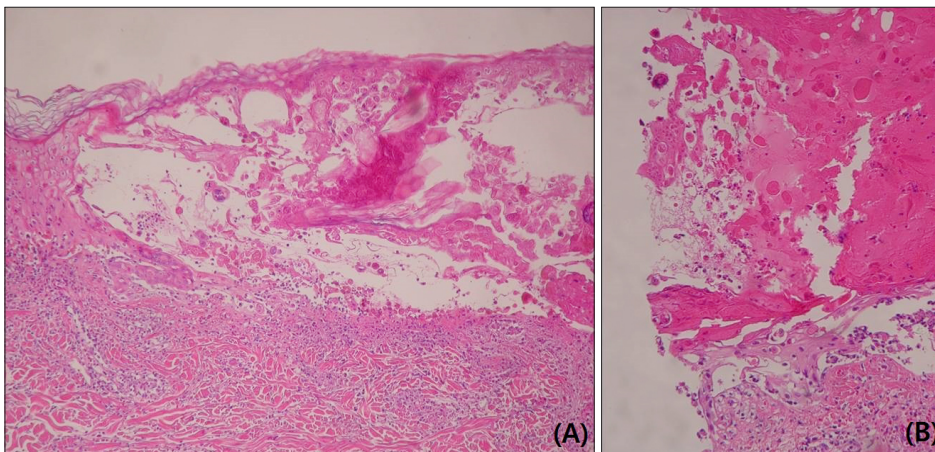


Fig. 2. (A) Skin biopsy from the skin lesion on the scalp shows intraepidermal blisters with characteristic eosinophilic intranuclear inclusion bodies and giant acantholytic multinucleated cells. Basal vacuolization, necrotic epidermal cells, and lymphocytic infiltration in the upper dermis are noted. (B) Skin biopsy from the skin lesion on the trunk also shows intraepidermal blisters with characteristic eosinophilic intranuclear inclusion bodies and acantholytic multinucleated giant cells (H&E, $\times 200$).

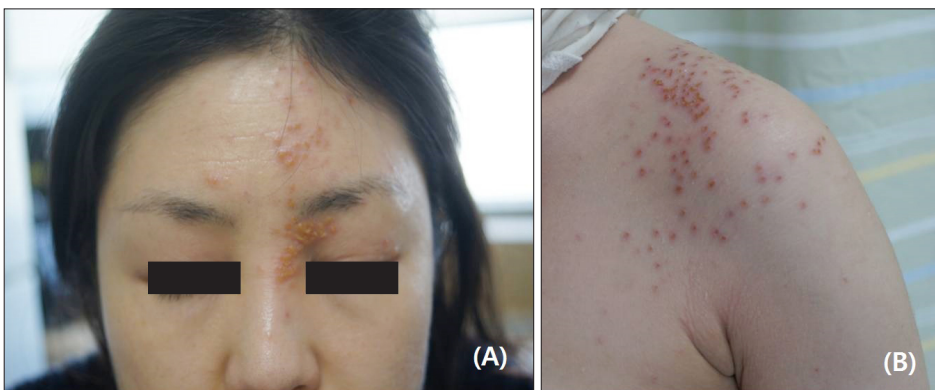


Fig. 3. A 33-year-old woman presented with erythematous grouped vesicles on her (A) forehead (left [Lt.] V1) and (B) neck (Lt. C5).

cles had crusted over. His scalp pain was relieved but pain in his trunk remained. He was transferred to anesthesiologist and a weekly nerve block was performed seven times during the four months since he first visited to our department (dermatology). His pain was improved but

numbness of that area still exists.

Case 2

A 33-year-old woman presented with erythematous grouped vesicles and crust on her left forehead and neck (Fig. 3).

Her pain and skin lesion had started 3~4 days and 1 day, respectively, before she visited our clinic. She had a history of atopic dermatitis (AD) when she was a child and her dyshidrosis began 5 years ago. Until now, tacrolimus ointment had been applied for her skin lesions. Laboratory studies, including a complete blood cell count and liver function tests, were done. All showed negative or within normal limits, except for a high eosinophil count and percentage ($0.77 \times 10^3/\mu\text{l}$, 12.7%). A serologic test and PCR from blood was done. Anti-VZV IgM was negative, but anti-VZV IgG was positive (1,341.0 mIU/ml). She was diagnosed with HZ involving two noncontiguous unilateral dermatomes (Lt. V1, Lt. C5). She was treated with oral administration of famcyclovir 750 mg/day for seven days and wet dressings were done three times. The skin lesions and

pain subsided without complications.

DISCUSSION

HZ is a relatively common disease (10% to 20% lifetime risk of HZ worldwide) and is characterized by several groups of painful vesicles with a characteristic distribution of unilateral dermatomes¹. The incidence rate is slightly different in Korean literature, ranging from 0.38% to 2.84%^{9,12-14}. Patients with malignancy, especially Hodgkin's disease and leukemia, are five times more likely to develop HZ than their age-matched counterparts. Other patients who also have a higher incidence of HZ include patients with deficient immune systems, such as individuals who were immunosuppressed for organ transplantation, by

Table 1. Reported cases with multidermatomal herpes zoster

Reports	Age (yr)/sex	Location	Characteristic finding	Treatment
Jin et al. (1990)	59/F	Lt. C5, Rt. T5	Lymphoma	-
Lee et al. (1994)	5/F	Lt. T2, Rt. T5	-	PO ACV 400 mg/day×5 days No PHN
Jang et al. (1998)	65/M	Rt. V1, Lt. T4	-	-
Kim et al. (1999)	46/F	Rt. L1~2	AIDS	IV ACV 1,500 mg/day×6 days
Bang et al. (2000)	68/M	Lt. V2, Lt. T10	DM, asthma	IV ACV 1,500 mg/day×7 days
Jung et al. (2000)	59/F	Lt. V1~2, Lt. L2	-	IV ACV 750 mg/day×5 days Topical acyclovir
Oh et al. (2001)	4/F	Lt. T4, Rt. T7~8	-	-
Jung et al. (2001)	65/M	Rt. V1, Lt. T4	-	IV ACV 2,500 mg/day×5 days
Shin et al. (2002)	22/F	Rt. T7, Lt. S3	Leukemia	PO FCV 750 mg/day×7 days, No PHN
Kim et al. (2004)	47/F	Rt. T4, Lt. L1	DM, HTN, RA	IV ACV 750 mg/day×5 days, No PHN
Park et al. (2005)	76/M	Rt. V1, Rt. T10, disseminated	Gastric ulcer, COPD	IV ACV 750 mg/day×5 days PHN
Ko et al. (2006)	54/F	Rt. T5~7	Multiple myeloma (recur, Lt. T10 7 months ago)	PO FCV 750 mg/day×7 days
Park et al. (2008)	71/F	Lt. V2, Lt. C4~5, Rt. S2~3, Lt. L1, Rt. T4~5	Non-Hodgkin's lymphoma HTN, DM	IV ACV 1,500 mg/day×7 days
Yoo et al. (2009)	49/F	Rt. T4, Lt. T4	Breast cancer	PO FCV 750 mg/day×7days No PHN
Shin et al. (2009)	67/F	Rt. L4~5, Lt. T7~8	HTN, osteoporosis, lumbar spine compression Fx.	PO FCV 750 mg/day×7 days No PHN
Lim et al. (2009)	49/F	Rt. C7~8, Lt. L2~3	Lung cancer	IV ACV 1,500 mg/day×7 days PHN
Ryu et al. (2010)	42/M	Rt. T4, Lt. T2	HIV	PO FCV 750 mg/day×7 days No PHN
Lee et al. (2011)	23/M	Rt. V1, Lt. V1	-	IV ACV 750 mg/day×7 days No PHN
Yang et al. (2012)	65/F	Lt. C2~5	-	IV ACV 750 mg/day×5 days No PHN

F: female, M: male, Lt.: left, Rt.: right, -: no data, PO: per oral, ACV: acyclovir, PHN: post-herpetic neuralgia, AIDS: acquired Immune deficiency syndrome, IV: intravenous, DM: diabetes mellitus, FCV: famcyclovir, HTN: hypertension, RA: rheumatic arthritis, COPD: chronic obstructive pulmonary disease, Fx.: fracture, HIV: human immunodeficiency virus.

connective tissue disease, and by agents such as corticosteroids¹. Noncontiguous HZ involving multiple dermatomes is very rare in both immunocompetent and immunocompromised patients^{9,10}. The phenomenon of zoster occurring in two noncontiguous dermatomes has been referred to as HZ duplex unilateralis or bilateralis, depending on whether one half or both halves of the body are involved⁵. One article in 1986 reviewed the medical English literature over the last three decades and only seven cases of HZ occurring in noncontiguous dual dermatomes had been reported¹⁵. In 2012, one article reviewed HZ duplex and until then, only 23 cases had been reported¹⁶.

In the Korean medical literature, we reviewed 17 cases of HZ duplex bilateralis or unilateralis (Table 1)³⁻¹⁰. The clinical features of HZ duplex bilateralis or unilateralis in previous reports are as follows; the age of onset varied from four to 76 years of age, but it was more common with advanced age. The affected dermatomes varied from thoracic, trigeminal areas to the lumbar area. It has been reported that HZ duplex is more common among immunocompromised patients^{4,5,15,16}. Castronovo and Nikkels¹⁶ reviewed 23 cases of HZ duplex worldwide and the majority of the adult and pediatric cases had immunosuppression, leukemia, or lymphoma. In the Korean medical literature, more than half of the cases of HZ duplex bilateralis or unilateralis, patients also had acute leukemia, lymphoma, or malignancy such as lung cancer, rheumatoid arthritis, diabetes mellitus, hypertension, asthma, chronic obstructive lung disease, gastric ulcer, or human immunodeficiency virus infection. Among them, there were five cases of zoster duplex bilateralis or unilateralis in immunocompetent patients, and one of our cases was also an immunocompetent patient.

Reported cases involving two noncontiguous dermatomes showed reduced cell immunity more frequently than cases with only one dermatome¹². Kim et al.¹² performed multi-cell mediated immunity testing in 88 patients and found differences in cell immunity depending on the number of dermatomes involved.

HZ duplex is the ultimate clinical proof that VZV remains latent in the majority of sensory dorsal root ganglia¹⁶. It is hypothesized that the highest viral genome load leads to clinical HZ. Concurrent VZV-specific immunoboosting induced by the HZ eruption probably prevents other eventual reactions from becoming expressed clinically. Only in cases of severe immunosuppression, VZV can be reactivated in multiple dorsal root ganglia and initiate multi-dermatomal HZ¹⁶. This might be due to secondary hematogenous infection¹⁶. A new VZV infection might occur hematogenously when VZV was already latent in more than two dermatomes⁶.

In our cases, the male patient was aged and had a history of hypertension, diabetes, and chronic alcoholism. We speculate that he was in an immunocompromised state that led to defective cellular immune response, allowing the development of zoster duplex unilateralis. The female patient had a history of AD and dyshidrosis with a quiet long period of tacrolimus ointment application. Even tacrolimus ointment functions as an immunosuppressant; however, it had been reported that the use of topical tacrolimus for the treatment of AD is not associated with an increase in HZ as side effect¹⁷. But, it can be considered that dysfunction of cell-mediated immunity in AD patients can increase susceptibility to HZ. It is reported that patients who had previously been hospitalized in childhood because of severe AD had a significantly higher incidence of HZ than non-atopic controls¹⁸.

Treatment for patients with HZ duplex was the same as the common treatment for HZ, which included an anti-viral agent, pain management, and care of the skin lesions. The skin lesions and pain subsided without complications in our female patient. However, the male patient had to be transferred to anesthesiologist due to postherpetic neuralgia. A weekly nerve block was performed seven times during four months. HZ duplex showed prognosis similar to that for HZ with only one nerve ganglion involved. It seems that HZ duplex is not a risk factor for poor prognosis and postherpetic neuralgia¹⁶.

ACKNOWLEDGMENT

This work was supported by the National Research Foundation of Korea (NRF) funded by the Ministry of Science, ICT & Future Planning (NRF-2014R1A1A3A04049491), and the Hallym University Research Fund 2014 (HURF-2014-53, HURF-2014-58).

REFERENCES

1. Odom RB, James WD, Berger TG. *Andrews' diseases of the skin: clinical dermatology*. 9th ed. Philadelphia: W.B. Saunders Co., 2000:473-525.
2. Vu AQ, Radonich MA, Heald PW. Herpes zoster in seven disparate dermatomes (zoster multiplex): report of a case and review of the literature. *J Am Acad Dermatol* 1999; 40:868-869.
3. Akladios FN, Nadvi NA, Park J, Hanrahan JR, Kapoor V, Gorrell MD, et al. Design and synthesis of novel inhibitors of human kynurenine aminotransferase-I. *Bioorg Med Chem Lett* 2012;22:1579-1581.
4. Lee SY, Choi YS, Yu HJ, Son SJ. A case of bilateral herpes zoster. *Korean J Dermatol* 1994;32:1119-1122.
5. Jung GD, Won JY, Choi YH, Jeon YM, Song ES. A case of zoster duplex unilateralis. *Korean J Dermatol* 2000;38:

- 1569-1570.
6. Jung BC, Lee SH, Kim SW. A case of herpes zoster duplex bilateralis. *Korean J Dermatol* 2001;39:614-616.
 7. Kim SJ, Kang JD, Yoon NH, Park SD. A case of herpes zoster duplex bilateralis. *Korean J Dermatol* 2004;42:367-369.
 8. Park SH, Lee SY, Yi JH, Choi HS, Yun SK, Kim HU, et al. A case of herpes zoster duplex unilateralis with herpes zoster generalisatus. *Korean J Dermatol* 2005;43:1579-1581.
 9. Shin BJ, Shim JH, Seo SJ, Hong CK. A case of zoster duplex bilateralis. *Ann Dermatol* 2002;14:59-62.
 10. Shin JW, Kim DH, Whang KU, Lee J, Park Y, Cho MK, et al. A case of zoster duplex bilateralis. *Ann Dermatol* 2009;21:423-425.
 11. Thomas SL, Hall AJ. What does epidemiology tell us about risk factors for herpes zoster? *Lancet Infect Dis* 2004;4:26-33.
 12. Kim SY, Cho BH, Kim JH. A 5-year clinical study on herpes zoster: 1990-1994. *Korean J Dermatol* 1997;35:266-272.
 13. Chun IK, Lee JJ, Won YH, Kim YP. Clinical study on relation between herpes zoster and underlying diseases. *Korean J Dermatol* 1988;26:356-365.
 14. Kim YP, Suh JI, Kahng JB. Clinical observation of herpes zoster during a 10-years-period (1968-1977). *Korean J Dermatol* 1980;18:65-79.
 15. Cousin GC, Ferguson MM. Bilateral shingles. *Br Dent J* 1986;160:189.
 16. Castronovo C, Nikkels AF. Chronic herpes zoster duplex bilateralis. *Acta Derm Venereol* 2012;92:148-151.
 17. Fleischer AB Jr, Ling M, Eichenfield L, Satoi Y, Jaracz E, Rico MJ, et al. Tacrolimus ointment for the treatment of atopic dermatitis is not associated with an increase in cutaneous infections. *J Am Acad Dermatol* 2002;47:562-570.
 18. Rystedt I, Strannegard IL, Strannegard O. Recurrent viral infections in patients with past or present atopic dermatitis. *Br J Dermatol* 1986;114:575-582.