

Cataract in keratoconus: Six-month results and a comparison of standard intraocular lens power calculation formulas

Reeda B. Said^{1,2}, Chahid Farah^{1,2}, Wassef Chanbour³, Elias Jarade^{1,2,4}

Access this article online
Quick Response Code:

Website: www.saudijophthalmol.org
DOI: 10.4103/sjopt.sjopt_184_21

Abstract:

PURPOSE: To report the results of cataract surgeries in keratoconus patients at 1 and 6 months postoperatively, and to compare the standard intraocular lens (IOL) calculation formulas in this population.

METHODS: This is a retrospective study, carried out in 44 eyes of 26 patients known to have keratoconus who underwent cataract surgery at Beirut Eye and ENT Specialist Hospital between 2010 and 2021. The patients were divided into groups based on Dr Jarade updated algorithm. Visual acuities before and after cataract surgery, at 1 and 6 months were recorded, as well as spherical equivalent. The difference between the expected spherical equivalent with each formula was subtracted from the actual resultant refraction, and its absolute value deduced. The means of the values were calculated and the 4 standard formulas (SRK/T, SRK/II, Holladay, and Hoffer Q) were compared.

RESULTS: Six eyes had similar topographic and manifest axes (category 1) and underwent toric IOL implantation. Corrected distance visual acuity (CDVA) at 1 and 6 months was 0.2 and 0.1 logMAR, respectively. 26 eyes had mismatching axes and had monofocal IOL placement. CDVA at 1 and 6 months was 0.3. Six eyes required intrastromal corneal ring placement before operating (category 3). CDVA was 0.3 and 0.2 at 1 and 6 months, respectively. Regarding category 4, requiring keratoplasty and cataract extraction, CDVA was 0.4 at both follow-ups. No statistically significant difference was found between the different formulas.

CONCLUSION: Categorization of keratoconus patients gave favorable results after cataract surgery. No superior IOL formula was found.

Keywords:

Astigmatism, biometry, cataract, ectasia, intraocular lens, spherical equivalent

INTRODUCTION

Keratoconus is a progressive form of corneal ectasia for which an etiology has not been fully elucidated.^[1] And as the name implies, it's characterized by conical changes to the shape of the cornea, with associated thinning and irregular astigmatism and resultant visual disturbances. It affects both eyes, though commonly in variable proportion. It affects both males and females, with predilection for the Asian population relative to Caucasians.^[1] Different modalities have been employed for stabilization, most notably collagen crosslinking,^[2] and visual rehabilitation. The latter have classically ranged from the least invasive to the most, including spectacles, contact lenses,

intraocular ring segments (ICRS),^[3] implantable collamer lenses,^[4] refractive cataract surgery (clear lens extraction), and penetrating keratoplasty (PKP)^[5] in advanced disease.

As life expectancy has increased,^[6] and with advancement in the techniques of cataract extraction, the incidence of cataract surgery has steadily surged.^[7,8] With this, the postoperative refractive expectations have also increased.^[9] Keratoconus patients are no strangers to this. In fact, it has been shown that cataract occurs earlier and more frequently in this population.^[10] It's more challenging, however, to achieve target results for these patients for multiple reasons. These have included abnormality in the tear film and corneal multifocality^[11] that may affect the topographic measurement, which is paradigm

This is an open access journal, and articles are distributed under the terms of the Creative Commons Attribution-NonCommercial-ShareAlike 4.0 License, which allows others to remix, tweak, and build upon the work non-commercially, as long as appropriate credit is given and the new creations are licensed under the identical terms.

For reprints contact: WKHLRPMedknow_reprints@wolterskluwer.com

How to cite this article: Said RB, Farah C, Chanbour W, Jarade E. Cataract in keratoconus: Six-month results and a comparison of standard intraocular lens power calculation formulas. Saudi J Ophthalmol 2022;36:201-6.

¹Department of Ophthalmology, Faculty of Medicine, Lebanese University, ²Department of Ophthalmology, Beirut Eye and ENT Specialist Hospital, Beirut, Lebanon, ³Beth Israel Deaconess Medical Center, Boston, Massachusetts, USA, ⁴Mediclinic Dubai Mall, Dubai, United Arab Emirates

Address for correspondence:

Dr. Elias Jarade,
Beirut Eye Specialist Hospital,
Al-Mathaf Square, P. O. Box
116-5311, Beirut, Lebanon.
E-mail: ejarade@yahoo.com

Submitted: 30-Jul-2021

Revised: 21-Nov-2021

Accepted: 20-Feb-2022

Published: 29-Aug-2022

in the preoperative evaluation. It can also be affected by previous surgical manipulation of the cornea as mentioned before. Moreover, the relationship between the anterior and posterior corneal surfaces differs from the norm.^[12] This affects the calculation of lens power, which is also determined by estimated lens position, affected in turn by the longer axial length and anterior chamber depth in keratoconic patients.^[13] Therefore, standard intraocular lens (IOL) calculation formulas have given variable results, leading to hyperopic surprises in many cases.^[13]

This study was conducted to report the results of cataract surgeries in keratoconus patients at 1 and 6 months postoperatively, and to compare the standard IOL formulas in this population.

METHODS

This is a retrospective study, carried out in patients known to have keratoconus who underwent cataract surgery at Beirut Eye and ENT Specialist Hospital (Beirut, Lebanon). The database was accessed for patients with stable keratoconus undergoing surgery between January 2010 and January 2021. To note that all patients were older than 18 years of age and had cataract surgery in one or both eyes.

Forty-four eyes of 26 patients fulfilled these criteria. Visual acuity before and after cataract surgery, at 1 and 6 months were recorded, as well as spherical equivalent. Preoperatively, topographic findings were recorded from the WaveLight® Allegro Oculyzer™ (WaveLight, GmbH, Erlangen, Germany), and biometric findings from the IOL Master 700 (Carl Zeiss Meditec AG). The Amsler-Krumeich classification was used to help classify the patients. History of previous keratoconus treatment was recorded.

In adherence with Dr. Jarade's algorithm^[14] for cataract management in keratoconus, eyes with advanced ectasia and/or scarring underwent combined cataract surgery with PKP or deep anterior lamellar keratectomy (DALK). On the other hand, eyes with a history of good preoperative corrected distance visual acuity (CDVA) before the development of cataractous changes, underwent cataract surgery with implantation of an aspheric monofocal IOL, in case of significant difference between the astigmatism axes of the manifest refraction and the topography, or a toric IOL if these axes match. Other patients with low CDVA that could benefit from ICRS, underwent ring segment implantation ahead of cataract surgery.

All surgeries were performed by a single surgeon (E. J.) and the cataract surgeries were either performed through a clear corneal wound by phacoemulsification or open-sky when combined with PKP. Location of IOL and any complications were noted. In cases of suboptimal visualization during cataract surgery, a customized rigid gas permeable lens was used to decrease distortions.^[15]

Uncorrected distance visual acuity (UDVA) and CDVA were recorded using the logMAR scale and compared at 1 and

6 months with preoperative VA. Statistical calculations for means were performed using descriptive statistics on MS Excel 2016. The difference between the expected spherical equivalent with each formula was subtracted from the actual resultant refraction, and its absolute value deduced. The means of the values were calculated (mean predictive error and mean absolute error, respectively). The four standard formulas (SRK/T, SRK/II, Holladay, and Hoffer Q) were compared based on these results using the Welch analysis on IBM SPSS Statistics for Windows, version XX (IBM Corp., Armonk, N.Y., USA).

RESULTS

Forty-four eyes of 26 patients were included in this study. The overall average patient age at time of surgery was 60.3 years. Average axial length, mean keratometry (Km), and central corneal thickness are recorded in Table 1. Preoperatively, UDVA mean was 1.2, and the mean CDVA was 0.6. After cataract surgery, UDVA improved significantly to 0.6 at 1 month and remained as such at 6 months. Similarly, CDVA improved postoperatively at 1 and 6 months to 0.3. The average spherical equivalent also improved from -6.51 before surgery to -0.53 at 1 month and -0.83 at 6 months. The average corneal preoperative astigmatism was 3.81. The average postoperative astigmatism at 6 months was 2.84. Moreover, the more prevalent astigmatism was with the rule (20 eyes, 45.4%), whereas 16 eyes (36.4%) had against-the-rule, and 8 eyes (18.2%) had oblique astigmatism. No surgical complications were reported.

Patients were divided according to Dr. Jarade's algorithm (updated), as shown in Figure 1. Visual acuity at 1 and 6 months is reported in Table 2 for the different categories.

Mild keratoconus and stable topography

Thirty-two eyes had stable topography with good CDVA. Of these, six fulfilled the criterion of category 1 having similar topographic and manifest axes. They underwent cataract extraction with toric IOL implantation. CDVA at 1 and 6 months was 0.2 and 0.1, respectively. The remaining 26 eyes included eyes in the 4 Amsler stages. These had mismatching axes and thus cataract extraction was accompanied by monofocal IOL placement. CDVA at 1 and 6 months was 0.3, improving from 0.5 before surgery.

Moderate and severe keratoconus

The remaining 12 eyes were divided equally between category 3, requiring intrastromal corneal ring placement before operating, and category 4 showing advanced disease, with or without corneal scars, requiring combined keratoplasty and cataract extraction. For category 3, the mean spherical equivalent before surgery was -5.65 and decreased to +0.33 at 1 month and stabilized at +0.55D at 6 months. This was accompanied by an improvement in UCVA from 1 logMAR before surgery to 0.6 at 6 months postoperatively, with comparable CDVA of 0.2 logMAR before and 6 months after surgery. Regarding category 4, spherical equivalent postoperatively was +2.15 and +2.35 at 1 and 6 months

Table 1: Average age at time of surgery, as well as preoperative measured axial length, mean keratometry, and central corneal thickness, divided according to the 4 categories of keratoconus and staged based on Amsler classification

Average	Category									
	1		2				3		4	
	Stage 2	Stage 3	Stage 1	Stage 2	Stage 3	Stage 4	Stage 2	Stage 3	Stage 4	Stage 4
Number of eyes	5	1	9	5	6	6	3	1	2	6
Age at surgery (years)	56.5		62.49				46.5		66.17	
AL (mm)	24.49		25.8				24.6		24.7	
Preoperative Km (D)	45.37		49.58				49.52		66.73	
Central corneal thickness (microns)	492.5		461.2				458.2		399	

Km: Keratometry, AL: Axial length

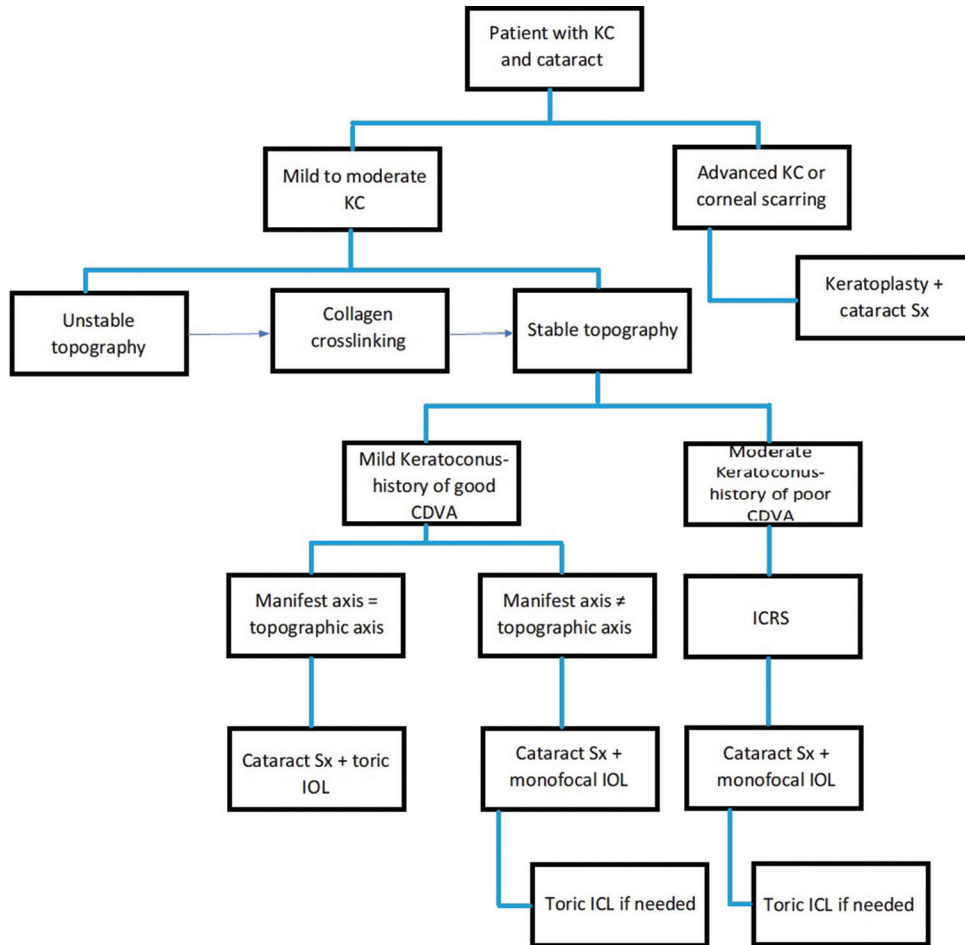


Figure 1: Dr. Jarade’s updated algorithm for the management of cataract in eyes with keratoconus. CDVA: Corrected distance visual acuity, IOL: Intraocular lens, ICL: Implantable collamer lens, ICRS: Intrastromal corneal ring segments, PKP: Penetrating keratoplasty

respectively, with CDVA of 0.4, an increase from 1.2 before the “triple procedure.”

Considering the overall values, no statistically significant difference was found between the different formulas ($P > 0.05$) with regard to mean predictive [Table 3] and absolute error [Table 4]. Most formulas resulted in a hyperopic shift postoperatively, except SRK-2 showing mean myopic results after cataract surgery.

Of note, we report a case in category 4, which underwent combined cataract surgery with DALK procedure. Preoperative

UDVA was 1 logMAR with nonmeasurable refraction. Standard k readings were employed for IOL calculation. At 1 and 6 months postoperatively, CDVA was 0.5. The patient was followed over a year after which vision improved to 0 logMAR with only 1 diopter of astigmatism.

DISCUSSION

Cataract occurrence in patients with keratoconus presents a disturbance in the visual acuity in patients with basic suboptimal vision and a challenge to ophthalmologists

Table 2: Average spherical equivalent, uncorrected distance visual acuity in logarithm minimum angle of resolution, and corrected distance visual acuity, at baseline before surgery, and at 1 and 6 months after surgery

Average	Category									
	1		2			3			4	
	Stage 2	Stage 3	Stage 1	Stage 2	Stage 3	Stage 4	Stage 2	Stage 3	Stage 4	Stage 4
Number of eyes	5	1	9	5	6	6	3	1	2	6
Preoperative means										
SE (D)	-3.35			-7.06			-5.65			-7.33
UDVA (logMAR)	0.5			1.2			1			1.42
CDVA (logMAR)	0.46			0.5			0.2			1.2
Postoperative means										
1 month										
SE (D)	0.75			-1.32			0.33			2.15
UDVA (logMAR)	0.2			0.5			0.7			0.7
CDVA (logMAR)	0.1			0.3			0.3			0.4
6 months										
SE (D)	0.96			-1.88			0.55			2.35
UDVA (logMAR)	0.2			0.6			0.6			0.7
CDVA (logMAR)	0.1			0.3			0.2			0.4

SE: Spherical equivalent, UDVA: Uncorrected distance visual acuity, CDVA: Corrected distance visual acuity, LogMAR: Logarithm minimum angle of resolution

Table 3: Mean predictive error of the 4 formulas at 1 and 6 months with 2 standard deviations, divided according to the 4 categories of keratoconus

Average	Category				P
	1	2	3	4	
Number of eyes	6	26	6	6	
Mean predictive error, months (D±2×SD)					
SRK/T					
1	0.94±2×1.15	0.11±2×2.31	0.85±2×0.88	2.36±2×3.27	0.43
6	1.44±2×1.83	0.17±2×1.88	1.07±2×0.63	2.69±2×3.35	0.64
SrK2					
1	0.54±2×1.73	-2.28±2×2.37	0.31±2×0.30	2.03±2×3.59	0.43
6	1.04±2×2.47	-1.94±2×2.16	0.35±2×0.28	2.37±2×3.45	0.37
Hoffer Q					
1	1.225±2×0.61	0.59±2×2.39	1.22±2×1.20	2.7±2×3.35	0.22
6	1.73±2×1.24	0.54±2×2.11	1.44±2×0.99	3.03±2×3.54	0.24
Holladay 1					
1	1.24±2×1.07	0.53±2×2.55	1.06±2×1.12	2.53±2×3.29	0.23
6	1.74±2×1.62	0.24±2×3.08	1.28±2×0.93	2.86±2×3.43	0.43

No significant difference was found ($P>0.05$). SD: Standard deviation, SRK II: Sanders-Retzlaff-Kraff formula

targeting good refractive outcomes. IOL power calculation in this population has multiple hurdles, most importantly accurate measurement of k readings, but also of axial length.^[16] Depending on the stage of keratoconus, ectasia can affect Km measurements to a variable degree. Moreover, the assumed index of refraction in normal corneas cannot be applied in ectatic ones due to different relationships between anterior and posterior corneal surfaces.^[16]

All four categories, divided as such as per Dr. Jarade's updated algorithm [Figure 1], had favorable visual outcomes. Thebpatiphat *et al.* conducted a retrospective case series with 12 eyes in 2007 and found similar results when dividing the patients into three categories based on mean Km.^[17] The mean postoperative CDVA in this study was 0.2 logMAR.

Cataract surgery with implantation of toric IOL has been previously described in mild keratoconus^[18] with good visual acuity results. We share these results and recommend toric IOL placement in patients with stable topography and matching refractive and topographic axes. On the other hand, patients with irregular astigmatism, are more likely to benefit from spherical monofocal IOL implantation.

ICRS followed by IOL implantation has been described in 70 eyes with good visual outcomes.^[19] We found similar results in category 3 of our patients. Moreover, the improvement of corneal astigmatism in 1 eye after ICRS, allowed placement of a toric IOL.

In cases of very advanced disease (corneal scarring, hydrops), combined procedure was done to remove the diseased

Table 4: Mean absolute error of the 4 formulas at 1 and 6 months with 2 standard deviations, divided according to the 4 categories of keratoconus

Average	Category				P
	1	2	3	4	
Number of eyes	6	27	6	6	
Mean absolute error (D±2×SD)					
SRK/T					
1	1.13±2×0.85	1.73±2×1.48	1.10±2×0.41	2.57±2×3.02	0.34
6	1.63±2×1.57	1.46±2×1.48	1.07±2×0.63	3.16±2×2.67	0.37
Srk2					
1	1.19±2×1.14	2.55±2×2.06	0.31±2×0.30	2.15±2×3.49	0.68
6	1.70±2×1.86	2.26±2×1.81	0.35±2×0.28	2.73±2×3.02	0.68
Hoffer Q					
1	1.23±2×0.61	1.82±2×1.61	1.40±2×0.93	2.95±2×3.02	0.47
6	1.73±2×1.24	1.64±2×1.39	1.44±2×1.00	3.53±2×2.76	0.19
Holladay 1					
1	1.24±2×1.07	1.88±2×1.75	1.24±2×0.86	2.75±2×3.01	0.23
6	1.74±2×1.62	1.93±2×2.37	1.28±2×0.93	3.34±2×2.71	0.08

No significant difference was found ($P>0.05$). SD: Standard deviation, SRK II: Sanders-Retzlaff-Kraff formula

cornea (either by penetrating^[20] or deep anterior lamellar keratoplasty^[21]) and cataract. This would be done either by open-sky technique or phacoemulsification. This “triple procedure” was preferred over sequential approach for faster visual rehab.^[20] The six eyes undergoing this procedure had good short-and long-term results.

Studies have showed that IOL calculation formulas usually result in hyperopic error, with less predictability as ectasia worsens.^[13] This matches with the results of our study except for SRK2 which gave a more myopic result. There has been some controversy regarding the IOL formula preferred in this population.^[13,15] Some argued that SRK2 may be more accurate in mild disease, others found SRKT to be overall more precise in keratoconus. Our study found no statistically significant difference between the different formulas in the four categories of the disease. A bigger sample would be needed to find if one of these formulas is superior in 1 category or another.

While reports have described complications of clear corneal incision in keratoconus,^[10,22] including the possibility of progression of ectasia, no significant complications were reported in our study population. Moreover, at 6 months postoperatively, patients had stable visual acuity.

Our study was limited by the number of patients and therefore further studies with a bigger sample and longer follow-up are warranted. Despite good visual outcomes, patients should be always made well aware of the potential residual ametropia postoperatively and the possible need of spectacles, contact lenses, or implantable collamer lenses.^[14]

CONCLUSION

We conclude that, in light of the above results in this study population, no superior IOL-calculation formula was found in keratoconus patients with cataract. 6-month follow-up of

patients divided according to the aforementioned algorithm maintained favorable visual outcomes emphasizing the importance of appropriate selection and categorization.

Financial support and sponsorship

Nil.

Conflicts of interest

There are no conflicts of interest.

REFERENCES

- Vazirani J, Basu S. Keratoconus: Current perspectives. *Clin Ophthalmol* 2013;7:2019-30.
- Wollensak G, Spoerl E, Seiler T. Riboflavin/ultraviolet-a-induced collagen crosslinking for the treatment of keratoconus. *Am J Ophthalmol* 2003;135:620-7.
- Colin J, Cochener B, Savary G, Malet F. Correcting keratoconus with intracorneal rings. *J Cataract Refract Surg* 2000;26:1117-22.
- Antonios R, Dirani A, Fadlallah A, Chelala E, Hamade A, Cherfane C, et al. Safety and visual outcome of visian toric ICL implantation after corneal collagen cross-linking in keratoconus: Up to 2 years of follow-up. *J Ophthalmol* 2015;2015:514834.
- Pramanik S, Musch DC, Sutphin JE, Farjo AA. Extended long-term outcomes of penetrating keratoplasty for keratoconus. *Ophthalmology* 2006;113:1633-8.
- GHE: Life Expectancy and Healthy Life Expectancy. WHO; 2021. Available from: <https://www.who.int/data/gho/data/themes/mortality-and-global-health-estimates/ghe-life-expectancy-and-healthy-life-expectancy#:~:text=Globally%2C%20life%20expectancy%20has%20increased, reduced%20 years%20lived%20 with%20disability.> [Last accessed on 2021 Jul 27].
- Gollogly HE, Hodge DO, St Sauver JL, Erie JC. Increasing incidence of cataract surgery: Population-based study. *J Cataract Refract Surg* 2013;39:1383-9.
- Erie JC, Baratz KH, Hodge DO, Schleck CD, Burke JP. Incidence of cataract surgery from 1980 through 2004: 25-year population-based study. *J Cataract Refract Surg* 2007;33:1273-7.
- Hawker MJ, Madge SN, Baddeley PA, Perry SR. Refractive expectations of patients having cataract surgery. *J Cataract Refract Surg* 2005;31:1970-5.
- Moshirfar M, Walker BD, Birdsong OC. Cataract surgery in eyes with keratoconus: A review of the current literature. *Curr Opin Ophthalmol* 2018;29:75-80.

11. Jarade EF, Abdelmassih Y, El-Khoury S. Reply. *Am J Ophthalmol* 2017;181:183-4.
12. Piñero DP, Nieto JC, Lopez-Miguel A. Characterization of corneal structure in keratoconus. *J Cataract Refract Surg* 2012;38:2167-83.
13. Wang KM, Jun AS, Ladas JG, Siddiqui AA, Woreta F, Srikumaran D. Accuracy of intraocular lens formulas in eyes with keratoconus. *Am J Ophthalmol* 2020;212:26-33.
14. Arej N, Chanbour W, Zaarour K, Amro M, El-Rami H, Harb F, *et al.* Management of cataract in keratoconus: Early visual outcomes of different treatment modalities. *Int J Ophthalmol* 2019;12:1654-8.
15. Chanbour W, Harb F, Jarade E. A modified customized rigid gas permeable contact lens to improve visualization during phacoemulsification in ectatic corneas. *Med Hypothesis Discov Innov Ophthalmol* 2020;9:1-6.
16. Bozorg S, Pineda R. Cataract and keratoconus: Minimizing complications in intraocular lens calculations. *Semin Ophthalmol* 2014;29:376-9.
17. Thebpatiphat N, Hammersmith KM, Rapuano CJ, Ayres BD, Cohen EJ. Cataract surgery in keratoconus. *Eye Contact Lens* 2007;33:244-6.
18. Kamiya K, Shimizu K, Miyake T. Changes in astigmatism and corneal higher-order aberrations after phacoemulsification with toric intraocular lens implantation for mild keratoconus with cataract. *Jpn J Ophthalmol* 2016;60:302-8.
19. Alfonso JF, Lisa C, Fernández-Vega Cueto L, Poo-López A, Madrid-Costa D, Fernández-Vega L. Sequential intrastromal corneal ring segment and monofocal intraocular lens implantation for keratoconus and cataract: Long-term follow-up. *J Cataract Refract Surg* 2017;43:246-54.
20. Seitz B, Langenbucher A, Viestenz A, Dietrich T, Kühle M, Naumann GO. Cataract and keratoplasty – Simultaneous or sequential surgery? *Klin Monbl Augenheilkd* 2003;220:326-9.
21. Muraine MC, Collet A, Brasseur G. Deep lamellar keratoplasty combined with cataract surgery. *Arch Ophthalmol* 2002;120:812-5.
22. Bourges JL. Cataract surgery in keratoconus with irregular astigmatism. In: Goggin M, editor. *Astigmatism: Optics, Physiology and Management*. Croatia: InTech; 2012.